



SOLACI
SOCIEDAD
LATINOAMERICANA
DE CARDIOLOGIA
INTERVENCIONISTA

**XLIV Jornadas
SOLACI**

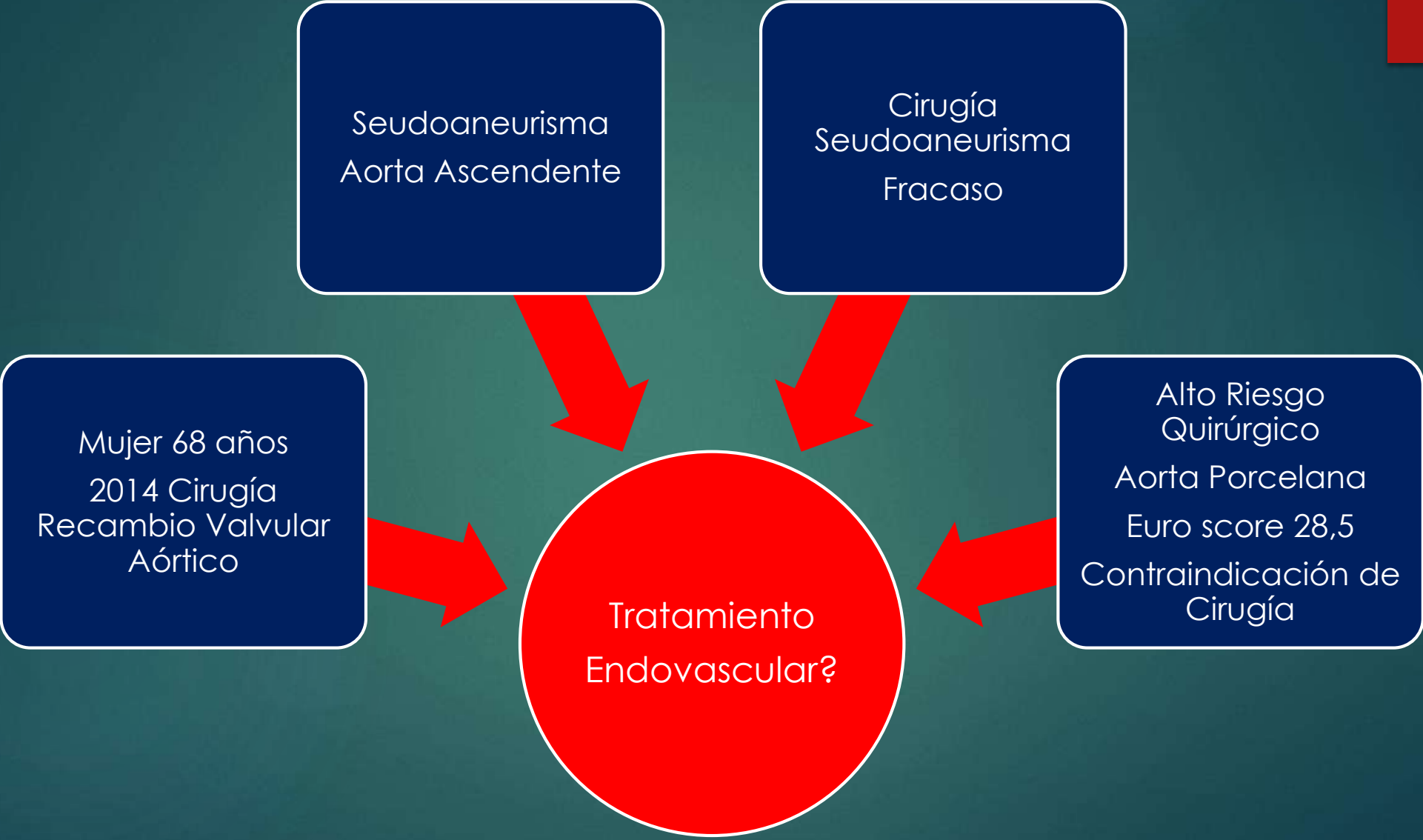
15° Región Cono Sur

30 de junio / 01 de julio

Tratamiento Endovascular de la Aorta Ascendente

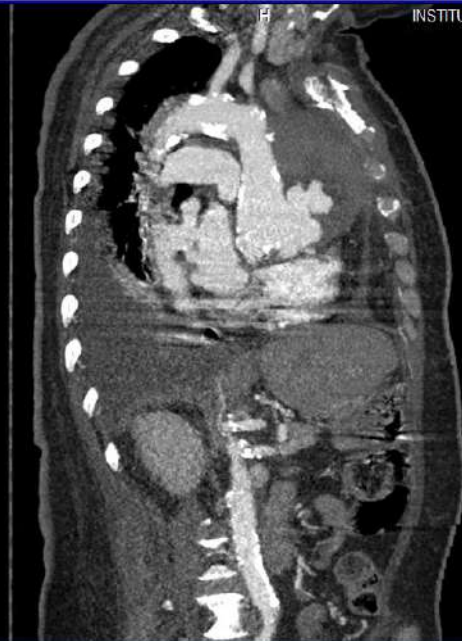ENDOVENTALL

Dr. Oscar Bernal
Centro Cardiovascular La Costa
Instituto Nacional de Cardiología



MENDIETA, SEBASTIANA
ID: 345160
* 25/02/1954
Study 1
05/09/2014
05:33:45 p.m.
21 IMA

INSTITUTO RADIOLOGICO CALVO
Emotion 16 (2007)



Spin: 119
Tilt: 0

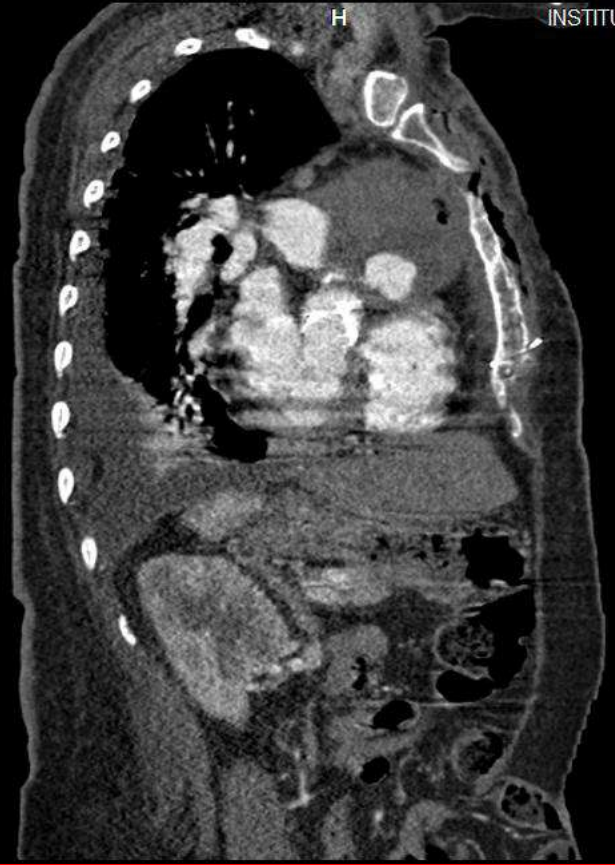

SL 5
C APPLIED

W: 598
C: 173

MENDIETA, SEBASTIANA
ID: 345160
* 25/02/1954
Study 1
05/09/2014
05:33:45 p.m.
9 IMA

INSTITUTO RADIOLOGICO CALVO
Emotion 16 (2007)



Spin: 116
Tilt: 0



PL

SL 3
C APPLIED

W: 554
C: 131

MENDIETA, SEBASTIANA

ID: 345160

* 25/02/1954

Study 1

05/09/2014

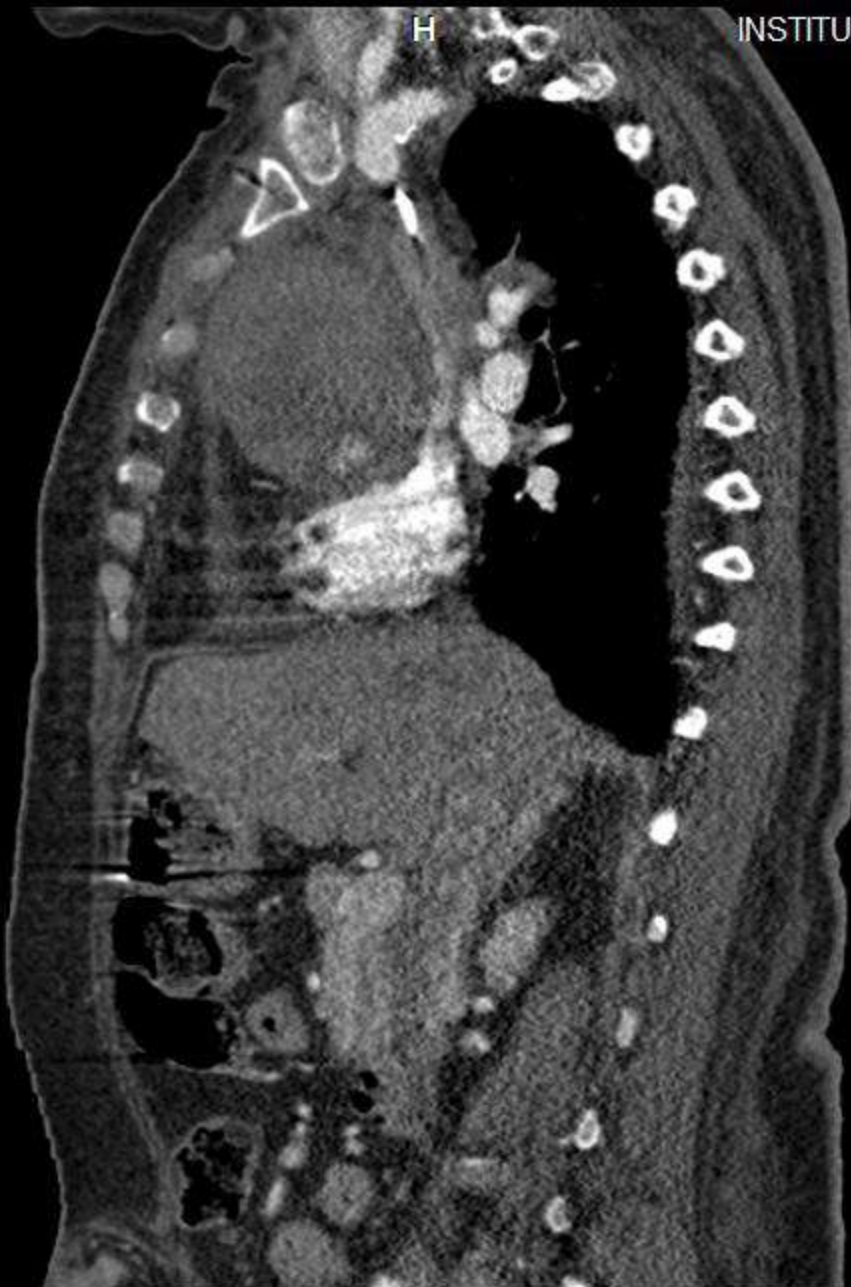05:33:45 p.m.

7 IMA

H

INSTITUTO RADIOLOGICO CALVO

Emotion 16 (2007)



Spin: -90

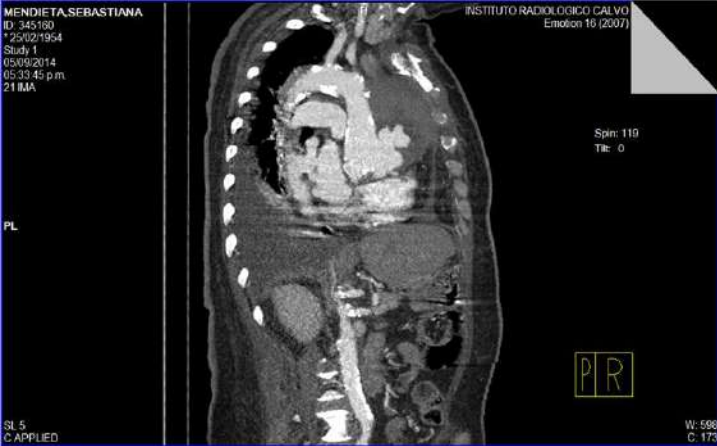
Tilt: 0

A

SL 3
C APPLIED



W: 554
C: 131



Vascular
plug

Amplatzer

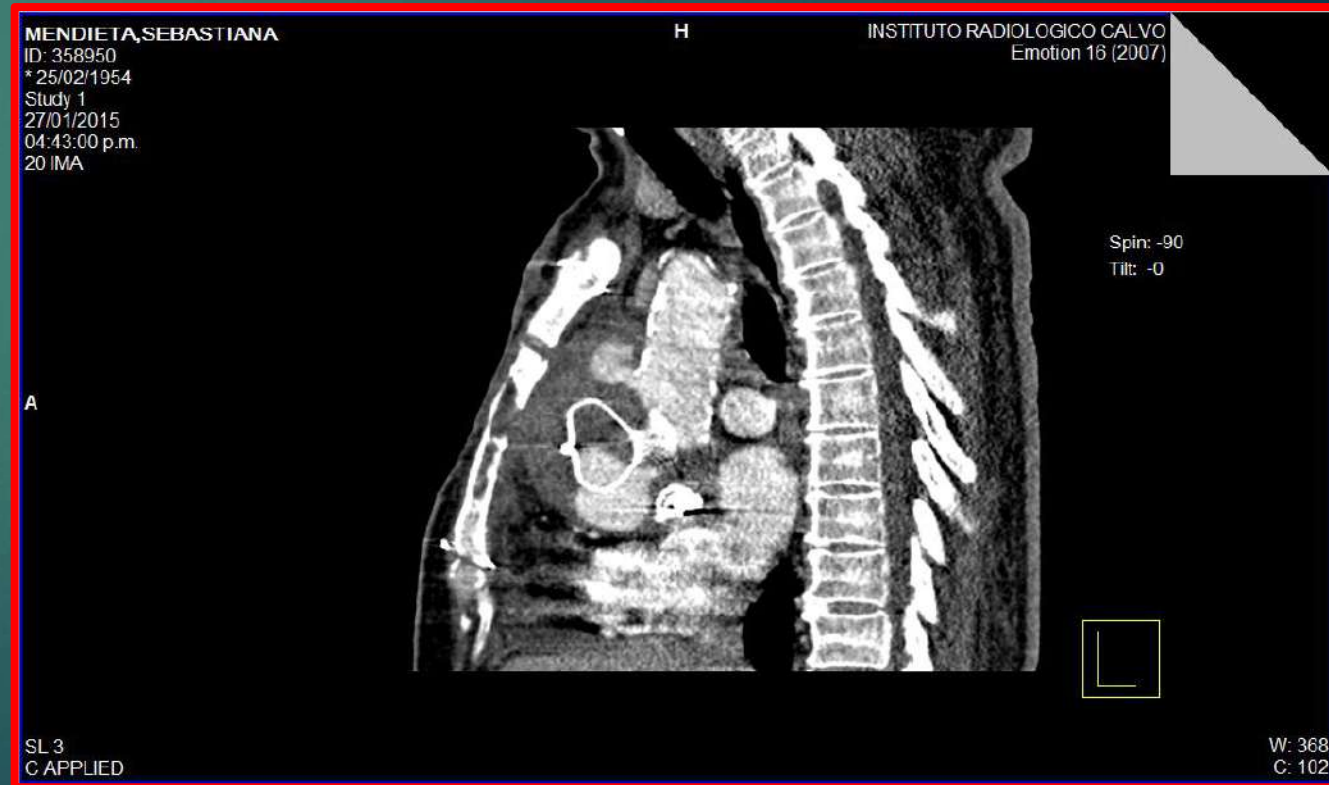
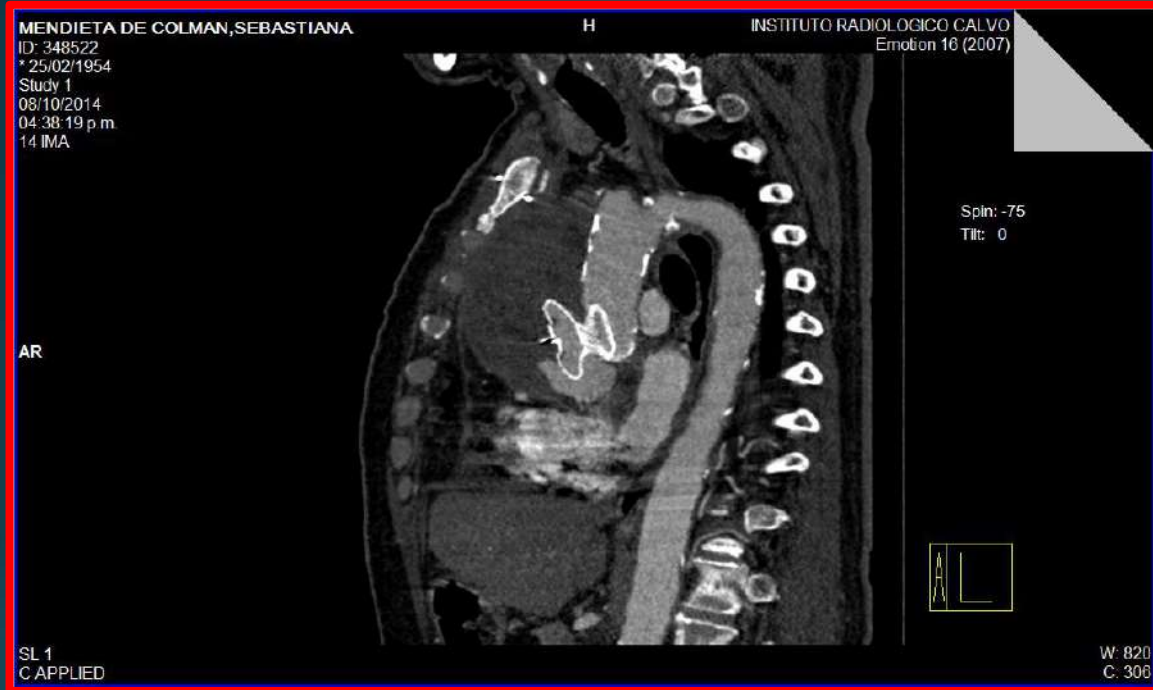
Coils

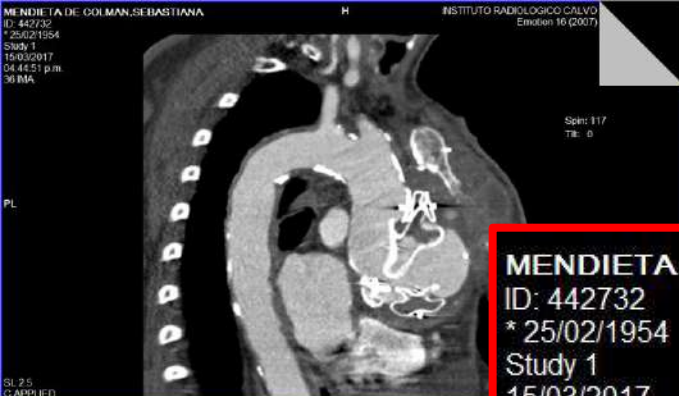Endoprotesis
Aorta
Ascendente

Tratamiento
Endovascular?



Consulta con un colega





MENDEIETA DE COLMAN, SEBASTIANA
ID: 442732
* 25/02/1954
Study 1
15/03/2017
04:44:51 p.m.
30 IMA

INSTITUTO RADIOLOGICO CALVO
Emotion 16 (2007)

Spin: 117
Tilt: 0

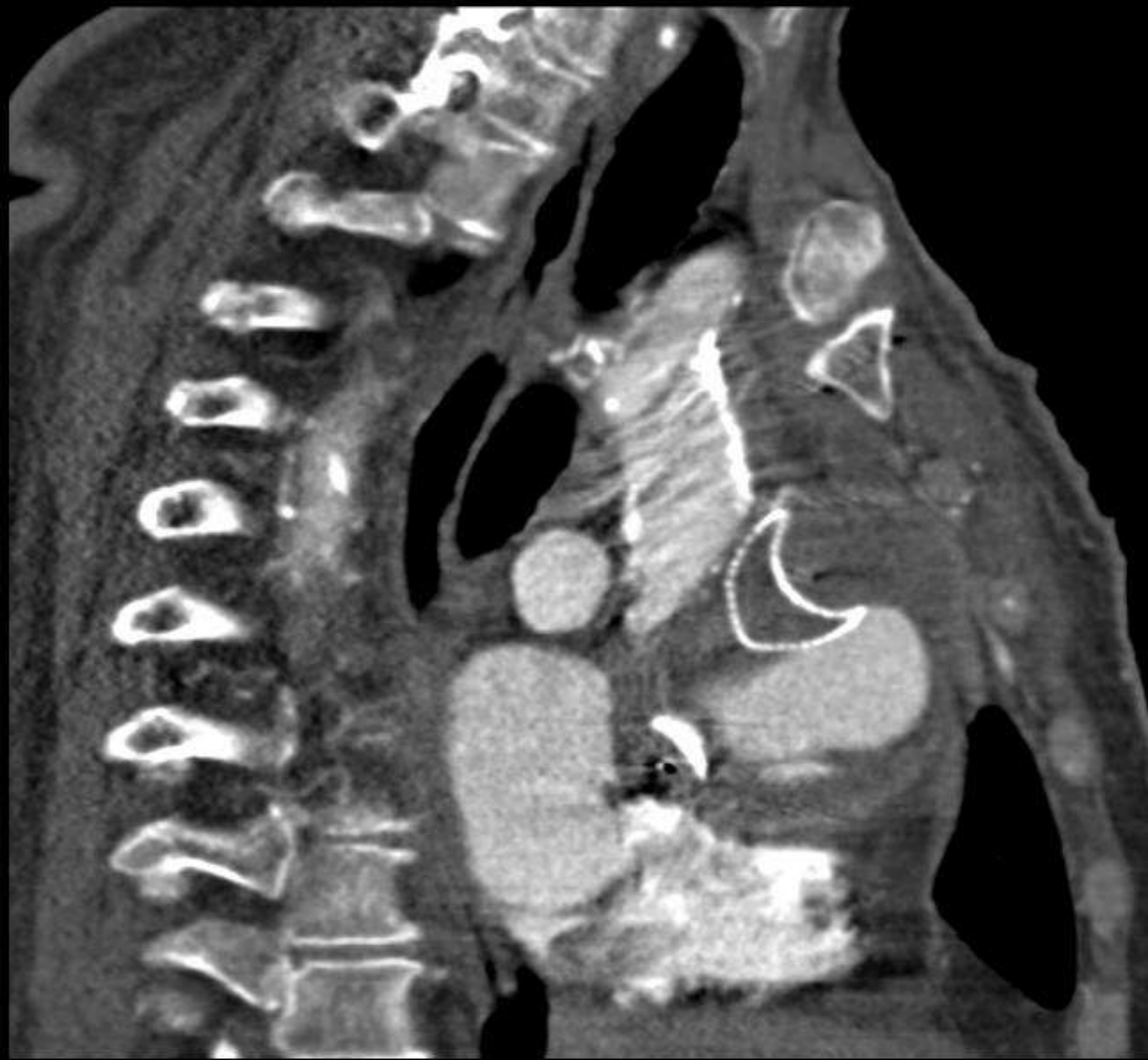PL

SL 2.5
C APPLIED

MENDEIETA DE COLMAN, SEBASTIANA
ID: 442732
* 25/02/1954
Study 1
15/03/2017
04:44:51 p.m.
31 IMA

H

INSTITUTO RADIOLOGICO CALVO
Emotion 16 (2007)



Spin: 117
Tilt: 0

PL

PR

SL 2.5
C APPLIED

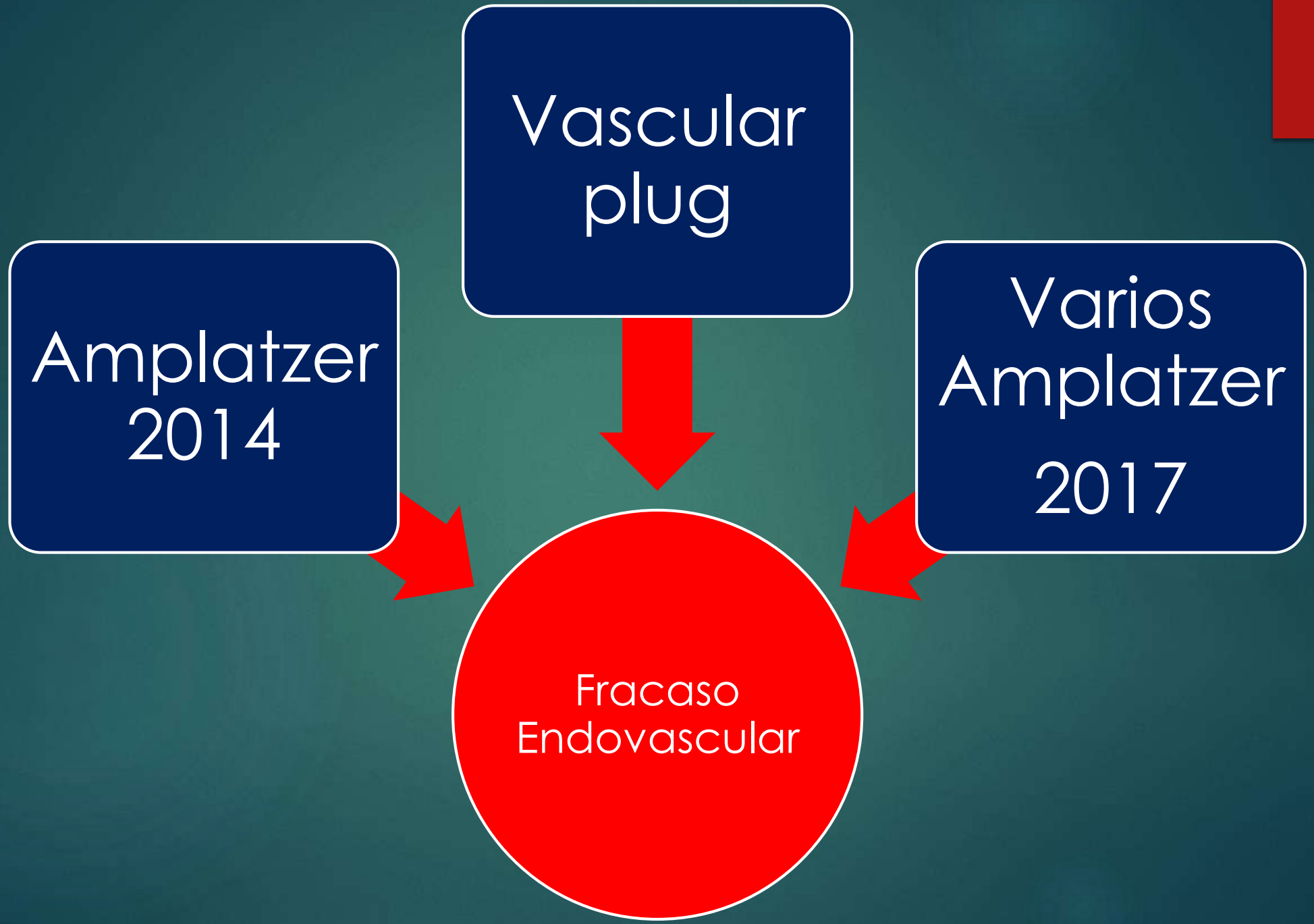

W: 748
C: 179

Amplatz
2014

Vascular
plug

Varios
Amplatz
2017

Fracaso
Endovascular



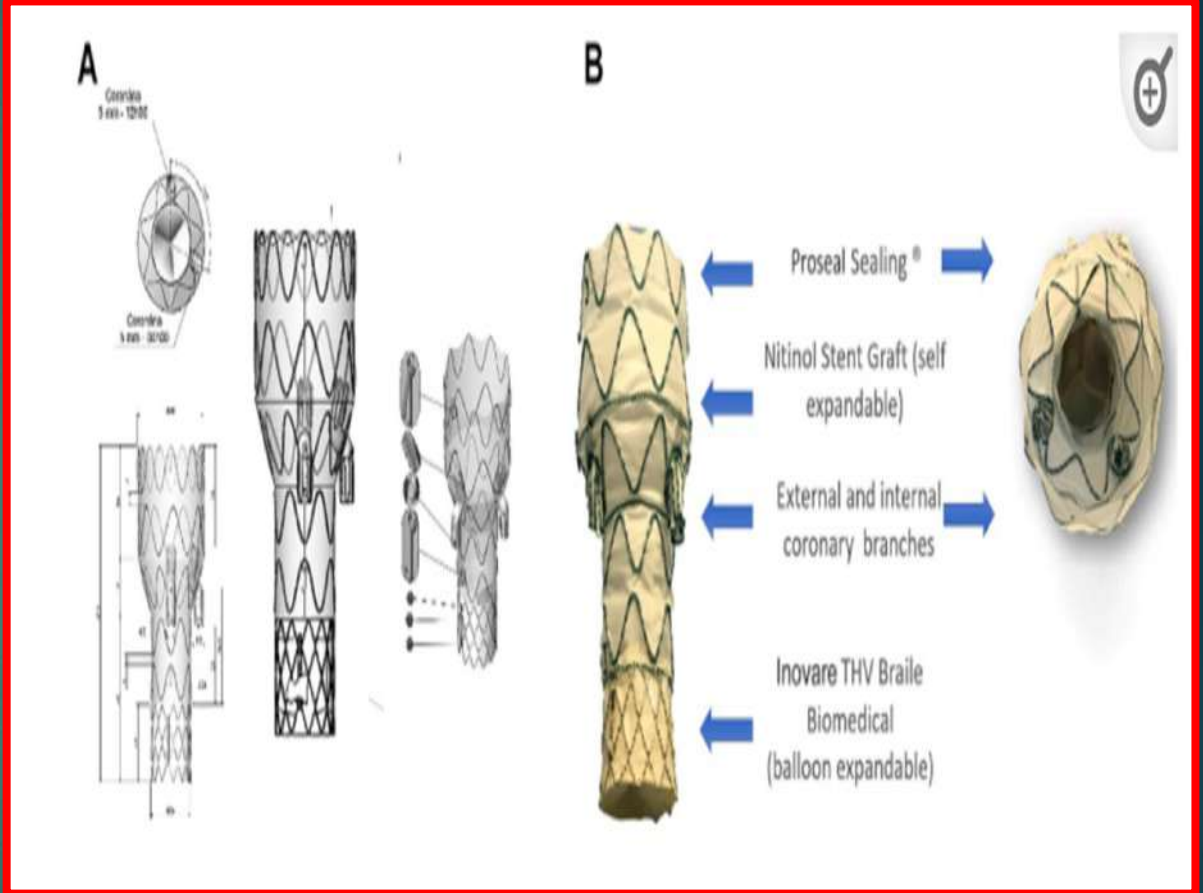
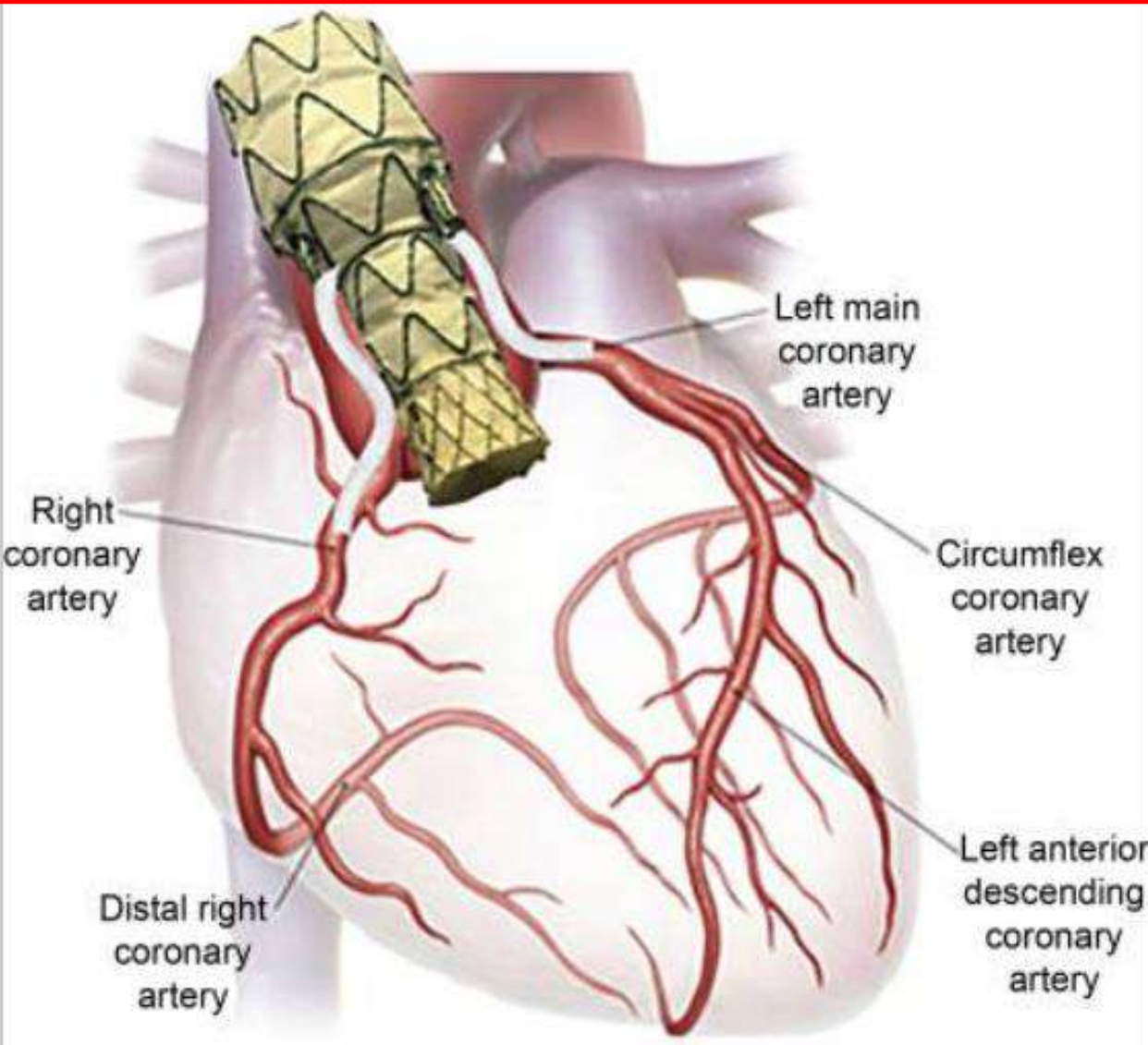
Braile
Dr. Diego Gaia
Dr. Honorio Palma

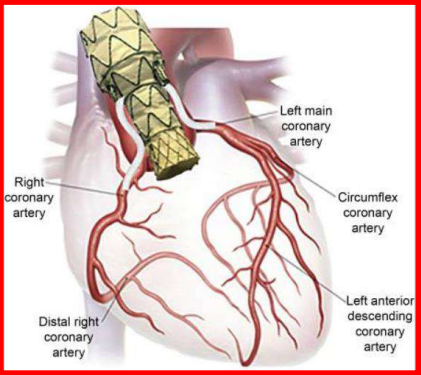
Antecedente
Razones
Humanitarias
Comité Etica CLC
Ministerio Salud

Diseño
2 años

ENDO BENTALL





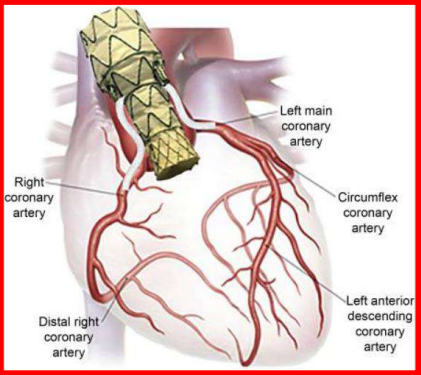


Transfemoral
Suprasternal
Trans-apical

Tavi Aortico
Endoprotesis
Aorta
Conexión para
las coronarias

Que stent utilizar
para la
conexión de la
endoprotesis

ENDOBENTALL

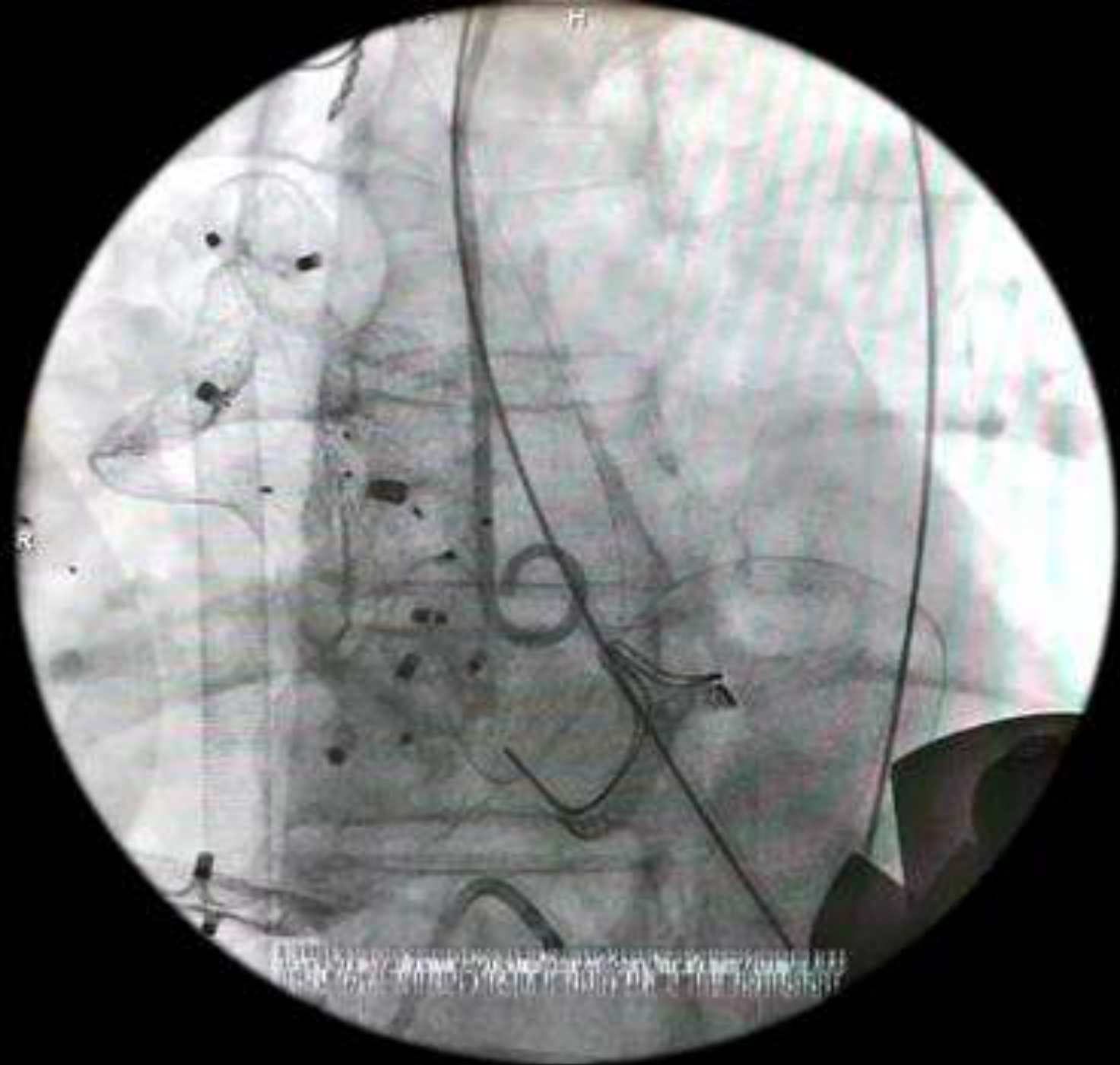


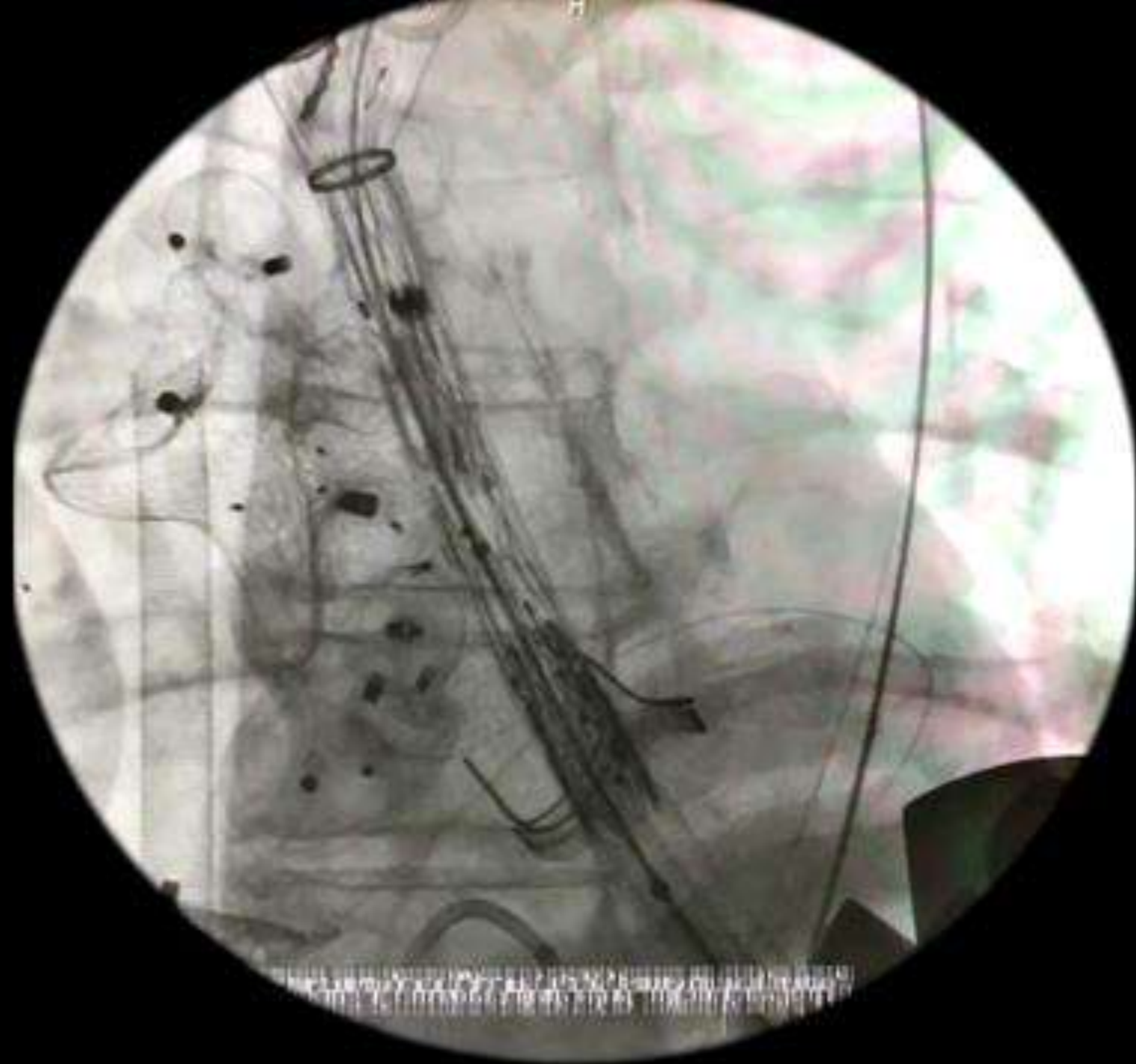
Endoprotesis Aorta
autoexpandible
Tavi balón
expandible

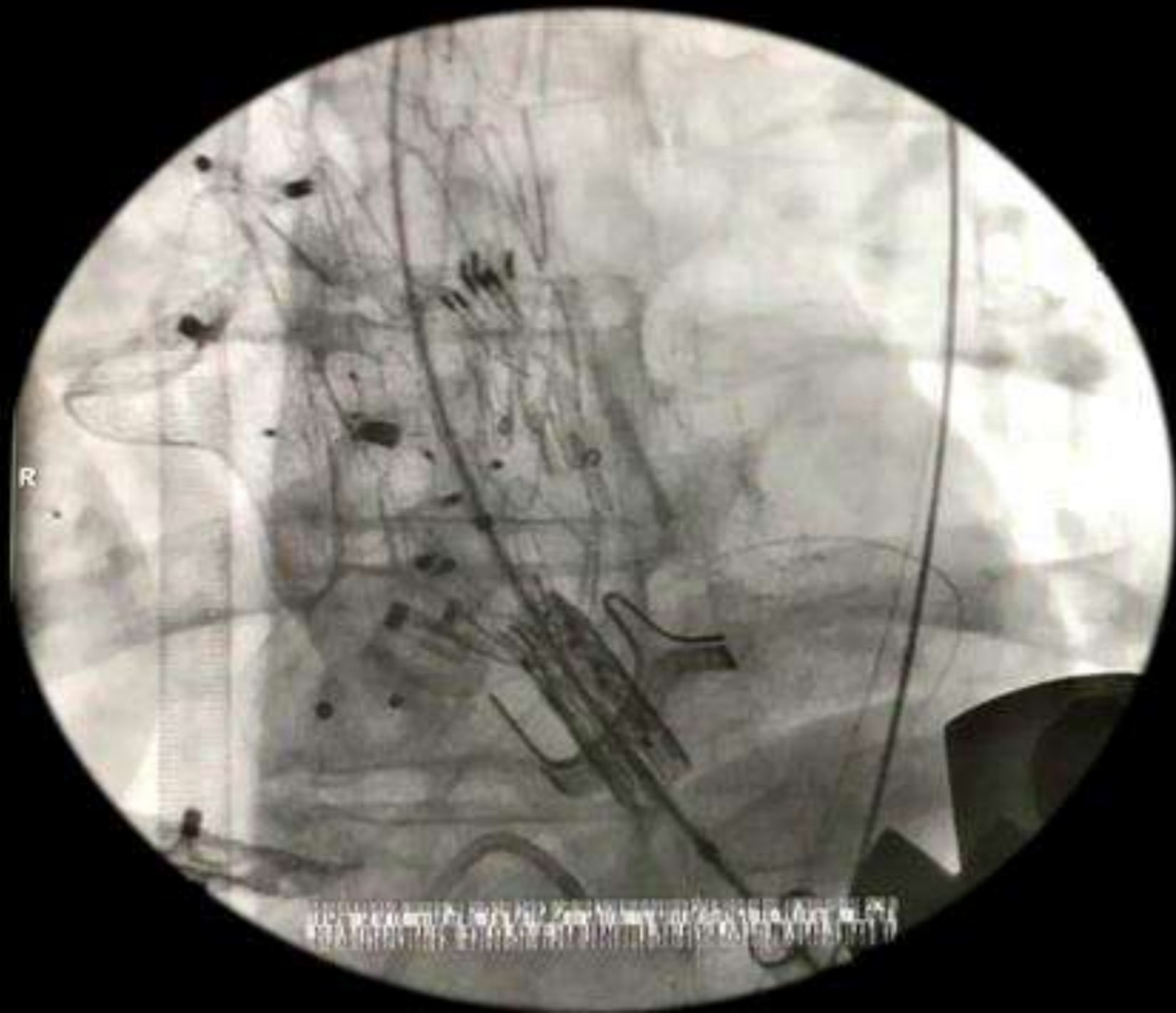
Guia 0.014 TCI
Guia 0.014 CD
Dos vías femorales
Una radial
Trans-apical

Circulación
extracorpórea
periférica
Stents Grafts
Coronarios
autoexpandibles

ENDOBENTALL

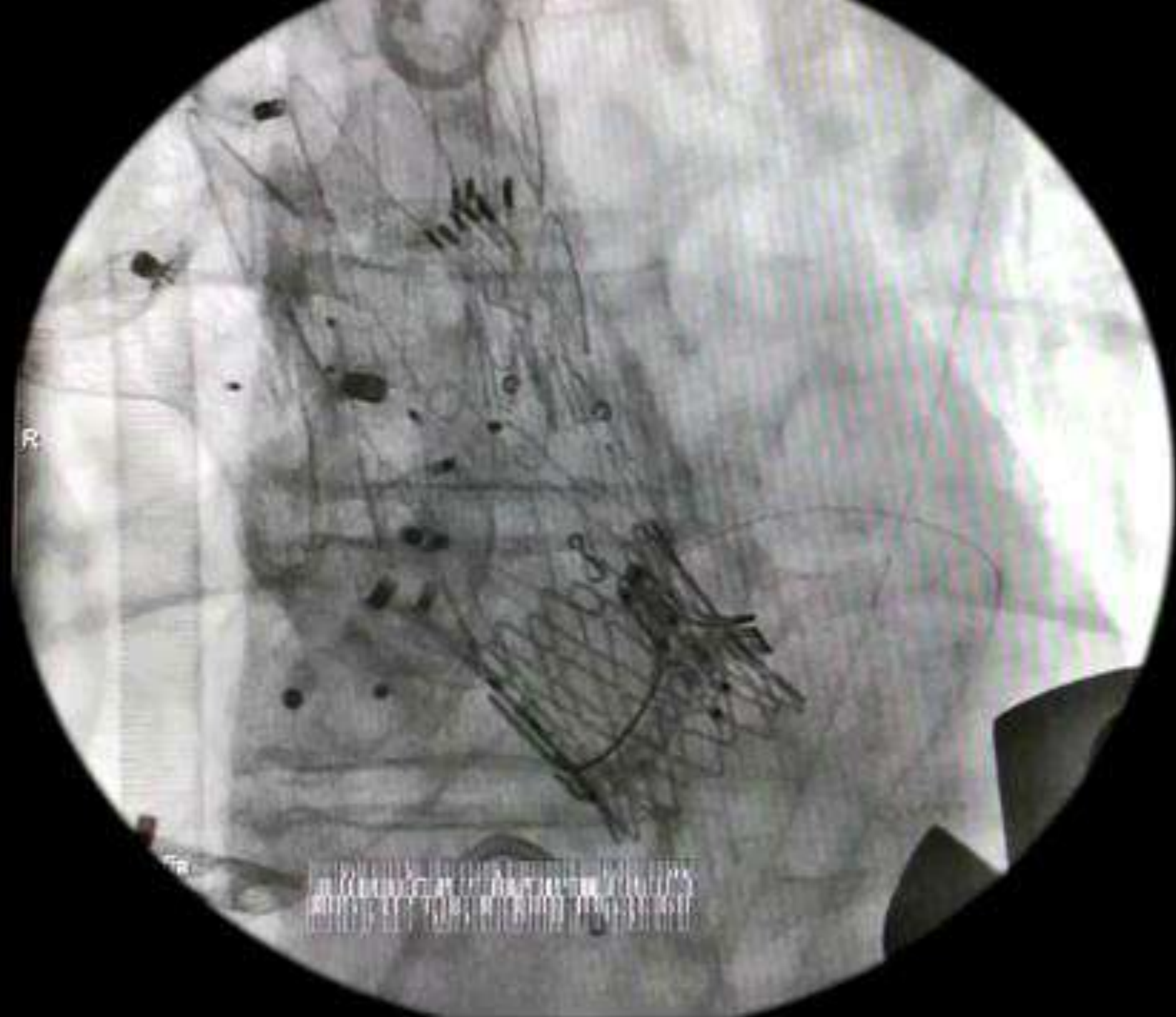


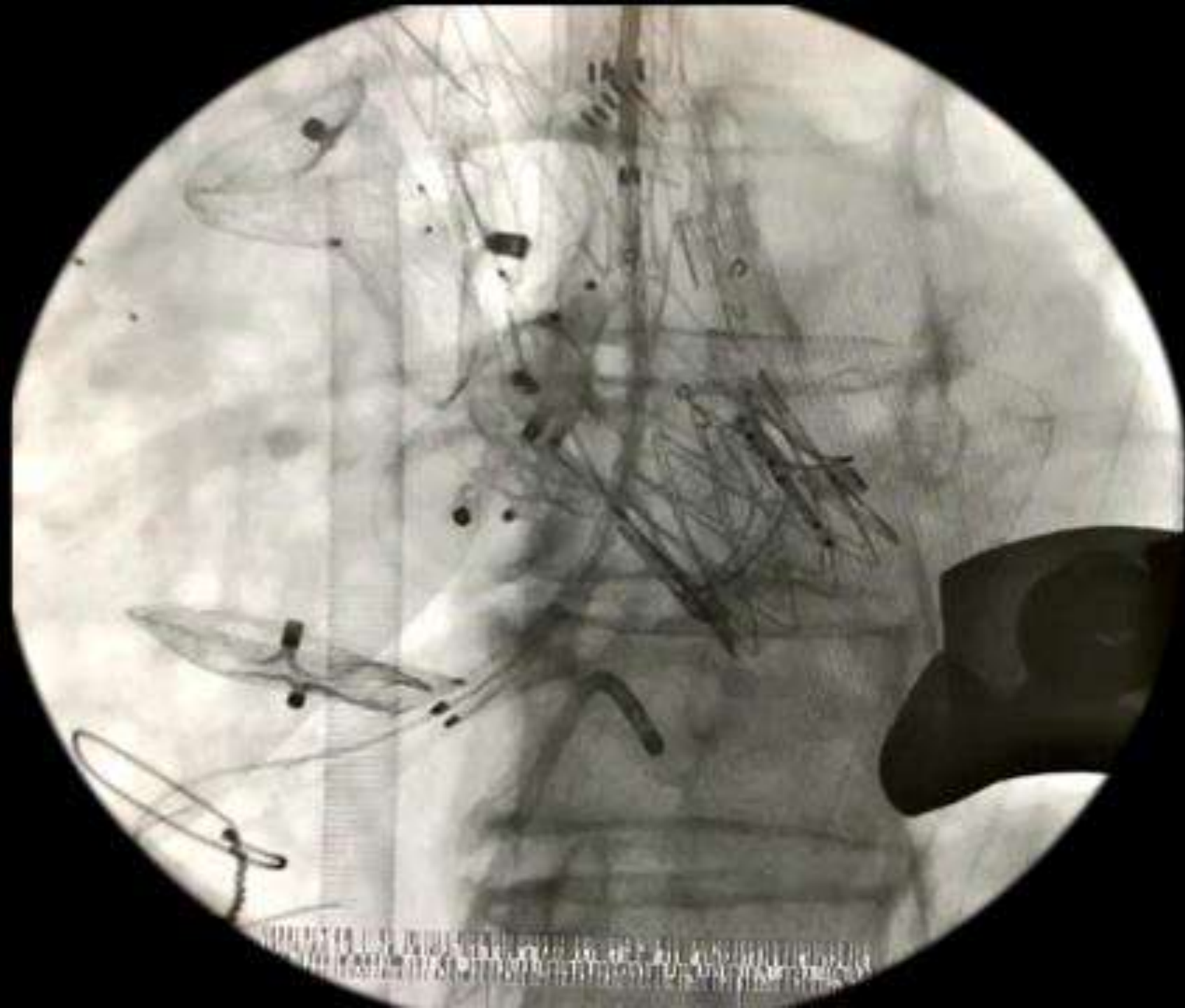

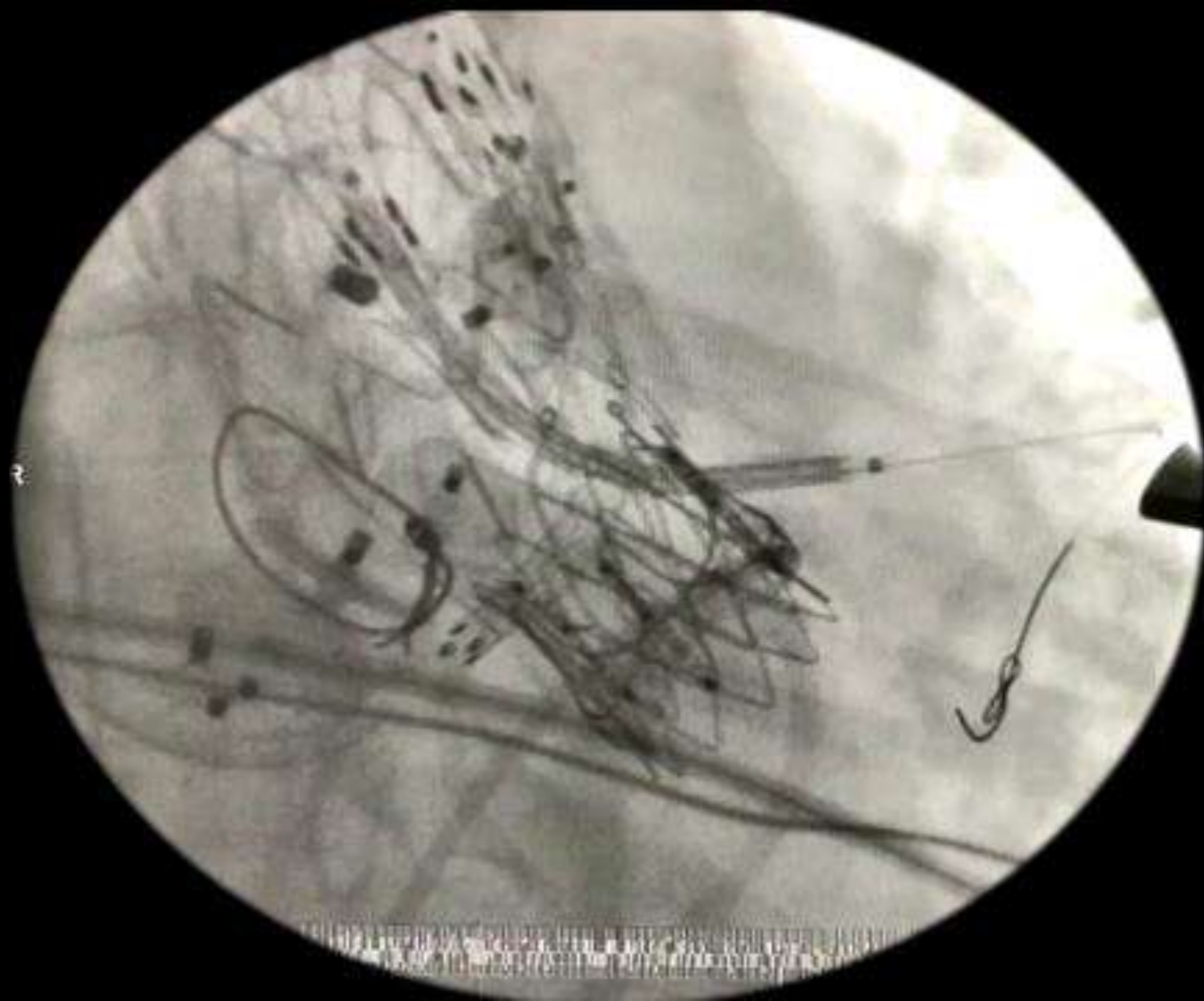


R

100 μm







MENDIETA DE COLMAN, SEBASTIANA

ID: 259432 - 64 AÑOS

* 25/02/1954

Study 1

04/12/2018

05:08:48 p.m.

1 IMA 57 FRM 1

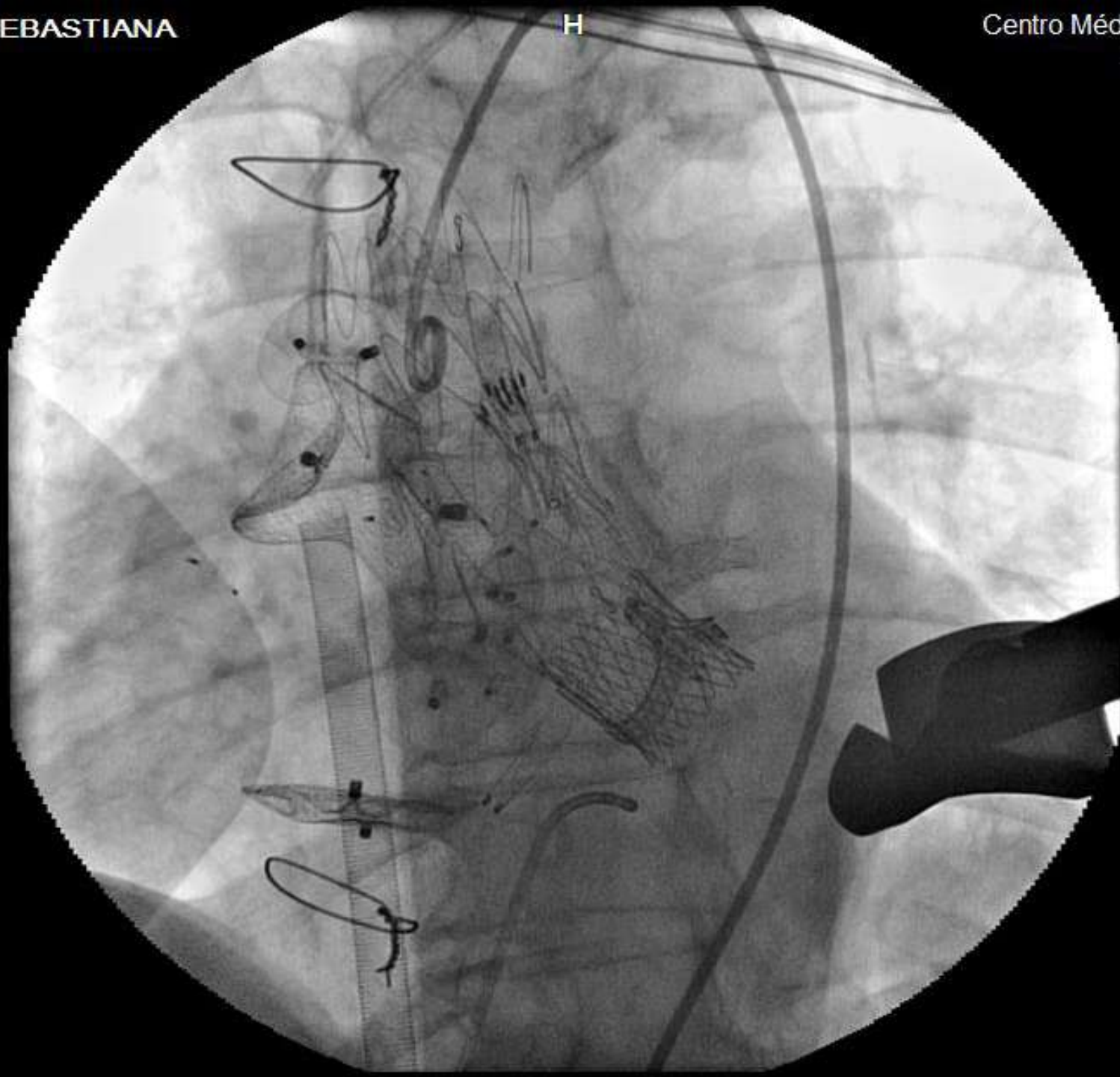
H

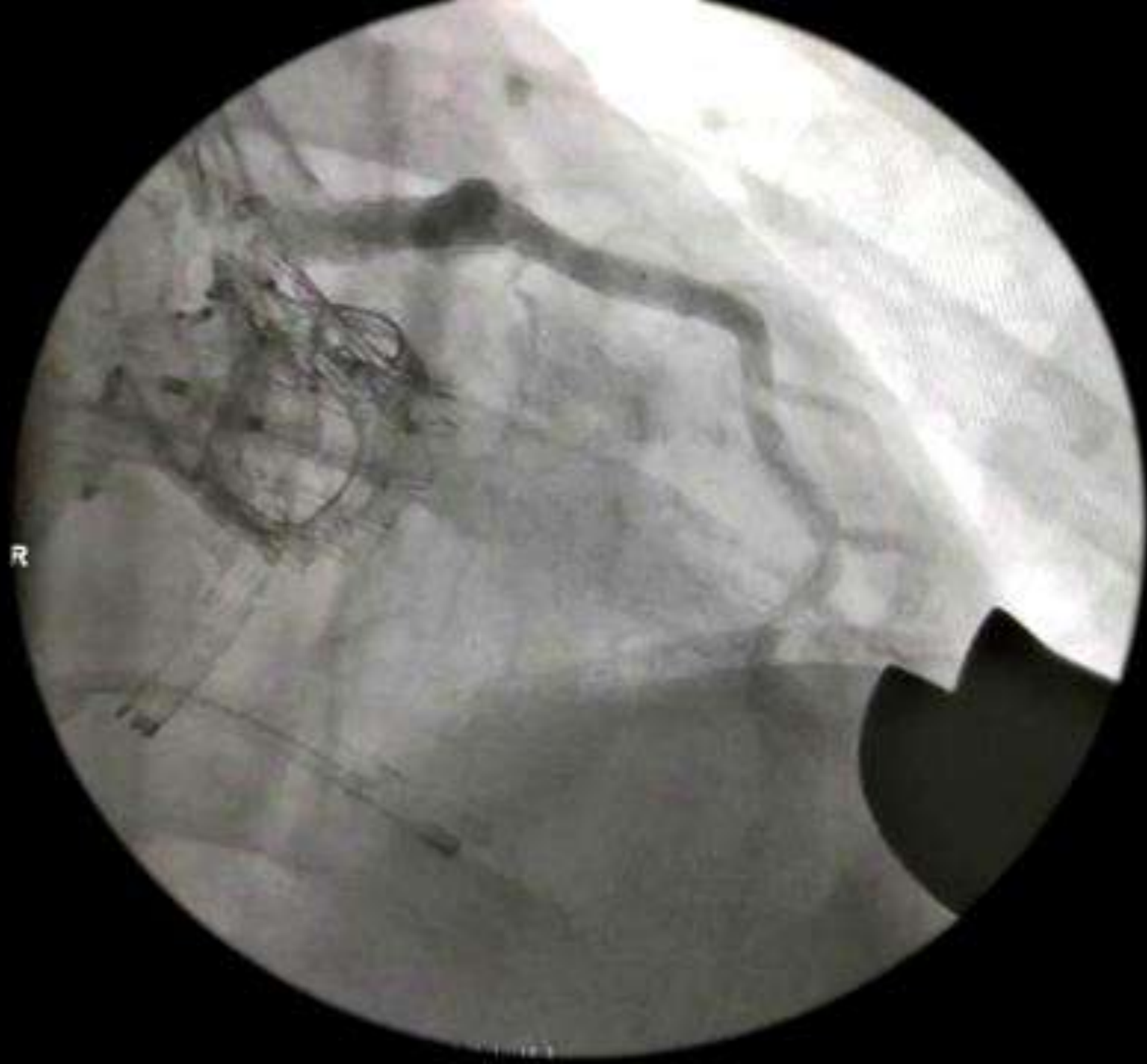Centro Médico La Costa
AXIOM-Artis
HFS

R

Coronariografía
Coronariografía
SINGLE PLANE\SINGLE A
CRA 0
LAO 20

W: 6387
C: 3200





MENDIETA DE COLMAN, SEBASTIANA

ID: 428232

* 25/02/1954

Study 1

10/09/2021

08:41:19 a.m.

1 IMA

A

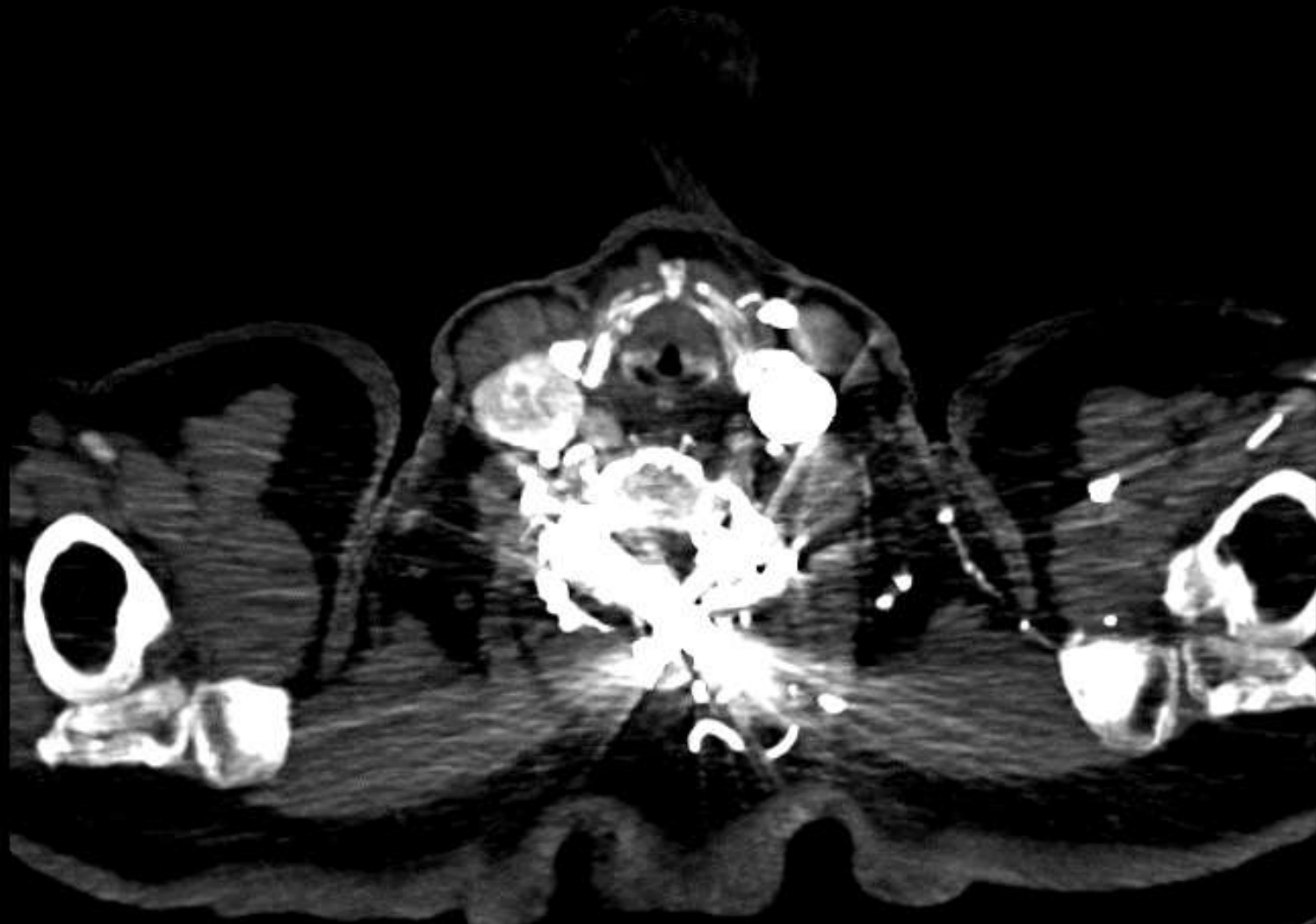INSTITUTO RADIOLOGICO CALVO

Emotion 16 (2007)

Spin: 0

Tilt: -90

R



SL 5
C APPLIED

W: 484
C: 201

MENDIETA DE COLMAN, SEBASTIANA

ID: CMLC4959154

* 25/02/1954

Study 1

29/06/2022

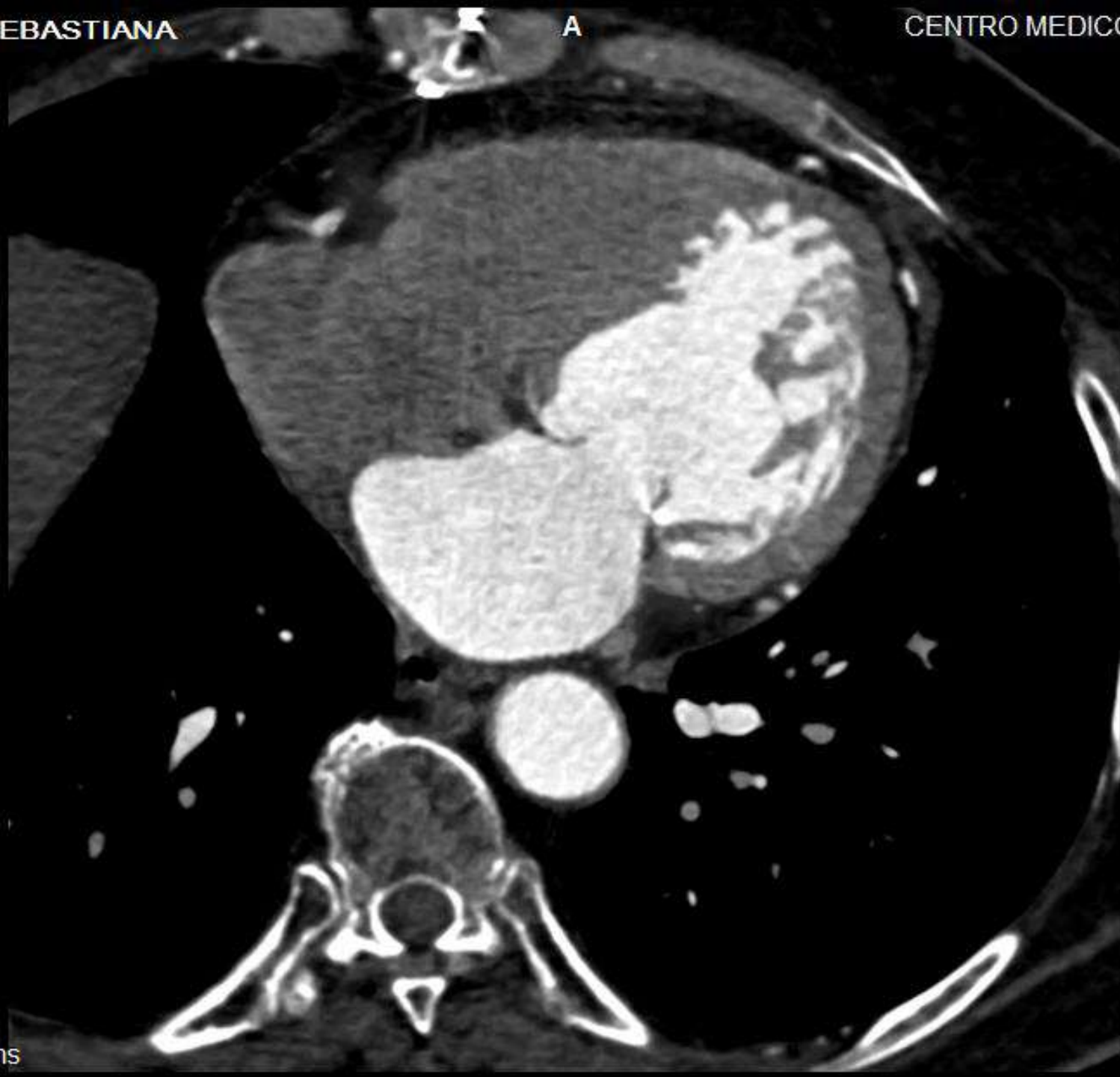
10:05:37 a.m.

114 IMA

A

CENTRO MEDICO LA COSTA
Perspective

R

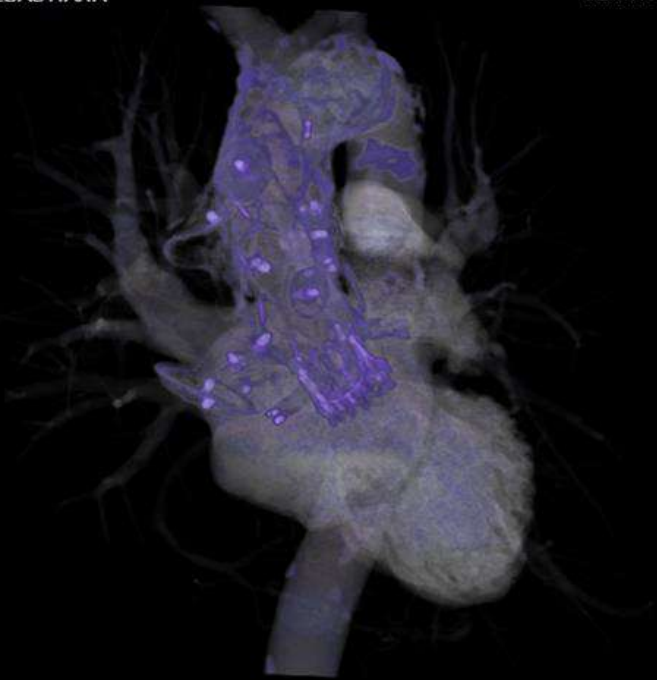


SL 0.75
C APPLIED
SP -941.3
Comment: 44 bpm, 78 %, 195 ms

W: 600
C: 200

MENDEIETA DE COLMAN, SEBASTIANA
ID: CMLC4959154
* 25/02/1954
Study 1
29/06/2022
10:05:30 a.m.
1 IMA

CENTRO MEDICO LA COSTA
Perspective

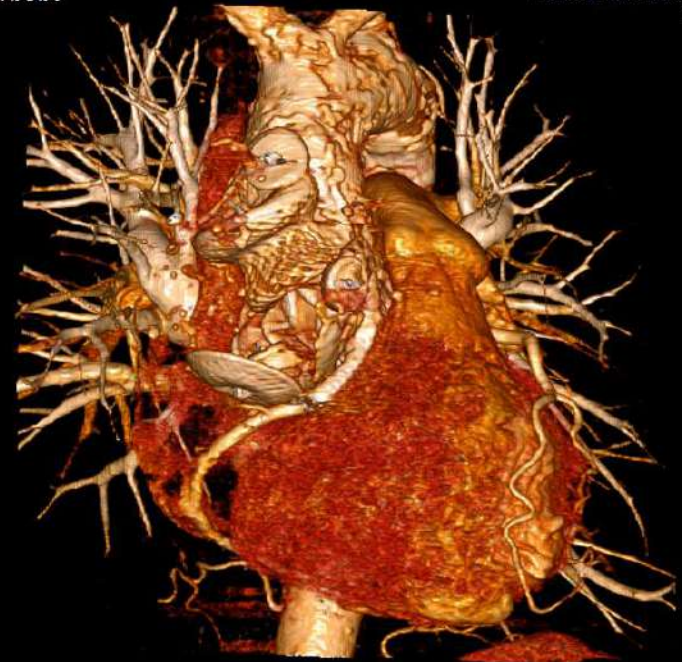


Spin: -6
Tilt: -1



MENDEIETA DE COLMAN, SEBASTIANA
ID: CMLC4959154
* 25/02/1954
Study 1
29/06/2022
10:05:30 a.m.
1 IMA

CENTRO MEDICO LA COSTA
Perspective

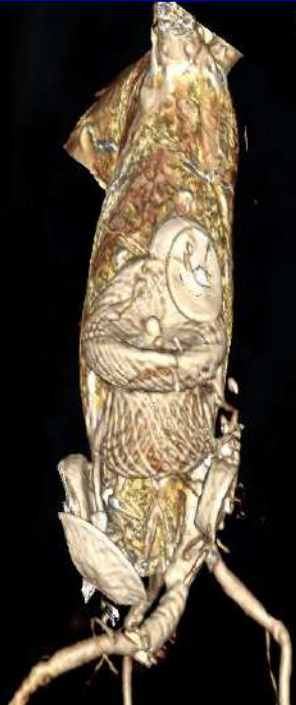

Spin: -1
Tilt: -1



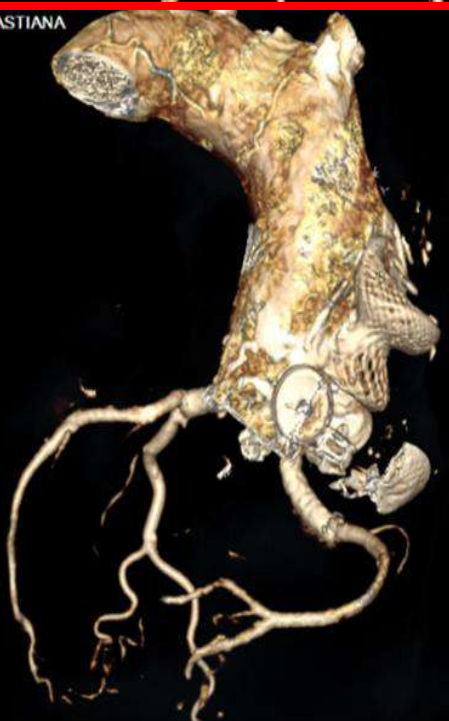MENDIETA DE COLMAN, SEBASTIANA
ID: CMLC4959154
* 25/02/1954
Study 1
29/06/2022
10:05:30 a.m.
0 IMA

CENTRO MEDICO LA COSTA
syngo.via.VA30A



MENDIETA DE COLMAN, SEBASTIANA
D: CMLC4959154
* 25/02/1954
Study 1
29/06/2022
10:05:30 a.m.
0 IMA

CENTRO MEDICO LA COSTA
syngo.via.VA30A

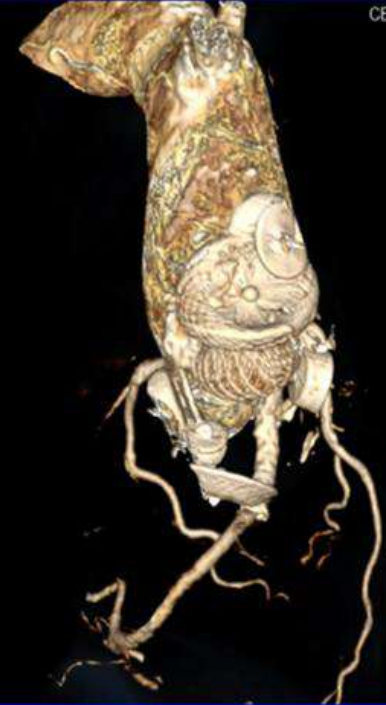

SL 0
Comment: 44 bpm, 78 %, 195 ms



MENDIETA DE COLMAN, SEBASTIANA
ID: CMLC4959154
* 25/02/1954
Study 1
29/06/2022
10:05:30 a.m.
0 IMA

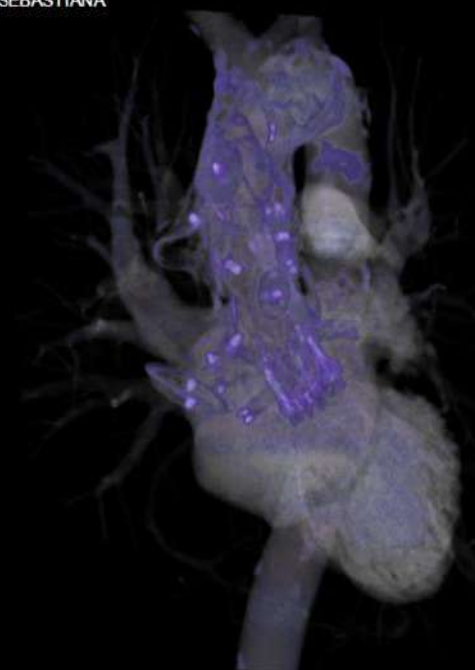
CENTRO MEDICO LA COSTA
syngo.via.VA30A



SL 0
Comment: 44 bpm, 78 %, 195 ms

MENDIETA DE COLMAN, SEBASTIANA
D: CMLC4959154
* 25/02/1954
Study 1
29/06/2022
10:05:30 a.m.
1 IMA

CENTRO MEDICO LA COSTA
Perspective



Spin: -6
Tilt: -1



First-in-Human Endo-Bentall Procedure for Simultaneous Treatment of the Ascending Aorta and Aortic Valve

[Diego Felipe Gaia](#), MD, PhD,^{a,*} [Oscar Bernal](#), MD,^b [Edilberto Castilho](#), MD,^a

[Carolina Baeta Neves Duarte Ferreira](#), MD,^a [Danny Dvir](#), MD,^c [Matheus Simonato](#), MD,^a and

[José Honório Palma](#), MD, PhD^a

