Un caso, una enseñanza

Un día, dos shocks cardiogénicos

Dra. Erika Ludeña Riveros
Cardiología Intervencionista
Hospital Nacional Guillermo Almenara

Caso clínico 1

- Paciente varón
- 61 años
- Niega factores de riesgo CV
- Tiempo de enfermedad: 9 hrs con historia de dolor torácico típico + síntomas neurovegetativos.
- Referido de clínica: Ingreso por emergencia
  - PA 103/69 mmHg FC 78 lpm
  - Sat 90 - 92 % MR 15 Lts

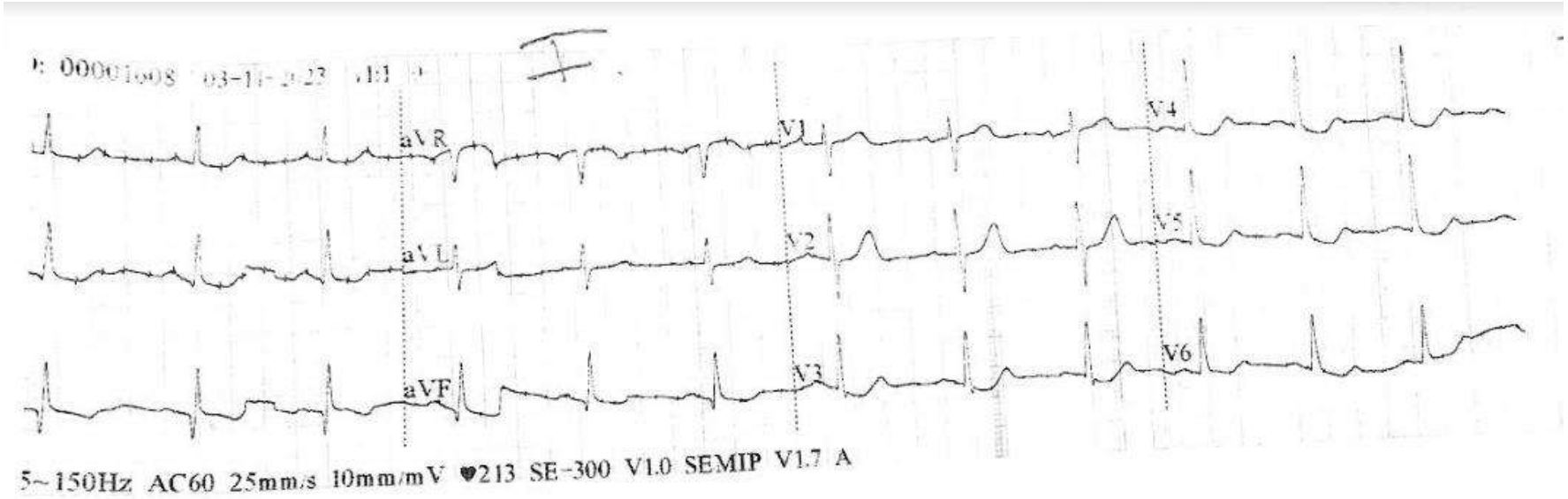
I
aVR
V1
V4
aVL
V2
V5
aVF
V3
V6
5~150Hz AC60 25mm/s 10mm/mV ♥213 SE-300 V1.0 SEMIP V1.7 A

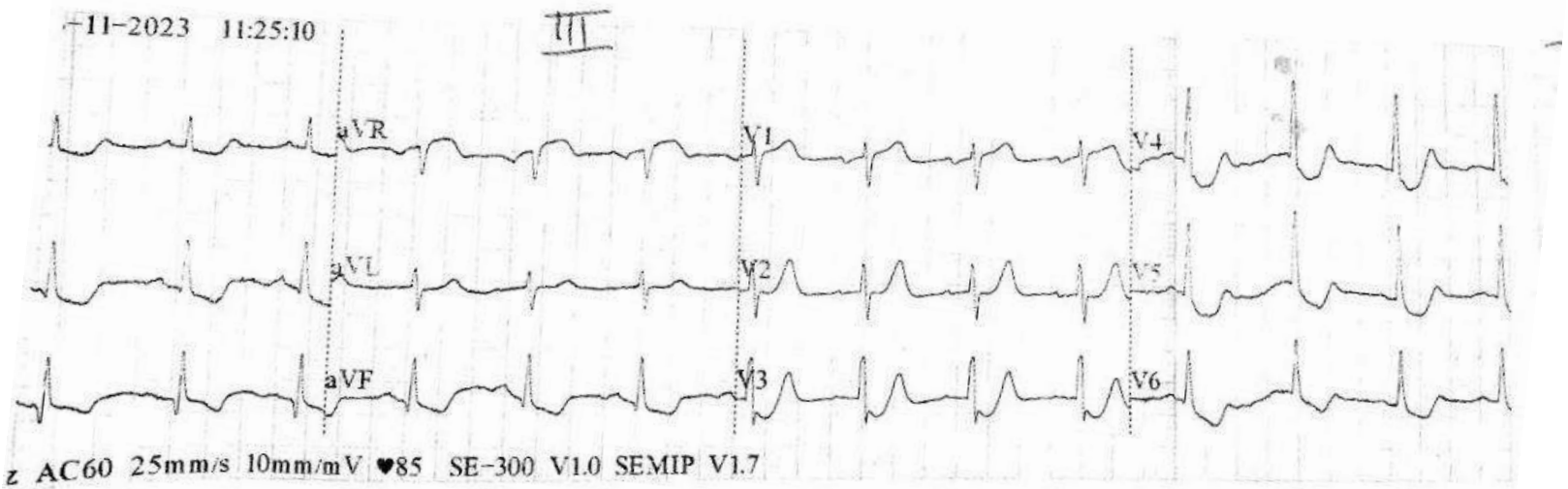
-11-2023 11:25:10
III
aVR
V1
V4
aVL
V2
V5
aVF
V3
V6
z AC60 25mm/s 10mm/mV ♥85 SE-300 V1.0 SEMIP V1.7

- Ingreso a UCICOR
  Dx: IMSTNE Alto riesgo
- 12 hrs del ingreso
- MR 15 Lts → VNI → VM
- NA 16 ucg/kg/min
- DBT 7 ucg/kg/min
- PAM 72 mmHg

→ Ingresa a sala de hemodinamica

Laboratorios:
Troponina 7447ng/mL
proBNP 1351 pg/mL
Hb 15.46 g
AGA
pH 7.33 pCO 35 pO2 67
PAFI 74.5

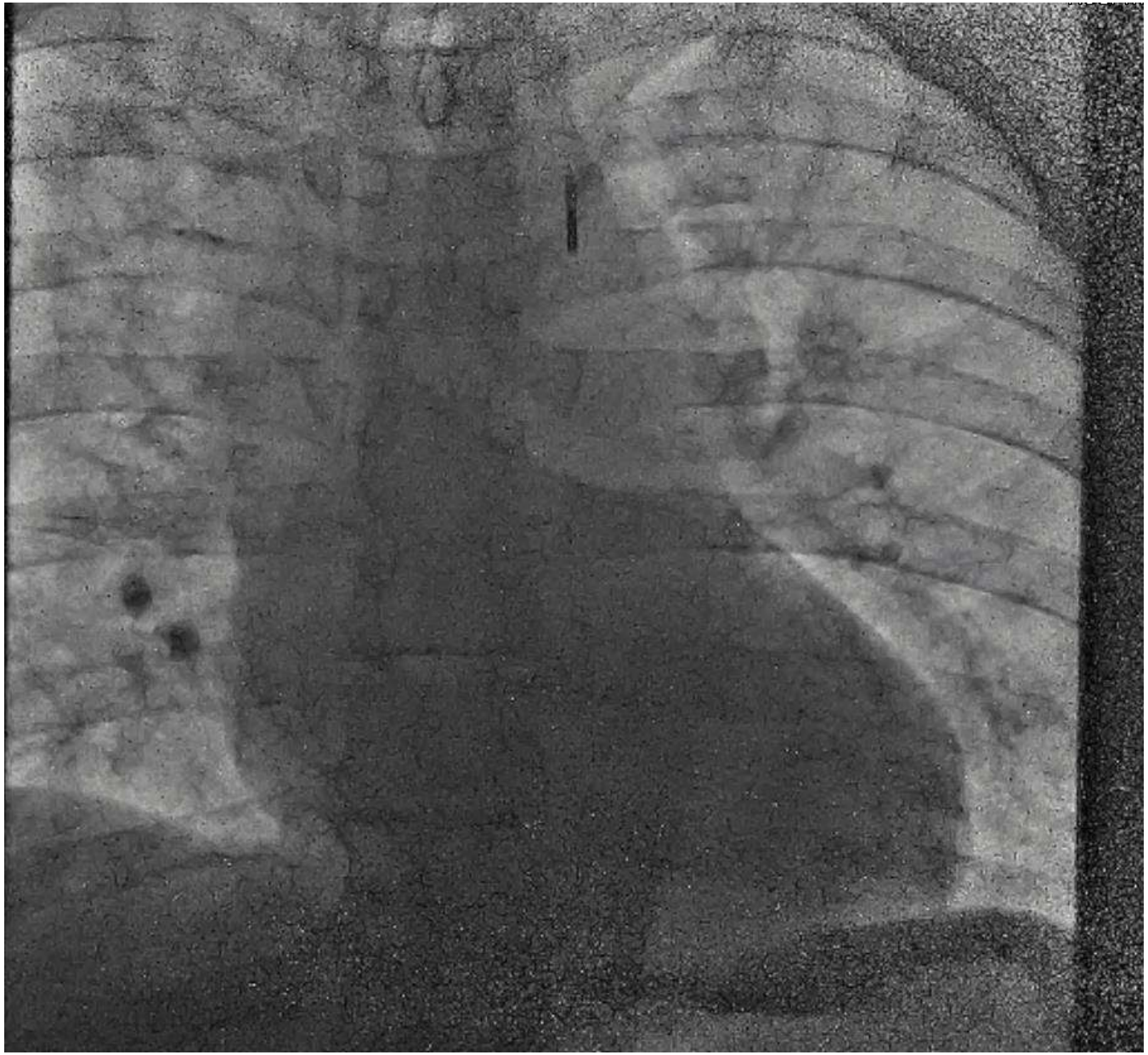

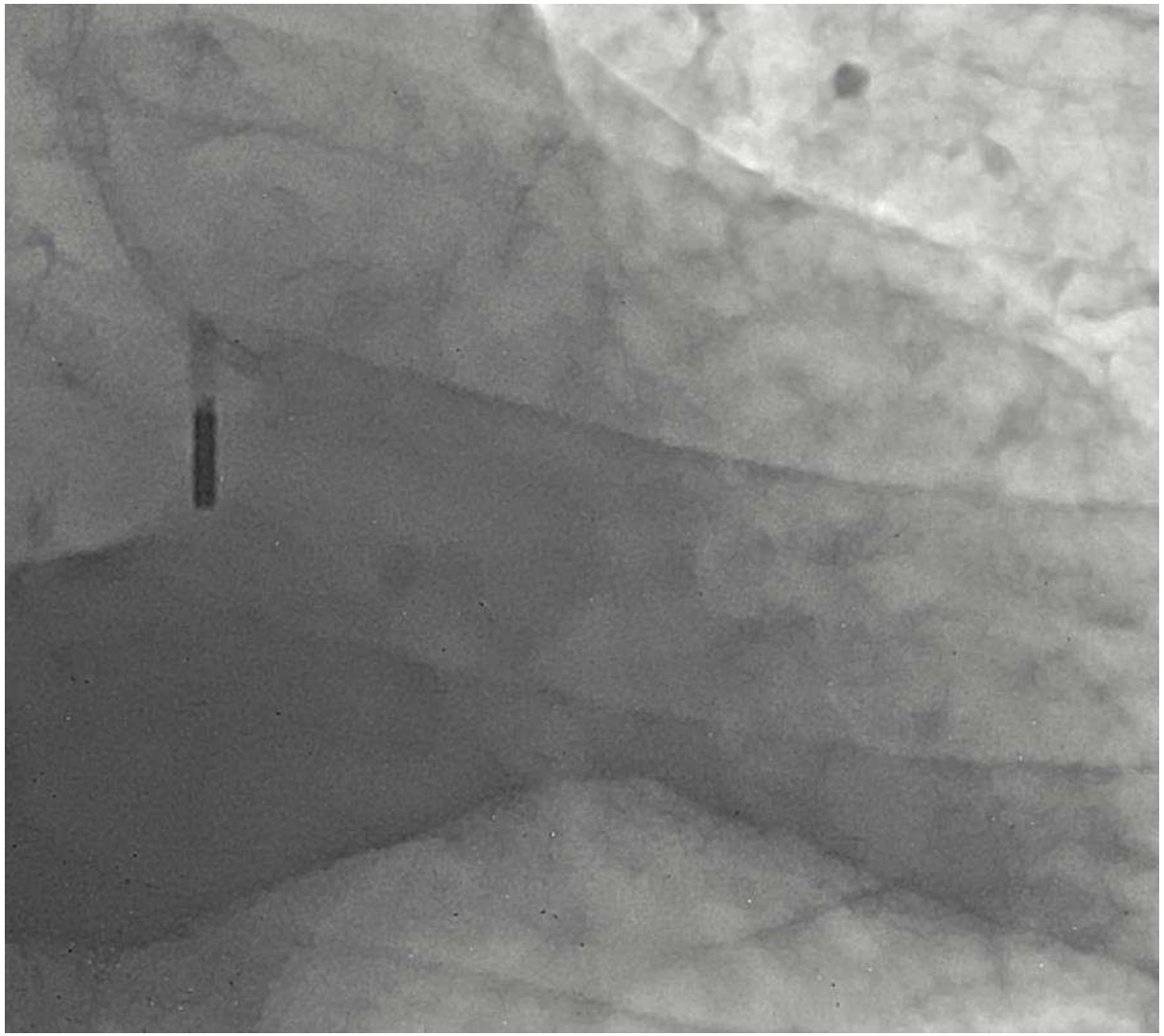

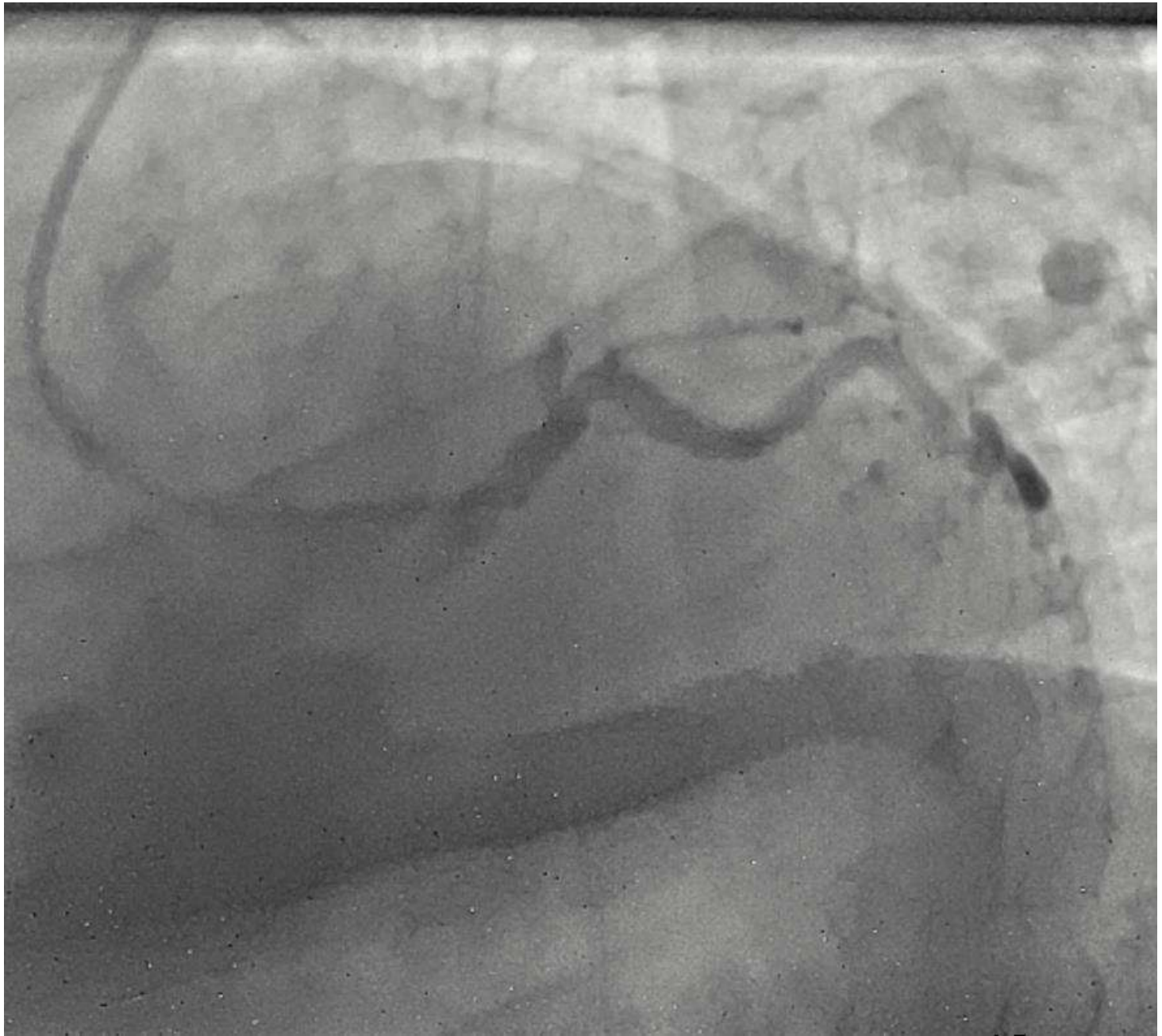

- Bifurcación: DA ostial
- Cx

- → Provitional stent hacia DA
- → Guia en Cx

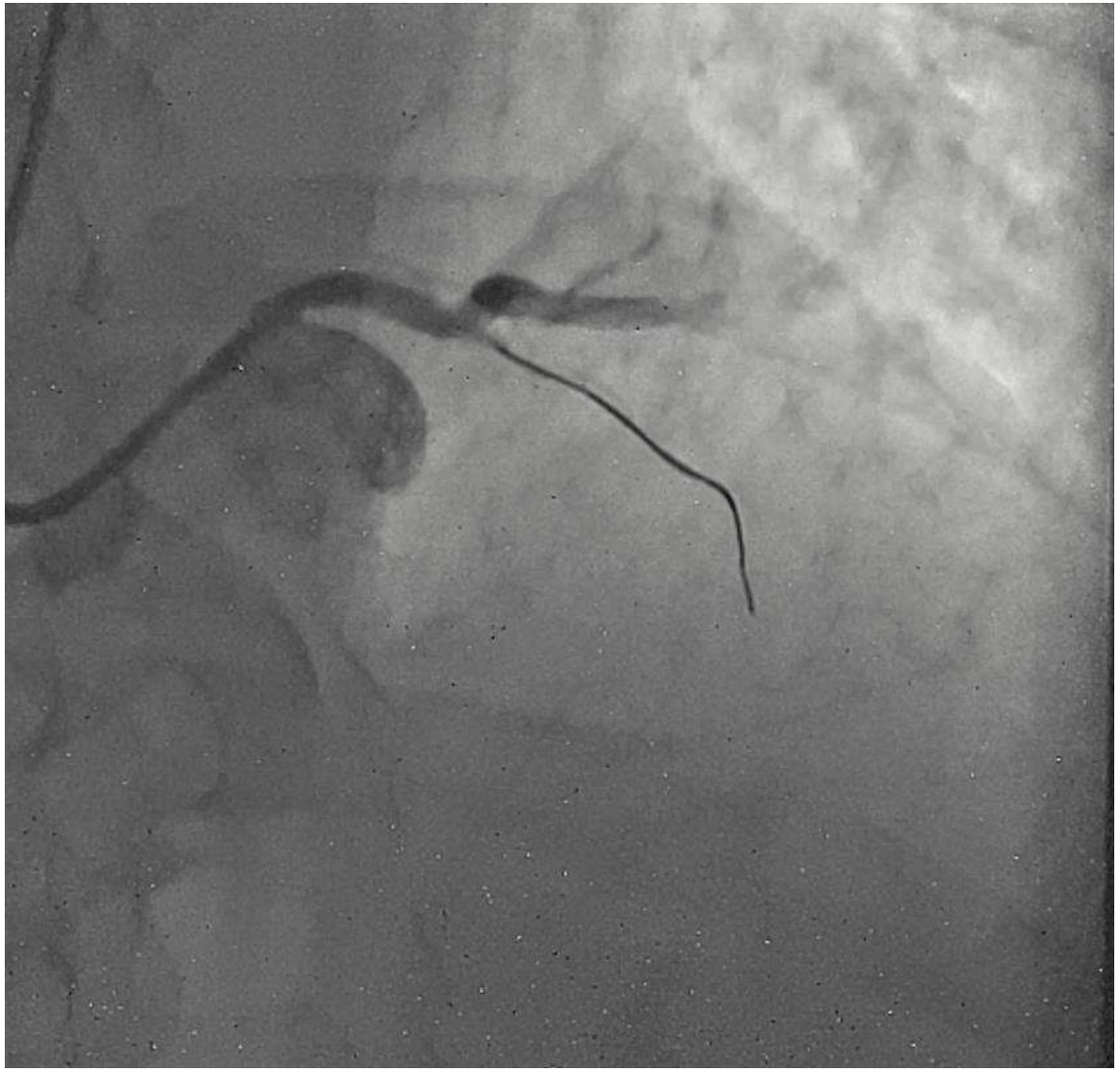

HOSPIT
At Detector

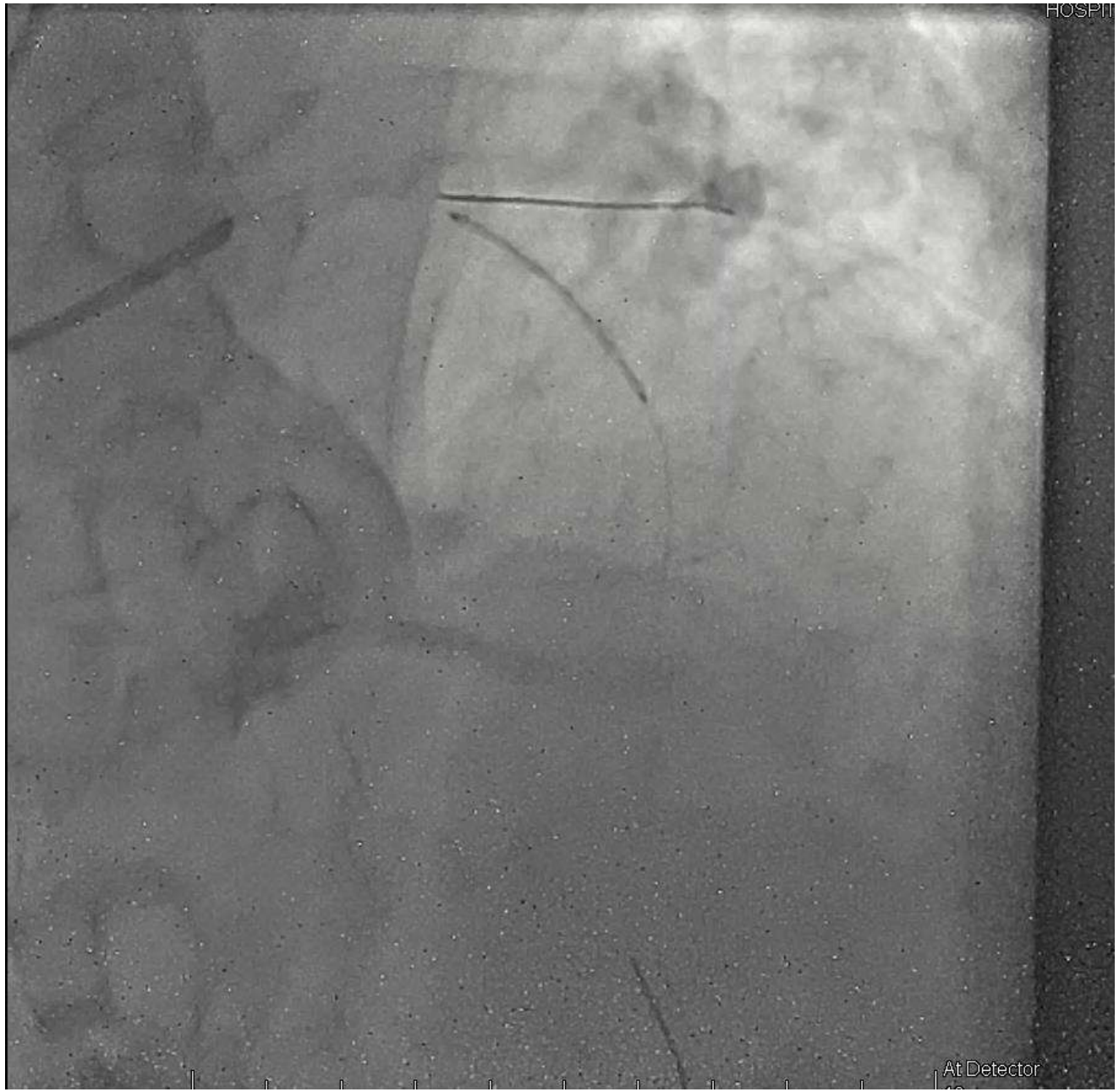
HOSPIT
At Detector

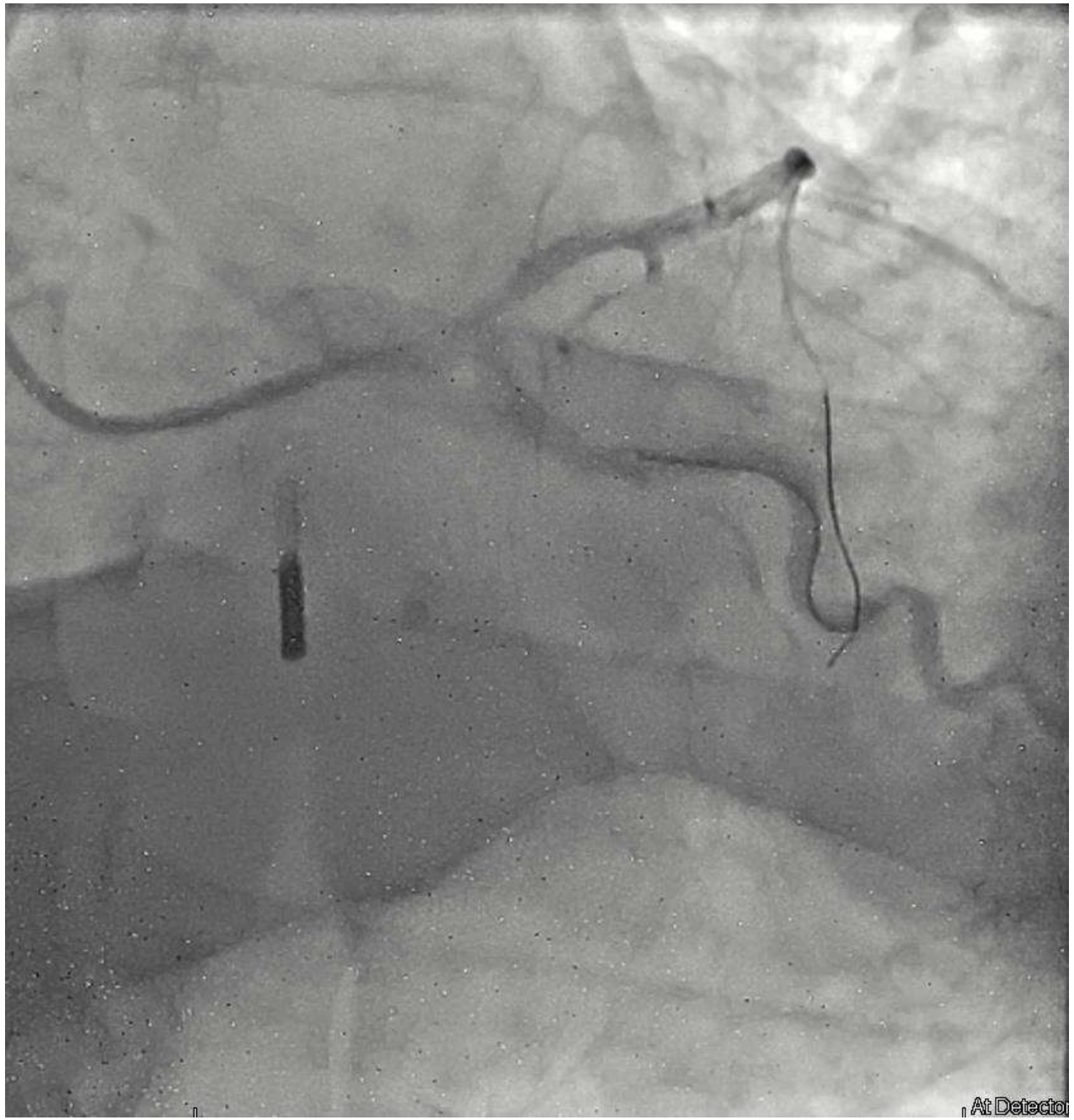
At Detector

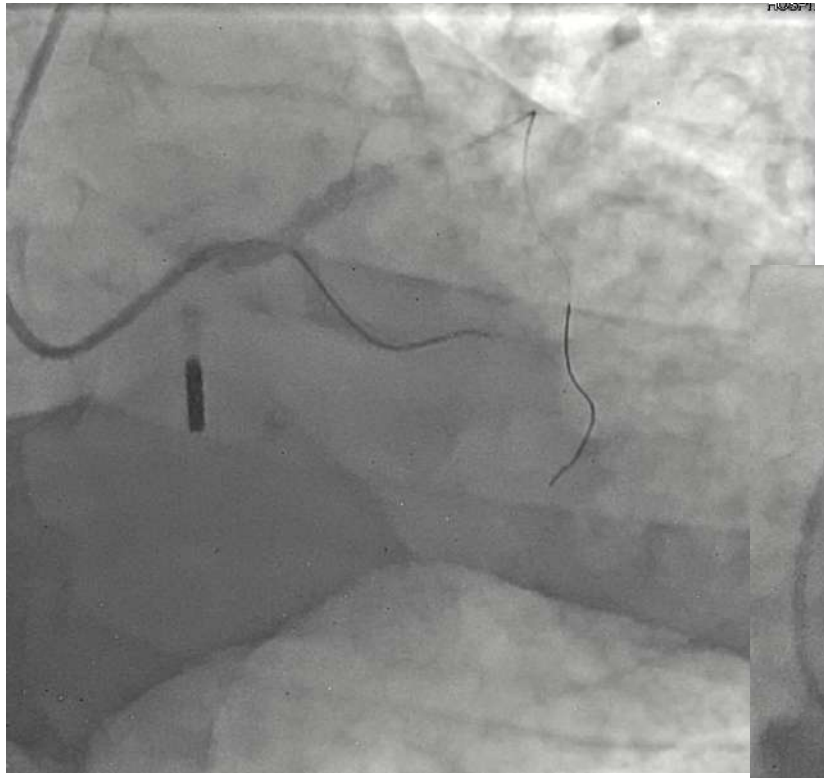

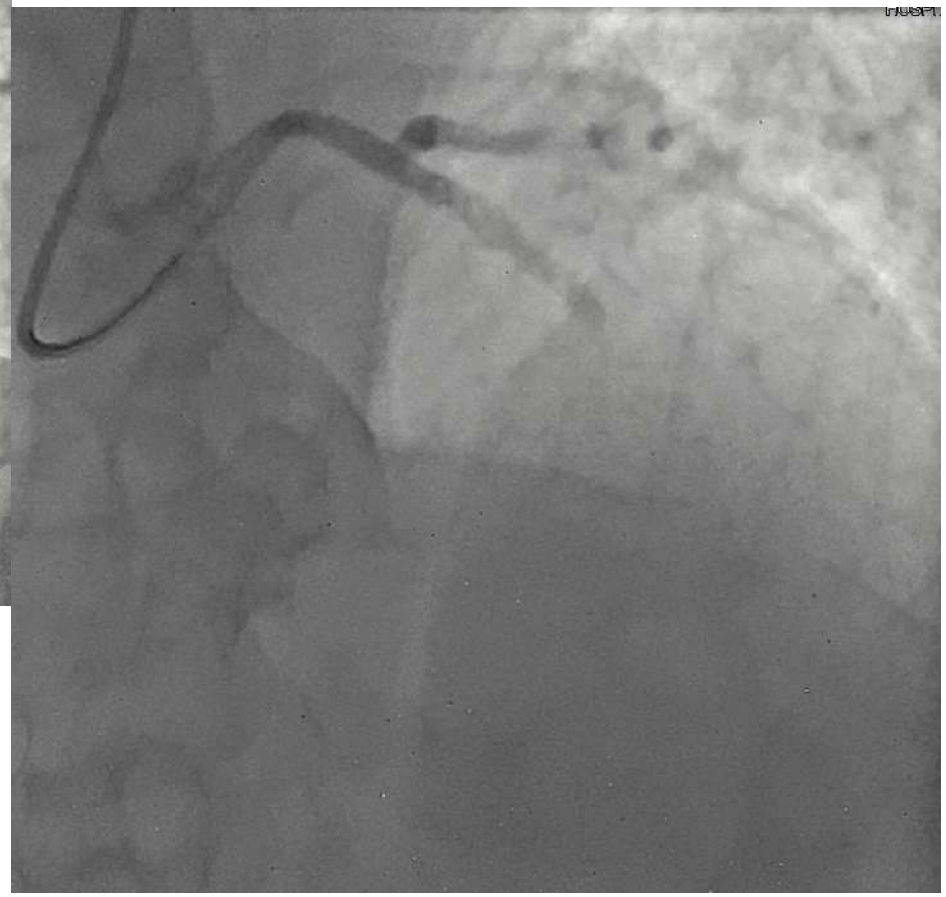

- *No realizamos IVUS por estado hemodinámico del paciente

- DAPT. Retiro progresivo de vasoactivos
- Ecocardiografía con FEVI 30%, DD III, función VD conservada
- Retiro de BCIA a las 48 horas, destete difícil de VM.
- Extubación 5 días
- ACTP 2do tiempo CD
- Ecocardiografía pre alta: FEVI 44%.

Caso clínico 2

- Paciente mujer
- 90 años
- Niega factores de riesgo CV
- Tiempo de enfermedad: 5 hrs con historia de dolor torácico típico
- EKG: STE anterior
- Referido de periferia → PCI Primaria

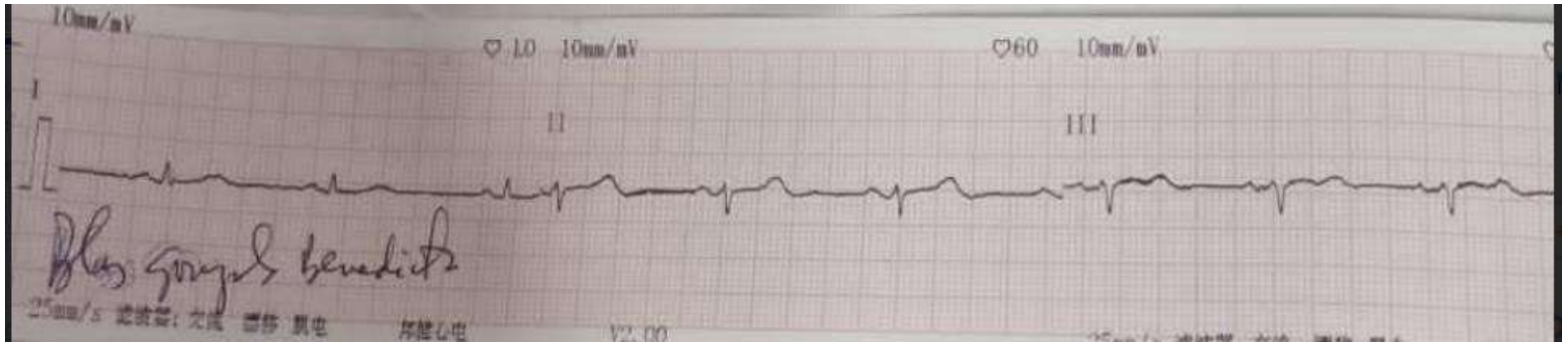
10mm/mV
I
II
III
25mm/s 滤波器: 交流 漂移 肌电
V2.00

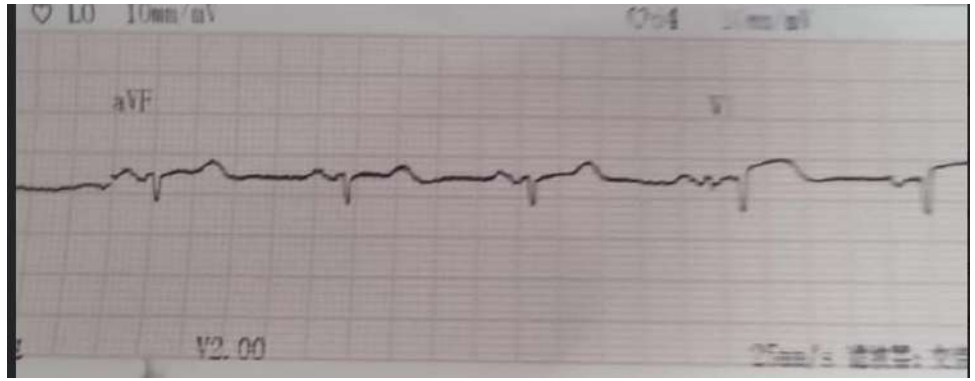
aVF
V2.00

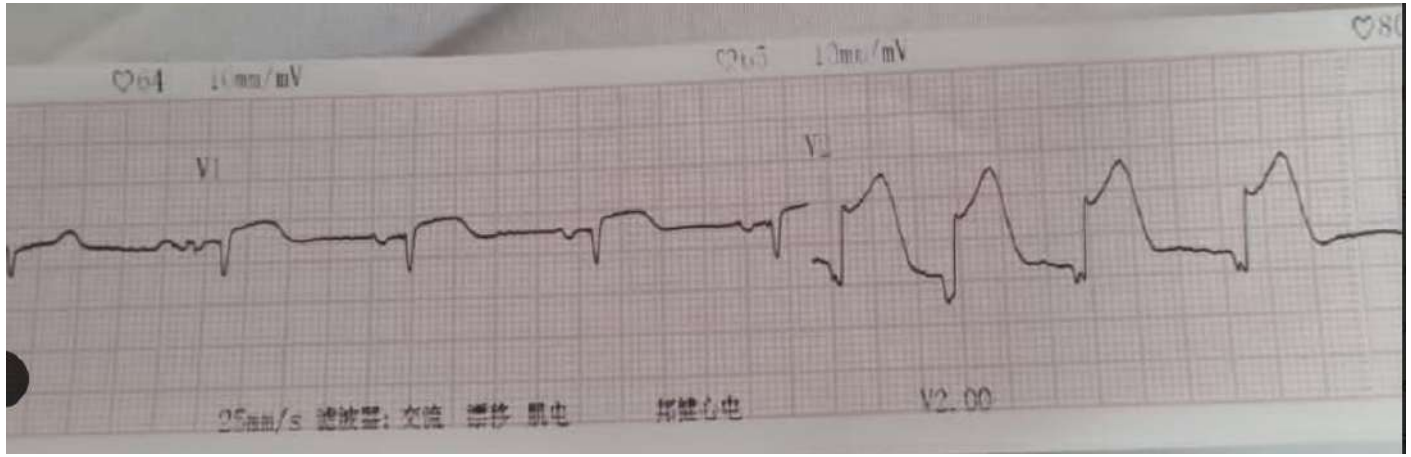
V1
V2
25mm/s 滤波器: 交流 漂移 肌电
V2.00

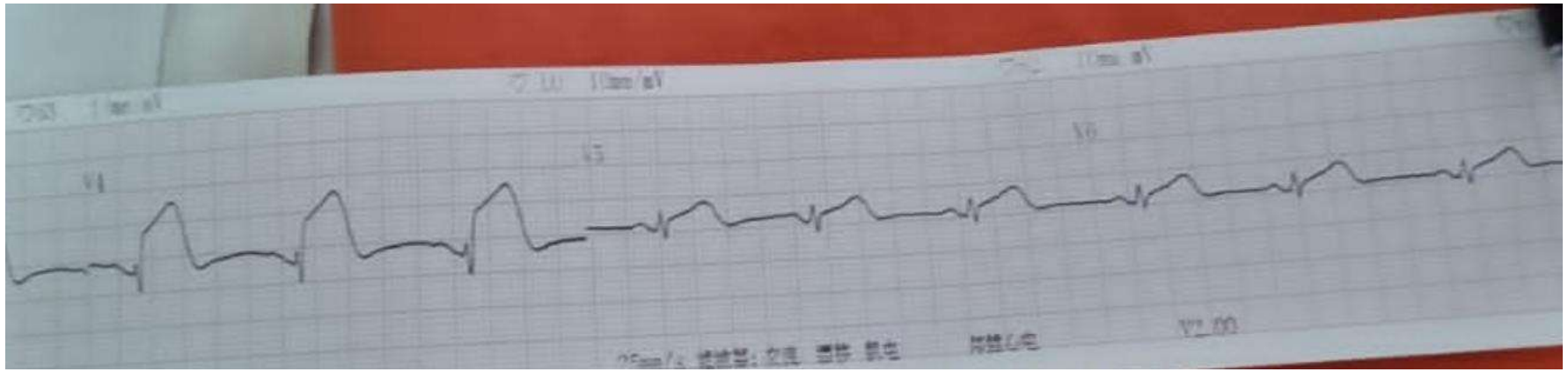
V4
V2.00

- Ingreso a emergencia

  Dx: IMSTE anterior KK II

  - PA 160/70 mmHg FC 87 lpm
  - Sat 92 % CBN 5 Lts
- No tolera decúbito, mal patrón ventilatorio
- IOT - VM

→ Ingresa a sala de hemodinámica

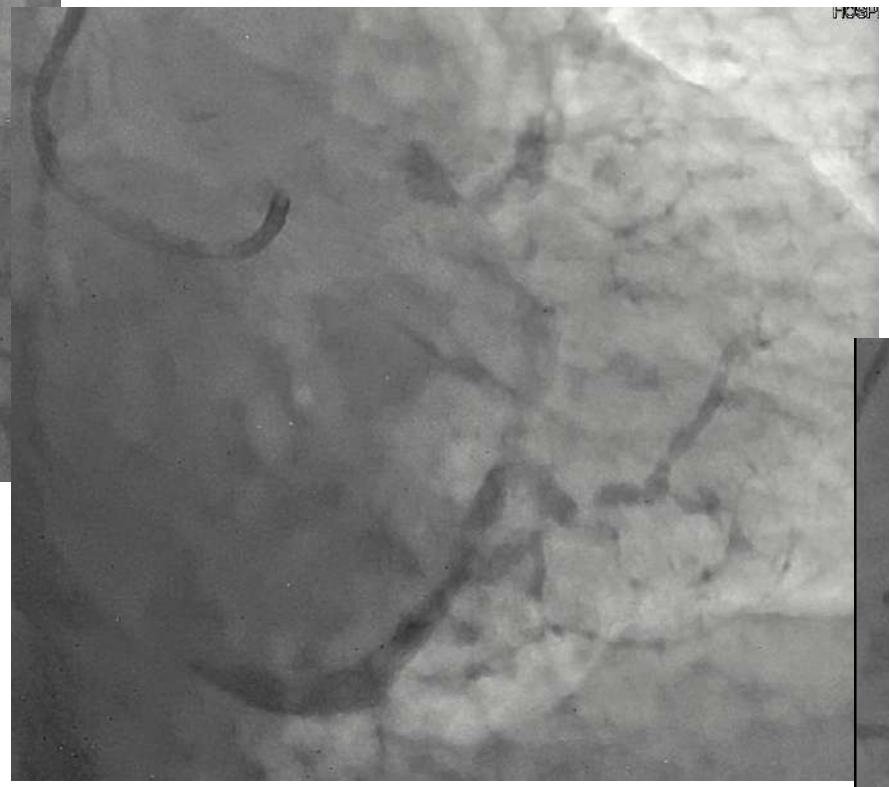

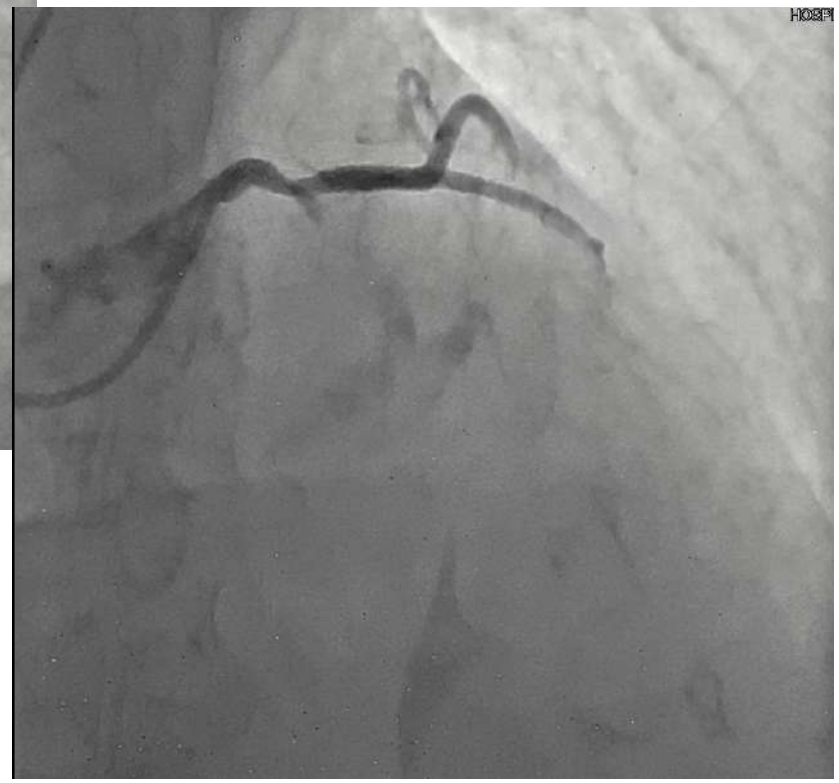

HOSP

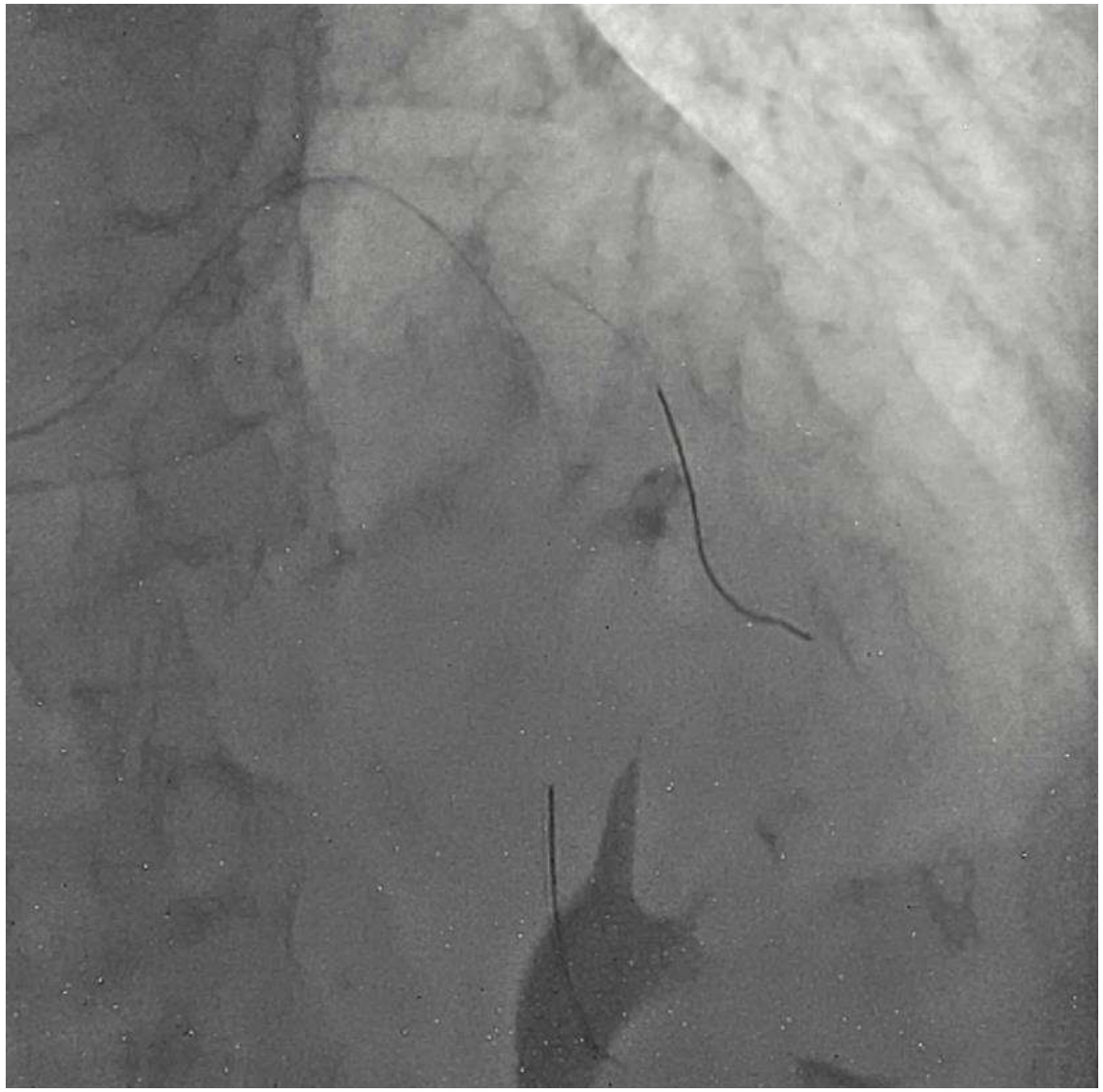

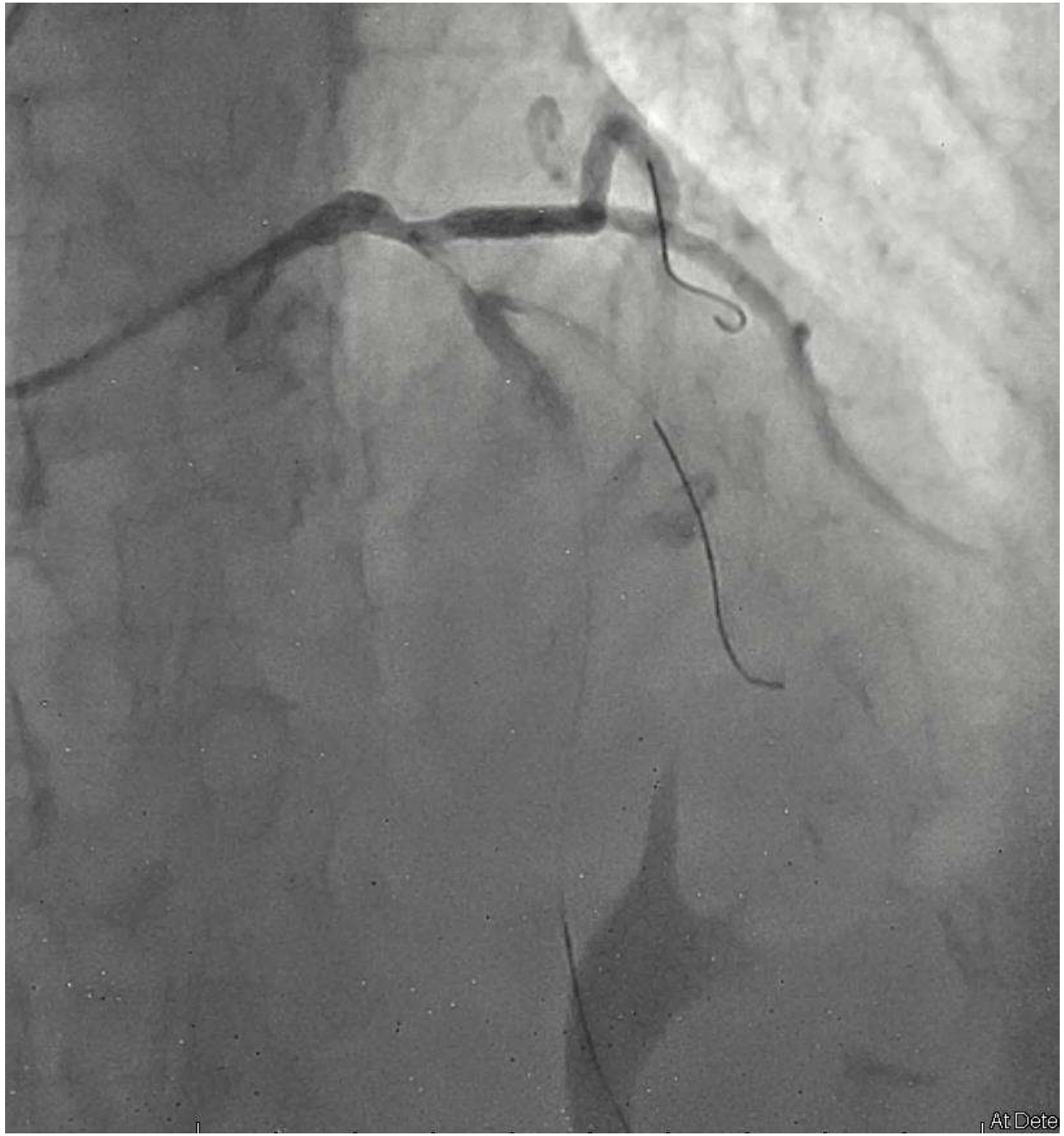

NO REFLOW
200 ucg Adenosina

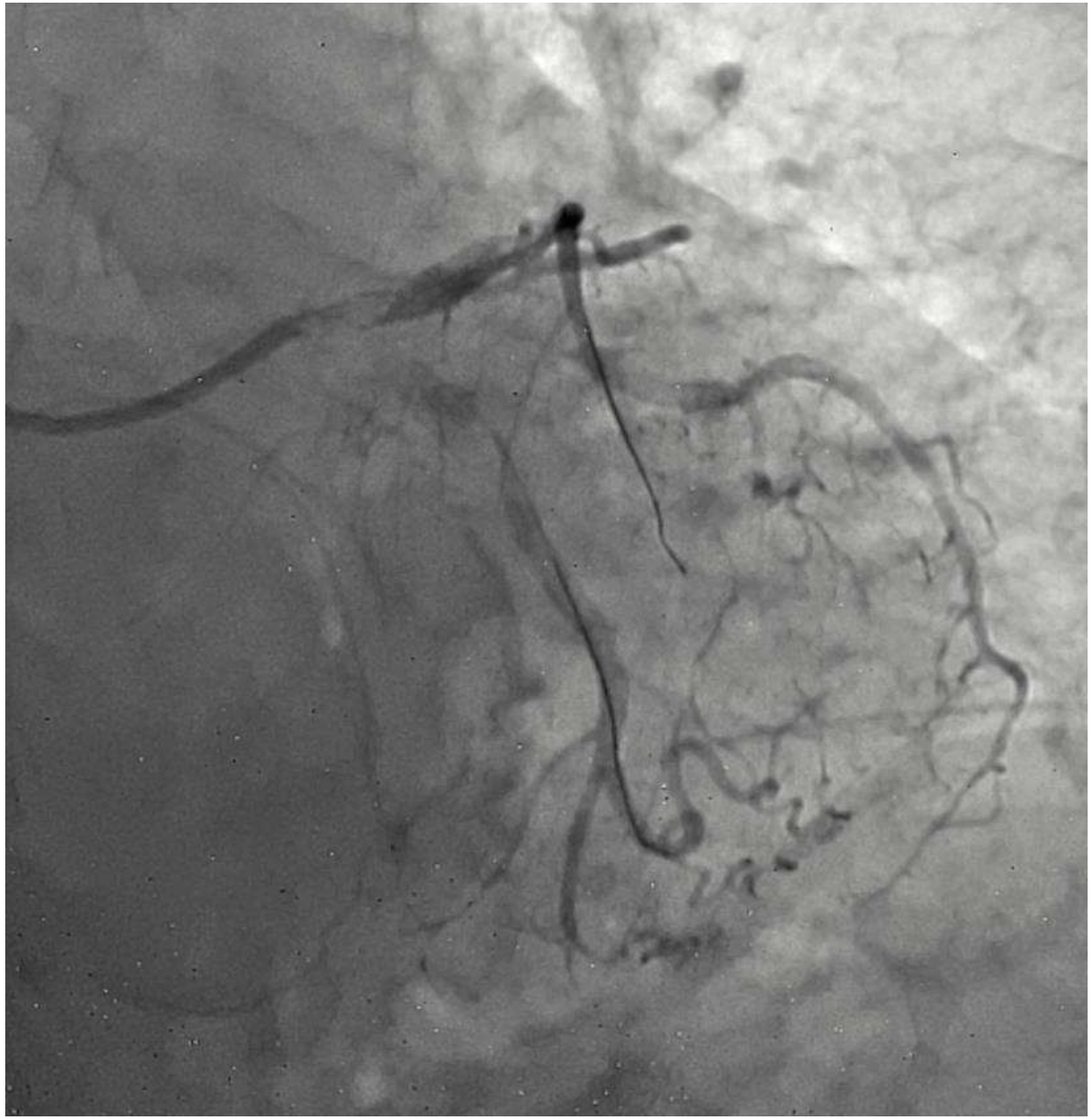

- Bifurcación: DA ostial
- Cx con ligera disminución de flujo

- → Recruzar a Cx

- Deterioro hemodinámico → soporte vasopresor e inotropo
- Retiro de vasoactivos en 24 hrs
- Extubación a 48 horas
- Ecocardiografía prealta con FEVI 46%

Conclusiones

- En inestabilidad hemodinámica: considerar soporte mecánico
- Provitional stent permite planificar y escalar a dos stents según la evolución del procedimiento
- Imagen intravascular: ideal en PCI tronco cuando la estabilidad clínica del paciente lo permita.