# CASO CLINICO

# *BIFURCACIONES*

## *EN SINDROME CORONARIO AGUDO*

**Dr. Gorky Mori Pinedo**

**Cardiólogo Intervencionista**

**INCOR – Clínica San Felipe - HRDCajamarca**

LIMA, Nov 17, 2023

Déjame
que te
Cuente

DEJAME QUE TE CUENTE...
CHABUCA GRANDA
INCLUYE:
LA FLOR DE LA CANELA • FINA ESTAMPA •
JOSE ANTONIO • ZEÑO MANUE y otros

# Entonces, les cuento…

## CASO CLINICO

### ANTECEDENTES

- Varón 59 años
- Casado
- Ocupación: Vigilante
- Procedente: Lima
- **Fumador** 12 – 15 cigarrillos/mes
- No: HTA, DM, DLP

# Entonces, les cuento…

## CASO CLINICO

### ANTECEDENTES

- Varón 59 anos
- Casado
- Ocupación: Vigilante
- Procedente: Lima
- Fumador 12 – 15 cigarrillos/mes
- No: HTA, DM, DLP

### PRESENTACION CLINICA

- A media mañana, Dolor precordial irradiado MSI, con sudoración
- Inmediatamente acude a Hospital MINSA donde se le Dx SCA STNE y administró DAPT con ticagrelor.
- 2 días después es referido a ESSALUD
- Hemodinámicamente estable.

# CASO CLINICO

- **EKG 1**

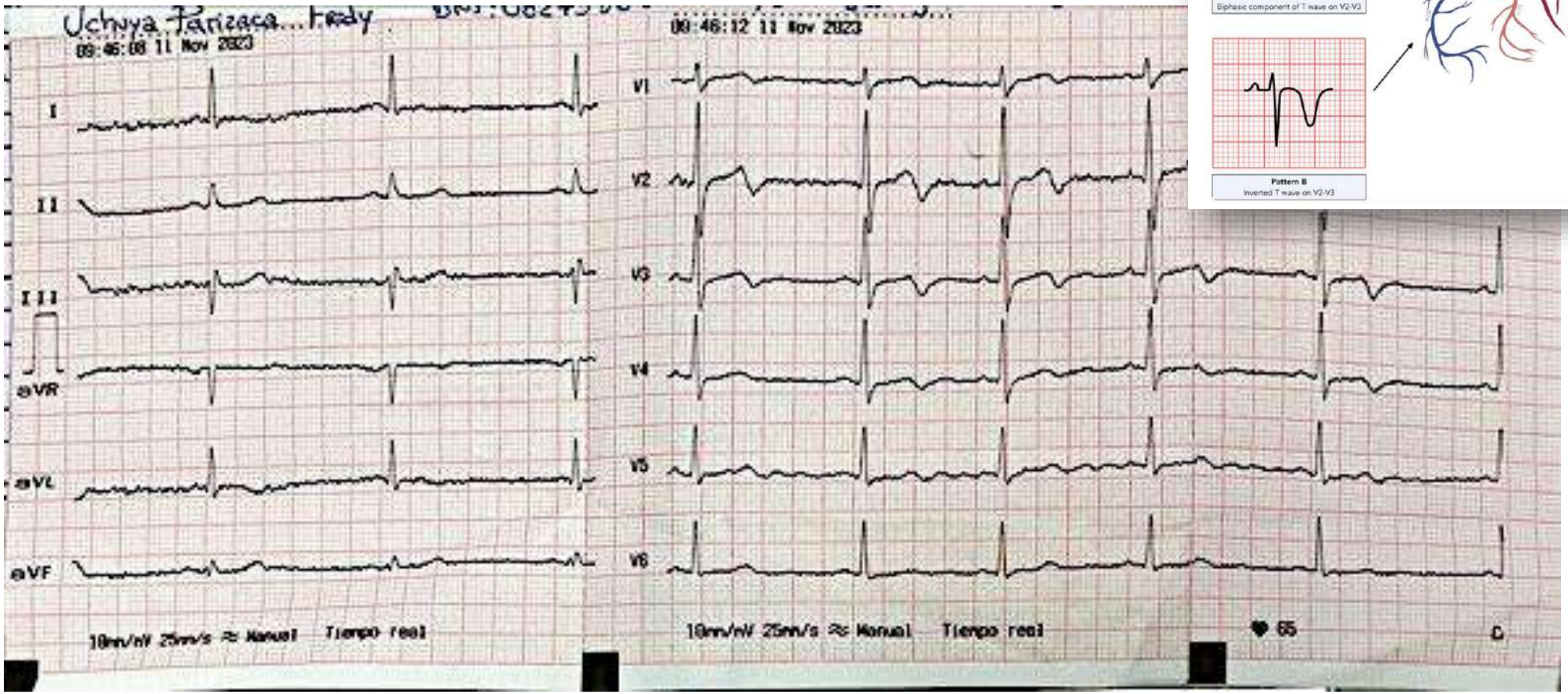


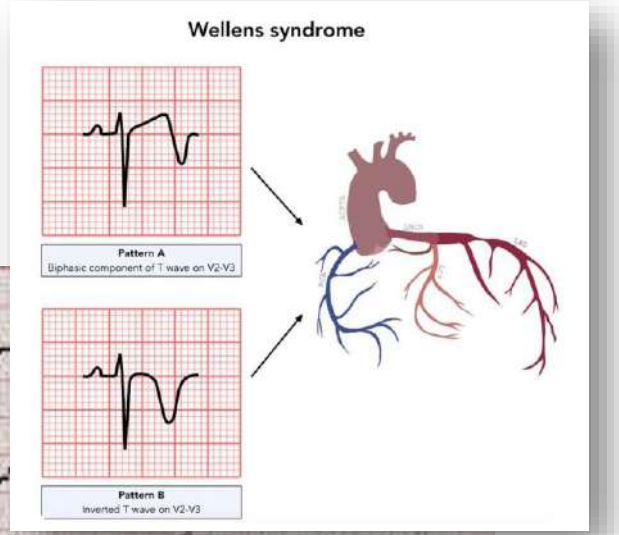

# CASO CLINICO

## LABORATORIO

- O+
- Hb 15.8 mg%
- Plaquetas: 252 000
- Glucosa: 93 mg%
- Creatinina:  0.79 mg%

## MEDICACION ACTUAL

- AAS 100 mg qd
- Clopidogrel 75 mg qd
- Atorvastatina 40 mg qd
- Enalapril 10 mg qd
- Ranitidina 300 mg

# CASO CLINICO

- RX Torax

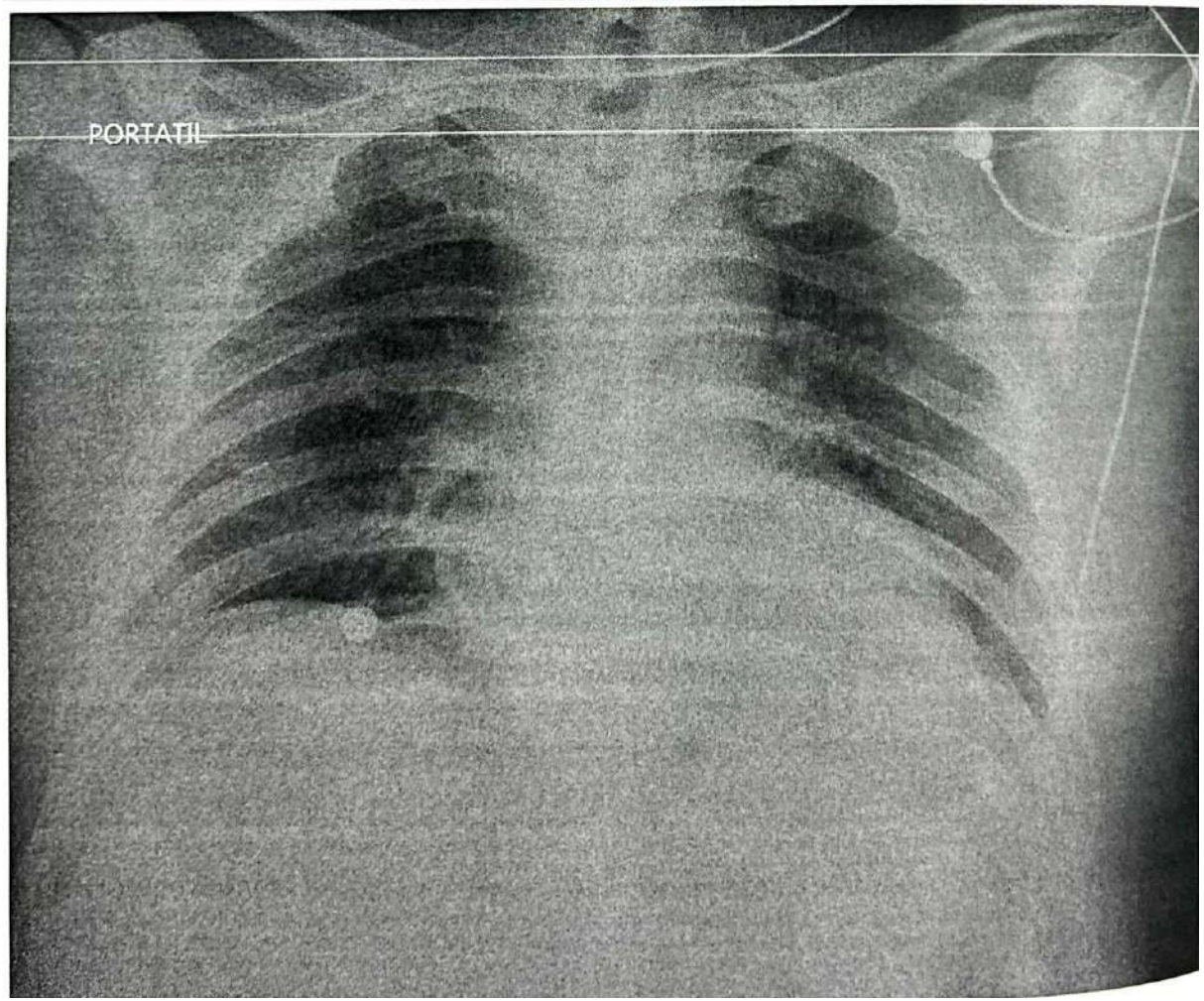

# CASO CLINICO

## ECOCARDIOGRAFIA

- FE 53%
- Hipocinesia apical, anterior, lateral, septal.
- DD tipo I.
- Funcion VD preservada
- No valvulopatias
- No HTP

(imagen de referencia)

# CASO CLINICO

- EKG 2

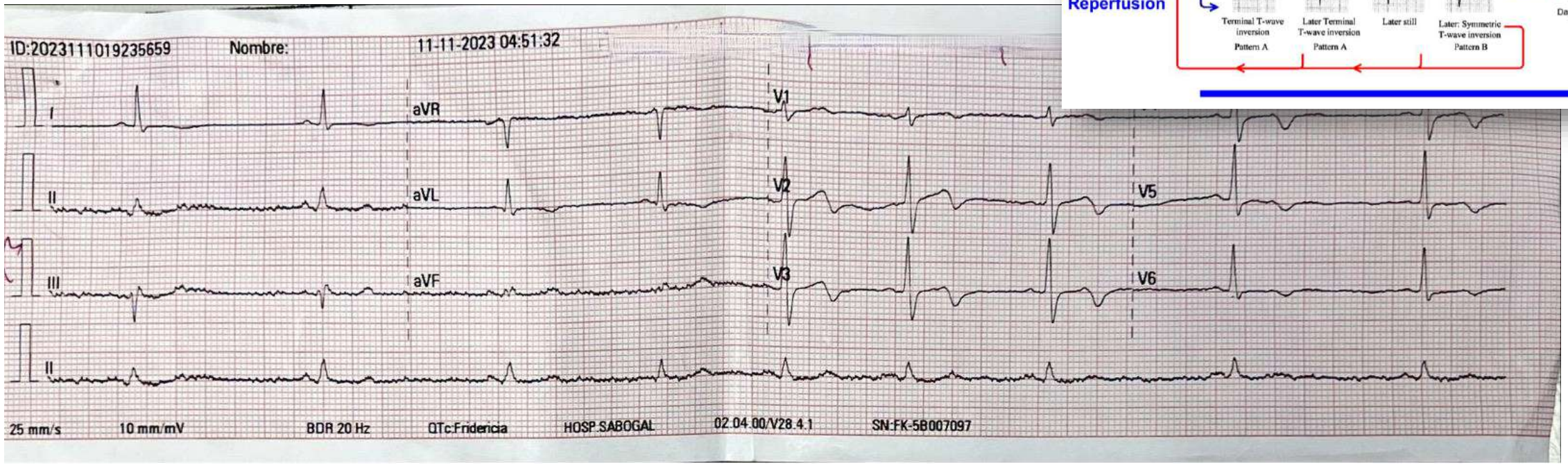


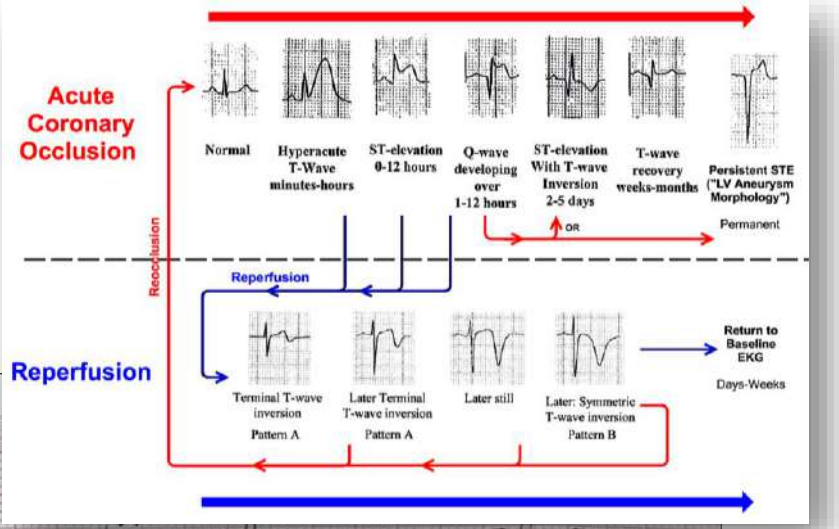

# CORONARIOGRAFIA

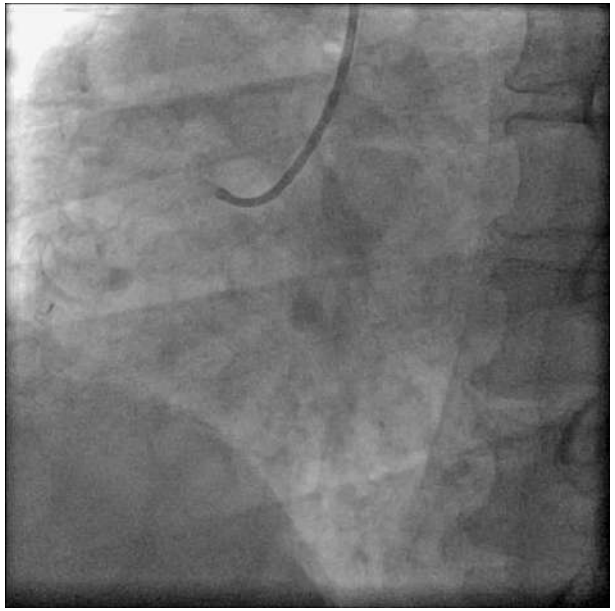

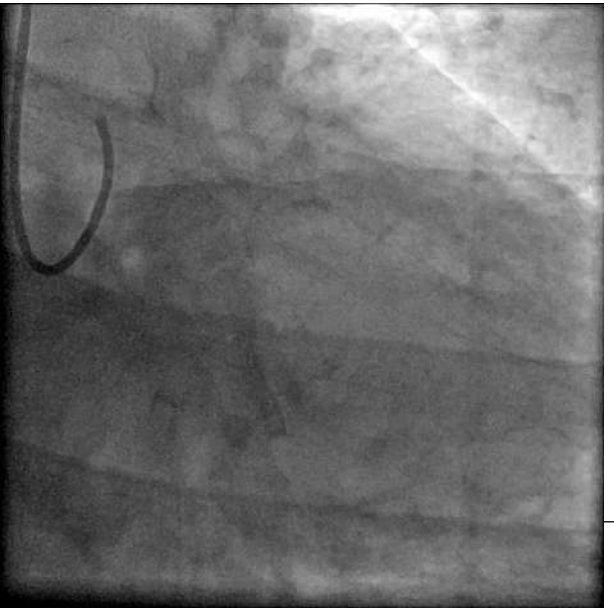

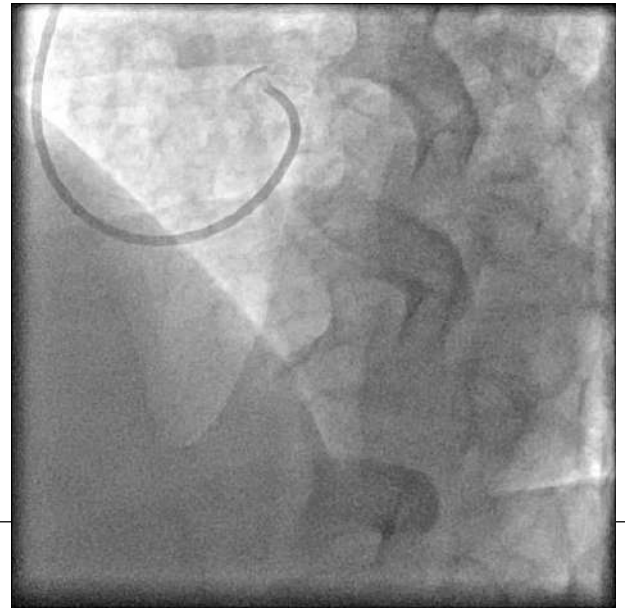

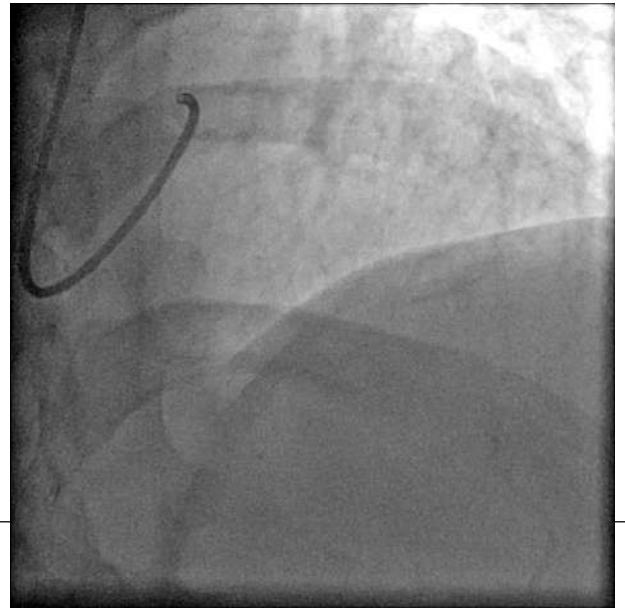

# CORONARIOGRAFIA

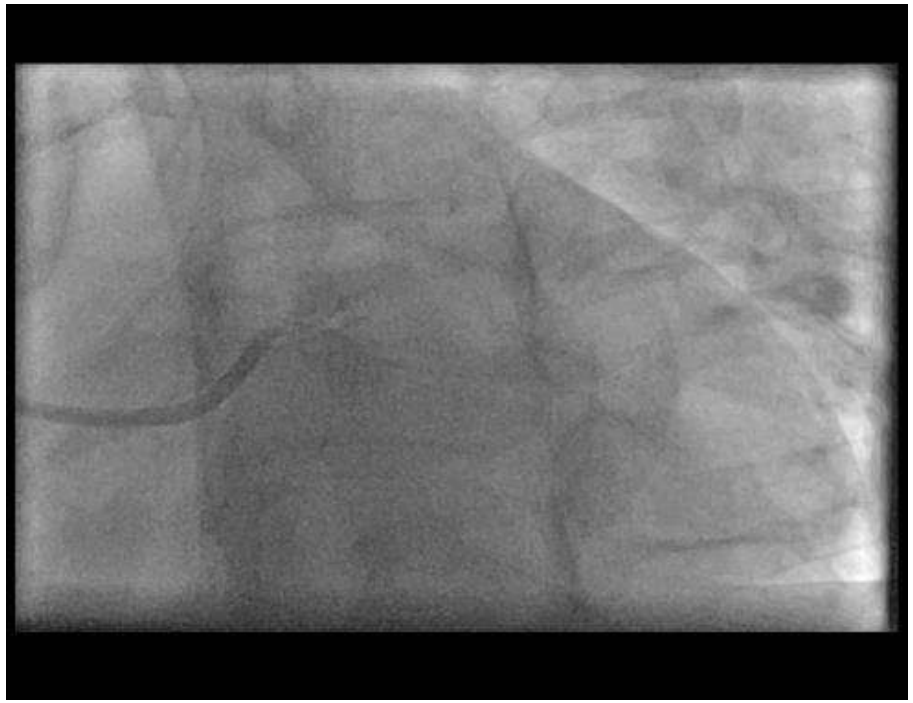

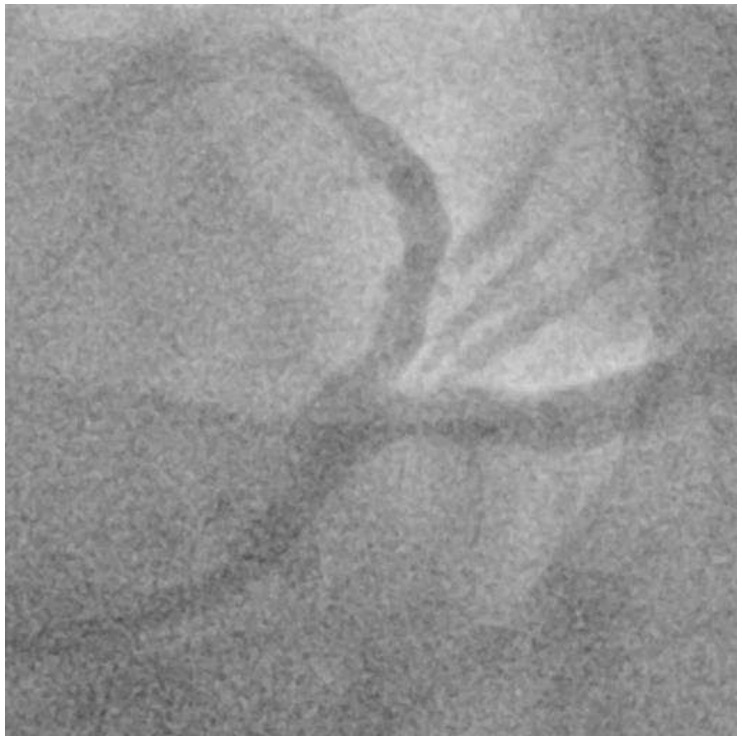

# IVUS DA a TCI

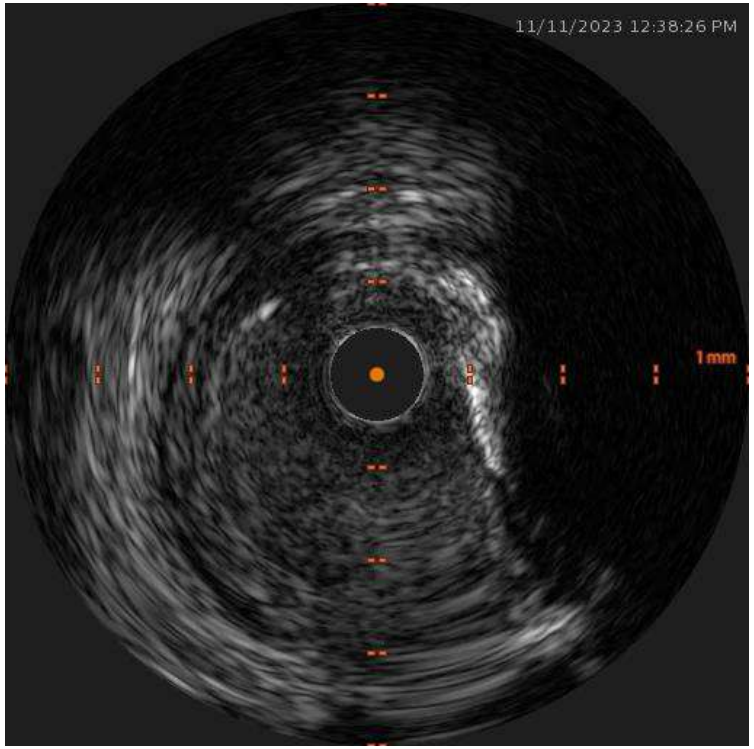


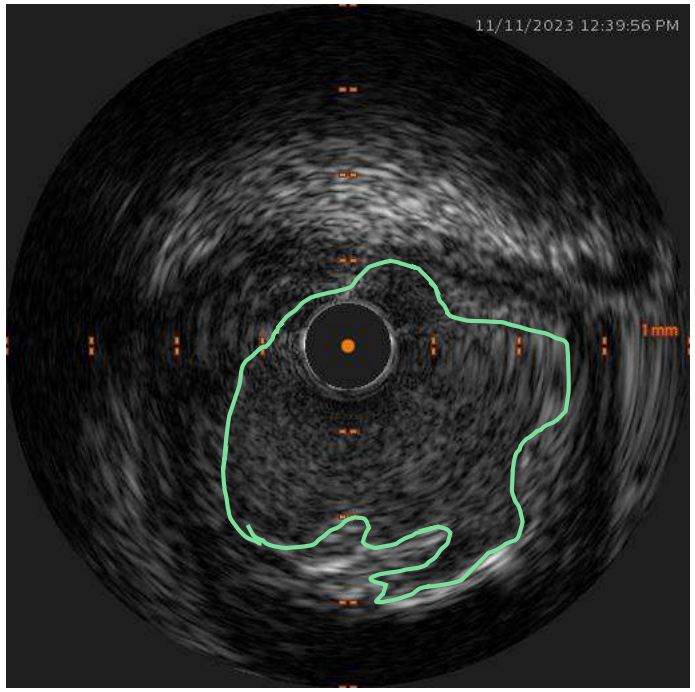


DA prox

Origen DA

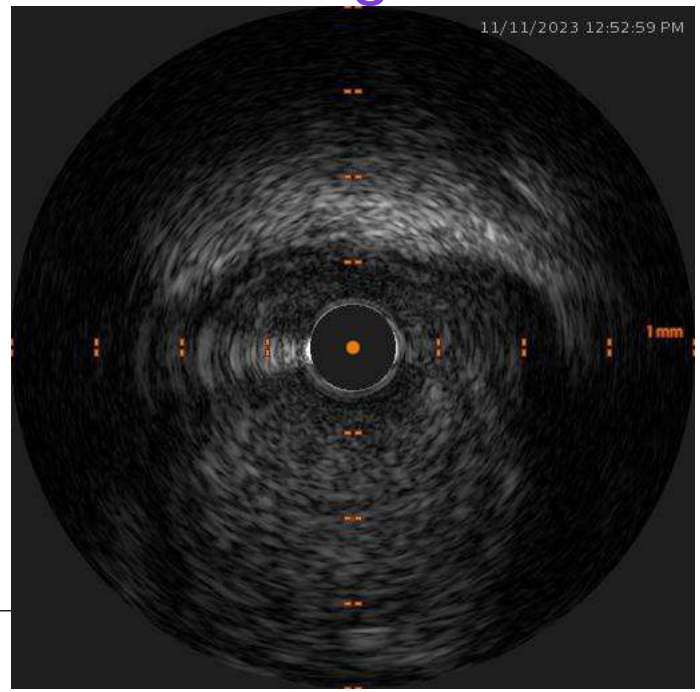

# ACTP DA Proximal con DES

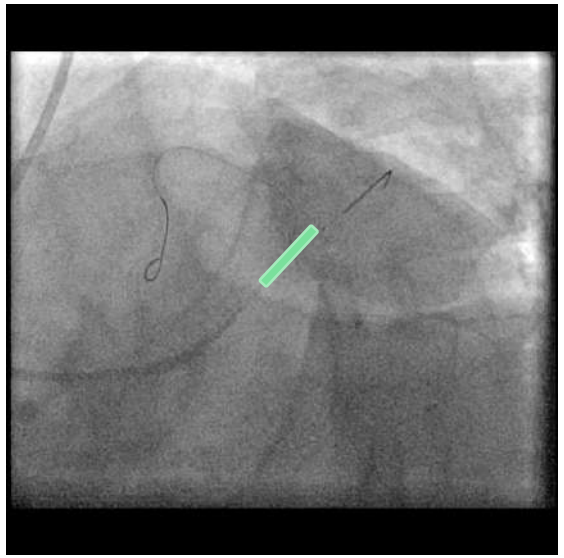

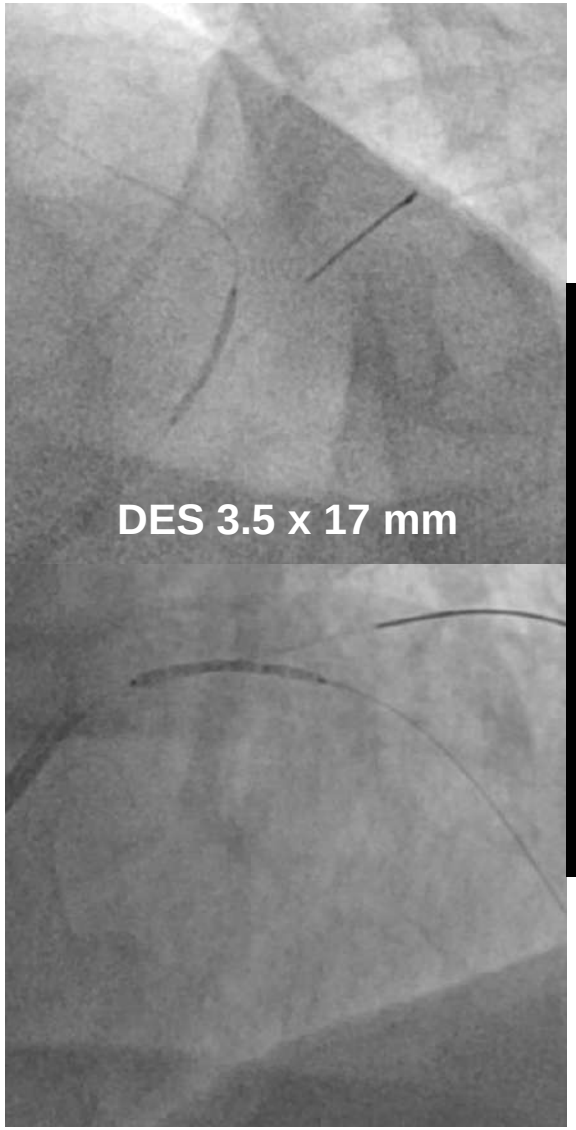


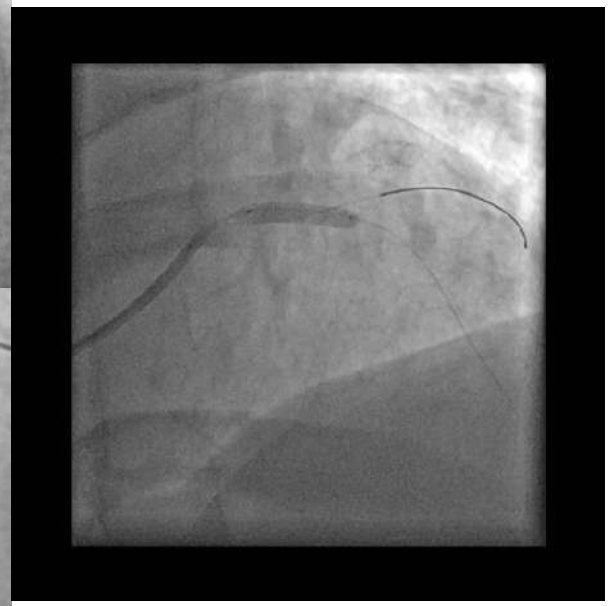

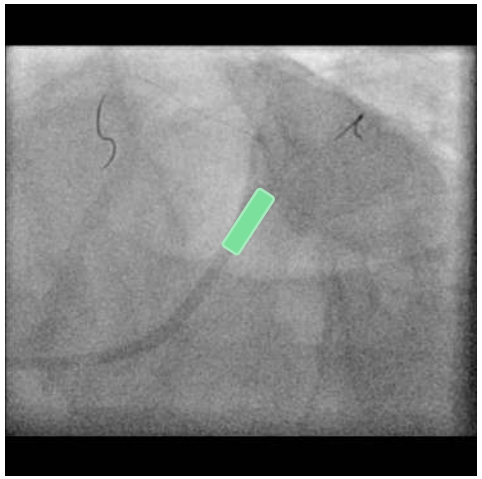

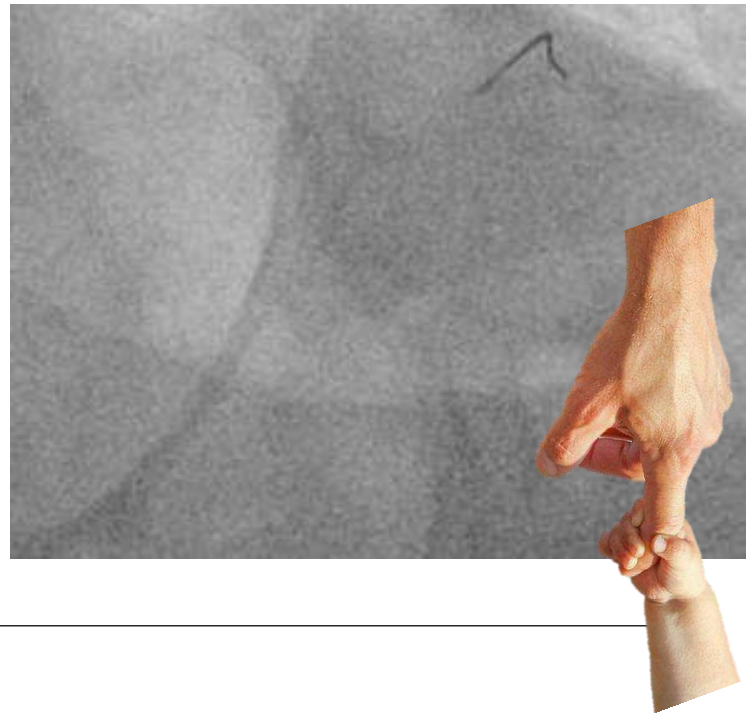

# Esto me recuerda al caso del paciente…

# Varón 53a, SCA STNE, Angor 10/10

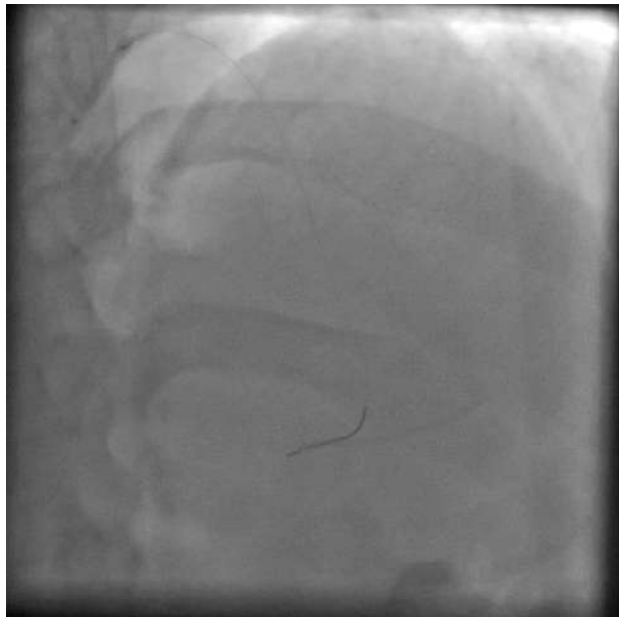

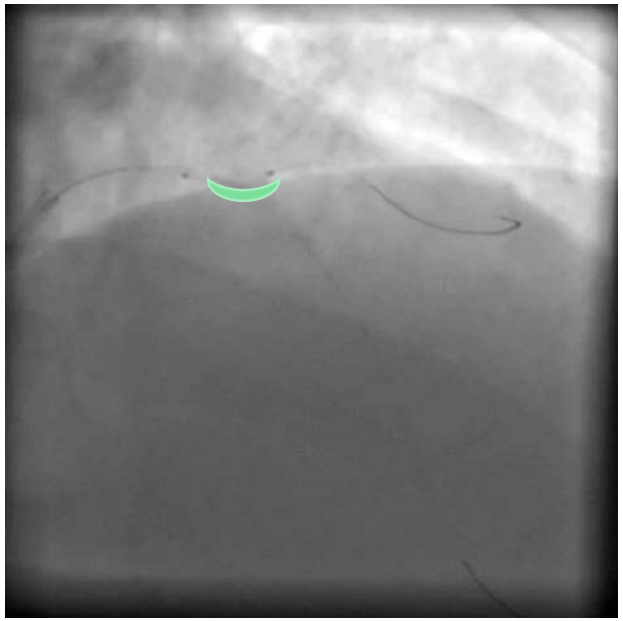

# Varón 53 a, STNE, Angor 10/10

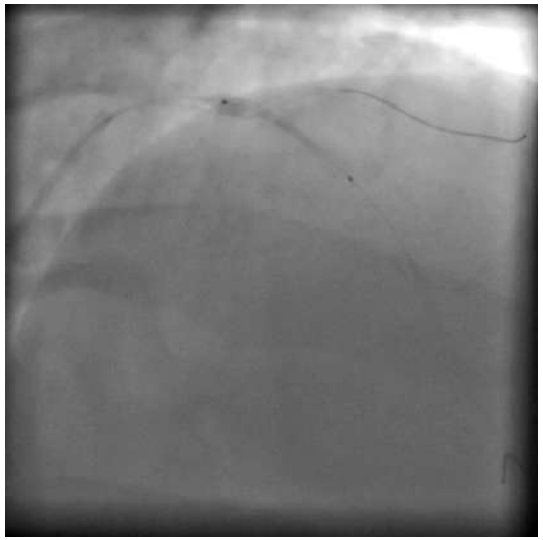

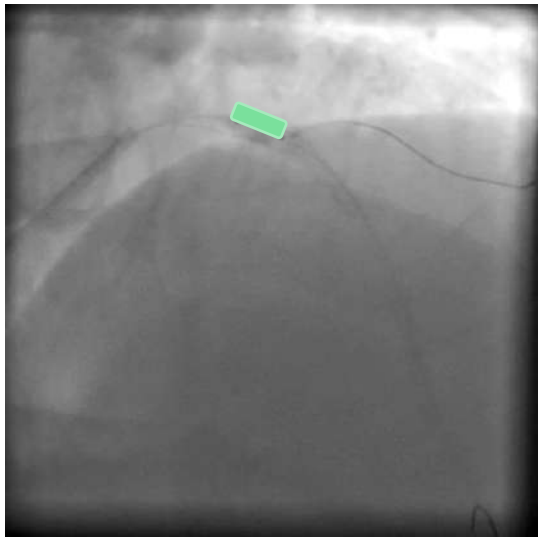

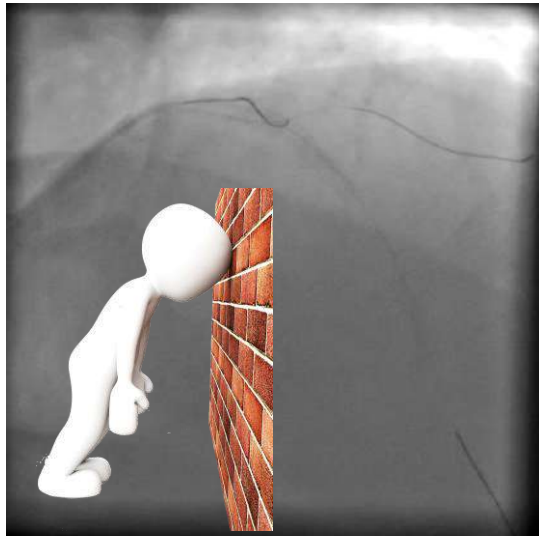

# Volvamos al caso…

# POT – side - POT

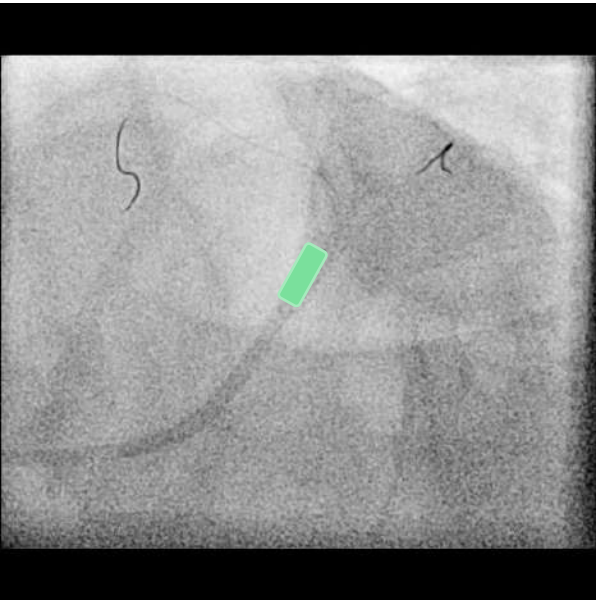

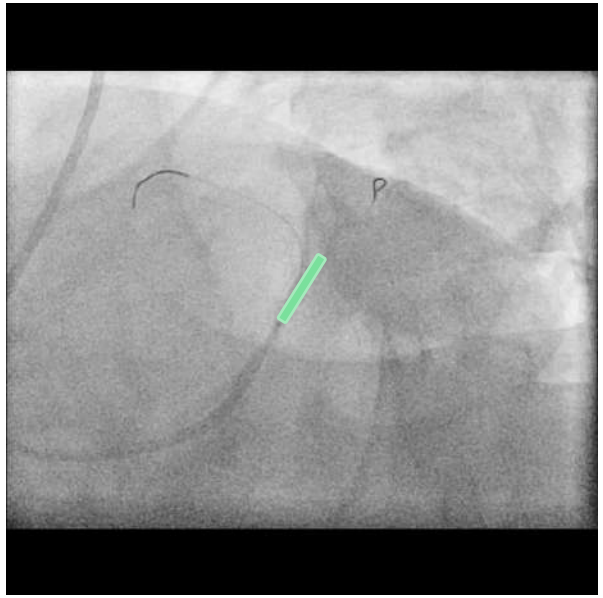

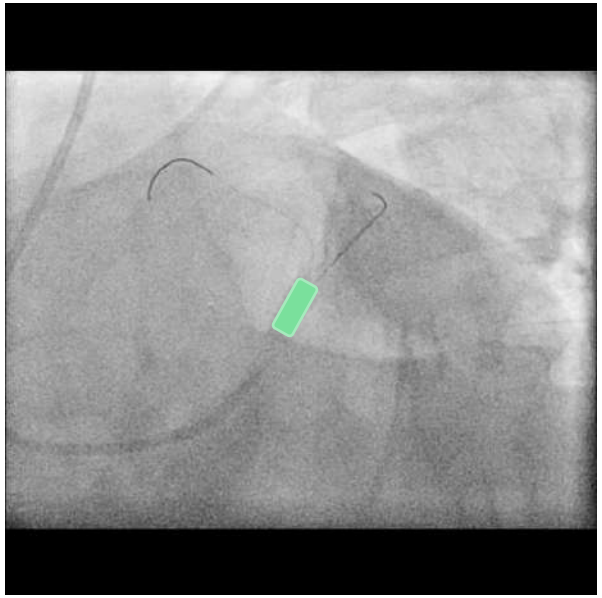

# POT – side - POT

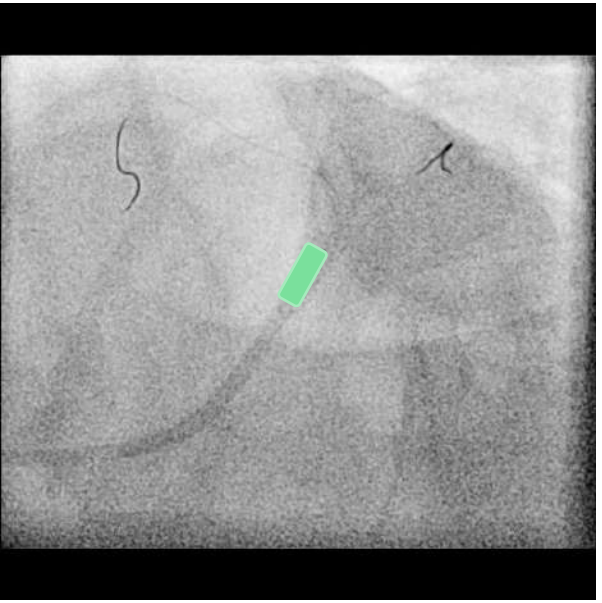

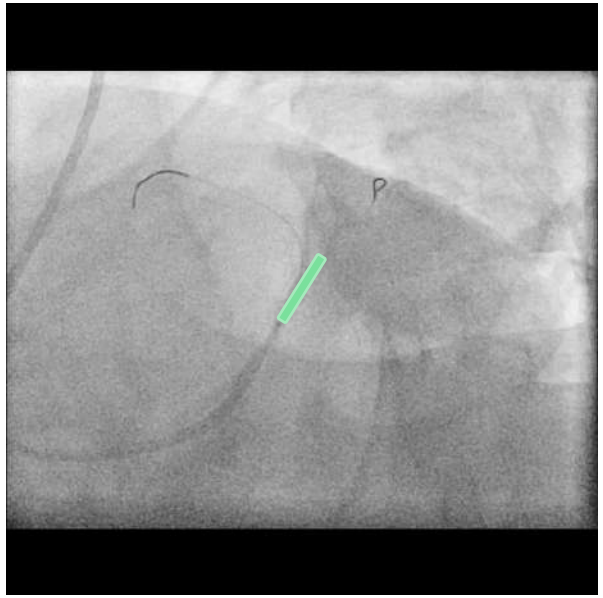

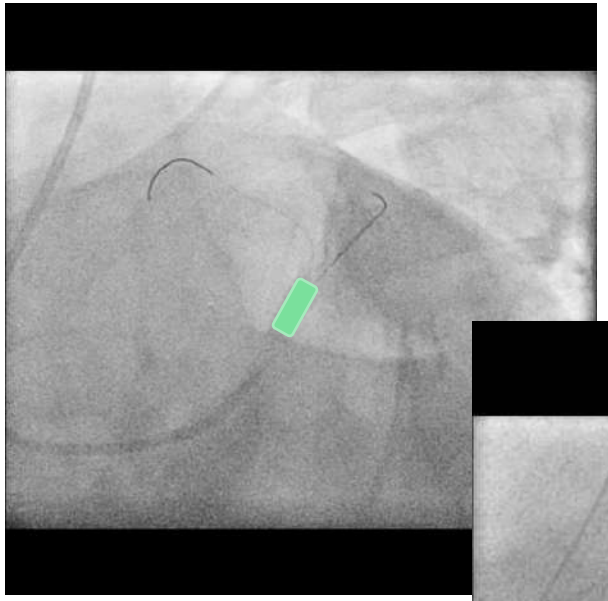

# IVUS Dg a DA

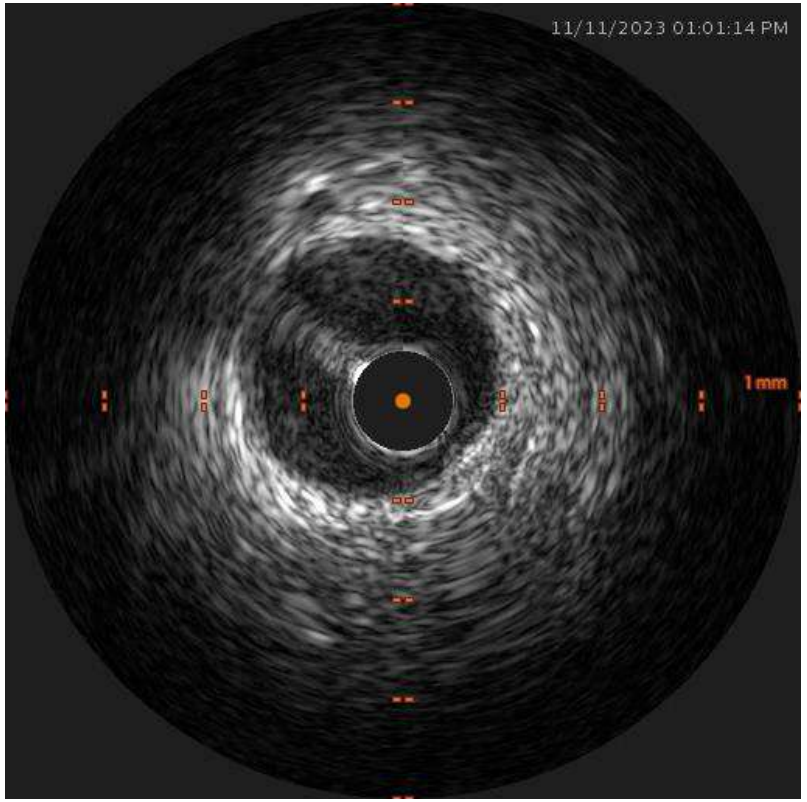


## Dg 3.9 mm2

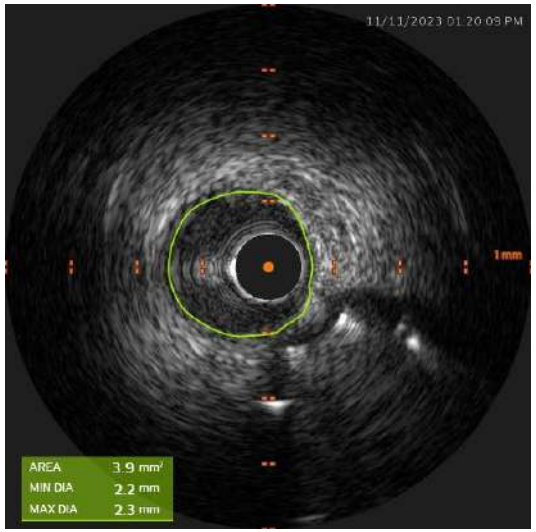


## bifurcación

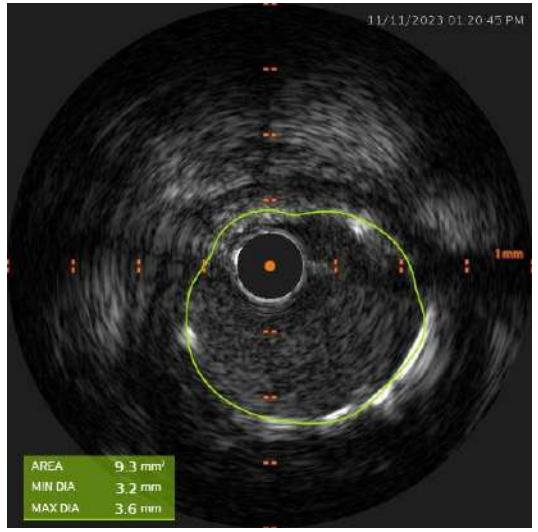


## DA 9.6 mm2

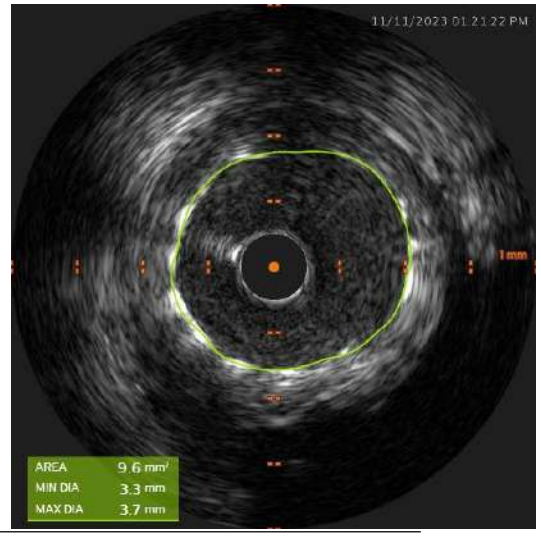

# RESULTADO FINAL

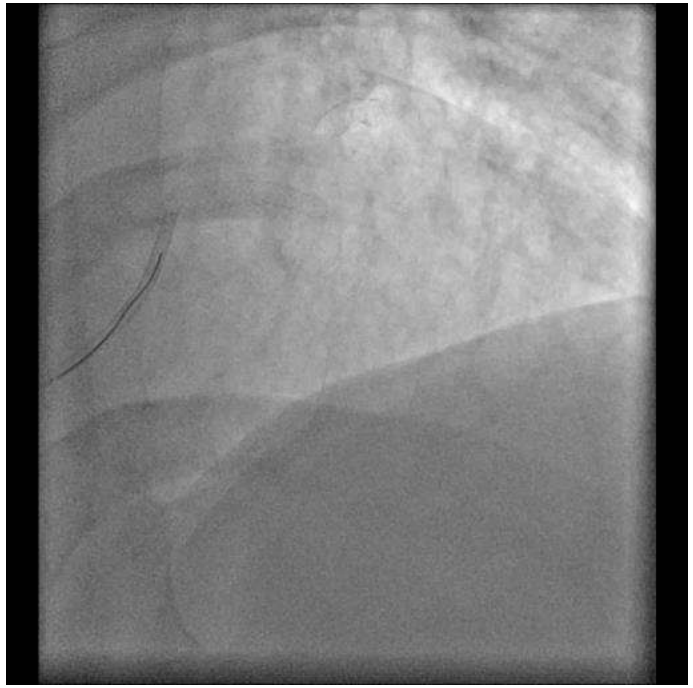

# Bonus track: **iFR EN BIFURCACIÓN**

# Bonus track: **iFR EN BIFURCACIÓN**

Varón 62 a, STE

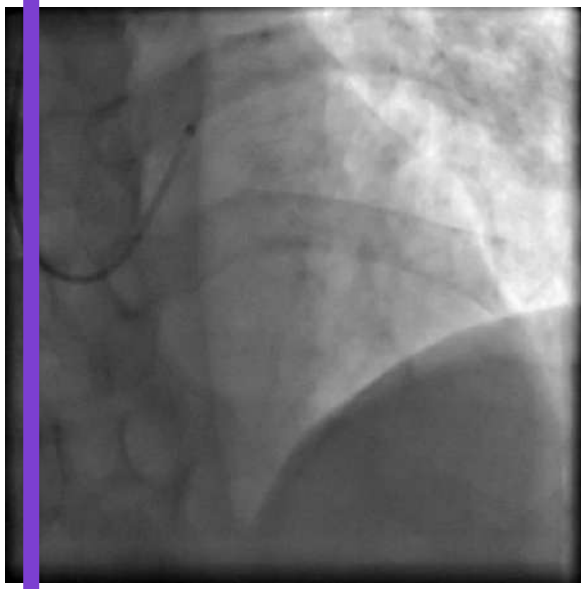
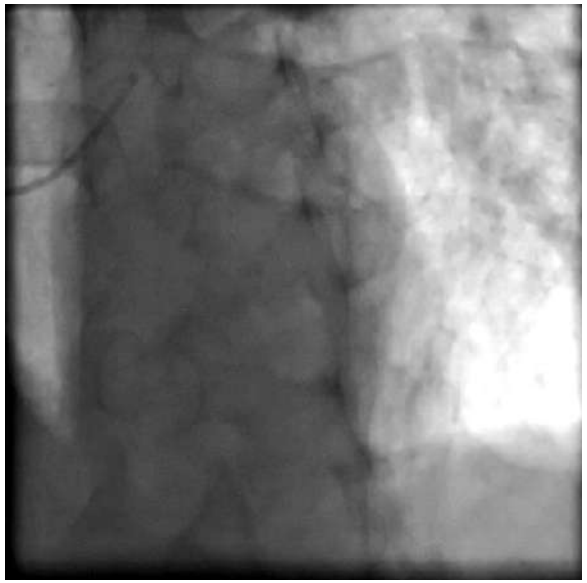
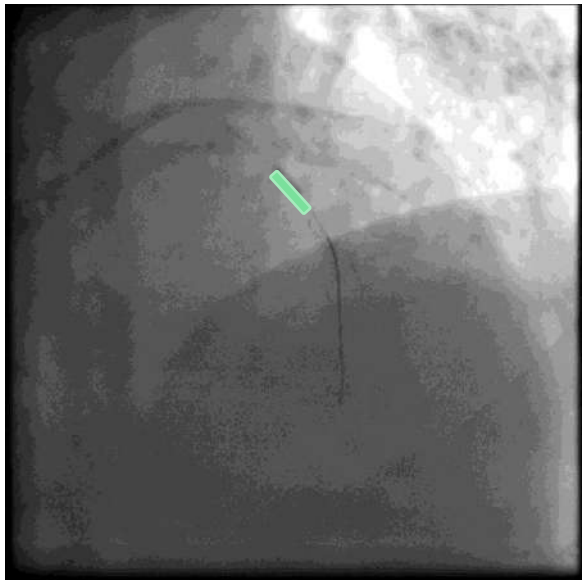
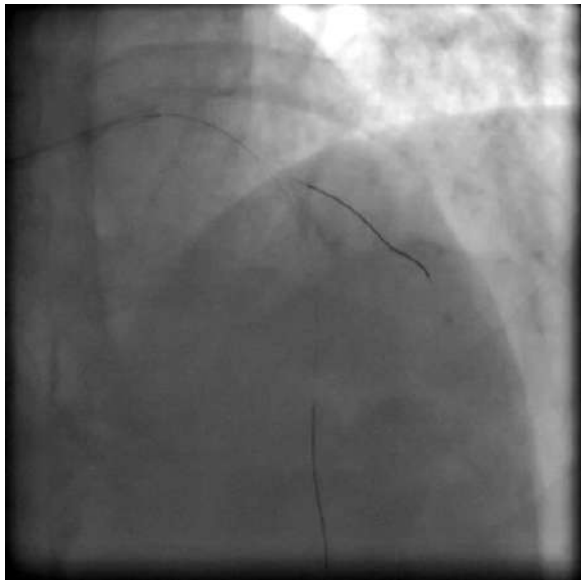

# ACTP DA Proximal con 2 DES

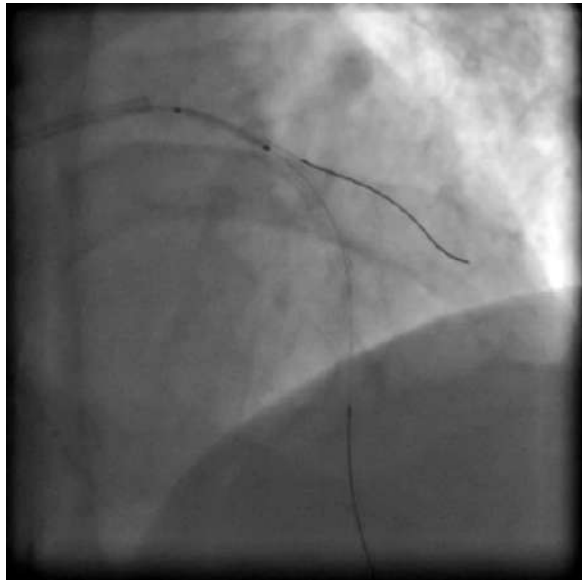

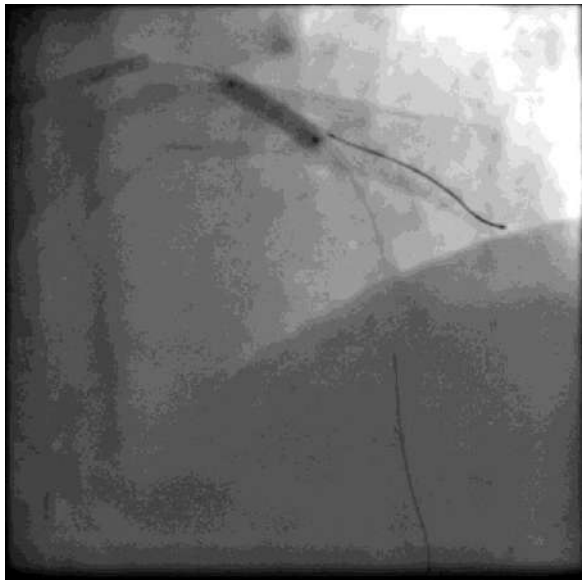

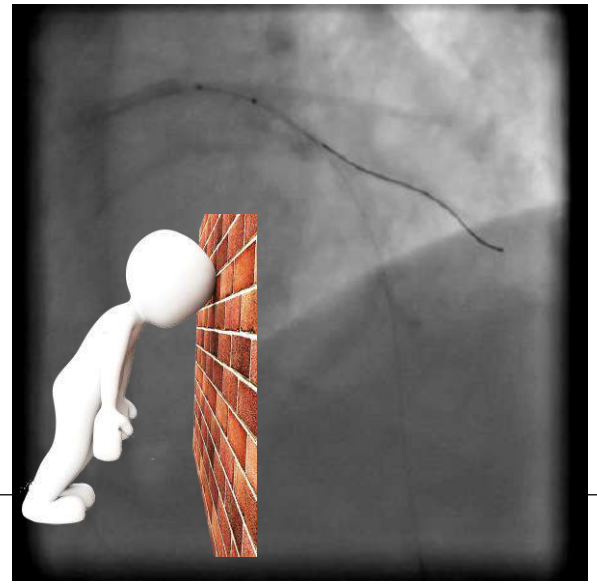

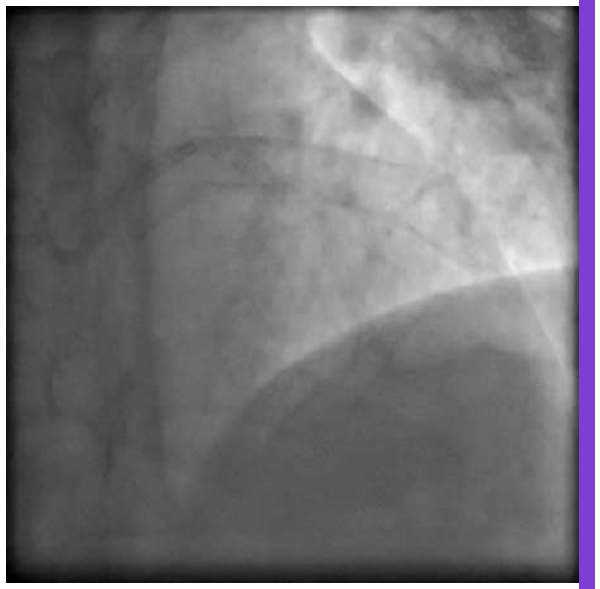

# 4 días después… Side – POT - iFR

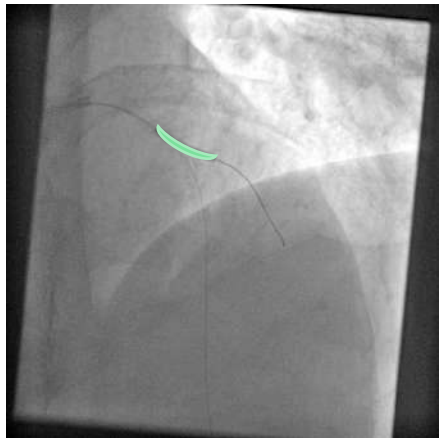

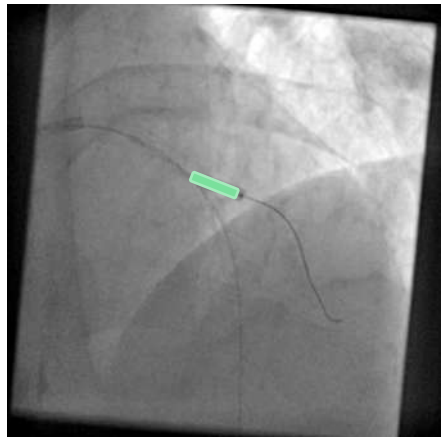

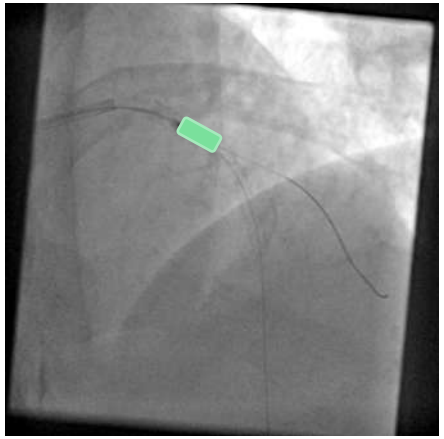

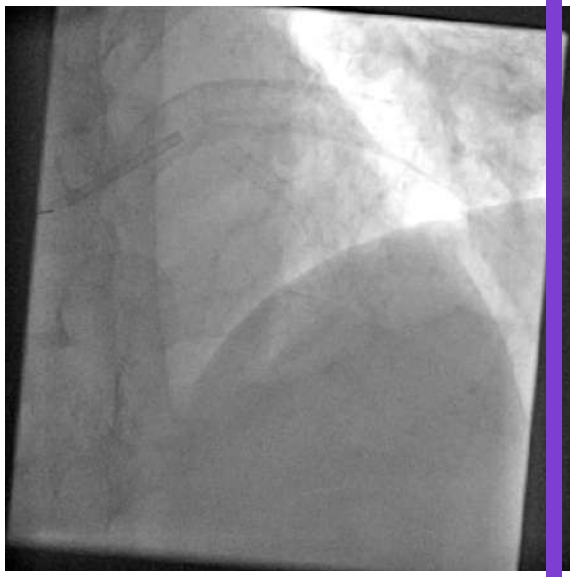

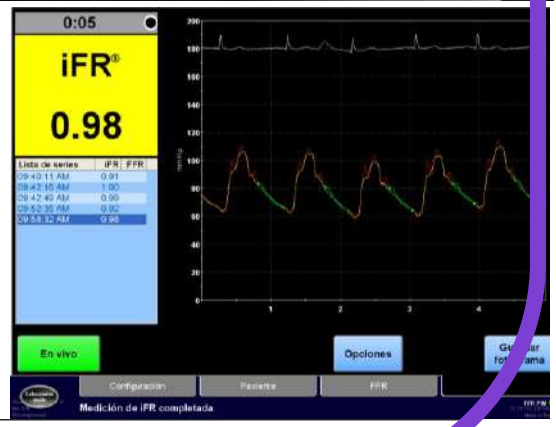

# Comentarios finales

1. Las lesiones de bifurcación están omnipresentes en nuestra práctica cotidiana.
2. Si bifurcación es una ICP Compleja, lo es más aún en el contexto de un Sindrome Coronario.
3. Stent Provisional siempre es la primera y mejor opción.
4. En nuestra realidad, las limitaciones de material muchas veces juegan en contra de la mejor resolución de una lesión en bifurcación.
5. El uso de Imágenes o de Fisiología Intracoronaria nos permiten optimizar el resultado en la ICP de bifurcación.
6. Si volvemos por una disección coronaria post anticoagulación ¿Por qué no volver por un gran ramo excluido?

Y ya
te lo
Conté