HOSPITAL UNIVERSITARIO
AUSTRAL

SOLACI
CACI`17
ARGENTINA

Curso Fellows ProEducar SOLACI

Ultrasonido Intracoronario

jtelayna@cas.austral.edu.ar

Estudio Complementario!! – Qué nos muestra?

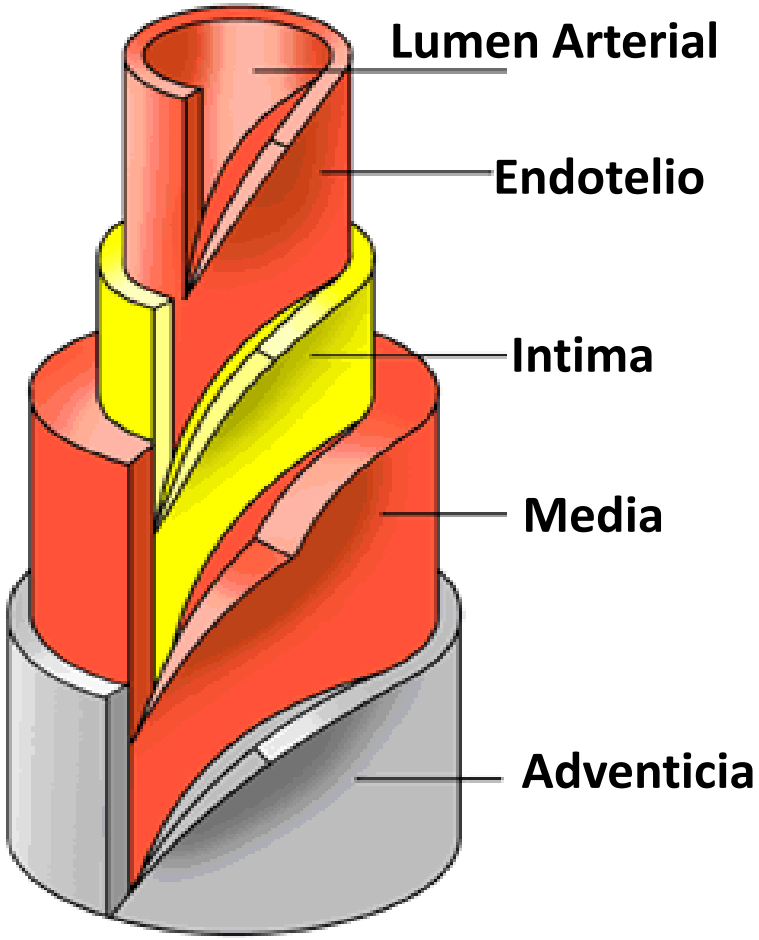

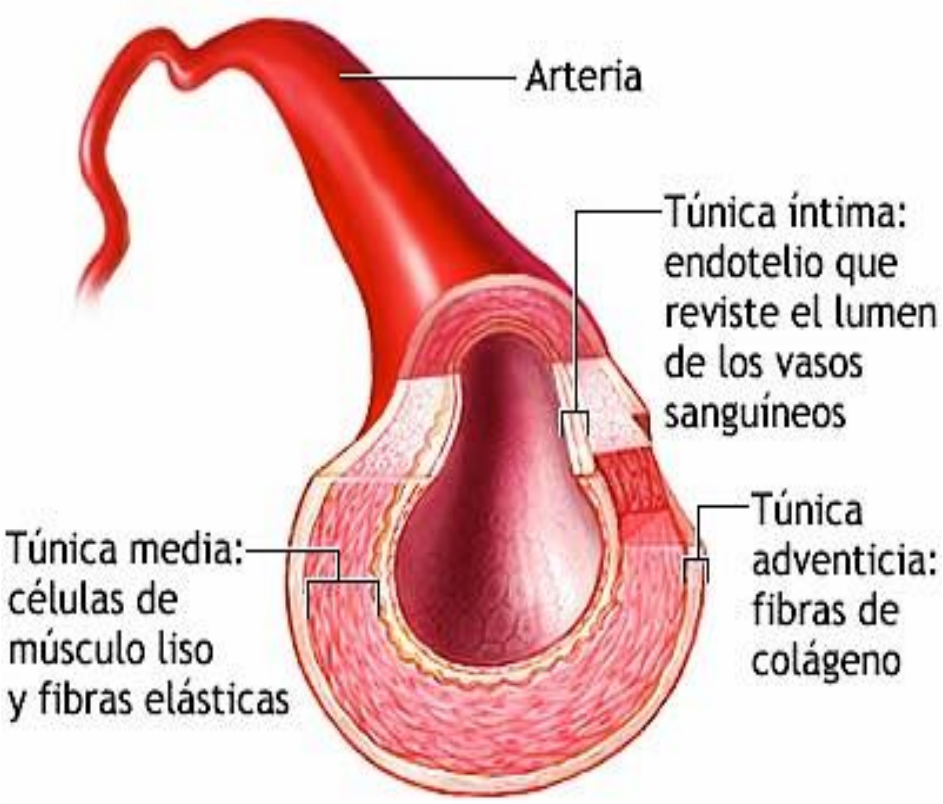

Estudio Complementario!!

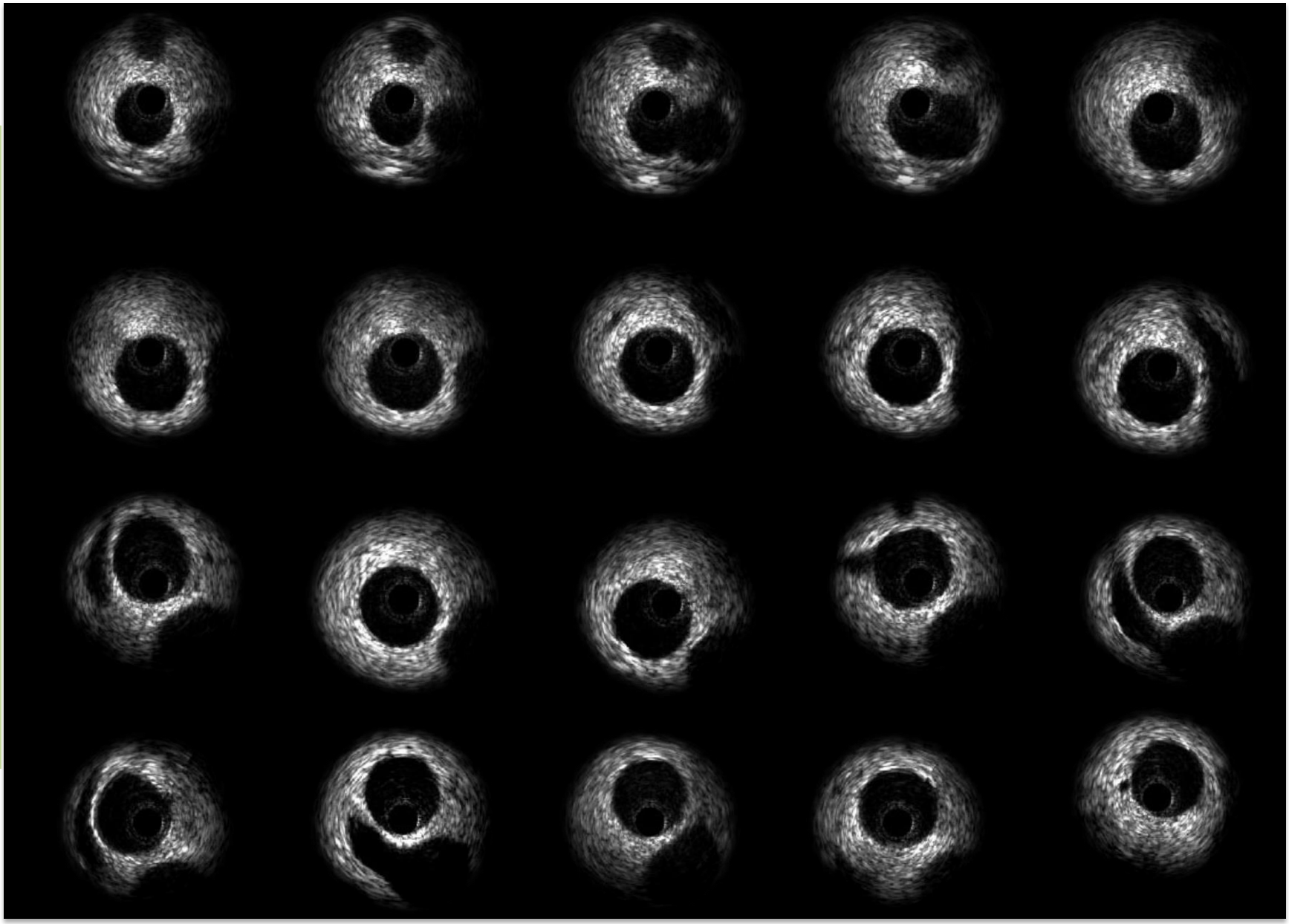

Estudio Complementario!! – Tipos de placas

Placa blanda: posee una densidad homogénea e inferior a la de la adventicia. No presenta calcio.

Placa cálcica: tiene ecos brillantes dentro de la placa, blancos, que producen una típica "sombra acústica" y que esta calcificación (medida en grados) sea mayor a 90° de la circunferencia del vaso.

Placa mixta: ecos brillantes dentro de la placa con sombra o una mezcla de placa blanda y dura.

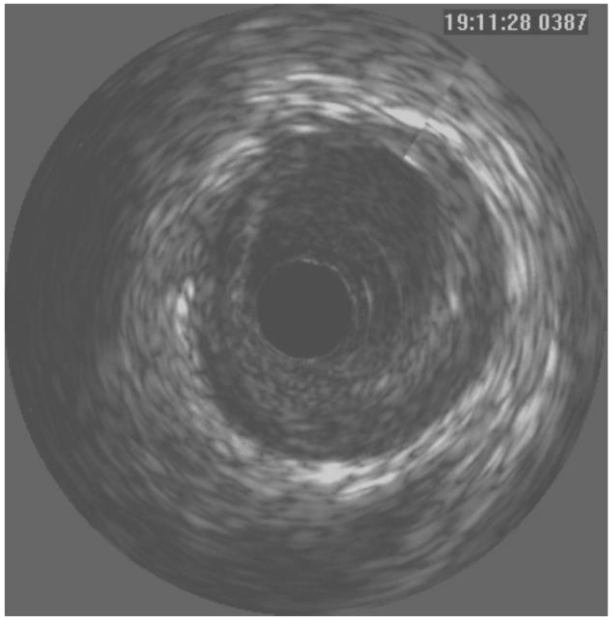

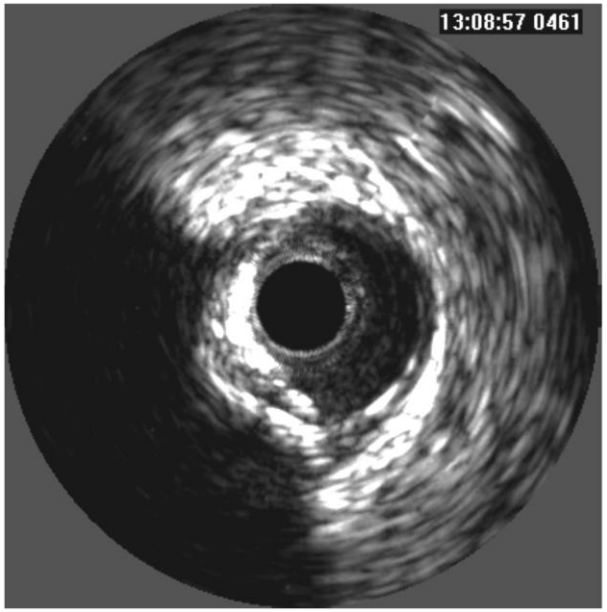

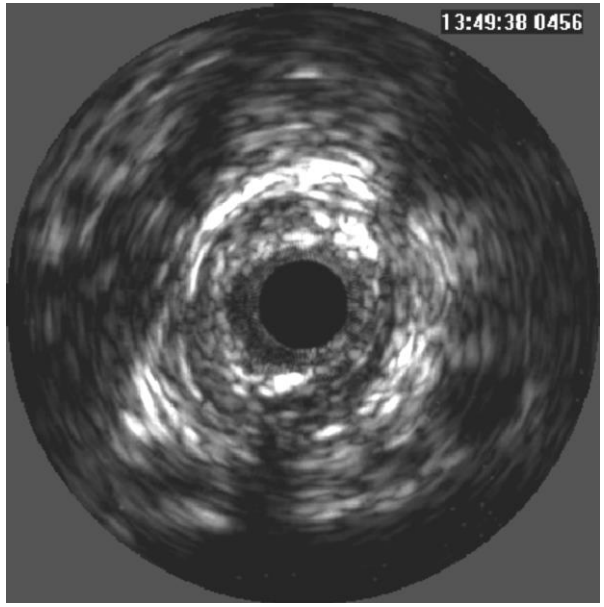

Estudio Complementario!! – Mediciones habituales

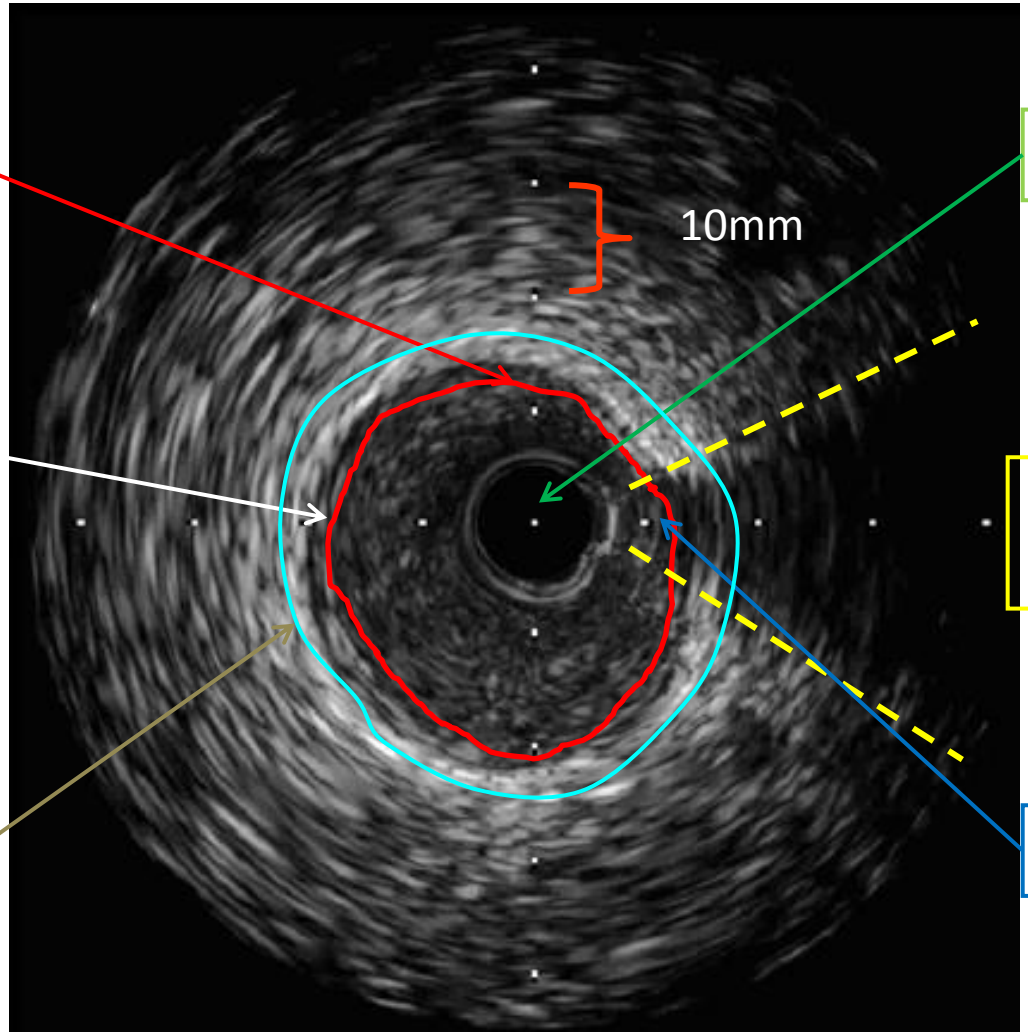

INTIMA

MEDIA

ADVENTICIA

CATETER

SOMBRA ACÚSTICA

CUERDA

HOSPITAL UNIVERSITARIO AUSTRAL

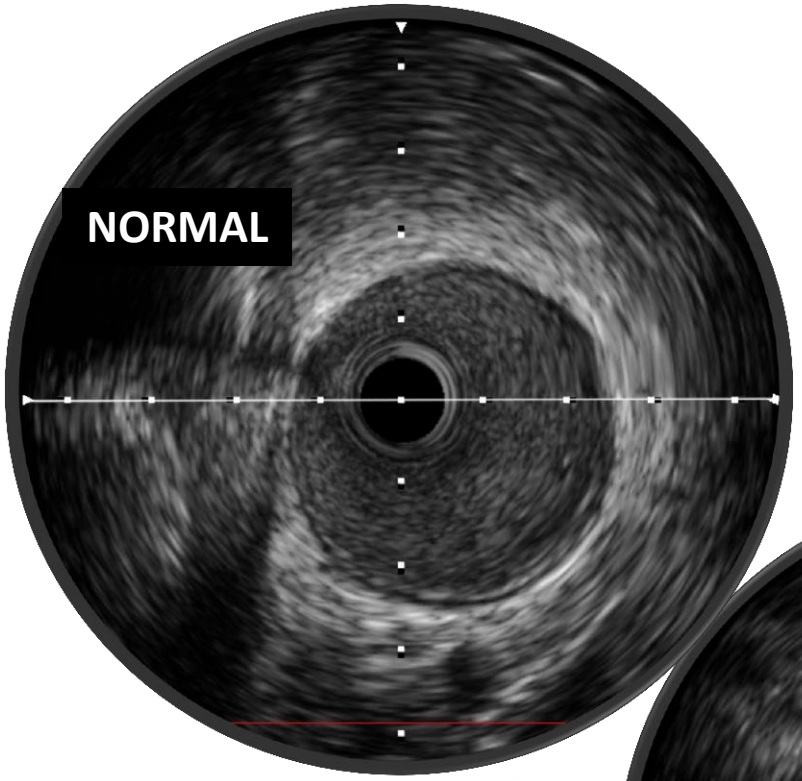

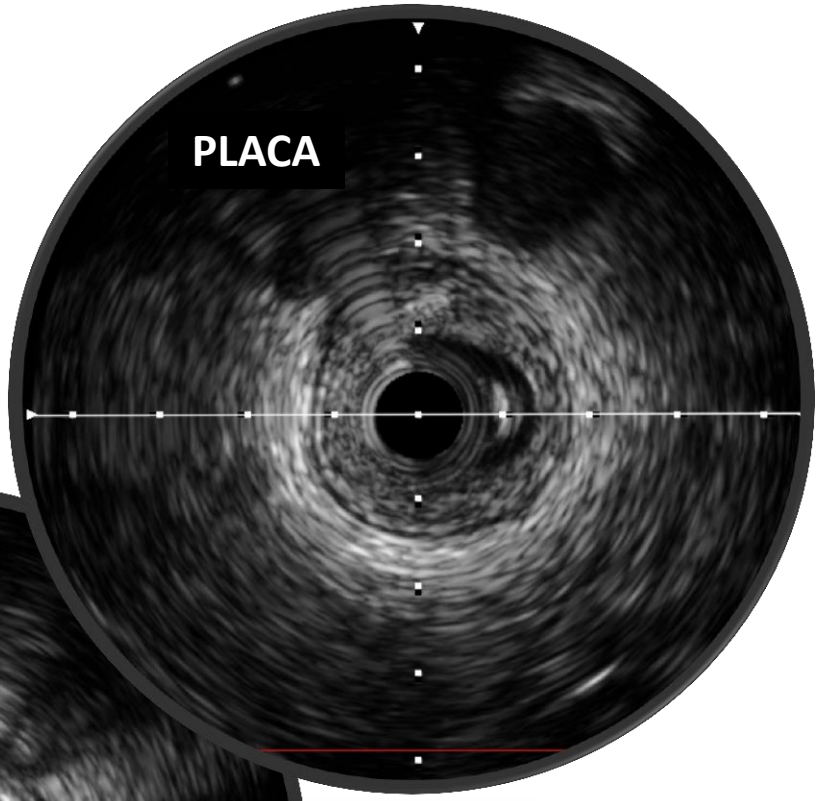

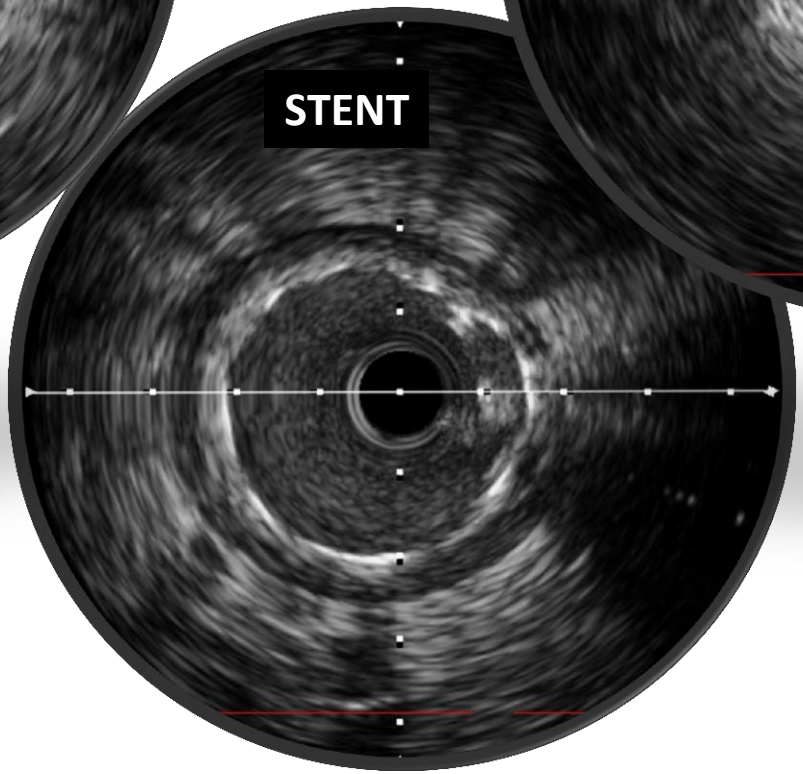

Interpretación de los SCA SST con CCG normal??!!

Año 1999!!!

Paciente de 34 años, hombre.
FRC: tabaquista y antecedentes familiares.

-INGRESA POR: IAM anterior en Killip A.
Tratado con tPA IV, criterios (+) de reperfusión.

-PREVIO AL ALTA: CCG: arterias sin lesiones significativas. TM: ß-bloqueantes, enalapril y aas.

-EVOLUCIÓN: Asintomático 20 días.

-REINTERNACIÓN: Por angina. ACO con heparina 72 hs.

-PLAN: nueva Coronariografía.

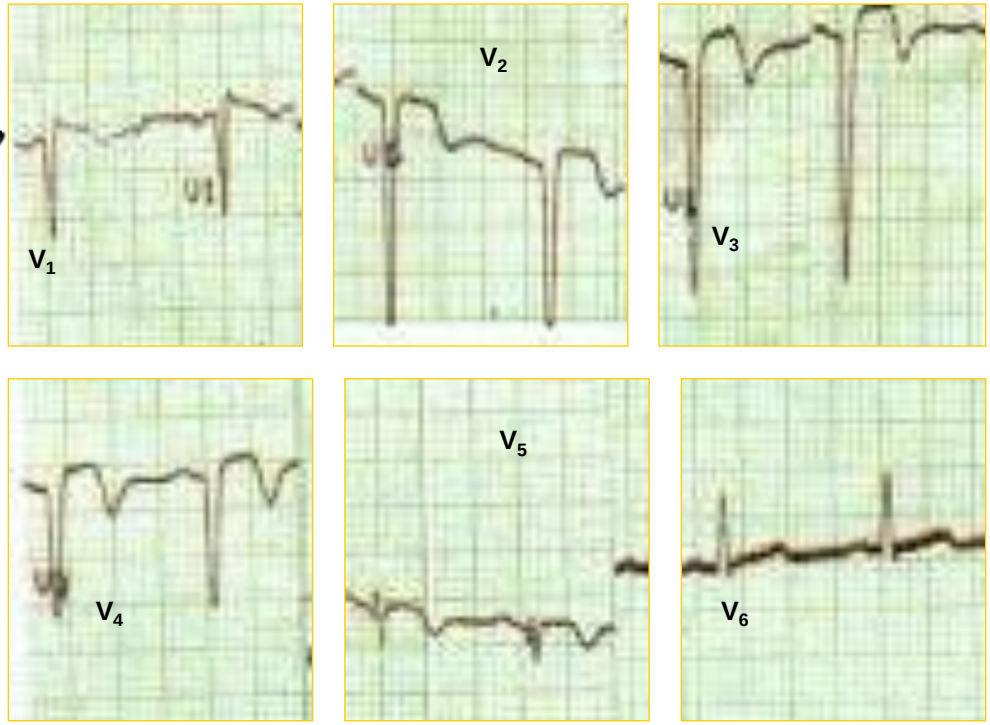

Interpretación de los SCA SST con CCG normal??!!

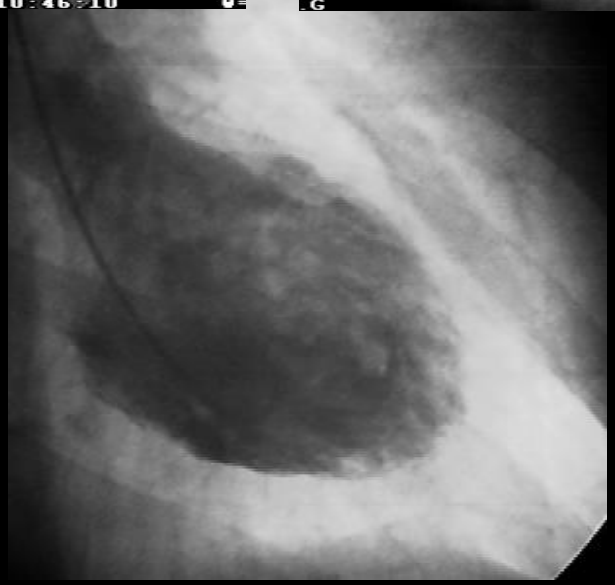

Interpretación de los SCA SST con CCG normal??!!

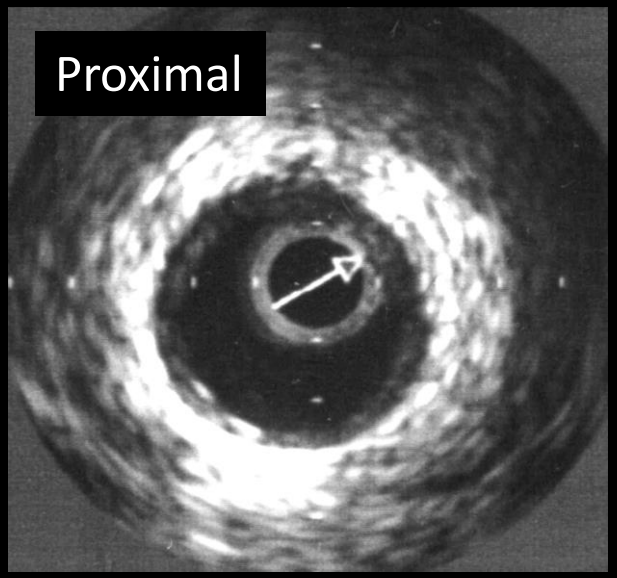

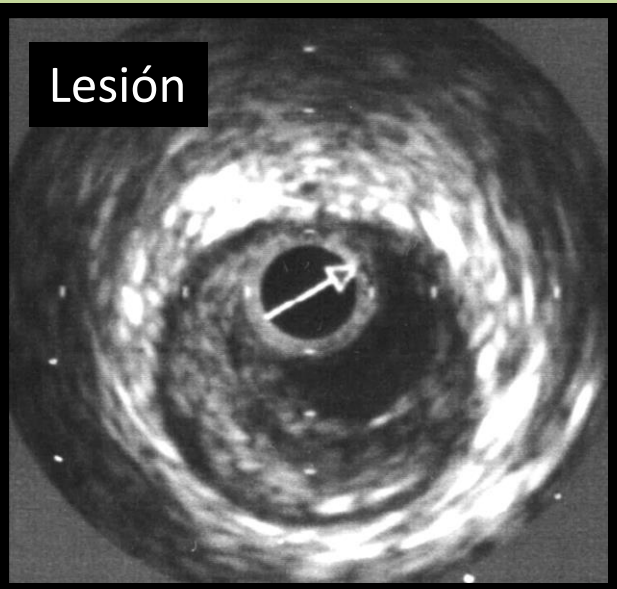

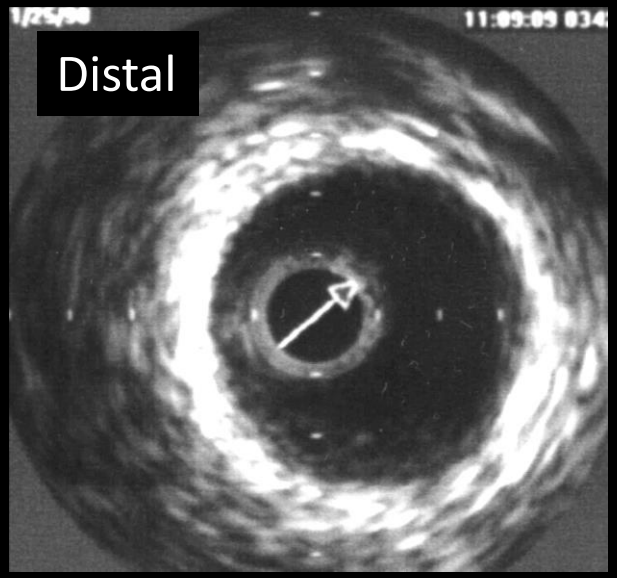

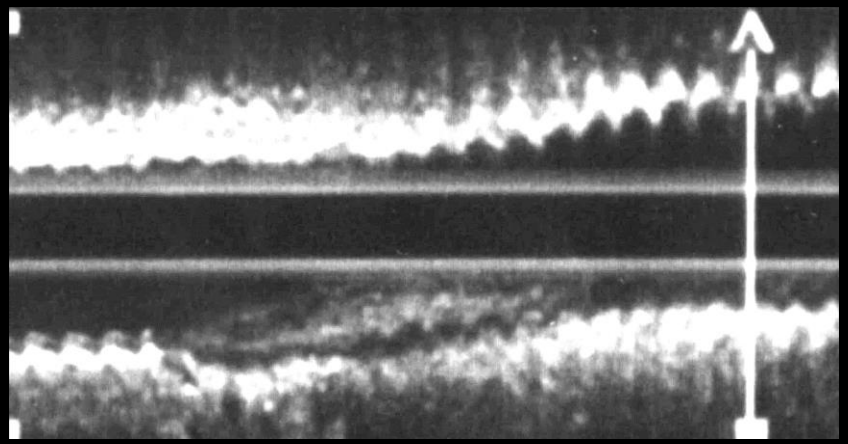

Visentín M, Telayna J, Desabato I, Lanzotti R, Cigalini C. XVIII Congreso Nacional de Cardiología.
VI Meeting of the International Society for Heart Research. Latin American Section. FAC. 1999.

HOSPITAL UNIVERSITARIO AUSTRAL

Interpretación de los SCA NSST con CCG normal??!!

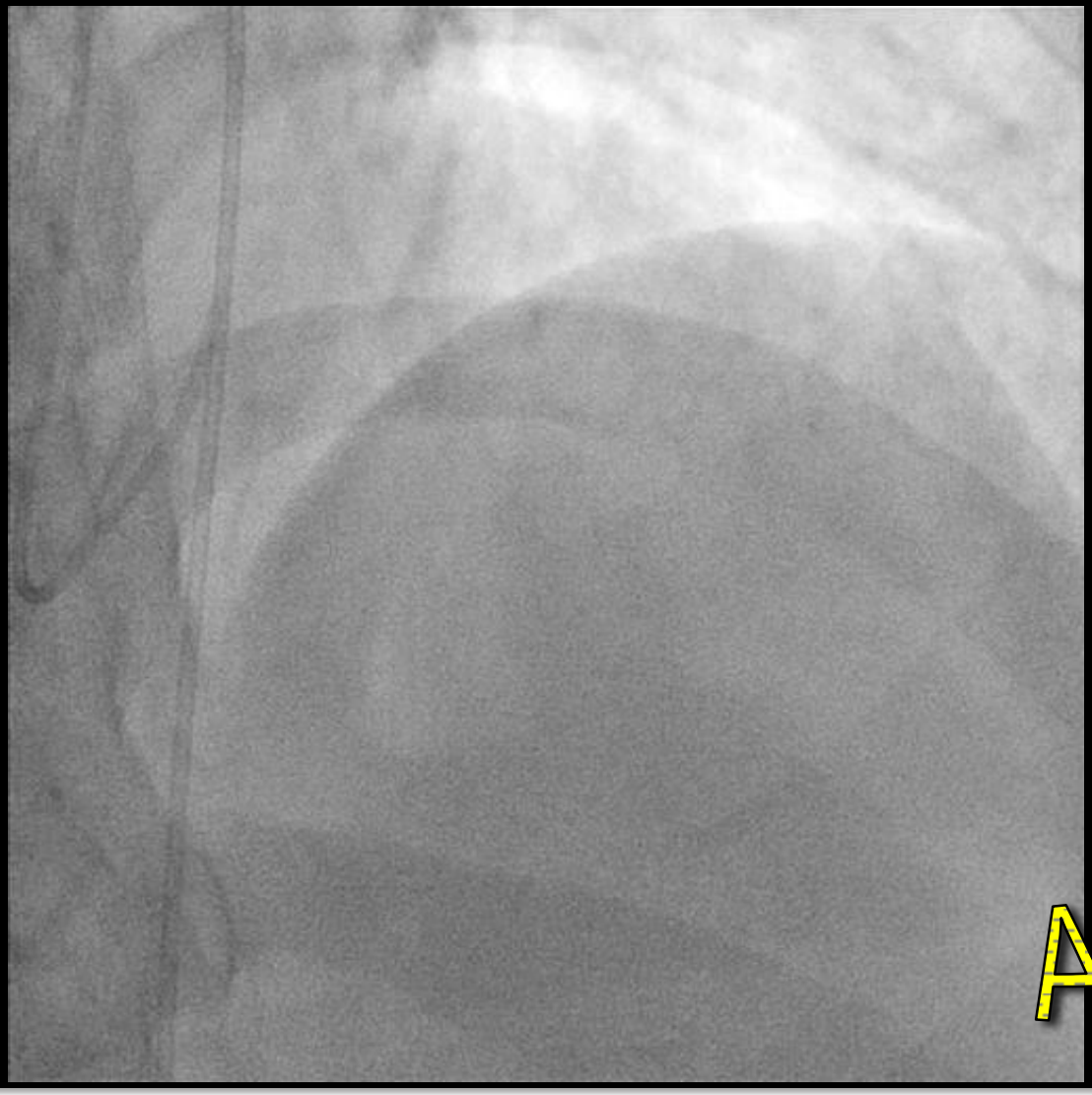

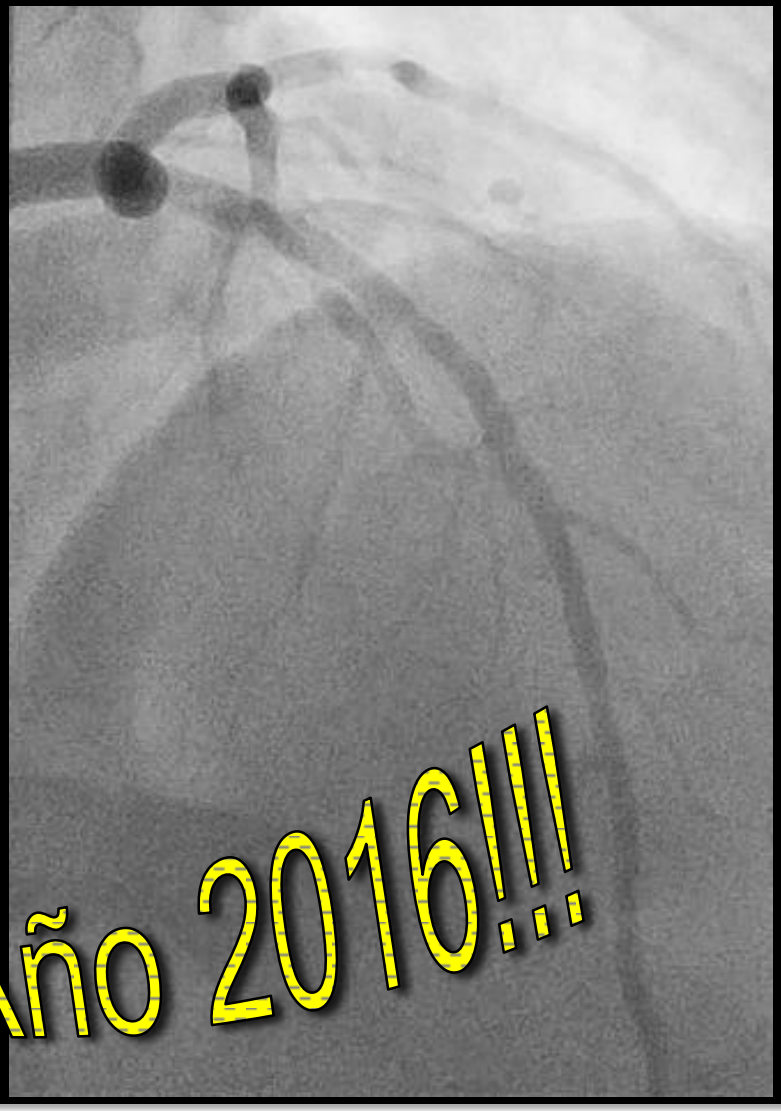

Interpretación de los SCA NSST con CCG normal??!!

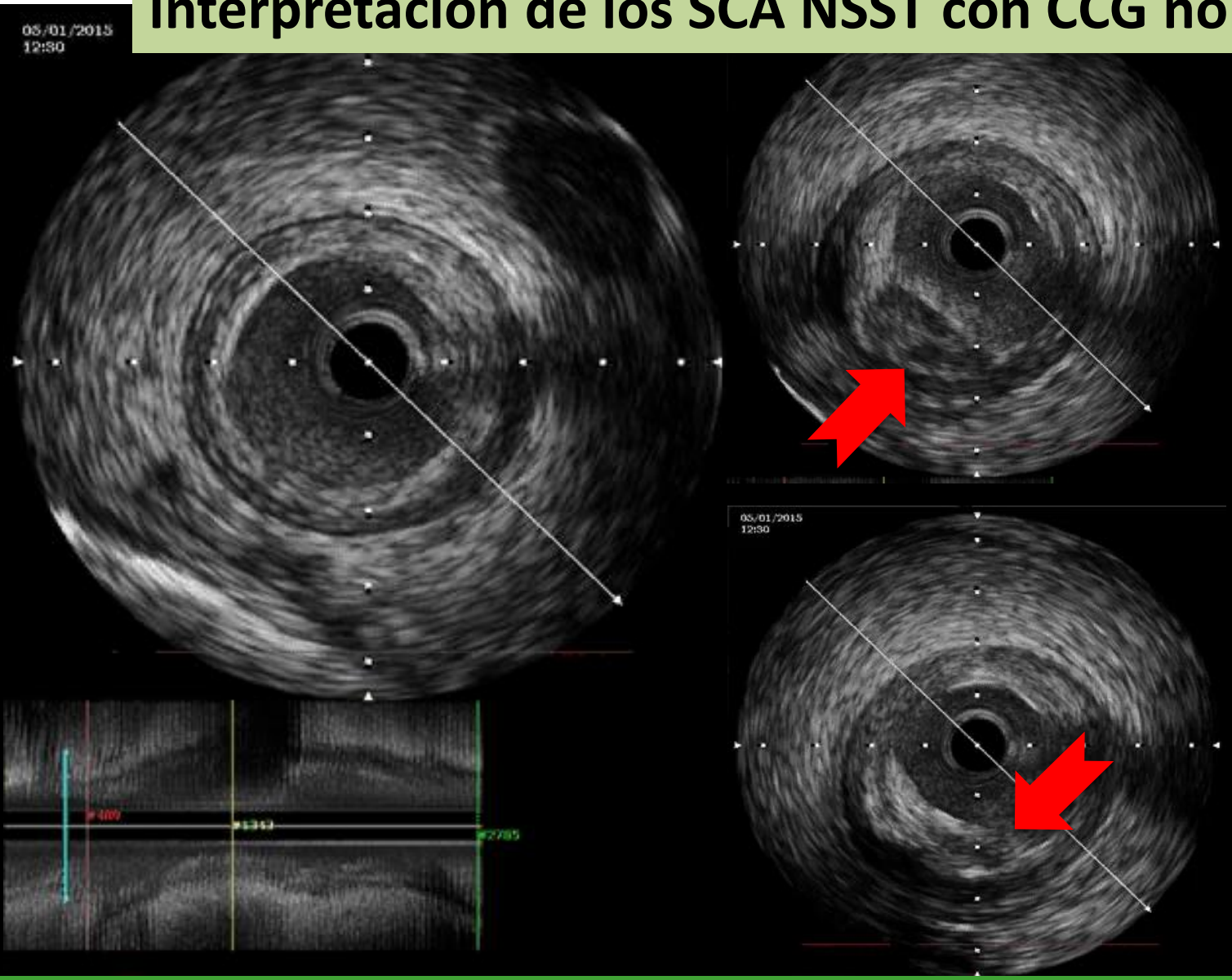

Placa fibrolipídica con gran core lipídico

Ruptura del cap (thin cap fibroatheroma)

Interpretación de los SCA NSST con CCG normal??!!

- Stent 3.5x32 a 16 atm
- Postd. 4.0 x 20 a 8 atm

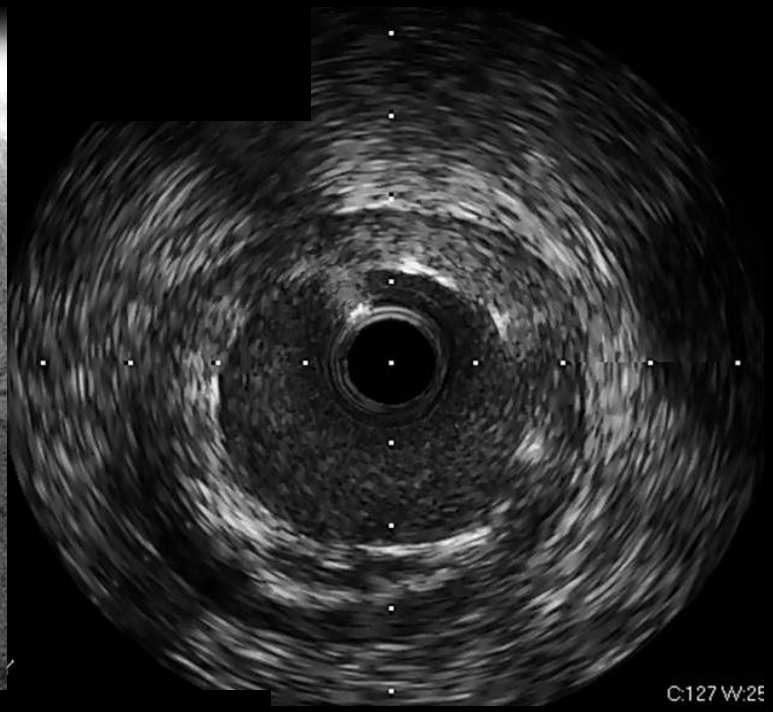

Lesiones de riesgo!!!

HOSPITAL UNIVERSITARIO AUSTRAL

La astronauta de la NASA Karen Nyberg ha tomado **imágenes del tifón Haiyan** que ha asolado a Filipinas y las ha publicado en su Facebook y en Twitter con la inscripción: "via Karen: 'Typhoon Haiyan. Taken November 9, 2013. KN from space".

Ver mejor, Ver precozmente e Intervenir a tiempo !!!

Responsables de Naciones Unidas advirtieron el viernes que **1.500.000 niños filipinos podrían sufrir desnutrición** como consecuencia del tifón que asoló el archipiélago.

HOSPITAL UNIVERSITARIO AUSTRAL

Tronco de Coronaria Izquierda

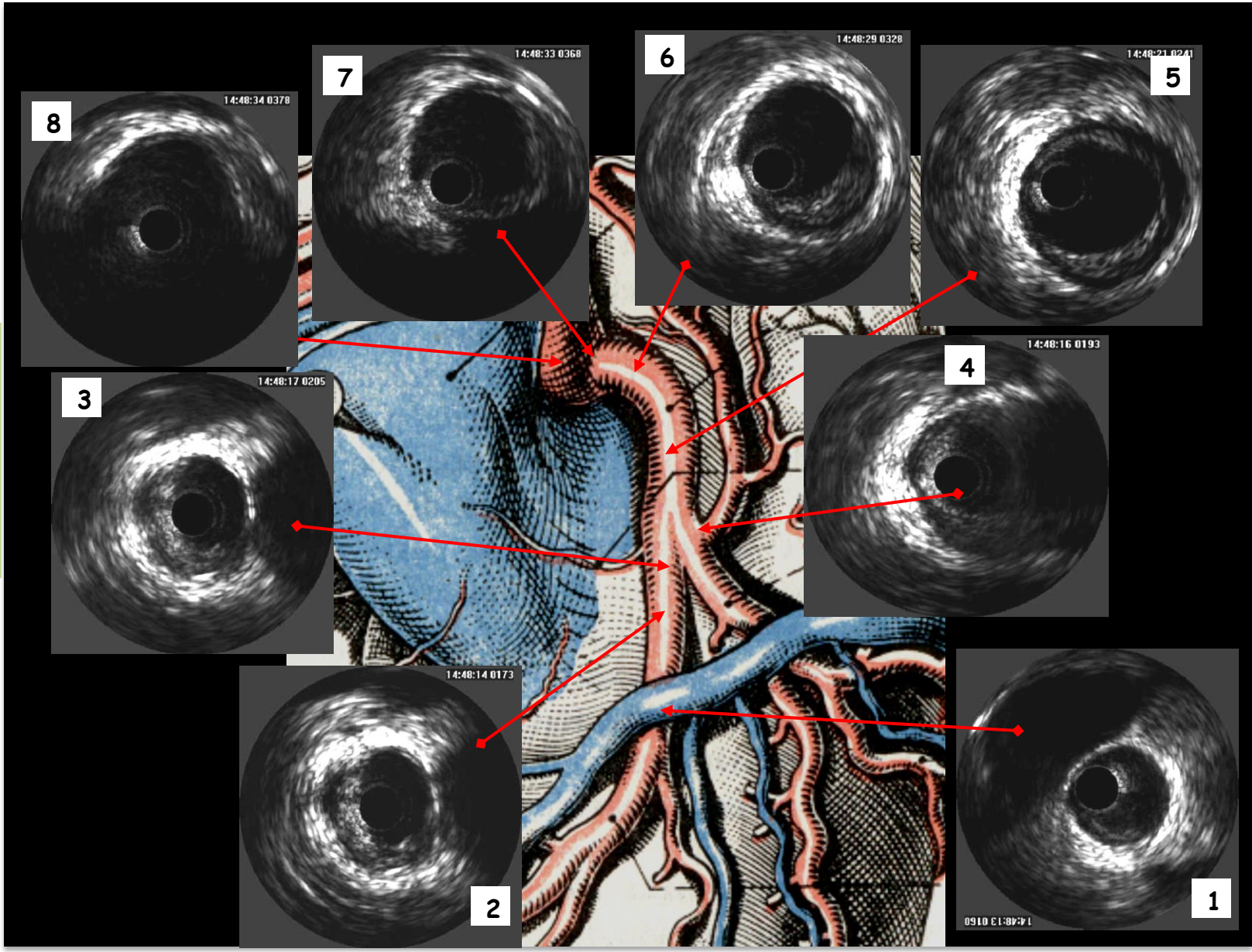

Tronco de Coronaria Izquierda: la evaluación de la bifuración con angiografía es desafiante

- Frecuente presencia de aterosclerosis (89%) con angio[1]
- Pobre correlación entre QCA e IVUS [1-2]
- Enfermedad difusa, no hay SR (cuerpo corto)
- Opacificación del seno coronario, angulación ostial
- Bifurcación DA-Cx – Tr distal, angio complejo
- Defectos intraluminales?
- Asociación con otras lesiones – isquemia?[3]
- Variabilidad intra – interobservador aumentada[4-5]

[1] Hermiller et al. Am J Card 1993;71:173-6
[2] Abizaid et al. Am J Cardiol 1999;34:707-15
[3] El-Menyar et al. Curr Probl Cardiol 2007;32:103-93
[4] Cameron et al. Circulation 1983:68:484-9
[5] Fisher et al. Catheter Cardiovasc Diagn 1982;8:565-75
[6] Ricciardi et al. Am Heart J 2003;146:507-12

El IVUS supera estas limitaciones angiográficas

Tronco de Coronaria Izquierda: análisis de las bifurciones y volumen de placa

Evaluación de la DA "desde la Cx"			Evaluación de la Cx "desde la DA"		
	Sensibilidad	**Especificidad**		**Sensibilidad**	**especificidad**
PB > 40%	59%	45%	**PB > 40%**	67%	55%
PB > 70%	78%	42%	**PB > 70%**	88%	42%

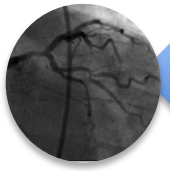

Si queremos cuantificar el volumen de placa debemos obtener las imagenes desde las ramas directamente

Oviedo et al. Am J Cardiol 2010;105:948-54

Tronco de Coronaria Izquierda: área luminal con dos stents

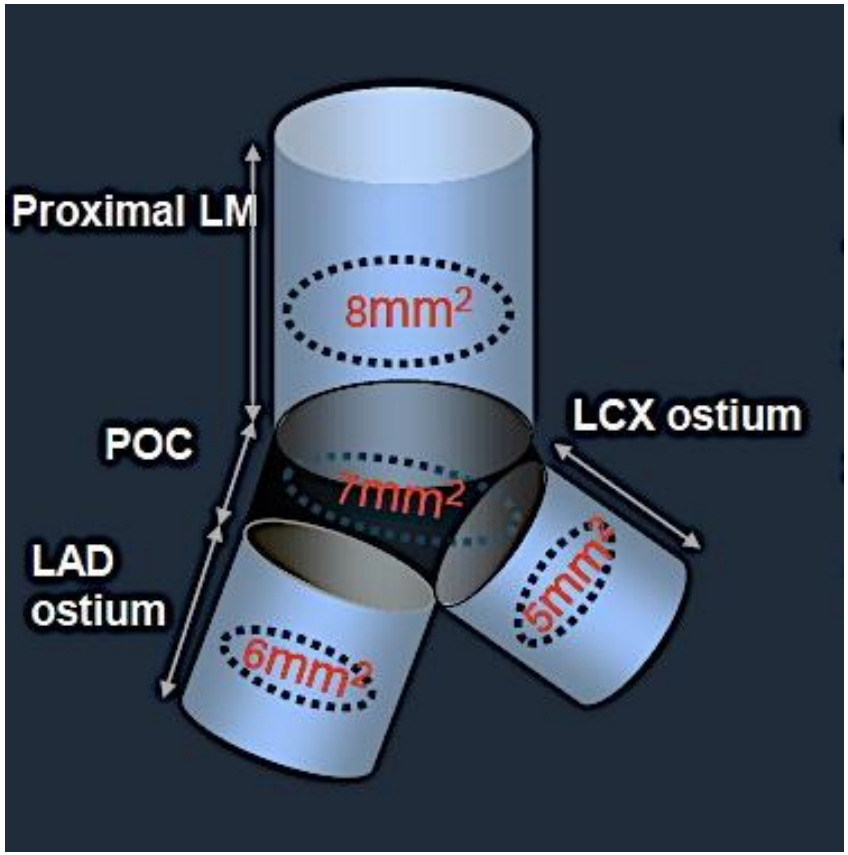

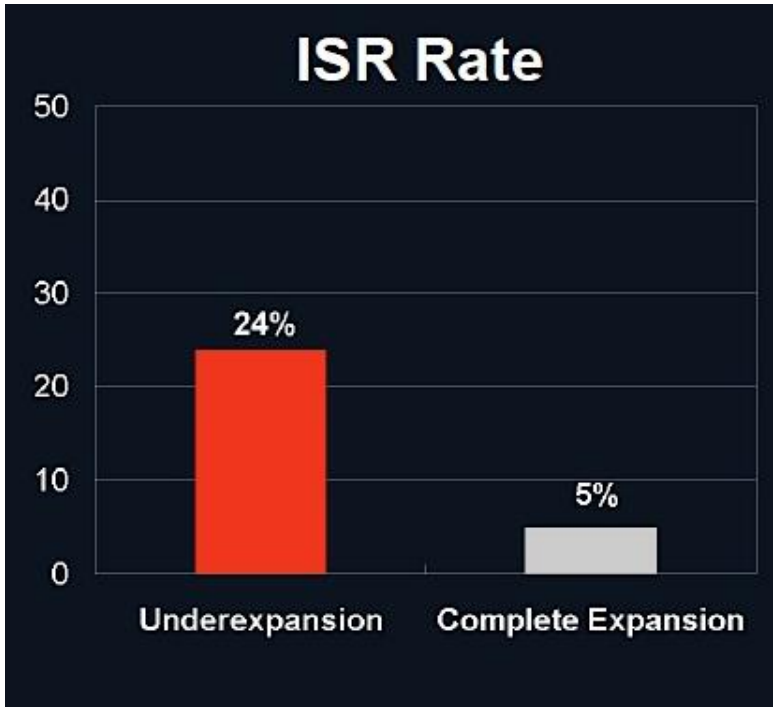

Kang et al. Circ Cardiovasc Inter 2011;4:11168-74

Tronco de Coronaria Izquierda: "la última frontera de la Angioplastia Coronaria"

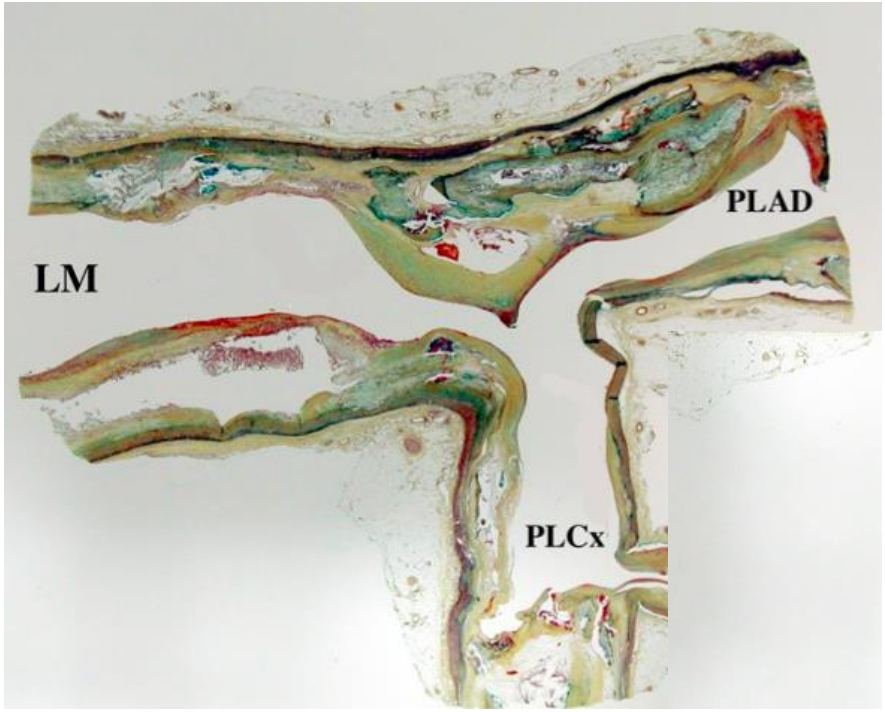

Lesiones complejas!!!

Cómo se mejora? – Diámetro del vaso

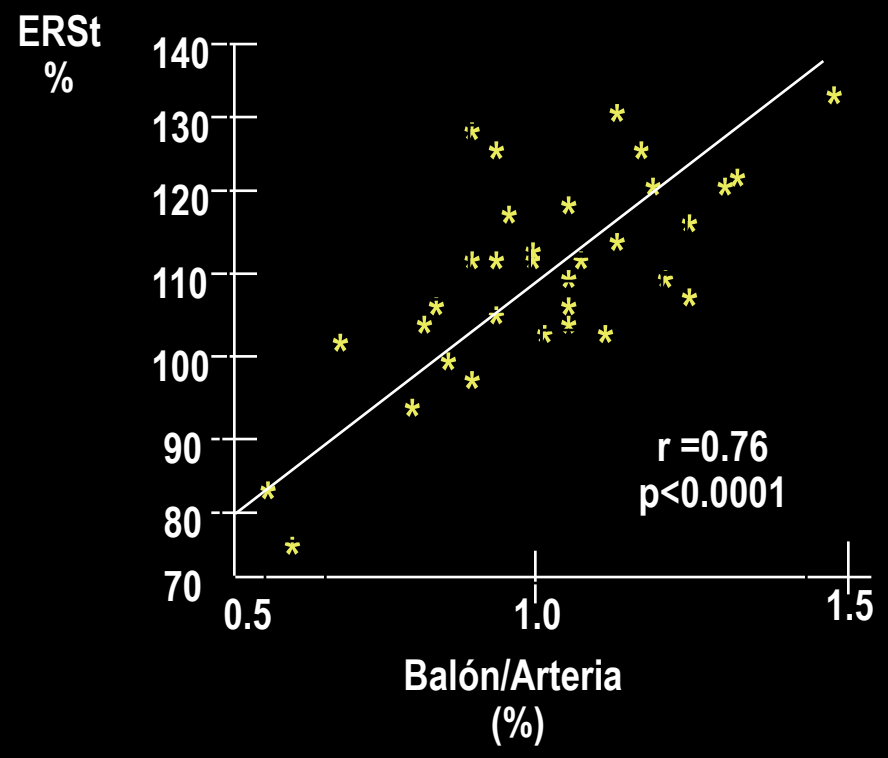

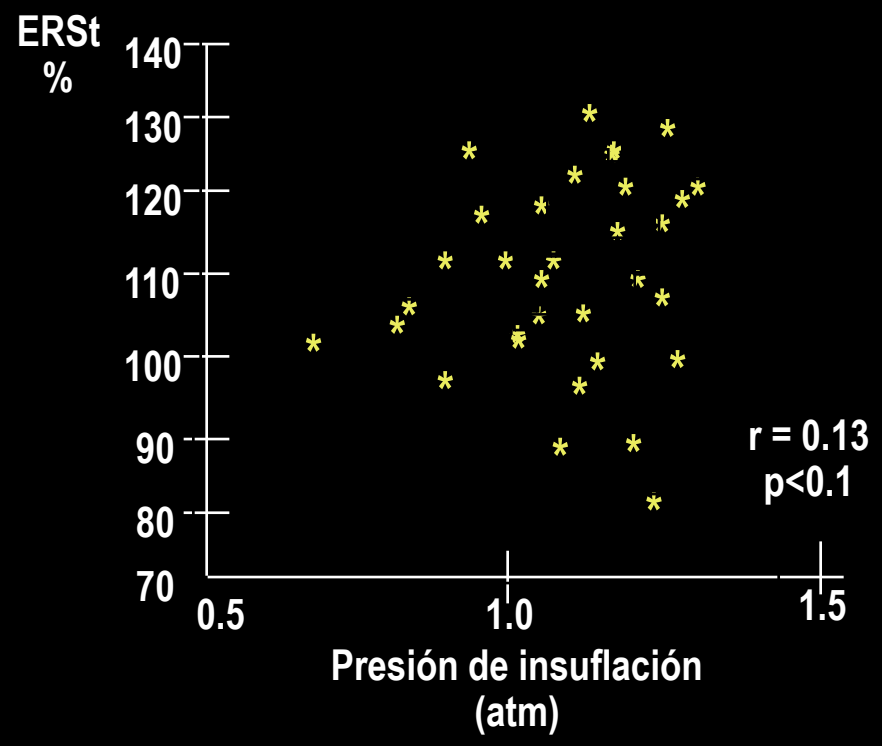

- ***Población:*** 32 pacientes, 33 stent.
- ***Presión media de insuflación:*** 14.7±0.6 atm.
- ***Balón/arteria:*** 1.03±0.02mm

K. Fujise, Houston Health Science Center. ACC 1997

Cómo se mejora la expansión y aposición de los stents

4.0 mm a 10 atm

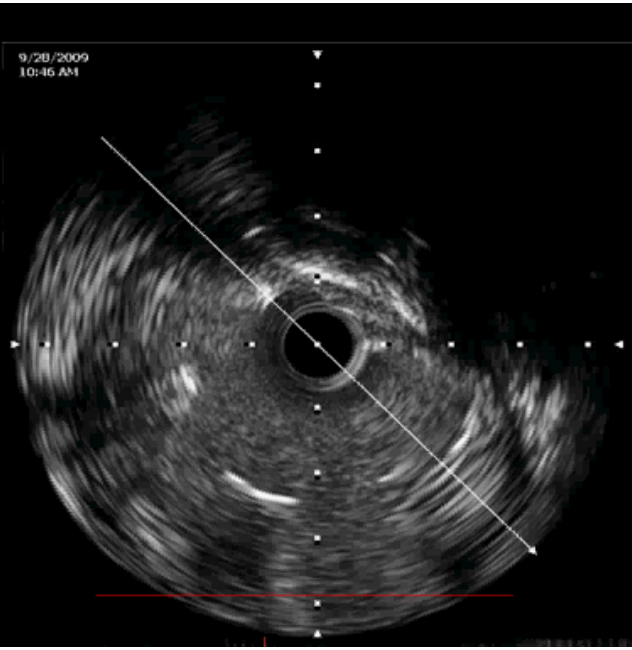

4.0 mm a 14 atm

4.5 mm a 12 atm

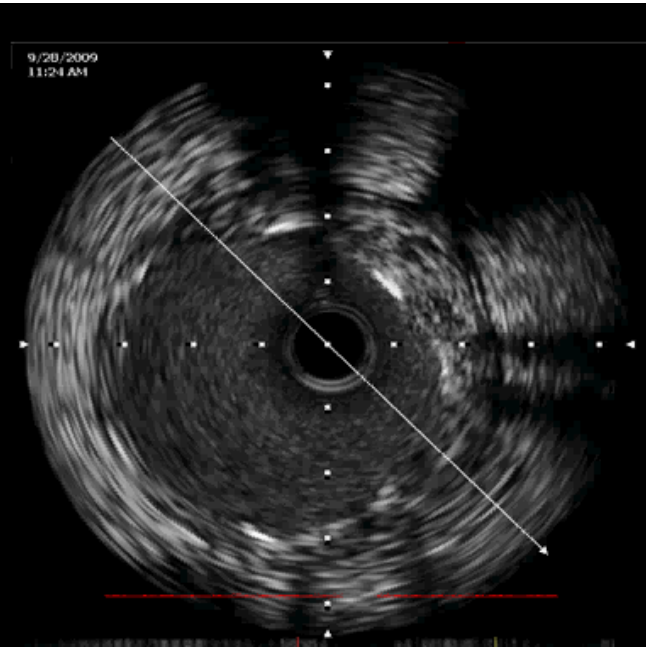

HOSPITAL UNIVERSITARIO AUSTRAL

Intravascular Ultrasound Guidance Is Associated With Better Outcome in Patients Undergoing Unprotected Left Main Coronary Artery Stenting Compared With Angiography Guidance Alone

Pontus Andell, Sofia Karlsson, Moman A. Mohammad, Matthias Götberg, Stefan James, Jens Jensen, Ole Fröbert, Oskar Angerås, Johan Nilsson, Elmir Omerovic, Bo Lagerqvist, Jonas Persson, Sasha Koul, David Erlinge

https://doi.org/10.1161/CIRCINTERVENTIONS.116.004813
Circulation: Cardiovascular Interventions. 2017;10:e004813
Originally published May 9, 2017

Conclusions—IVUS was associated with an independent and significant outcome benefit when performing unprotected LMCA PCI. Potential mediators of this benefit include **larger and more appropriately sized stents**, perhaps translating into lower risk of subsequent stent thrombosis. Although residual confounding cannot be ruled out, our findings indicate a possible hazard when performing unprotected LMCA PCI without IVUS guidance.

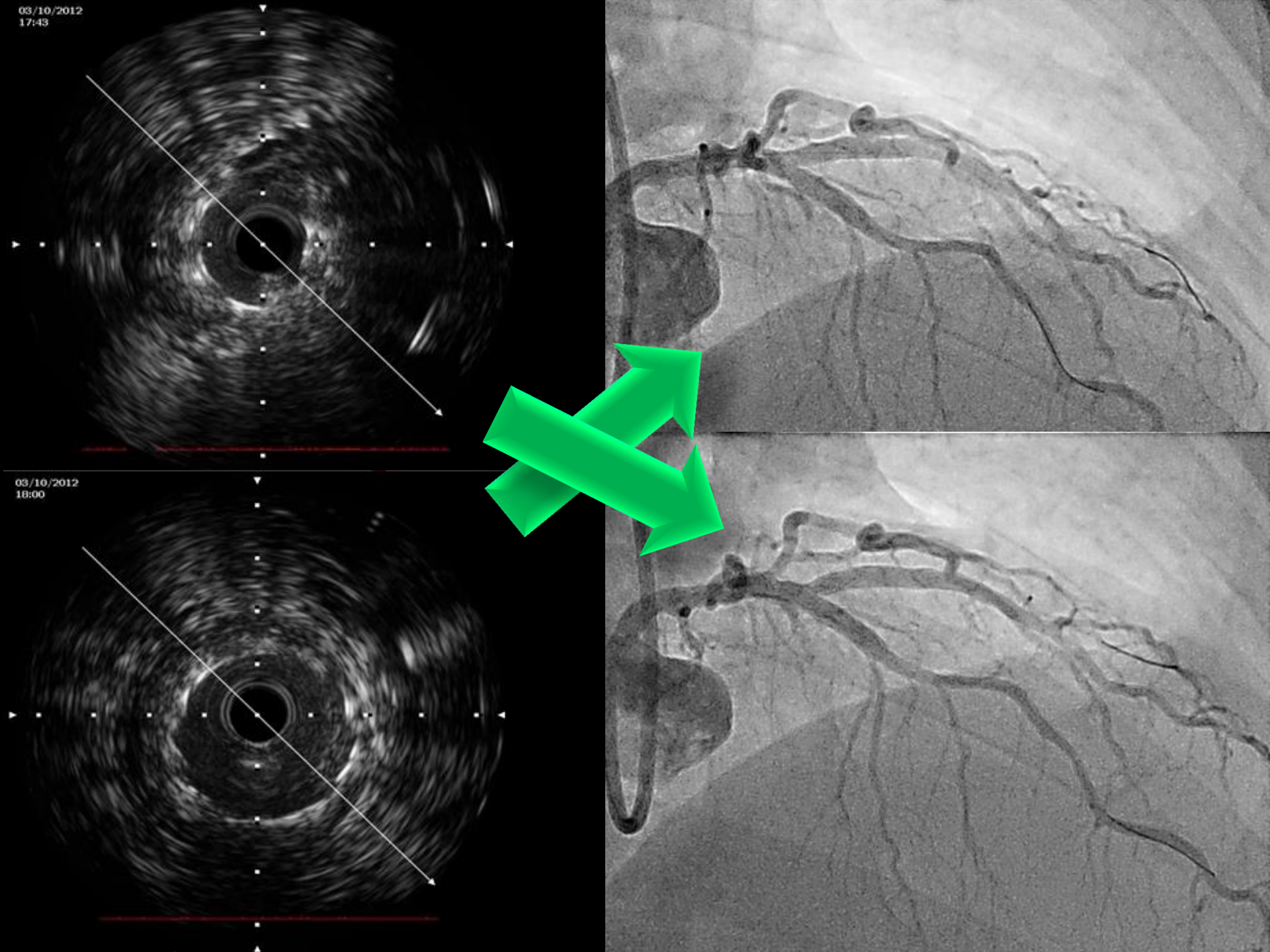
03/10/2012
17:43
03/10/2012
18:00

Prolapso de placa: impacto clínico

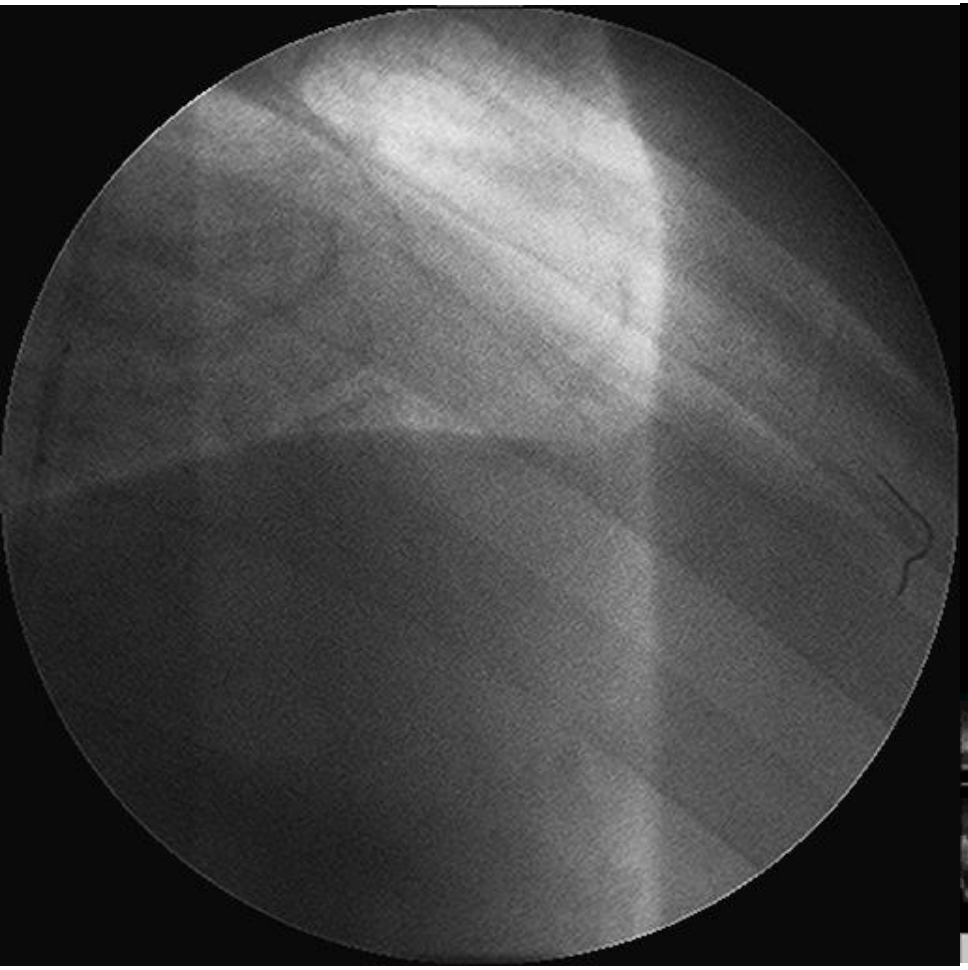

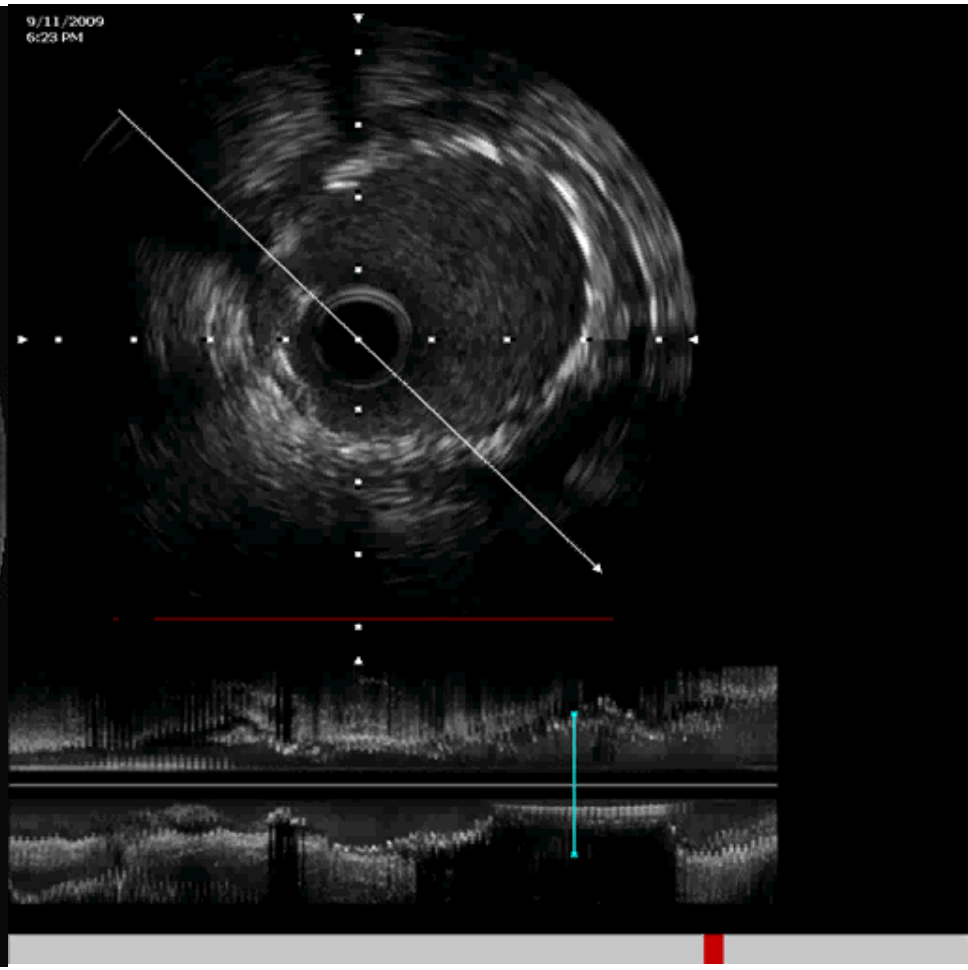

Prolapso de placa

Clinical Impact of Suboptimal Stenting and Residual Intrastent Plaque/Thrombus Protrusion in Patients With Acute Coronary Syndrome

The CLI-OPCI ACS Substudy (Centro per la Lotta Contro L'Infarto-Optimization of Percutaneous Coronary Intervention in Acute Coronary Syndrome)

Francesco Prati, MD; Enrico Romagnoli, MD, PhD; Laura Gatto, MD; Alessio La Manna, MD; Francesco Burzotta, MD, PhD; Ugo Limbruno, MD; Francesco Versaci, MD; Franco Fabbiocchi, MD; Alessandro Di Giorgio, MD; Valeria Marco, RT; Vito Ramazzotti, MD; Luca Di Vito, MD; Carlo Trani, MD; Italo Porto, MD, PhD; Alberto Boi, MD; Luigi Tavazzi, MD; Gary S. Mintz, MD

Conclusions—In this retrospective study of acute coronary syndrome patients undergoing percutaneous coronary intervention, a composite of OCT-defined suboptimal stent implantation characteristics at the culprit lesion and residual intrastent plaque/thrombus protrusion was associated with adverse outcome. (*Circ Cardiovasc Interv*. 2016;9:e003726. DOI: 10.1161/CIRCINTERVENTIONS.115.003726.)

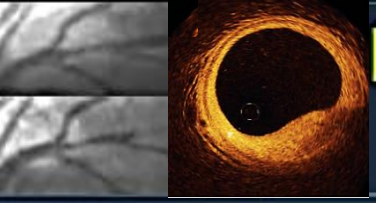

PROSPECT: VH-TCFA and Non-Culprit Lesion Related Events

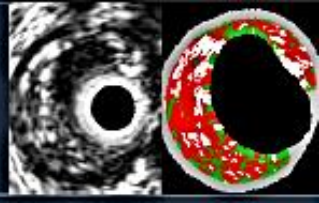

Median 3 .4 Yr MACE Rate per lsn (%)

20
15
10
5
0

Present
Absent

	TCFA	TCFA + MLA ≤4.0mm2	TCFA + PB ≥70%	TCFA + PB ≥70% + MLA ≤4mm2
Present	4.9	10.2	16.4	18.2
Absent	1.3	1.7	1.7	1.9
	CÁPSULA	EROSION	FISURA DE PLACA	MACRÓFAGOS
Lesion HR	3.90 (2.25, 6.76)	6.55 (3.43, 12.51)	10.83 (5.55, 21.10)	11.05 (4.39, 27.82)
P value	<0.0001	<0.0001	<0.0001	<0.0001
Prevalence*	46.7%	15.9%	10.1%	4.2%

*Likelihood of one or more such lesions being present per patient. PB = plaque burden at the MLA

HOSPITAL UNIVERSITARIO
AUSTRAL

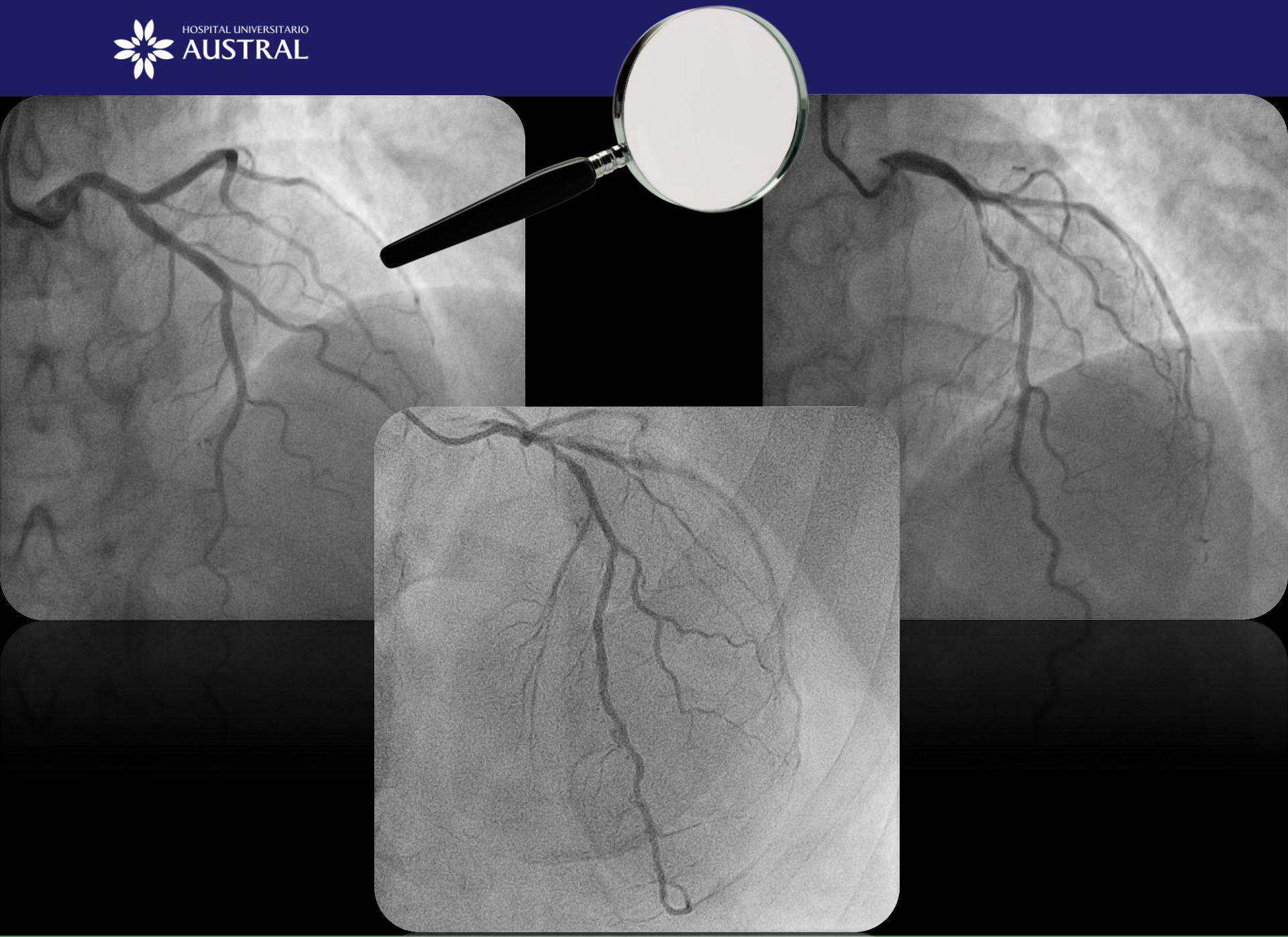

RESUMEN

- Diagnóstico
- Tipo de placa
- Mediciones
- Interpretación de SCA con CCG normal
- Interpretación de SCA con discordancia con los estudios complementarios
- Lesiones de riesgo
- Lesiones complejas
- Estudio más moderno de historia natural de la Enfermedad Coronaria
- CCG normal, sin lesiones, sin lesiones significativas: con enfermedad coronario o sin enfermedad coronaria!!

jtelayna@cas.austral.edu.ar

INFERENCIAS

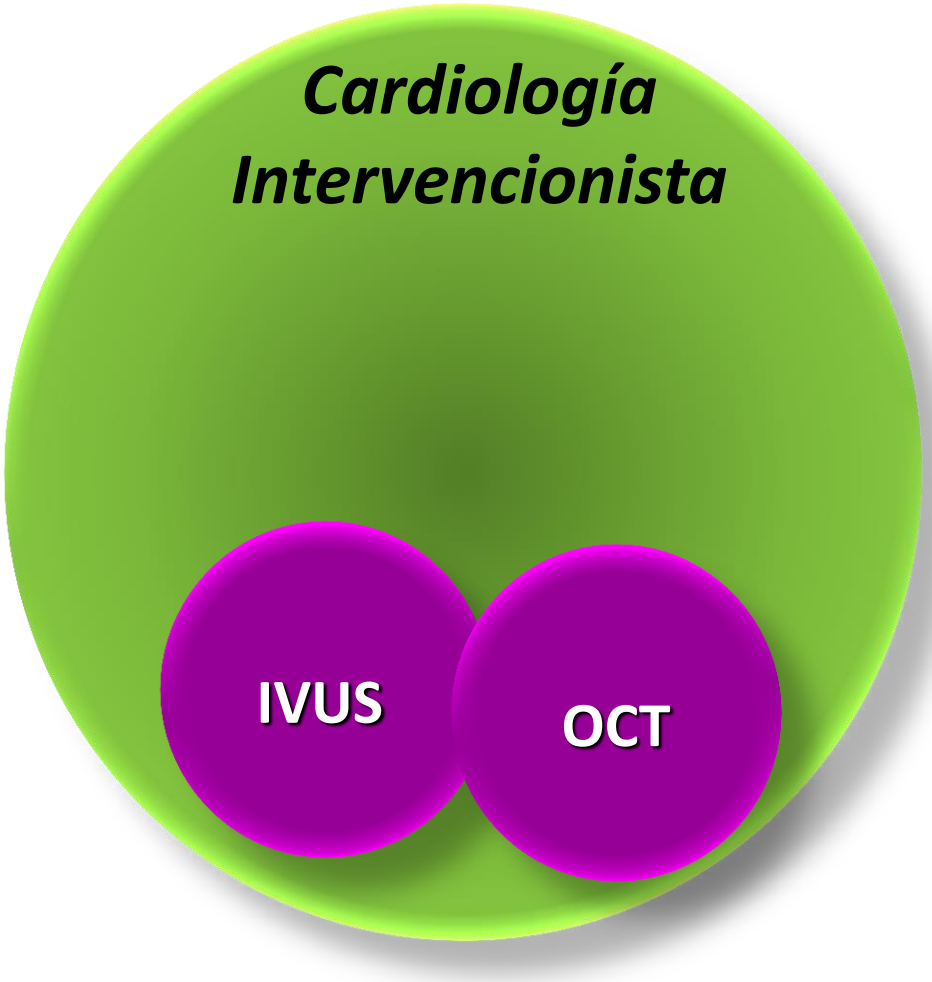

Muchas gracias!!!