euro PCR 2012 YEAR OF THE TEXTBOOK

SOLACI

"SOLACI@EuroPCR"

Interventional Treatment for Structural heart disease in Latin-America

"Left Atrial Appendage Closure LATAM Registry"

Dr. Aníbal Damonte
Department of Interventional Cardiology
Instituto Cardiovascular de Rosario
Rosario, Argentina

PCR EAPCI EUROPEAN SOCIETY OF CARDIOLOGY® EACTS

euro PCR 2012

"Percutaneous Closure of the LAA with the Amplatzer Cardiac Plug: Initial Experience in Latin America"

Coauthors and Participating Hospitals

- Dr. C Costantini, Hospital Cardiológico Costantini, Curitiba, Brasil
- Dr. M Montenegro, Dr. E Quintella, Instituto Estadual de Cardiología, Río de Janeiro, Brasil
- Dr. C Pedra, Dra. L Armaganijan; Instituto Dante Pazzanese, San Pablo, Brasil
- Dr. Alejandro Martinez, Universidad Católica de Chile, Santiago, Chile
- Dr. Fabio Brito, Dr. M Perin, Hospital Albert Einstein, San Pablo, Brasil
- Dr. José Condado, Hospital Perez Carreño, Caracas, Venezuela
- Dr. Daniel Aguirre, Clínica Alemana, Santiago, Chile
- Dr. Horacio Faella, Dr. Germán Henestrosa, Instituto FLENI, Buenos Aires, Argentina
- Dr. León Valdivieso, Dr. Oscar Mendiz, Fundación Favaloro, Buenos Aires, Argentina
- Dr. C Pincetti, Dr. L Romero, Hospital Regional de Temuco, Chile
- Dr. C Deck, Dr. Polentzi Uriarte, Instituto Clínico del torax, Santiago, Chile
- Dr. Miguel Ballarino, Dr. Alejandro Peirone, Hospital Privado, Córdoba, Argentina
- Dr. Alejandro Fernandez, Dr. Daniel Berrocal, Hospital Italiano, Buenos Aires, Argentina
- Dr. Fernando Cura, Dr. Sebastian Peralta, Instituto Cardiovascular de Buenos Aires, Argentina
- Dr. Alejandro Palacios, Dr. Juan Arellano, Sanatorio de la Trinidad, Buenos Aires, Argentina
- Dr. R LLuberas, Dr. Alvaro Rivara, Hospital de Clínicas, Montevideo, Uruguay
- Dr. Aníbal Damonte, Dr. Eduardo Picabea, Instituto Cardiovascular de Rosario, Argentina.

Background

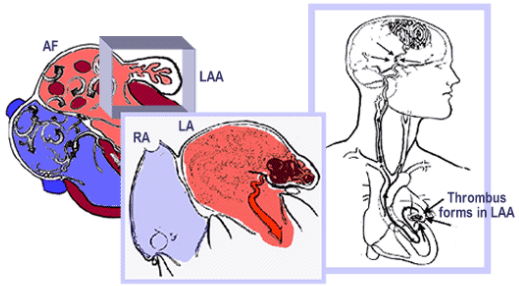

- Atrial fibrillation (AF) is the most common cardiac arrhytmia and a major cause of morbidity and mortality secondary to cardioembolic stroke.

- In patients with non valvular AF 90% of intracavitary thrombi form in the LAA.

- Percutaneous closure of the LAA has emerged as a potential alternative to anticoagulation therapy for the prevention of cerebrovascular events in patients with AF and contraindications or difficulties for oral anticoagulation.

euro PCR 2012

Objectives

- This experience describes the feasibility, in hospital and 30 days follow up results of the transcatheter closure of the LAA with the Amplatzer Cardiac Plug in an initial Latin American experience.

euro PCR 2012

Methods

- Physician initiated, voluntary, retrospective registry, including 54 consecutive patients with AF at high risk for cardioembolic stroke, from different Latin American hospitals that were treated with the ACP from August 2009 to April 2012.

- The procedures were performed under general anesthesya, transesophageal ecocardiography (TEE), fluroscopic and angiographic guidance.

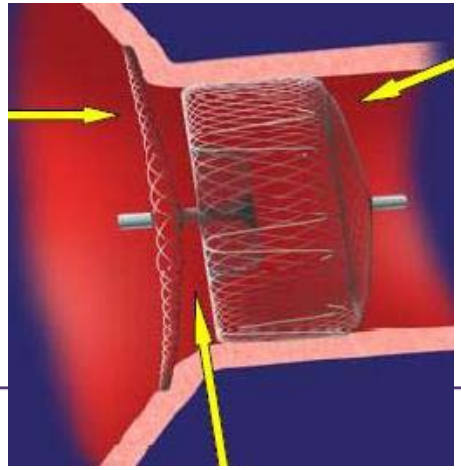

"Left Atrial Appendage Closure LATAM Registry"

N=54 April 2012

Procedures / Country

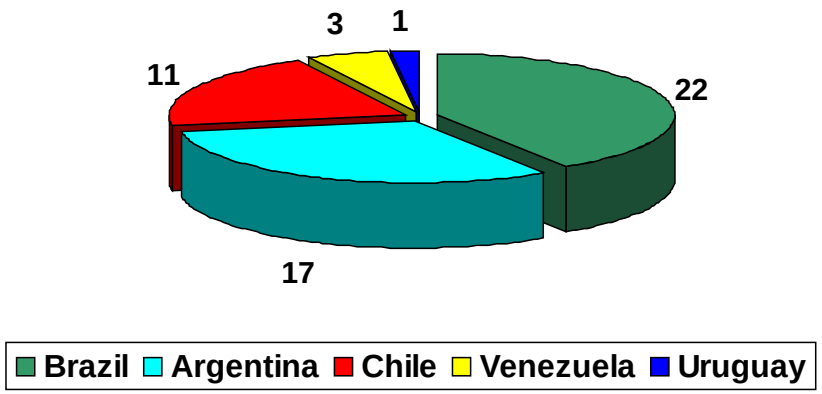

Insert references here

Methods - Device

- The ACP is a self expandable nitinol mesh device specifically designed for the transcatheter closure of the LAA.
- It consists of a lobe with stabilizing wires to assure retention and a disc connected by a central waist.

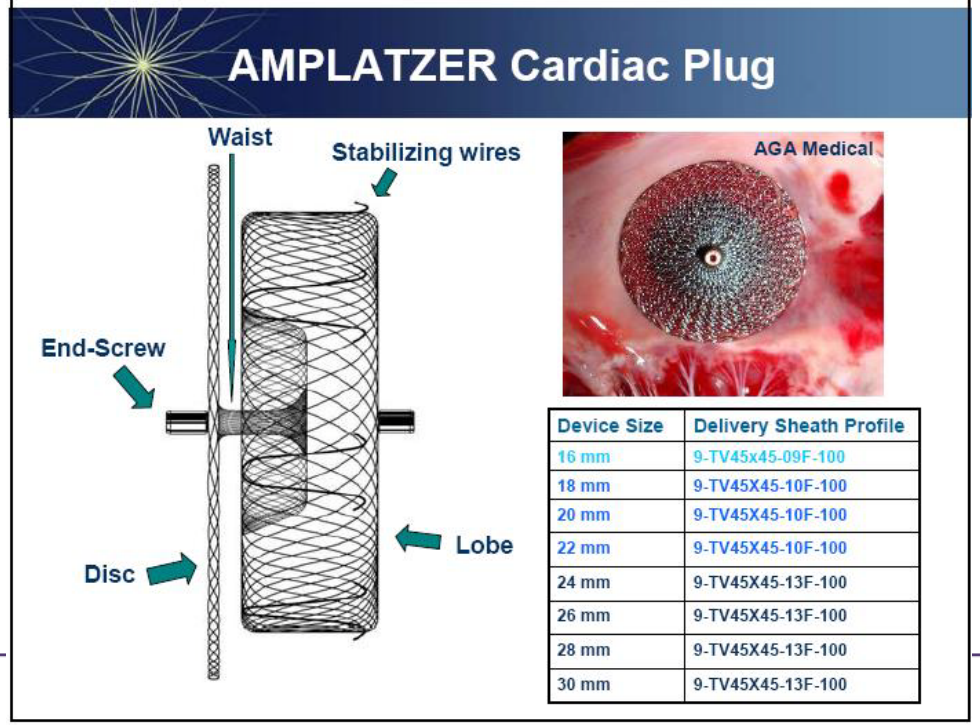

Device Size	Delivery Sheath Profile
16 mm	9-TV45x45-09F-100
18 mm	9-TV45X45-10F-100
20 mm	9-TV45X45-10F-100
22 mm	9-TV45X45-10F-100
24 mm	9-TV45X45-13F-100
26 mm	9-TV45X45-13F-100
28 mm	9-TV45X45-13F-100
30 mm	9-TV45X45-13F-100

LAA Measurements (Angio and TEE)

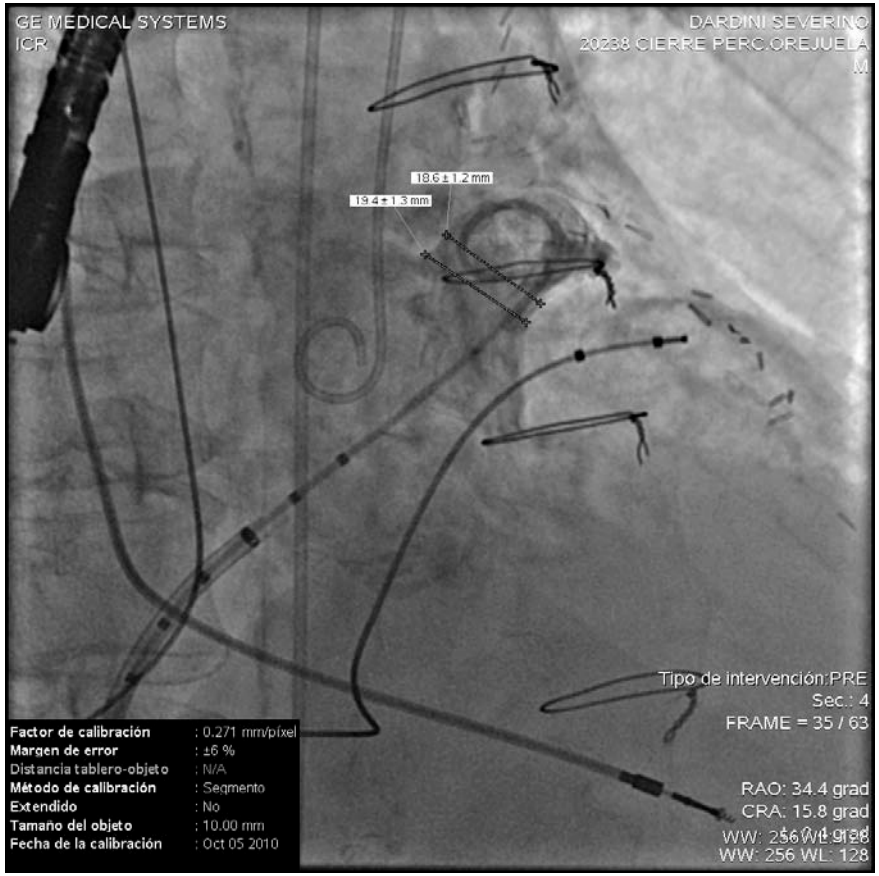

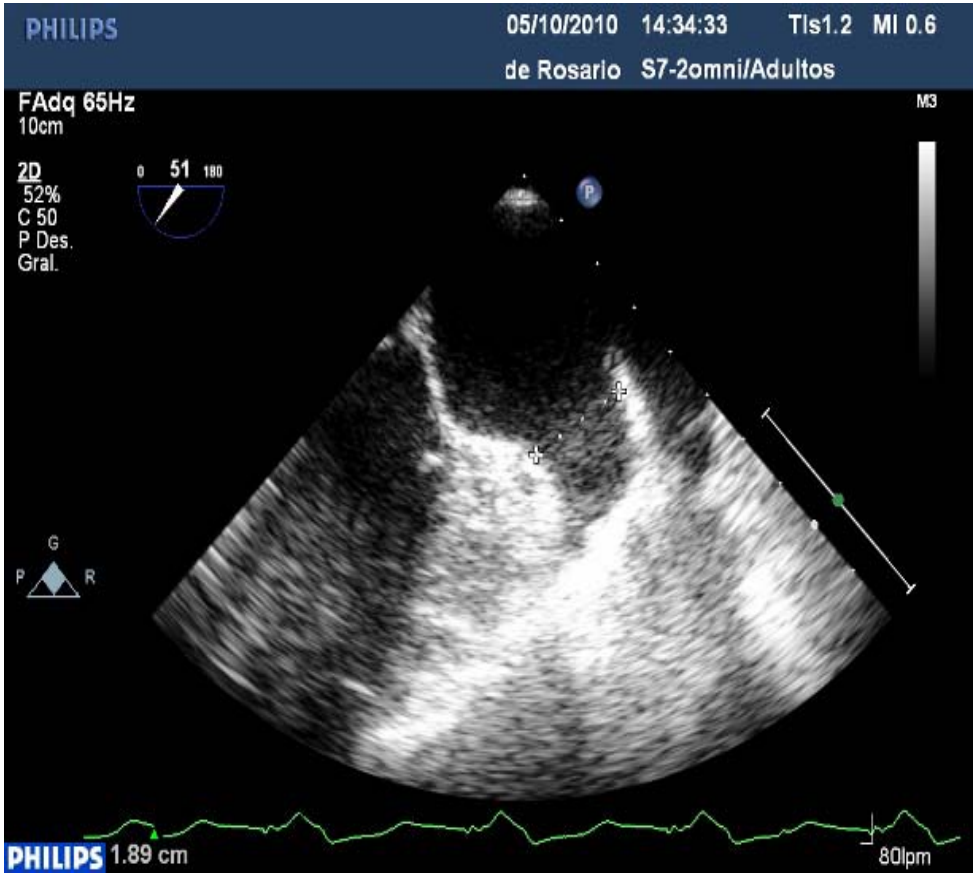

euro PCR 2012

Results

• Age	72 ± 8,7
• Male	70 %
• HTA	78 %
• DBT	17 %
• CHF	32,17 %
• Contraindic. ACO	64,29 %
• **CHADS2 score**	3,15 ± 1,12

euro PCR 2012

Results

- LAA neck (TEE) 20,3 ± 3,8 mm
- LAA neck (Angio) 22,6 ± 3,2 mm

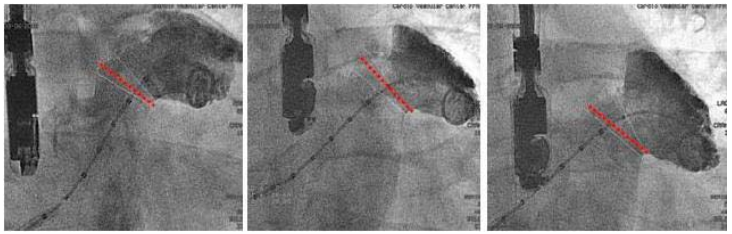

- LAA Orifice (TEE) 21,4 ± 4,3 mm
- LAA Orifice (Angio) 24,2 ± 4,6 mm
- LAA 1 lobe 38 (70%)
- LAA 2+ lobes 16 (30%)
- Trans septal 51 (94%)
- Vía PFO/ASD 3 (6%)
- Selected ACP device 25 ± 2,9 mm

In Hospital and 30d FU Results

Successfull Implant	54	(100%)
Simultaneous PFO/ASD Closure	3	(5.5%)

- In hospital Complications:

5 patients (9.2%)
1 embolization (retrieved surgically)
4 severe pericardial effussions – pericardiocentesis (7.4%)
No death, stroke or myocardial ischaemia.

- No new events reported at 30 days clinical FU.

euro PCR 2012

Results

	Protect AF[1] N= 463	Protect AF(early)[1] N=271	ACPIn.Eu.Ex[2] N= 143	ACP LatAm N= 54
Successfull implant (%)	90.9	88.2	96.4	100
Severe peric. effussion (%)	5.0	6.3	3.5	7.4
Emboliztion of device (%)	0.2	N/A	1.4	1.8
Stroke/TIA (%)	0.9	1.1	2.1	0
Major complic. (%)	7.7	10	7.0	9.2

[1]*Reddy V, et al. Circ 2011;123:417-424* [2]*Park J, et al. CCI 2011;77:701-706*

euro PCR 2012

Conclusions

- Left atrial appendage closure is a new transcatheter procedure, and a learning curve is expected.

- In this initial experience, percutaneous closure of the LAA with the ACP in patients with AF at high risk of stroke, was feasible, with a high rate of technical success and a complications rate similar to previous reports with this and other devices during the learning phase of the procedure.

- We are commited with the continous access to this registry of each patient performed in Latin America, and with their long term clinical and TEE follow up, to generate a valuable body of clinical information from our region of this new therapeutic alternative

Thank You!

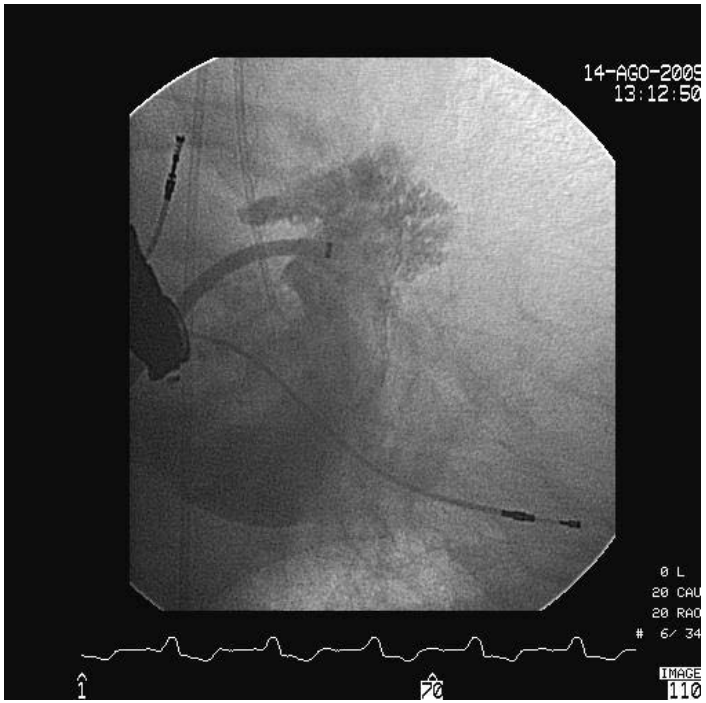
14-AGO-2005
13:12:50
0 L
20 CAU
20 RAO
6/ 34
IMAGE
110

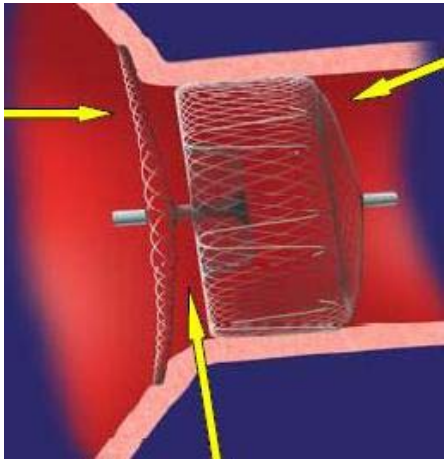

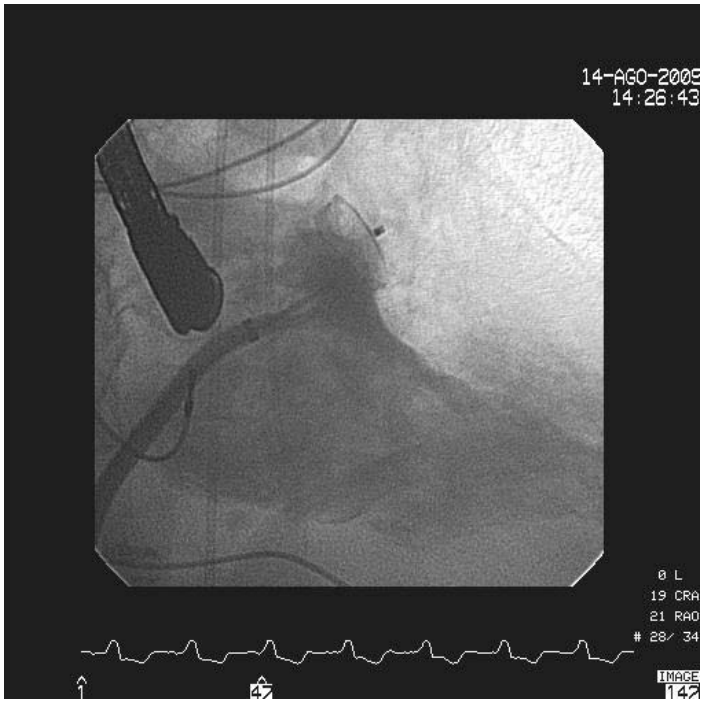
14-AGO-2005
14:26:43
0 L
19 CRA
21 RAO
28/ 34
IMAGE

euro PCR 2012

Insert references here

euro PCR 2012

Insert references here