SOLACI CACI '14
ARGENTINA
In partnership with TCT
April 23-25, 2014
Hilton Hotel, Buenos Aires

Rotablator de la Coronaria Derecha y la Circunfleja (OM1, OM3) en una intervención

Iván Darío Rendón Múnera, MD [1]; Cesar Hernández Chica, MD[2]; Diego Velásquez Meisel MD[2]; Álvaro Escobar Franco, MD [2].

[1]Fellow de Cardiología Intervencionista y Vascular Periférico. Universidad CES. Medellín, Antioquia. Colombia.
[2]Servicio de Cardiología Intervencionista y Vascular Periférico. Clínica CES, Clínica las Vegas, Hospital General de Medellín. Medellín, Antioquia. Colombia.

Historia Clínica

- Masculino, 70 años
- Paciente con antecedentes de *bypass* coronario hace 10 años, con prueba de esfuerzo (Eco stress-dobutamina) realizada 3 meses antes que reporta acinesia anterior (sin viabilidad) con isquemia en pared lateral e inferior (FE: 35%); Ingresa a la institución con choque cardiogénico (frío / Humedo).

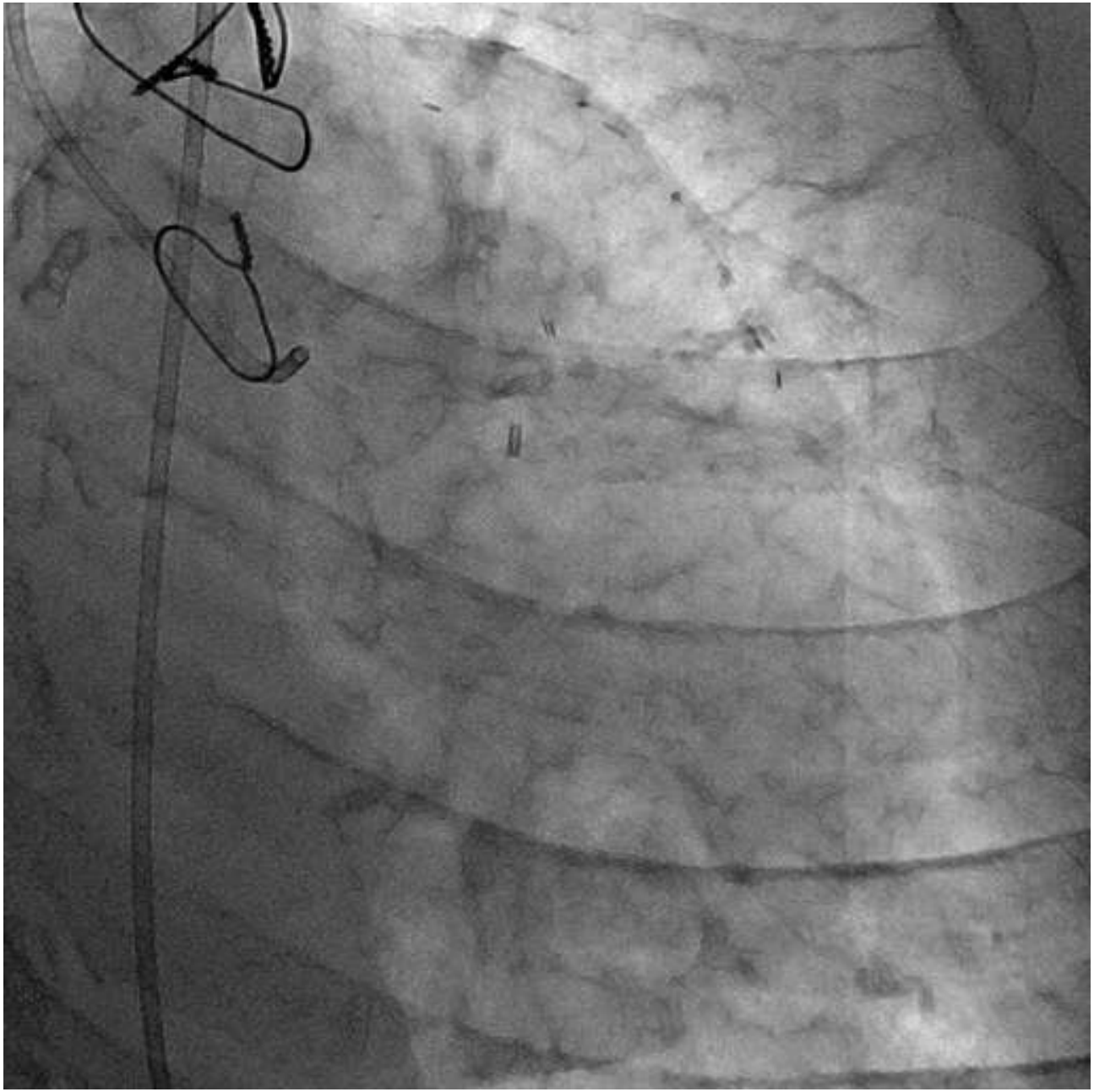

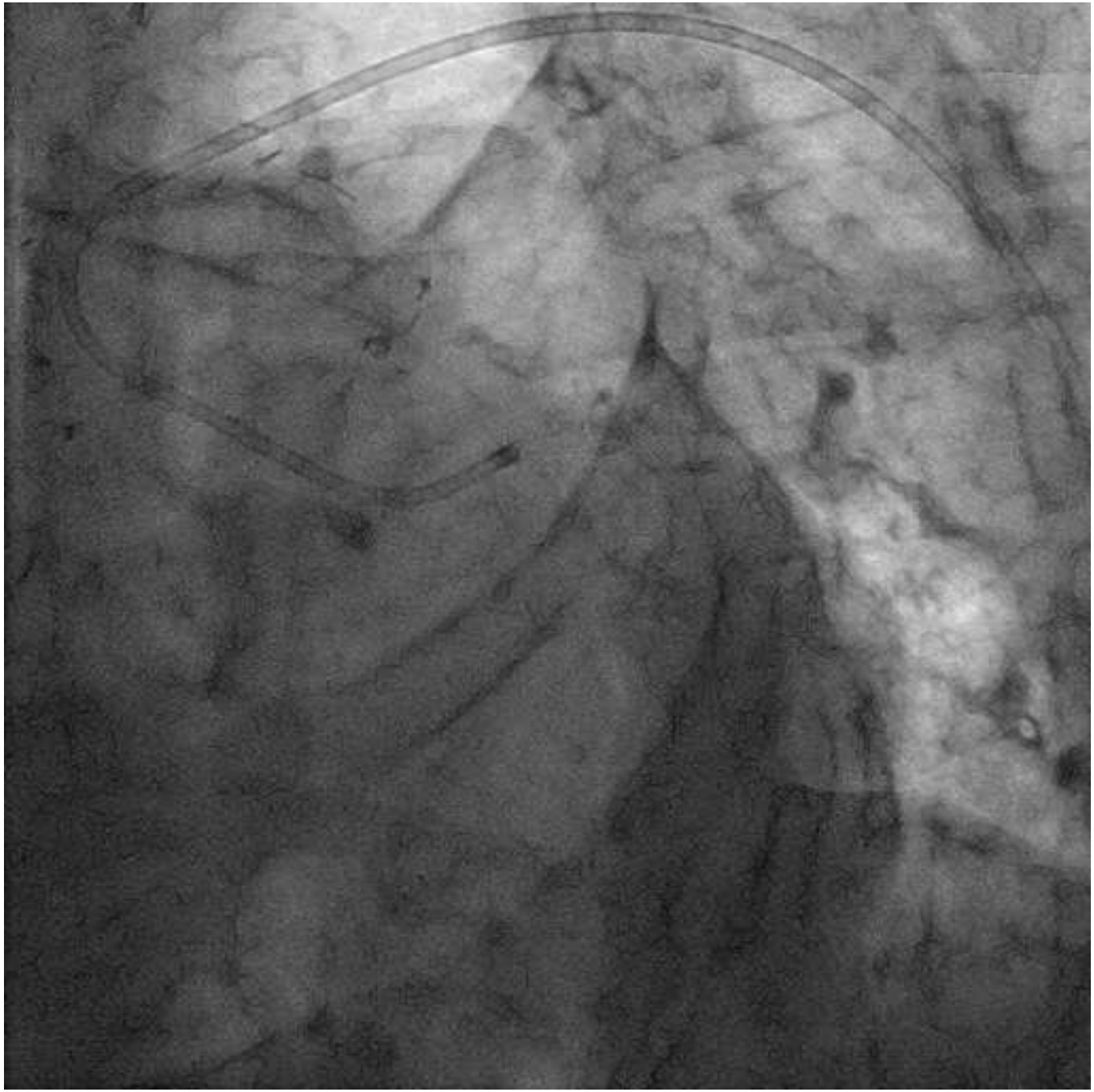

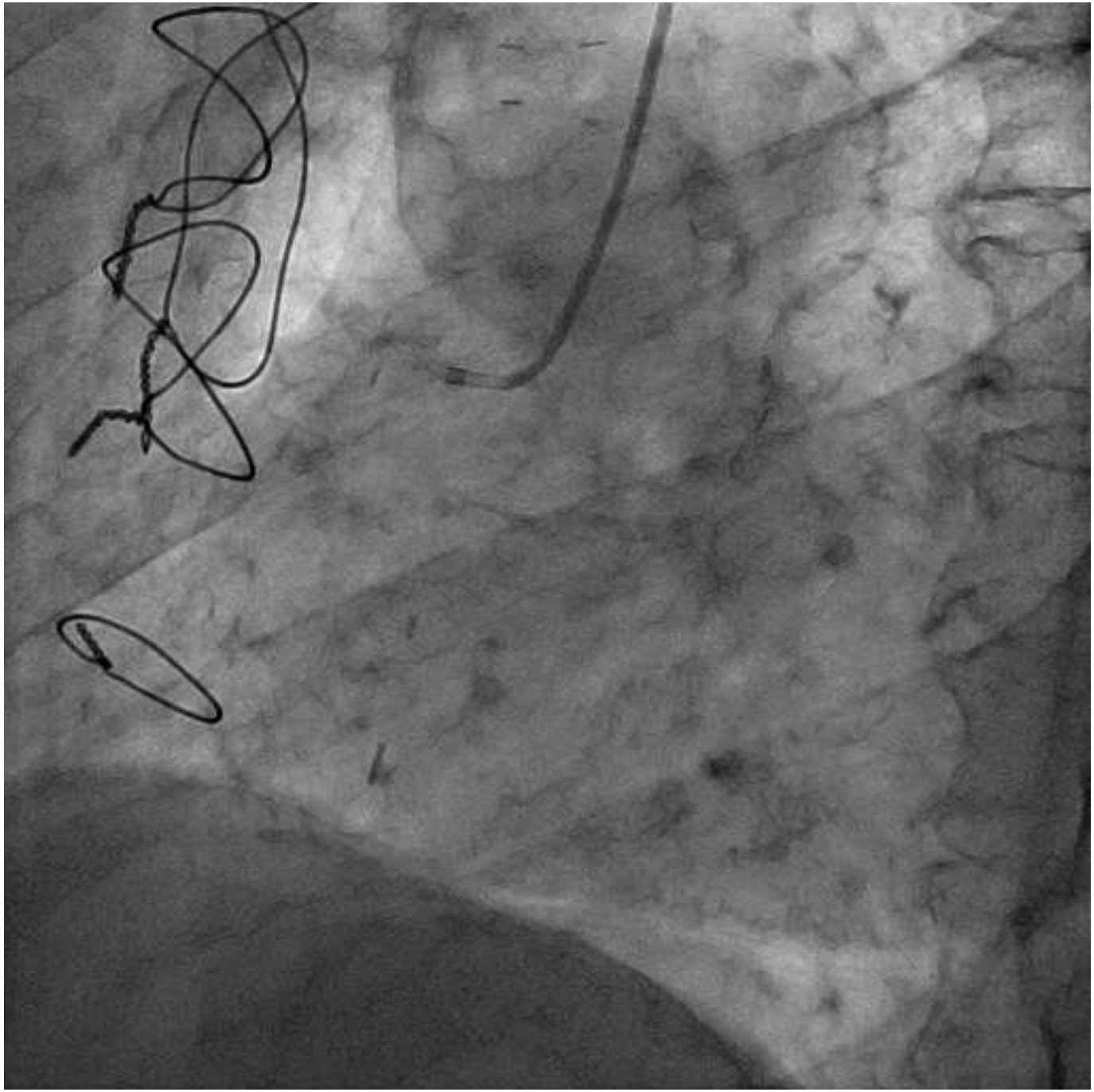

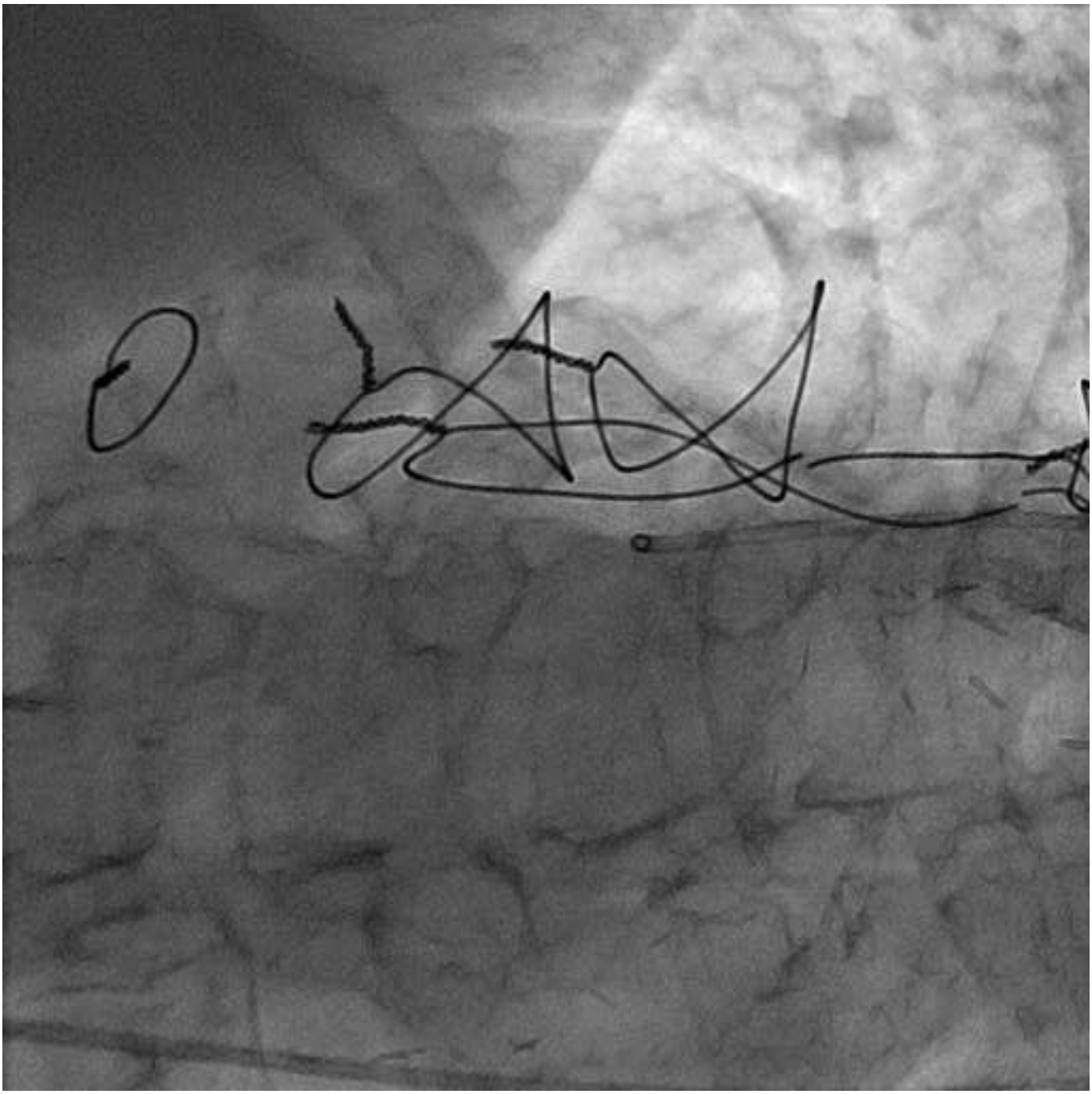

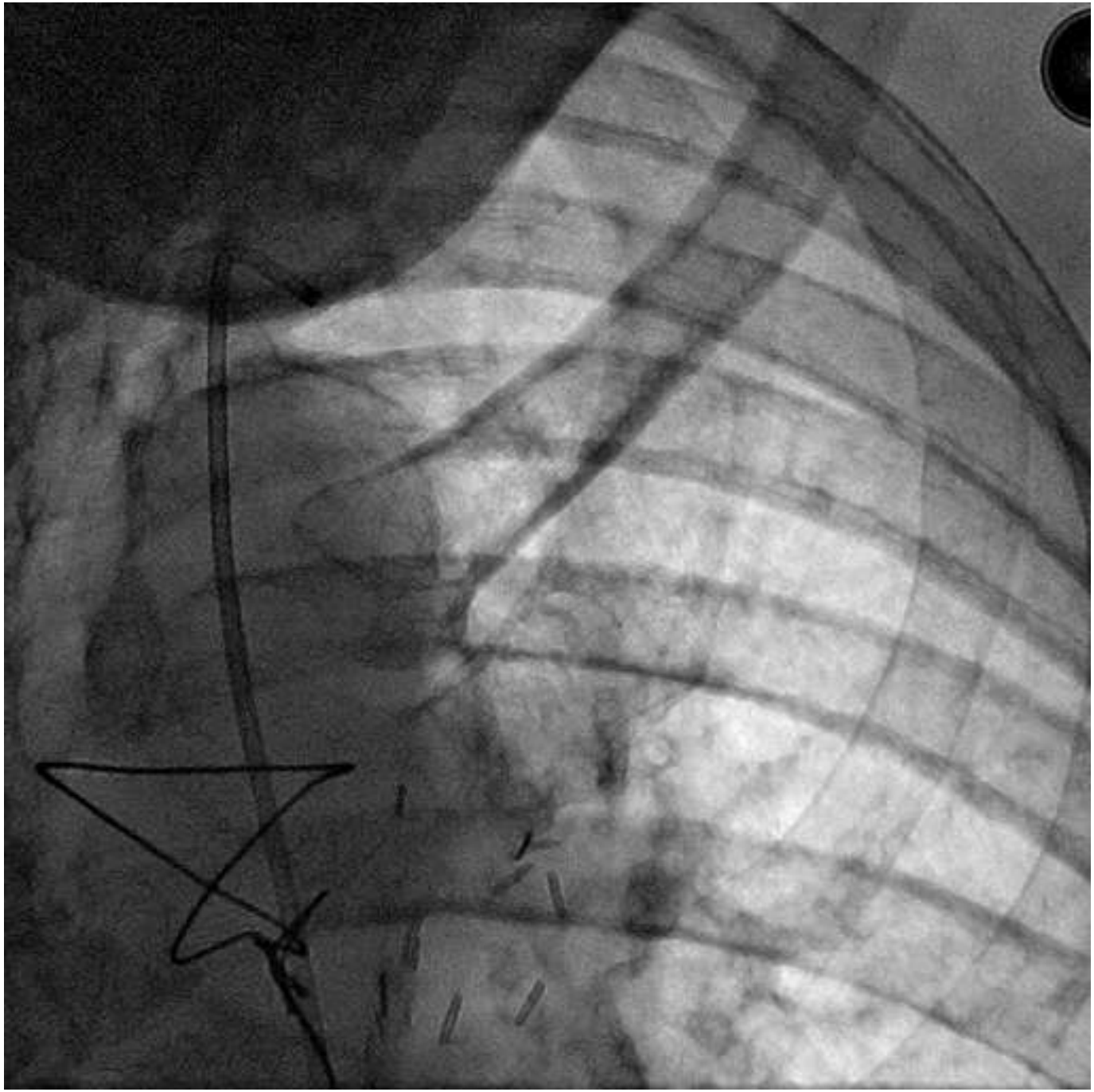

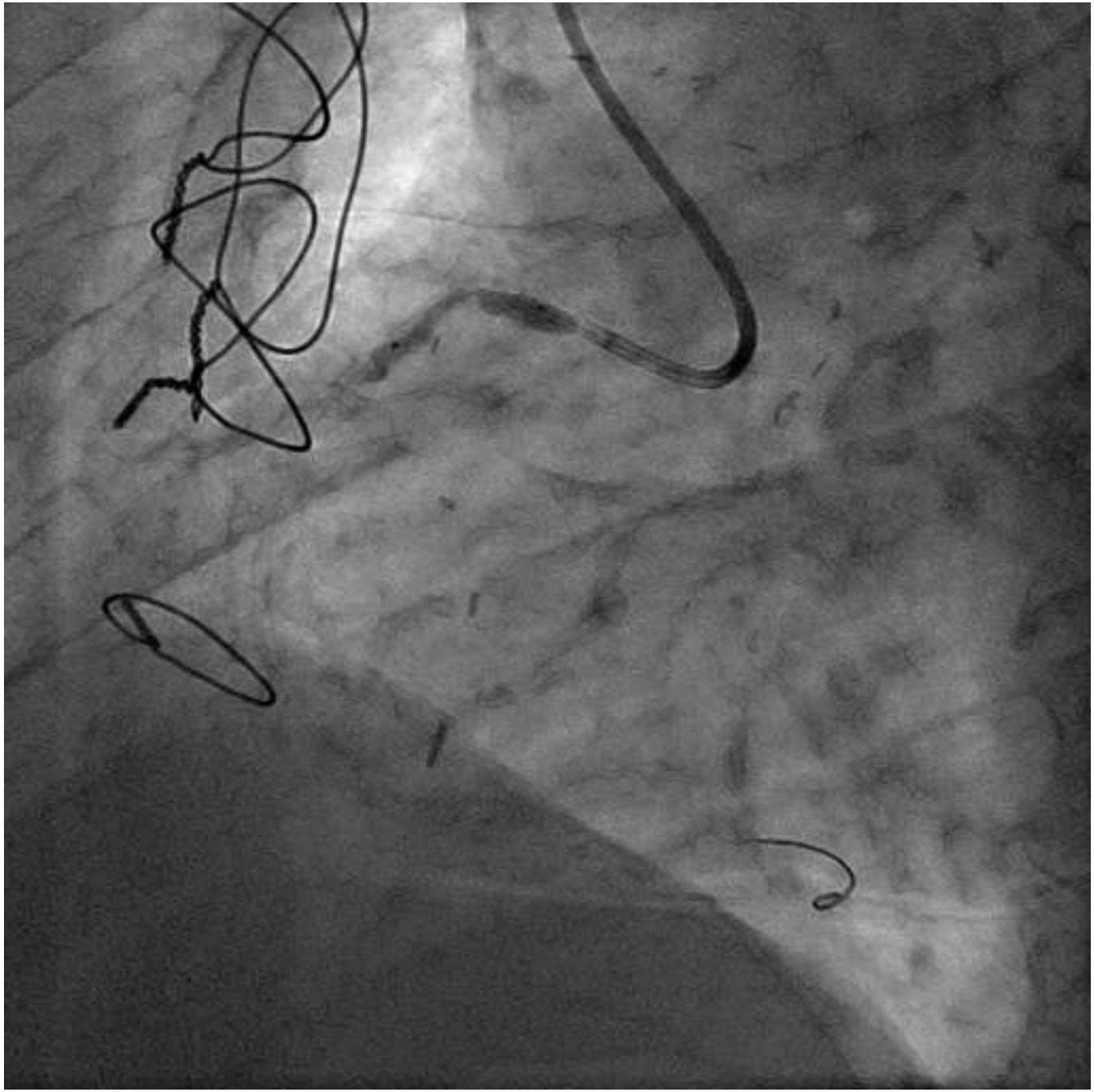

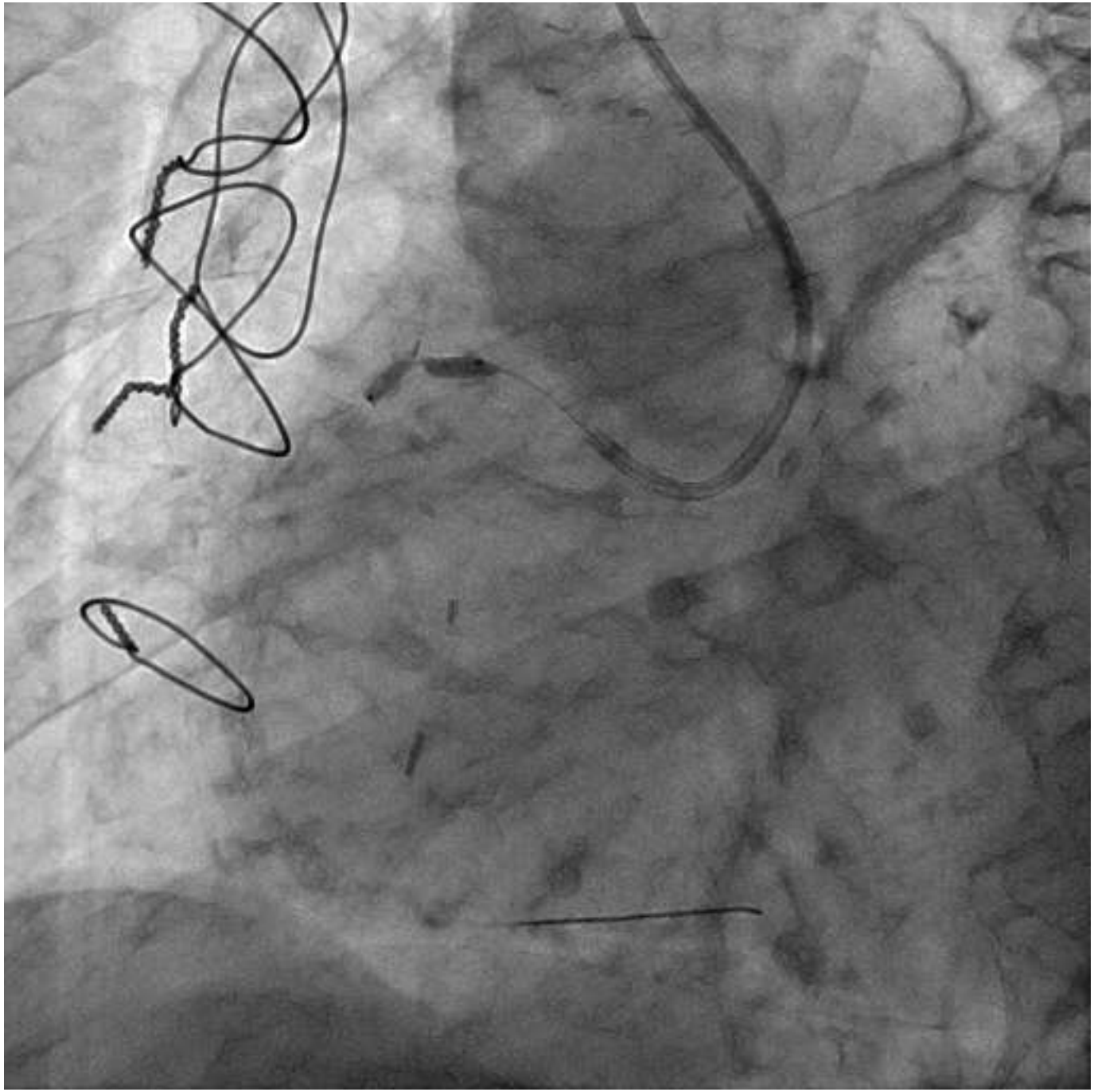

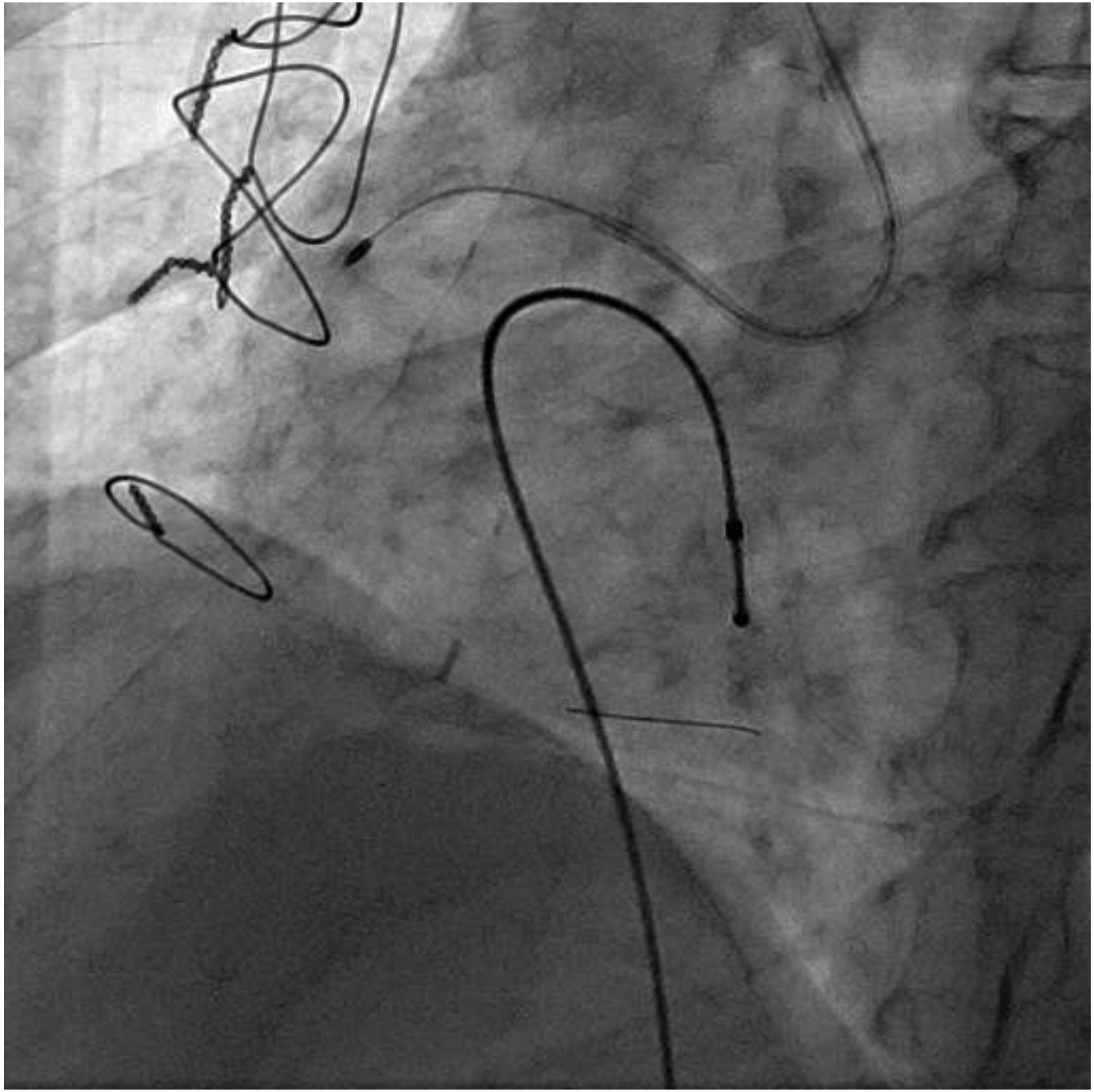

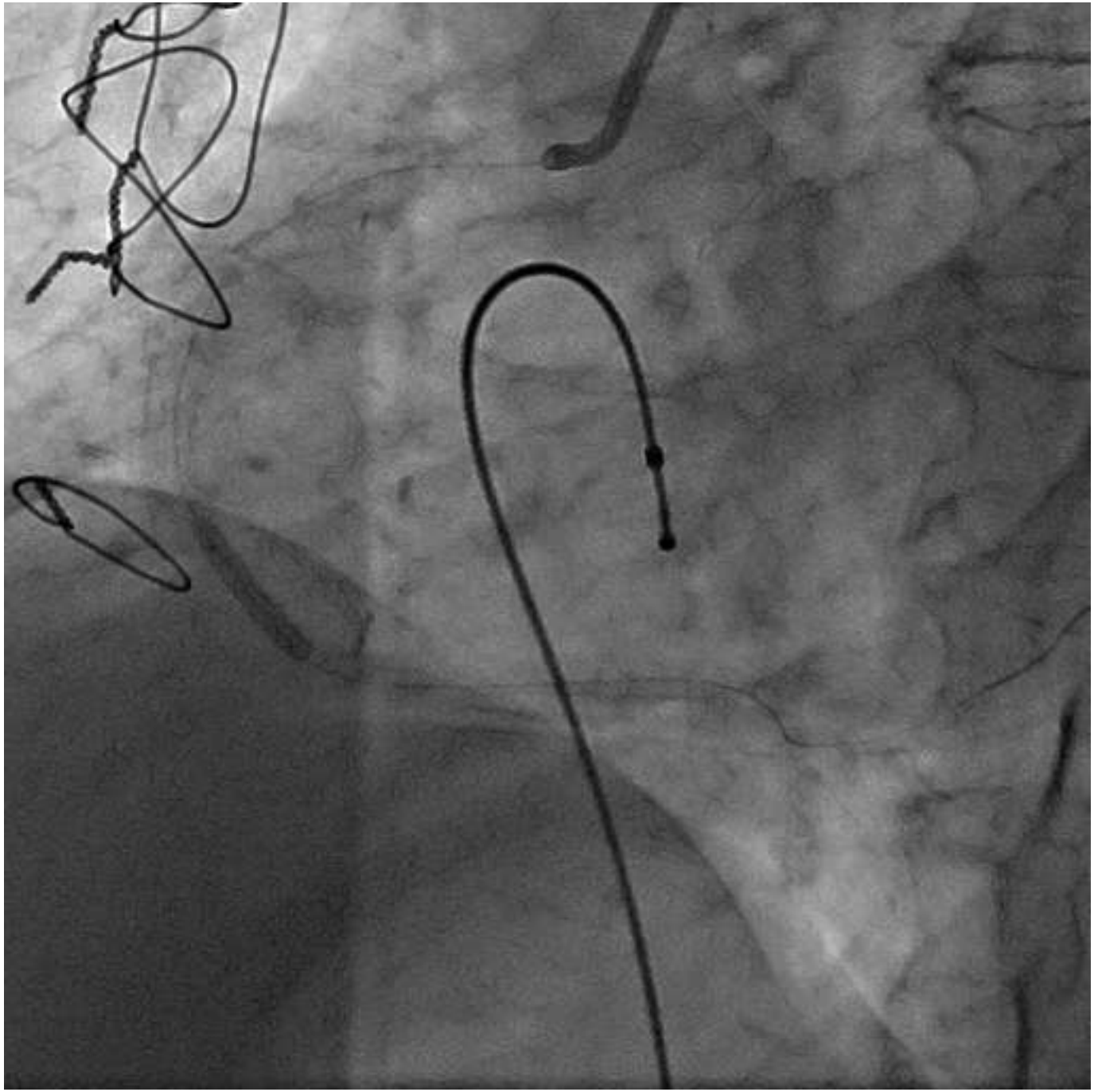

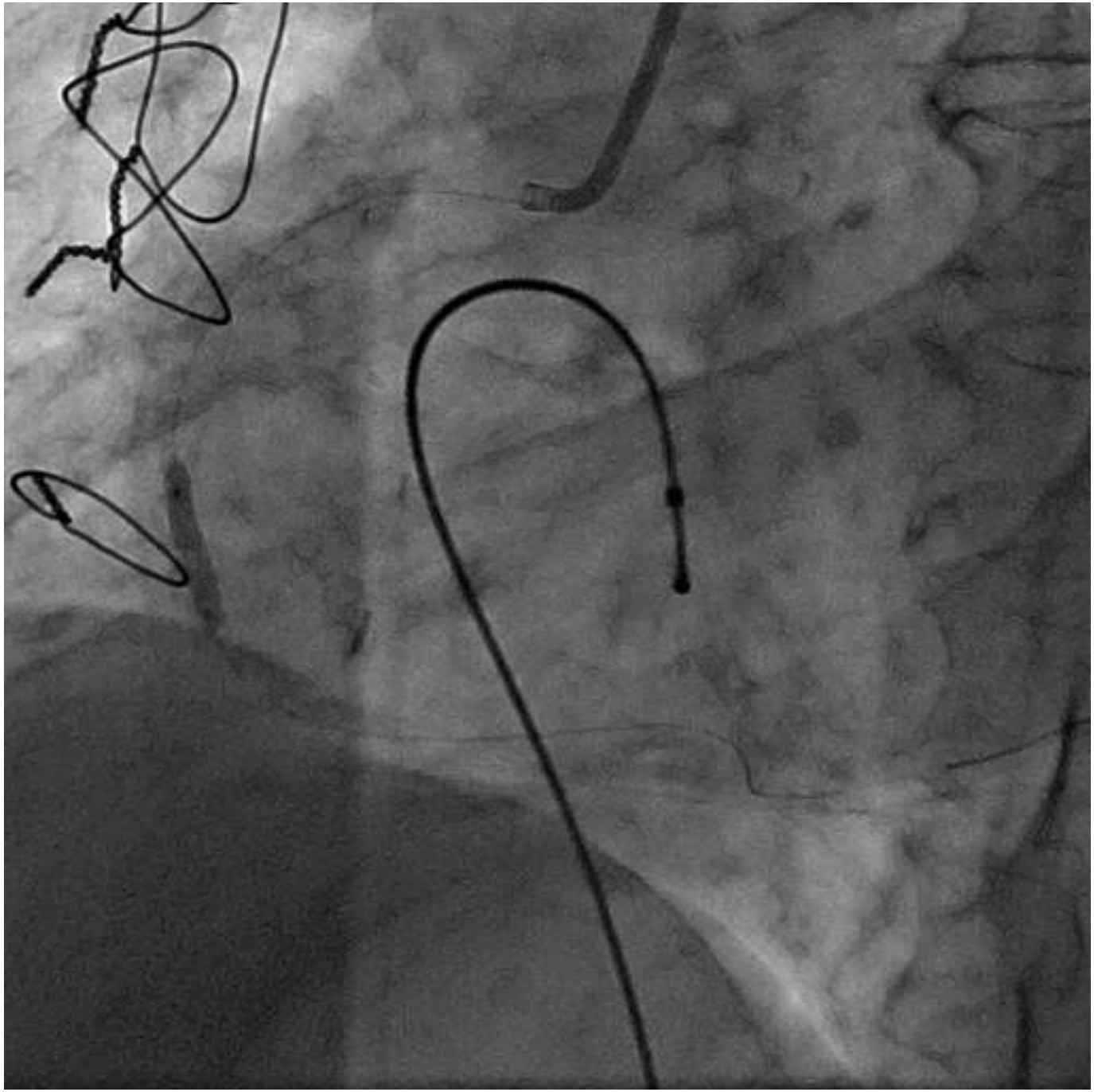

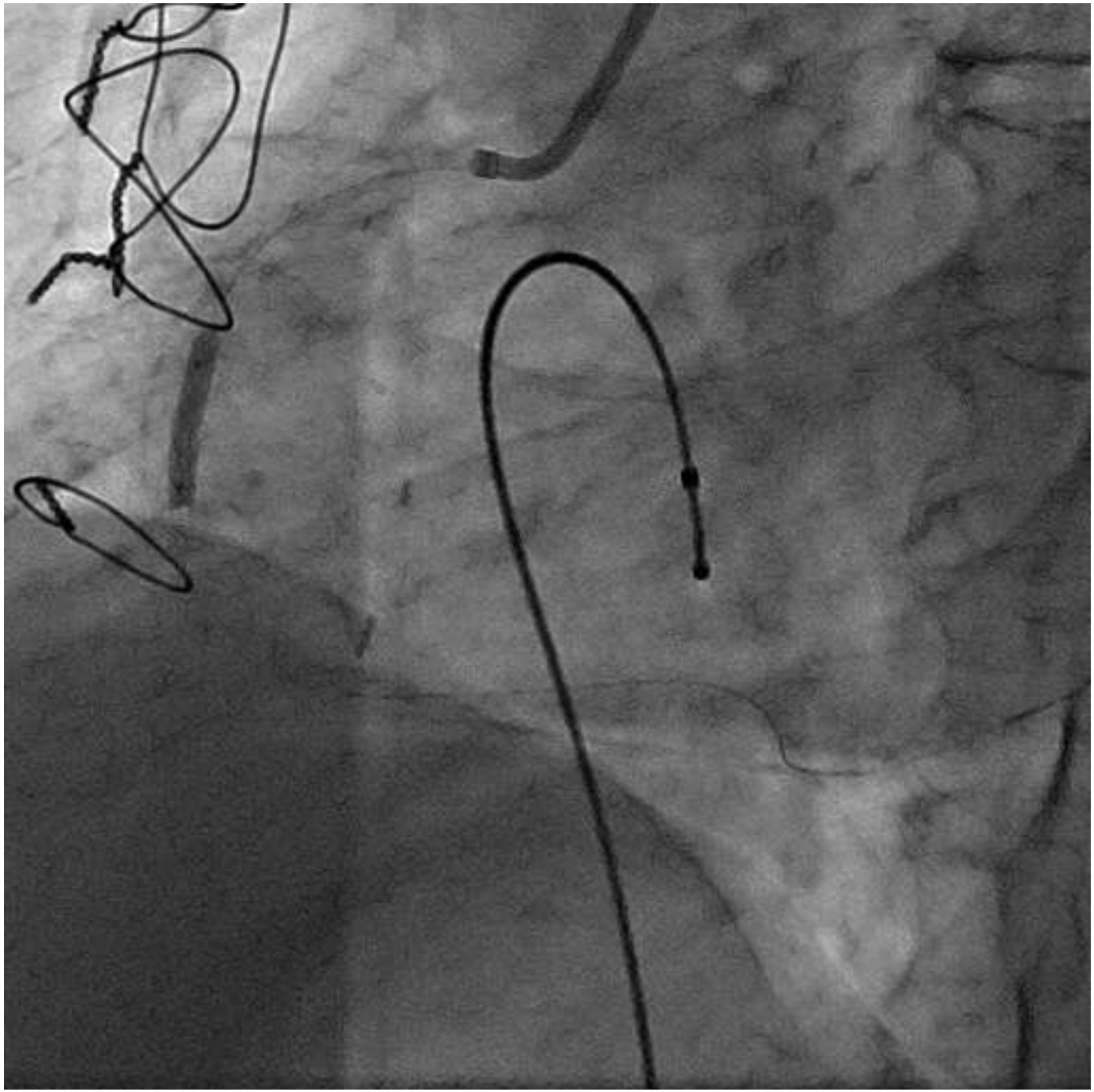

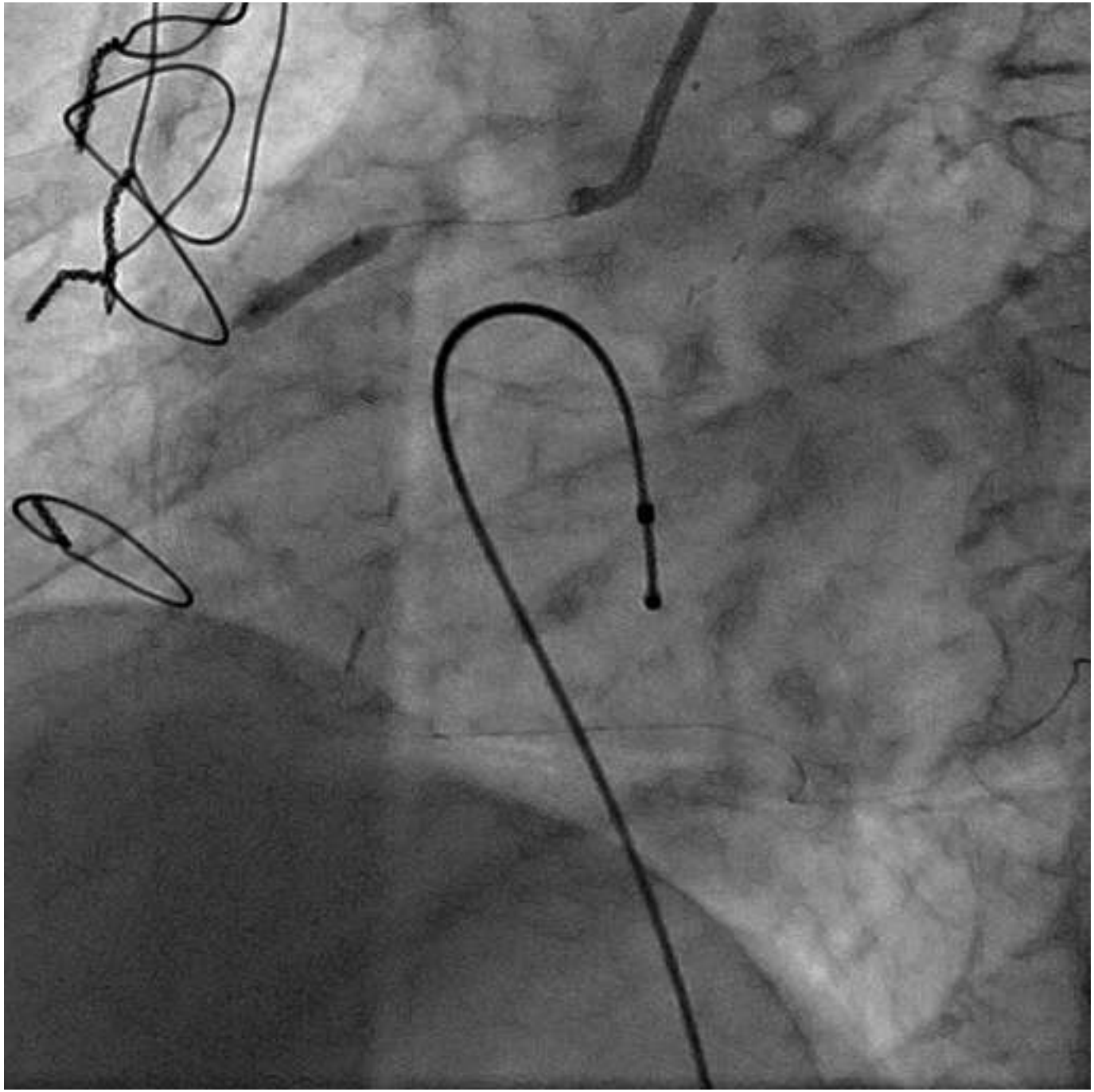

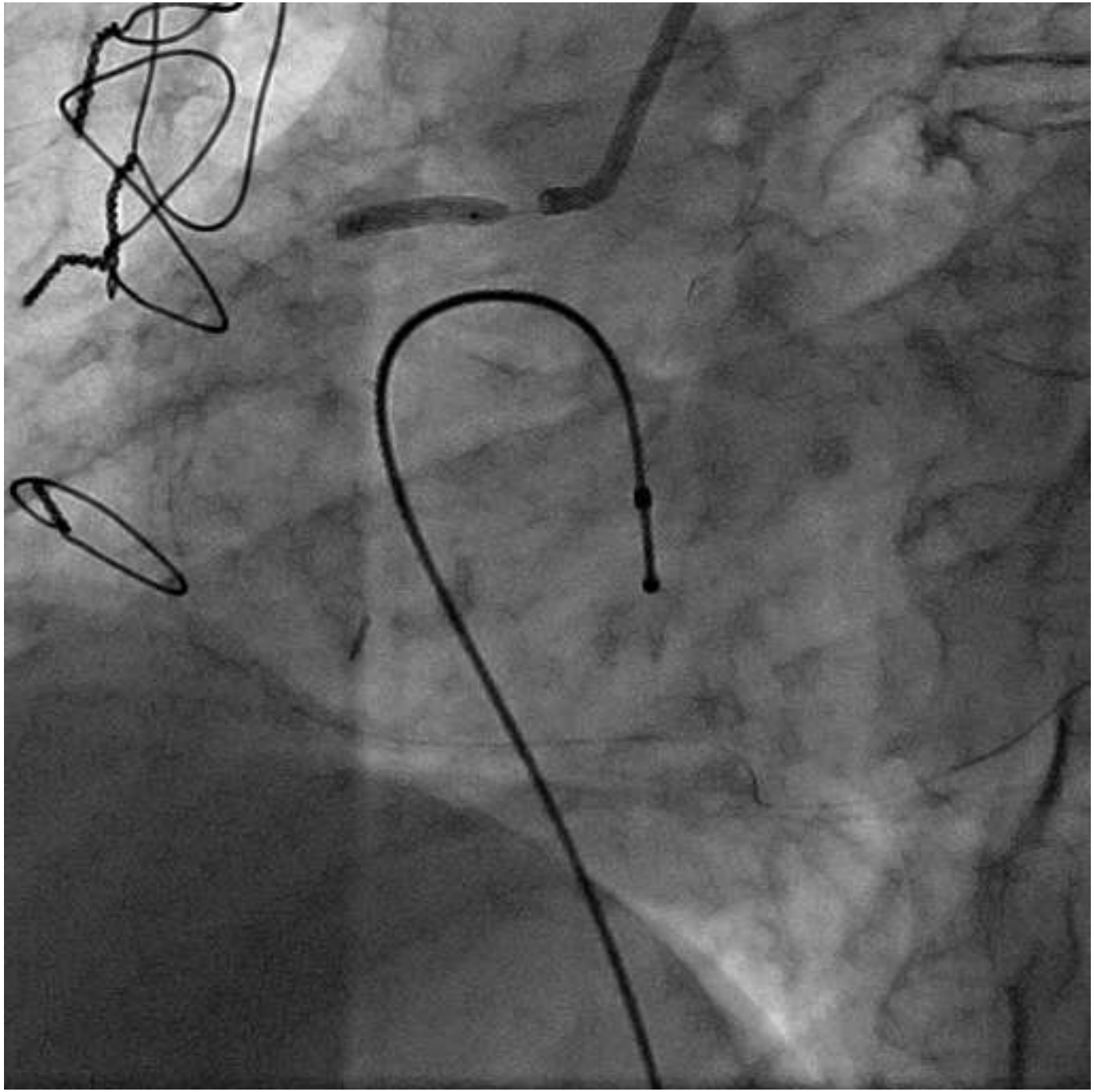

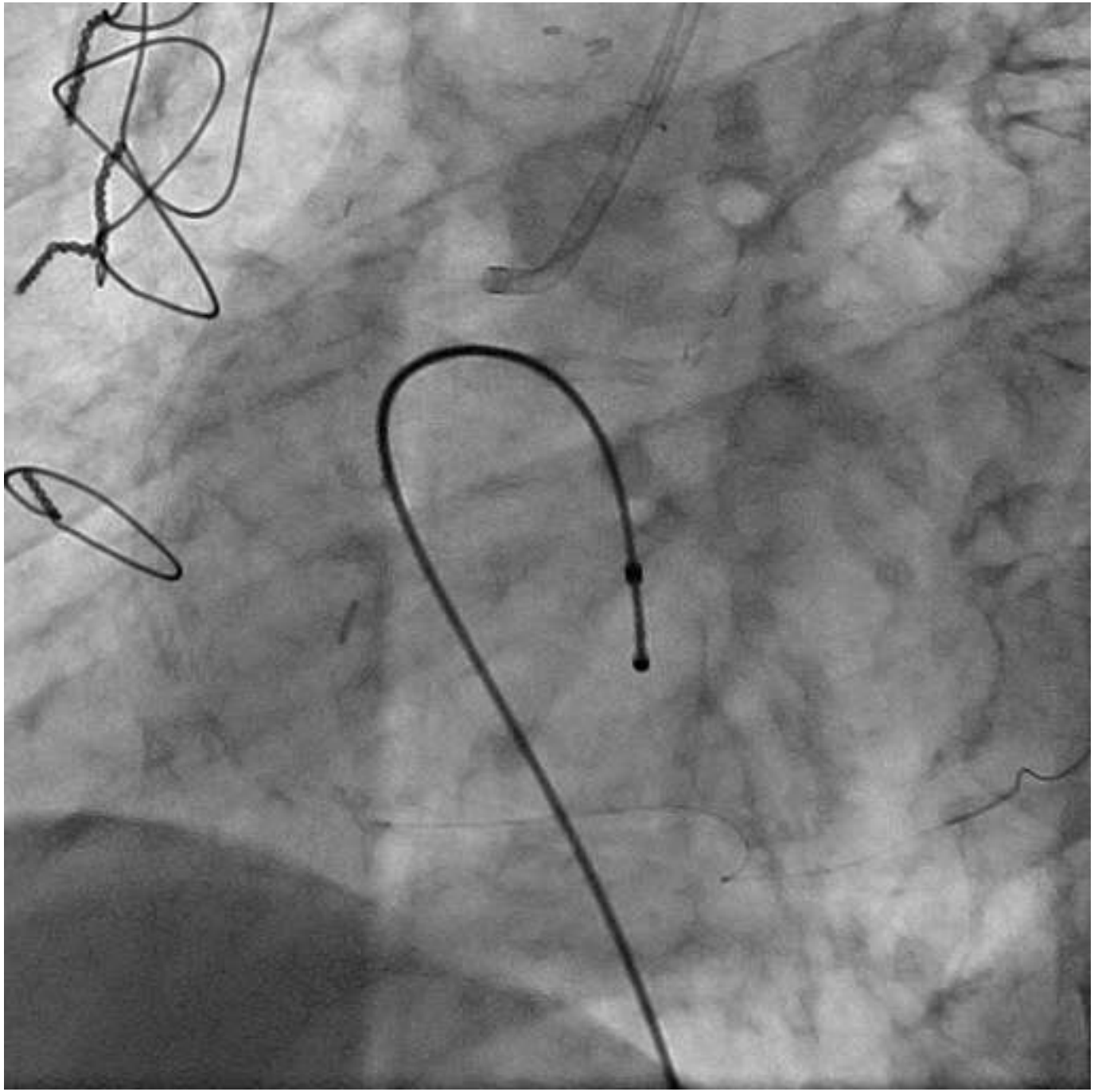

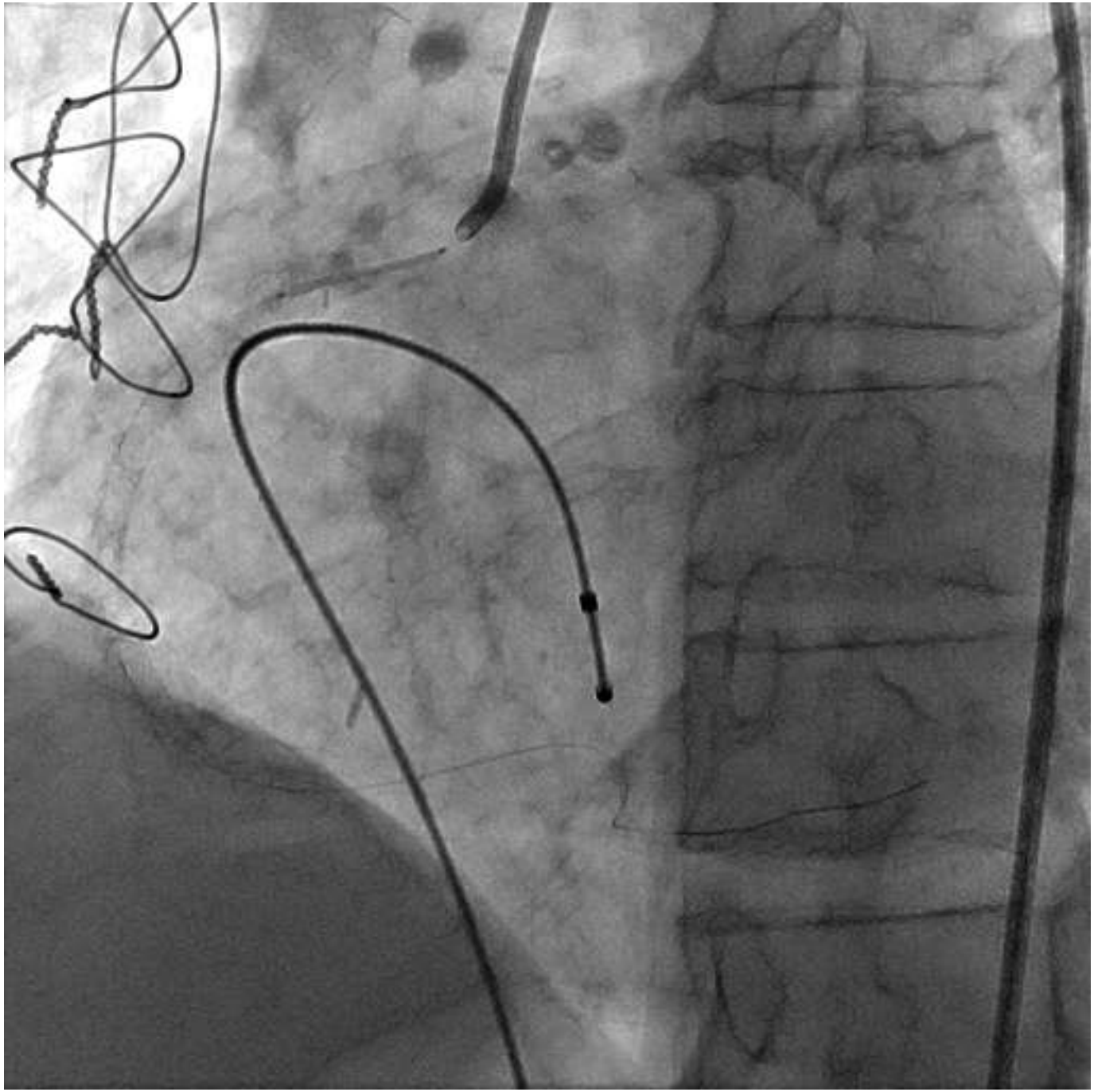

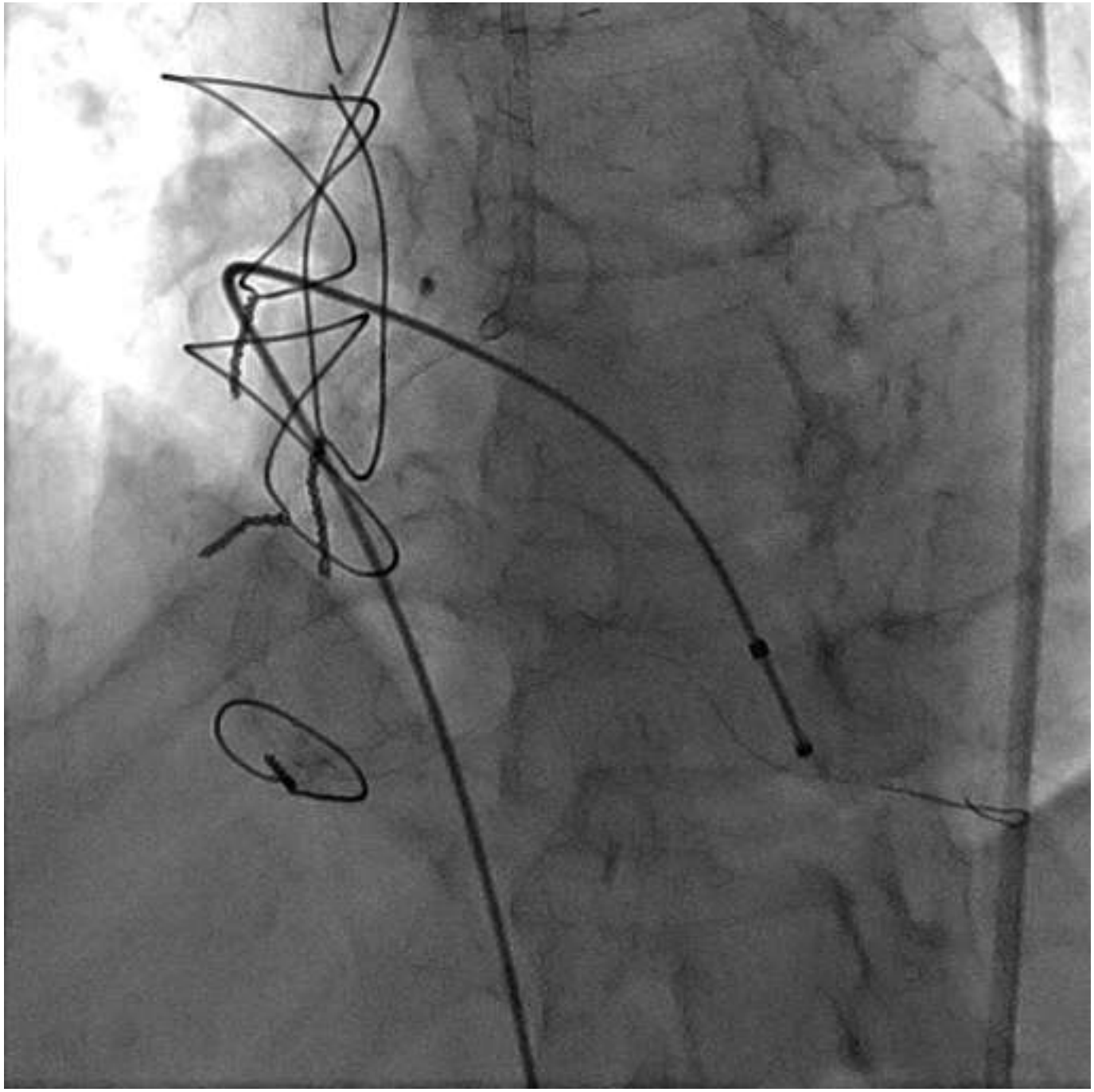

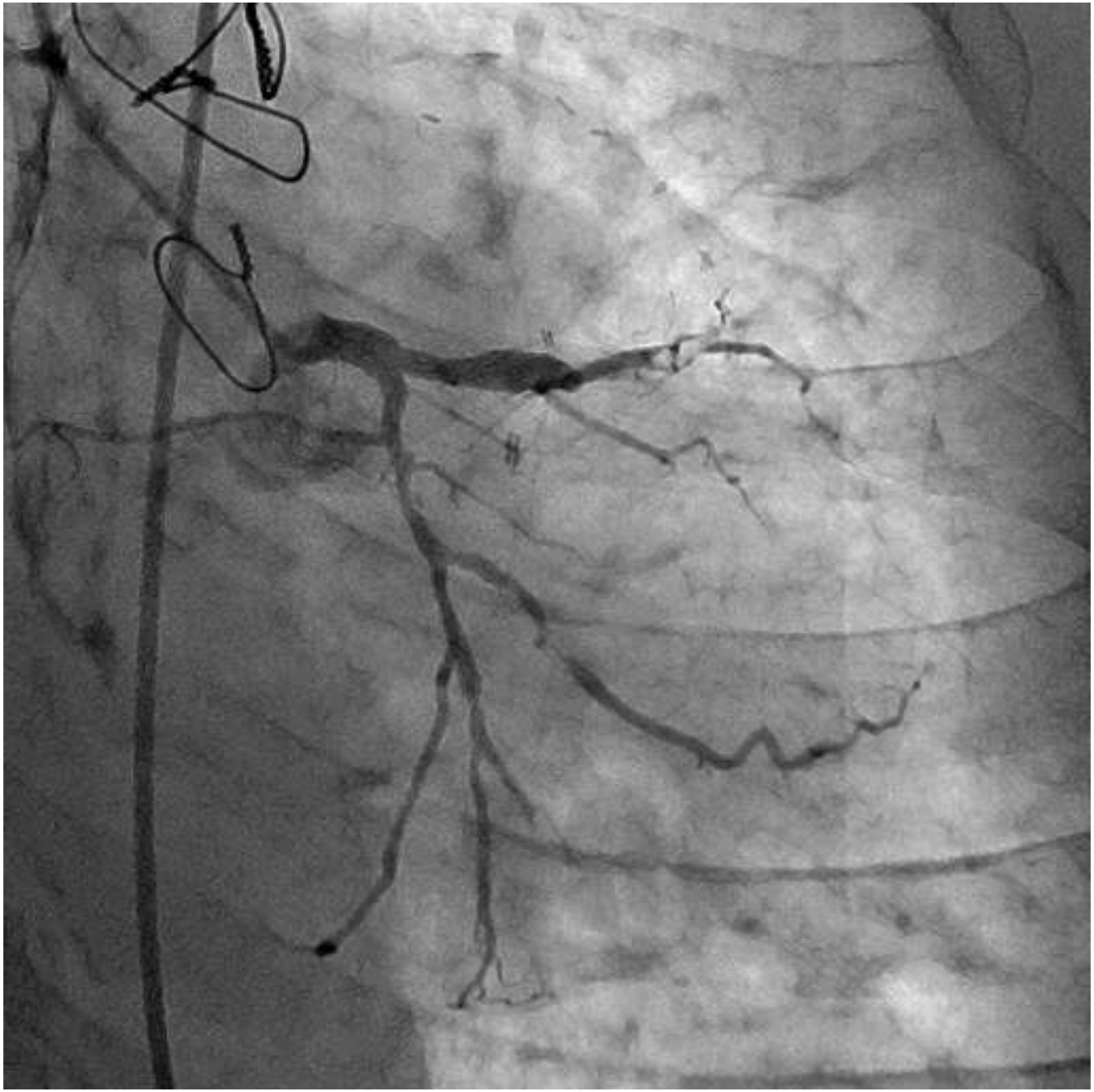

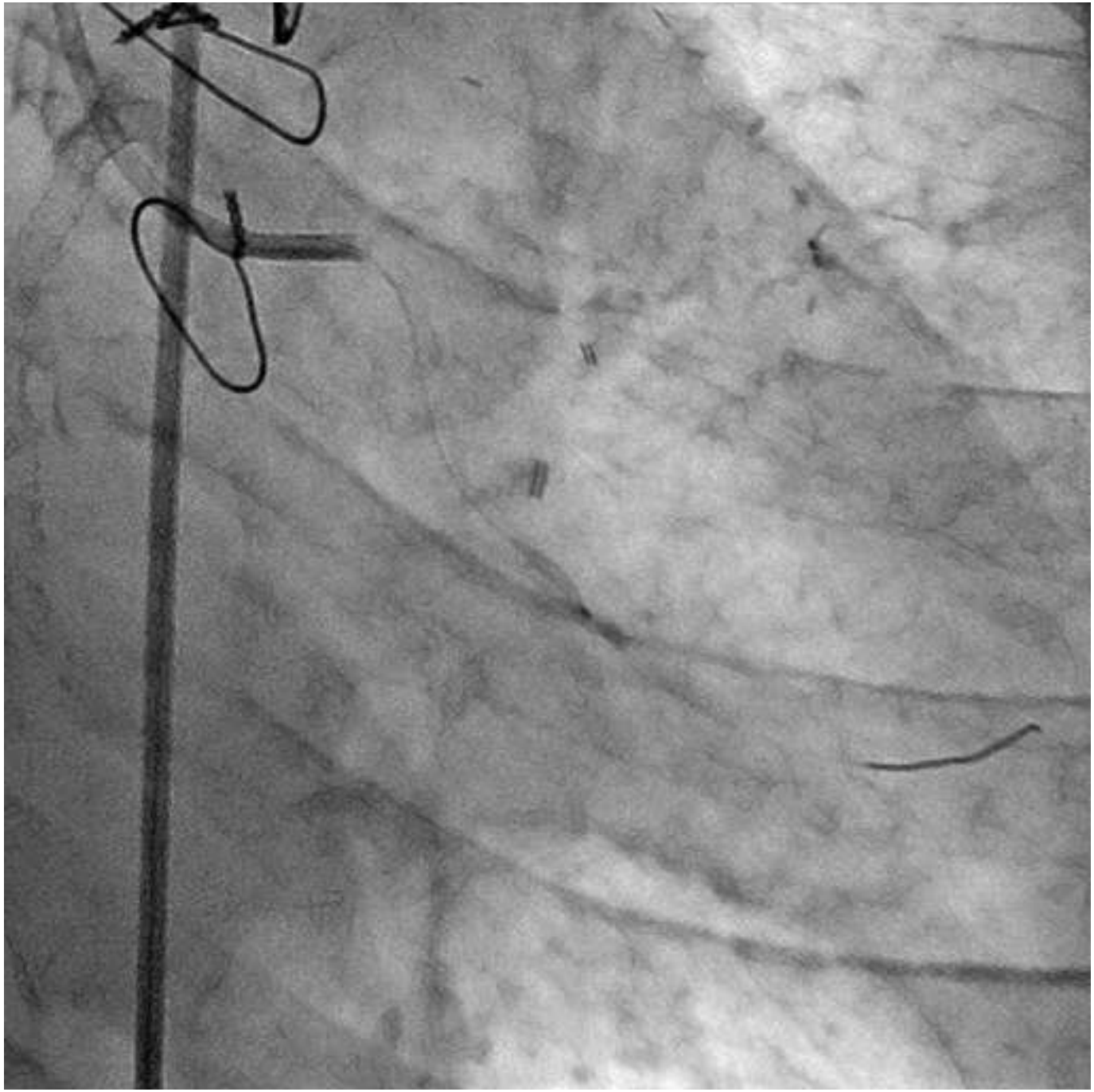

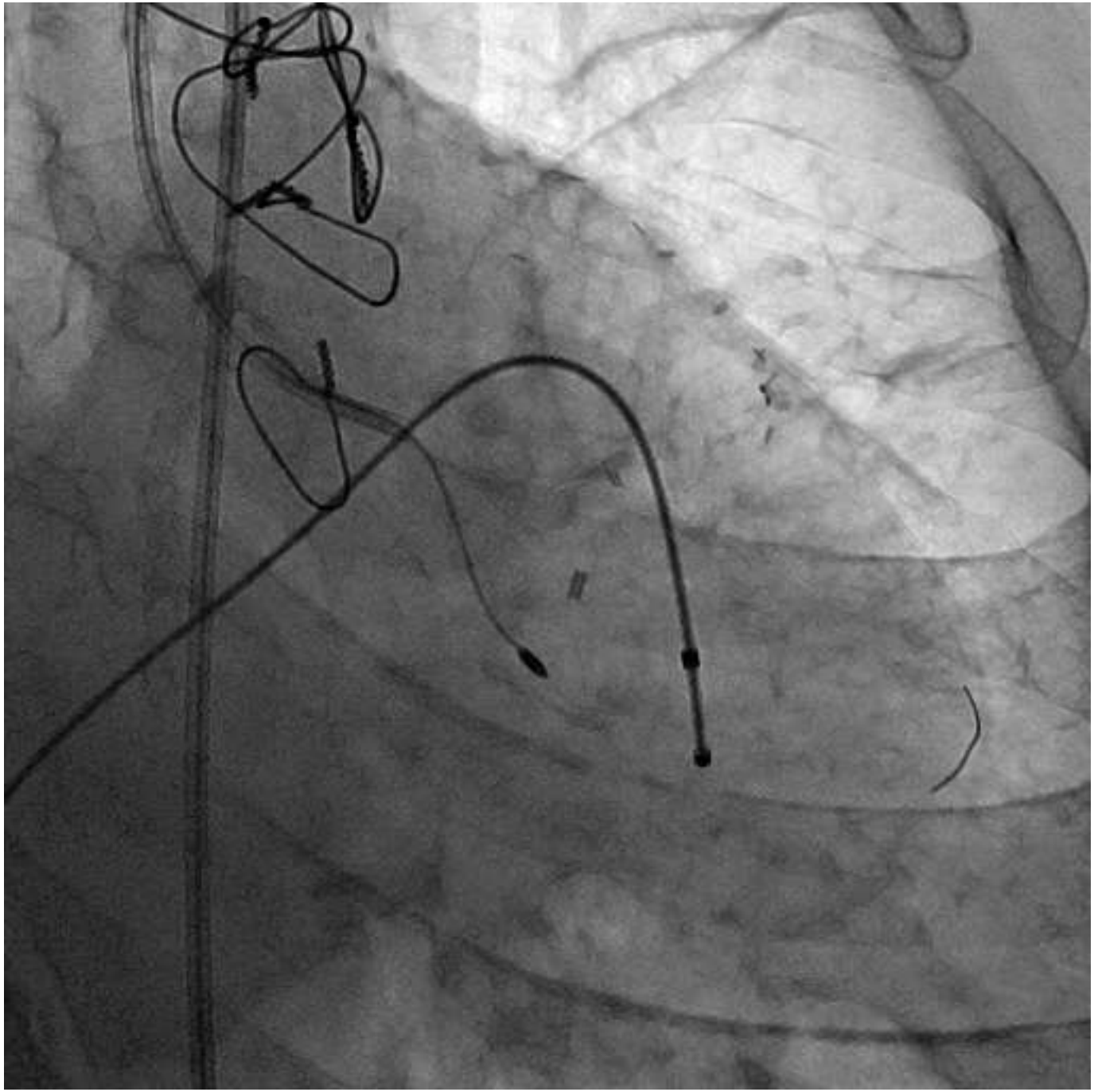

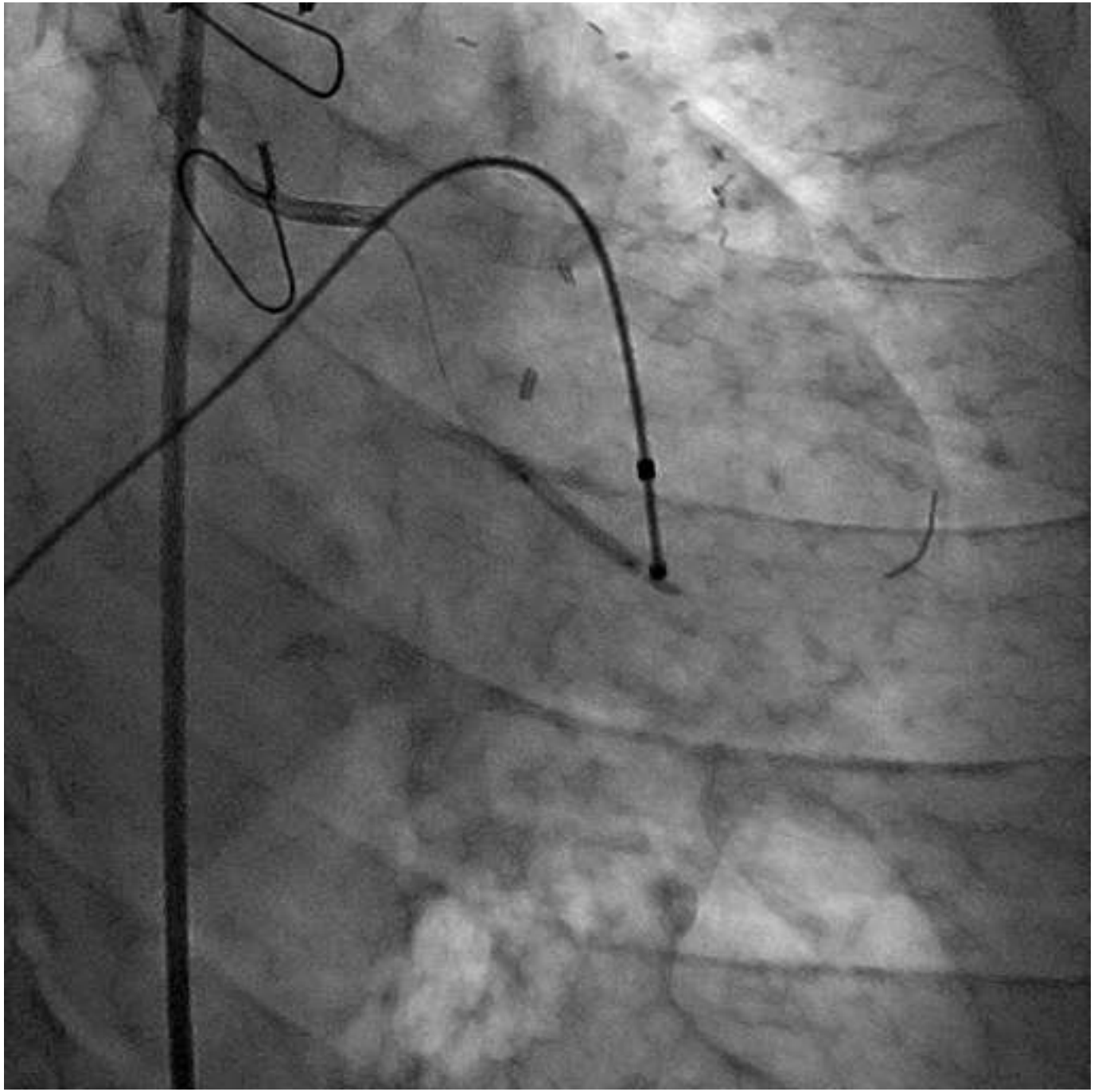

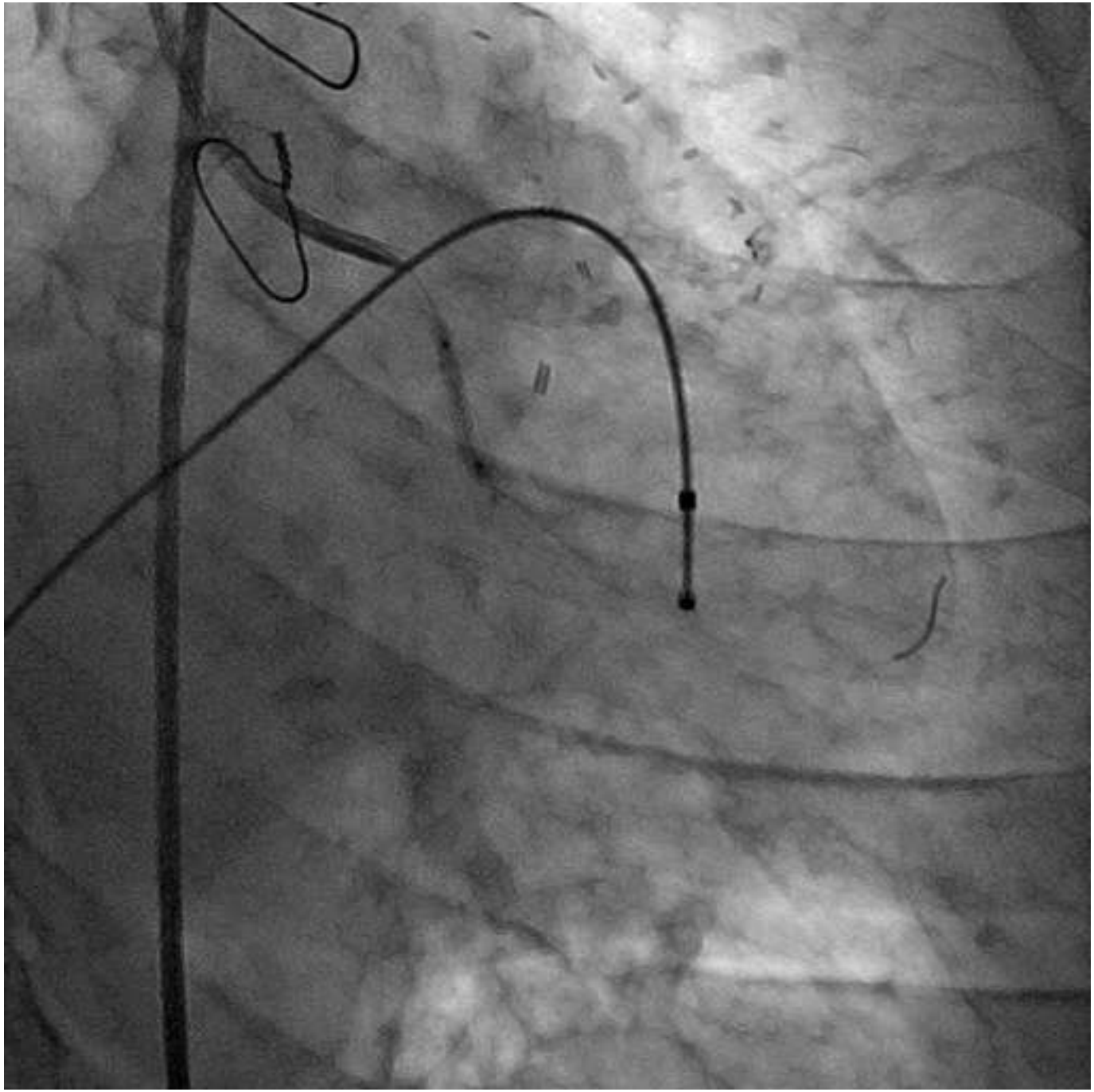

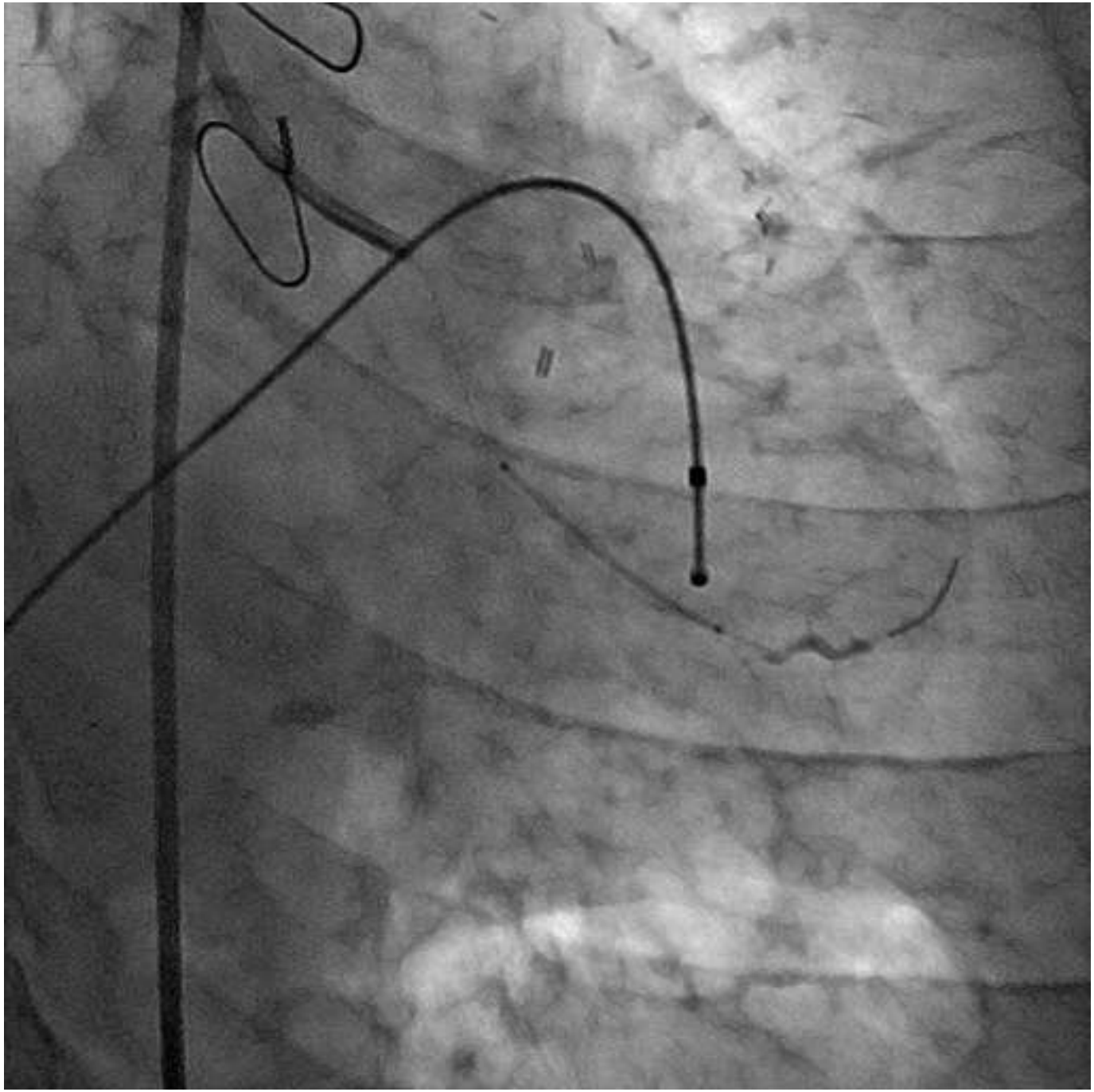

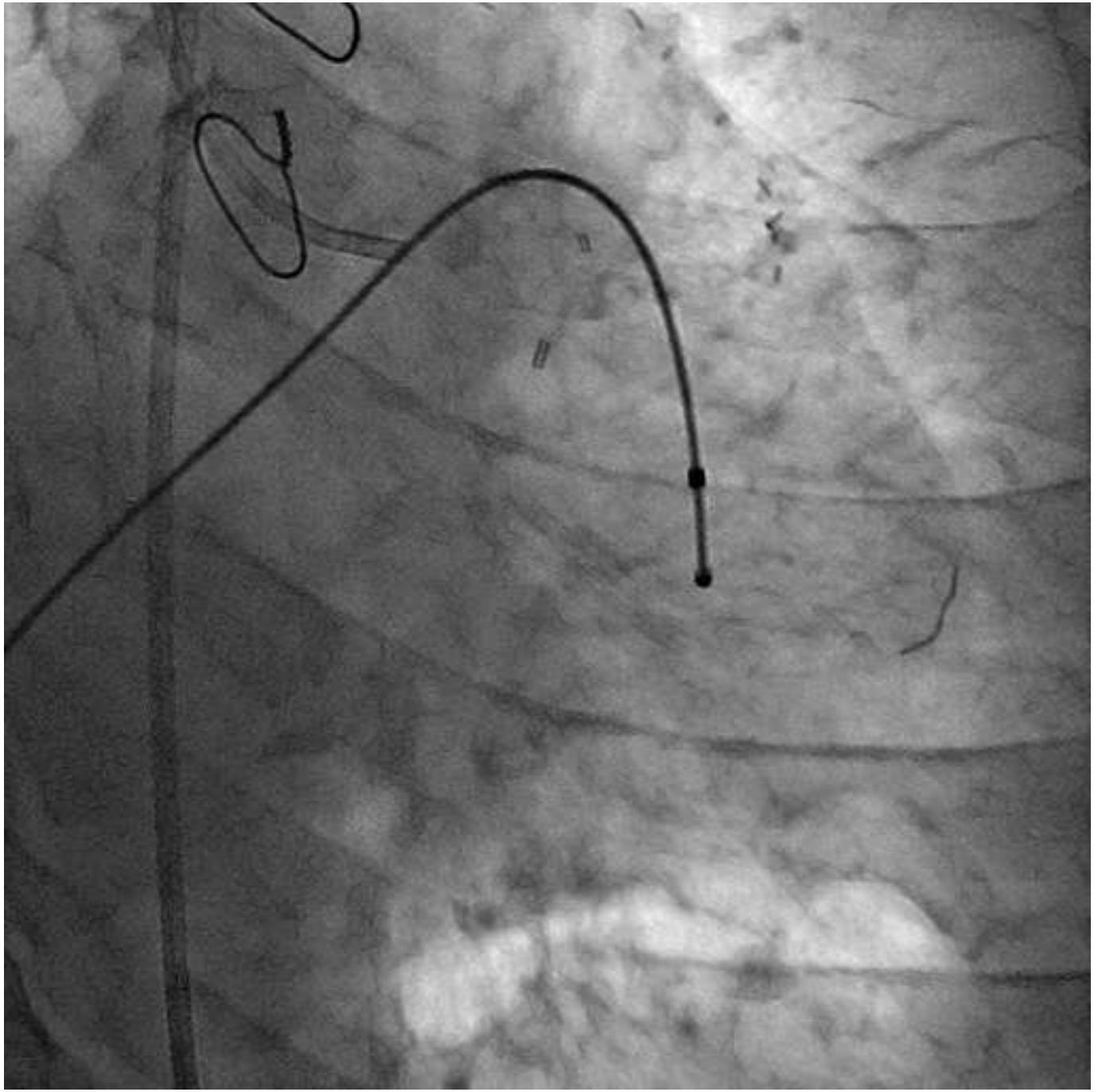

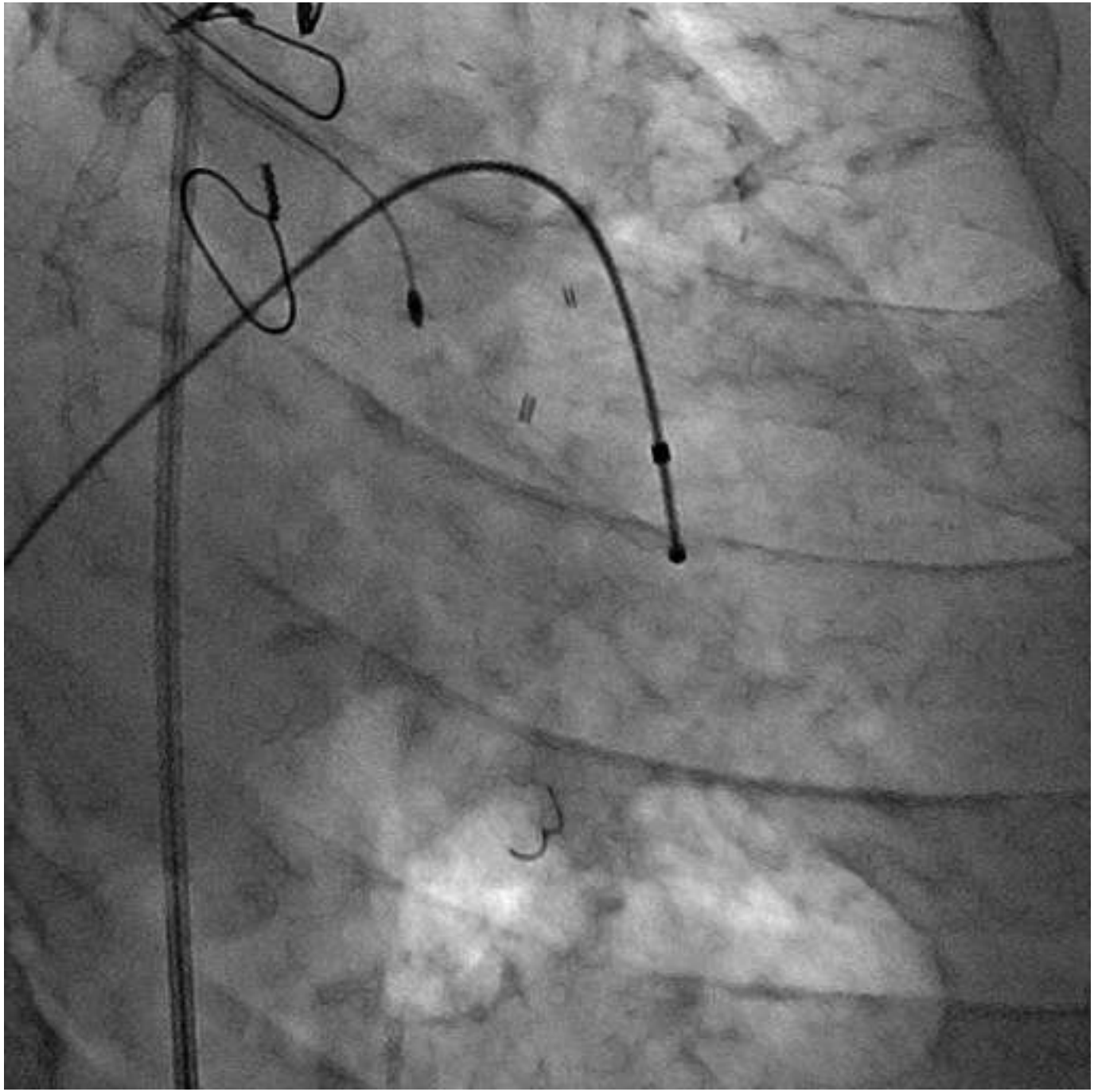

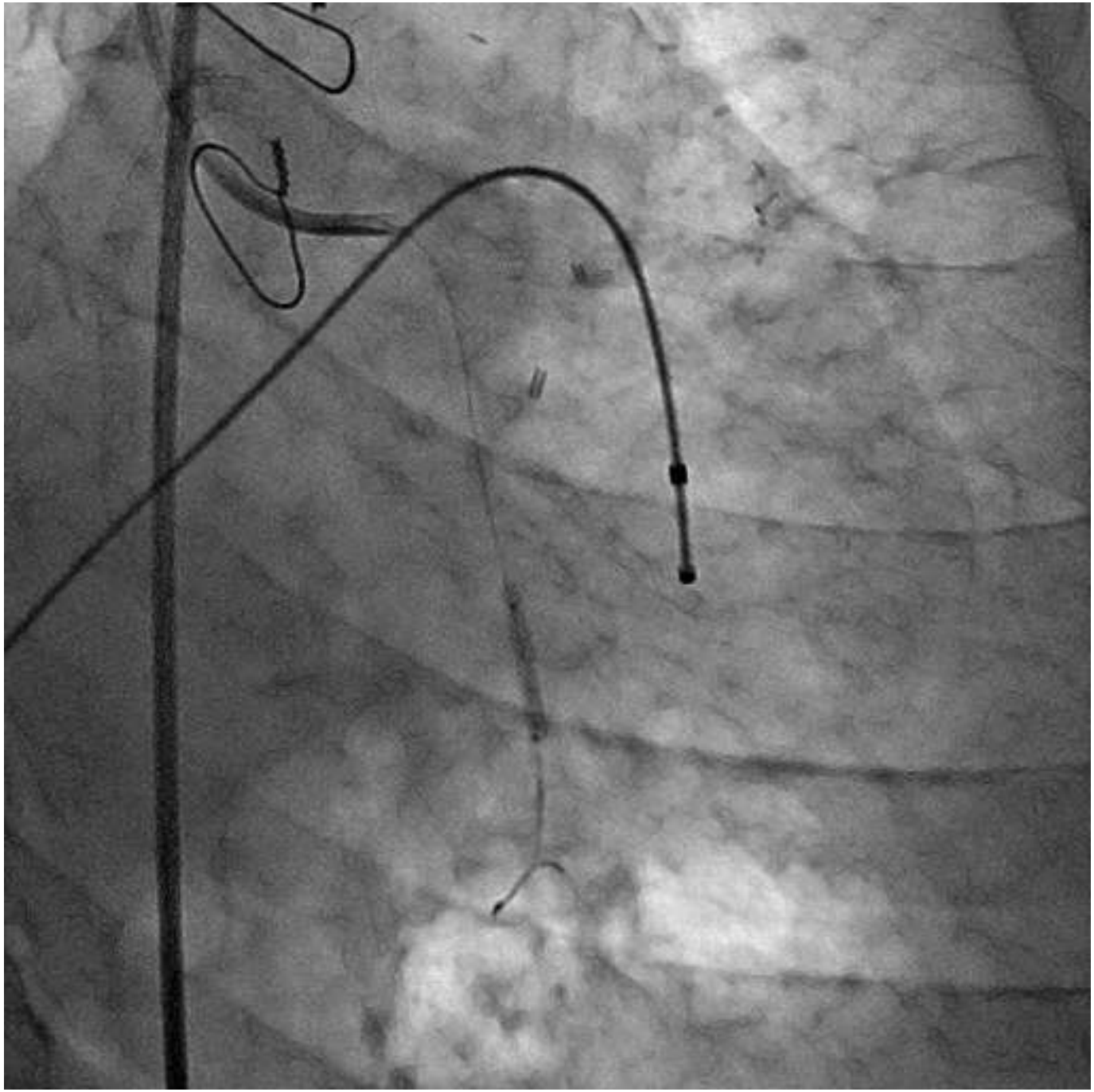

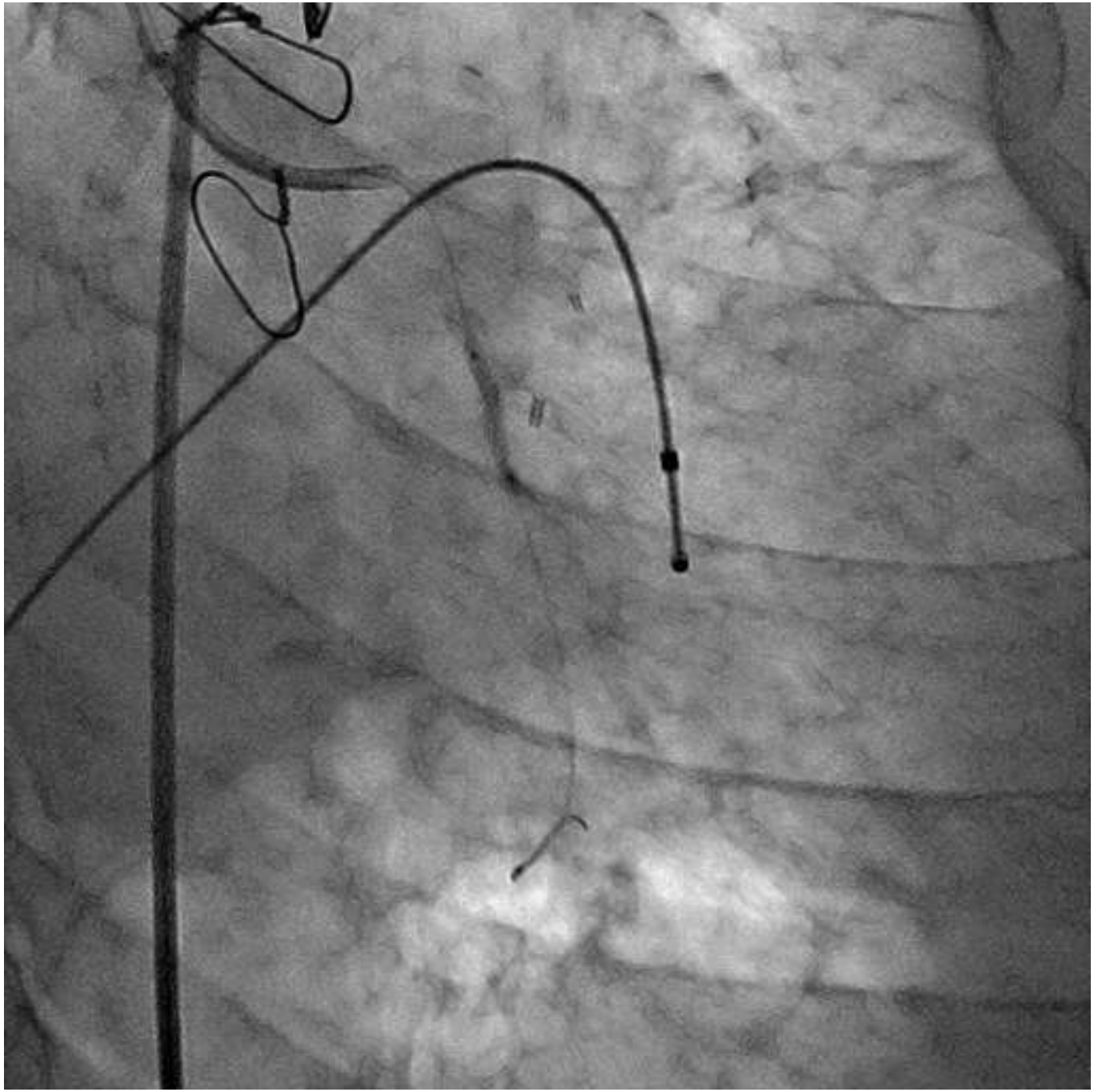

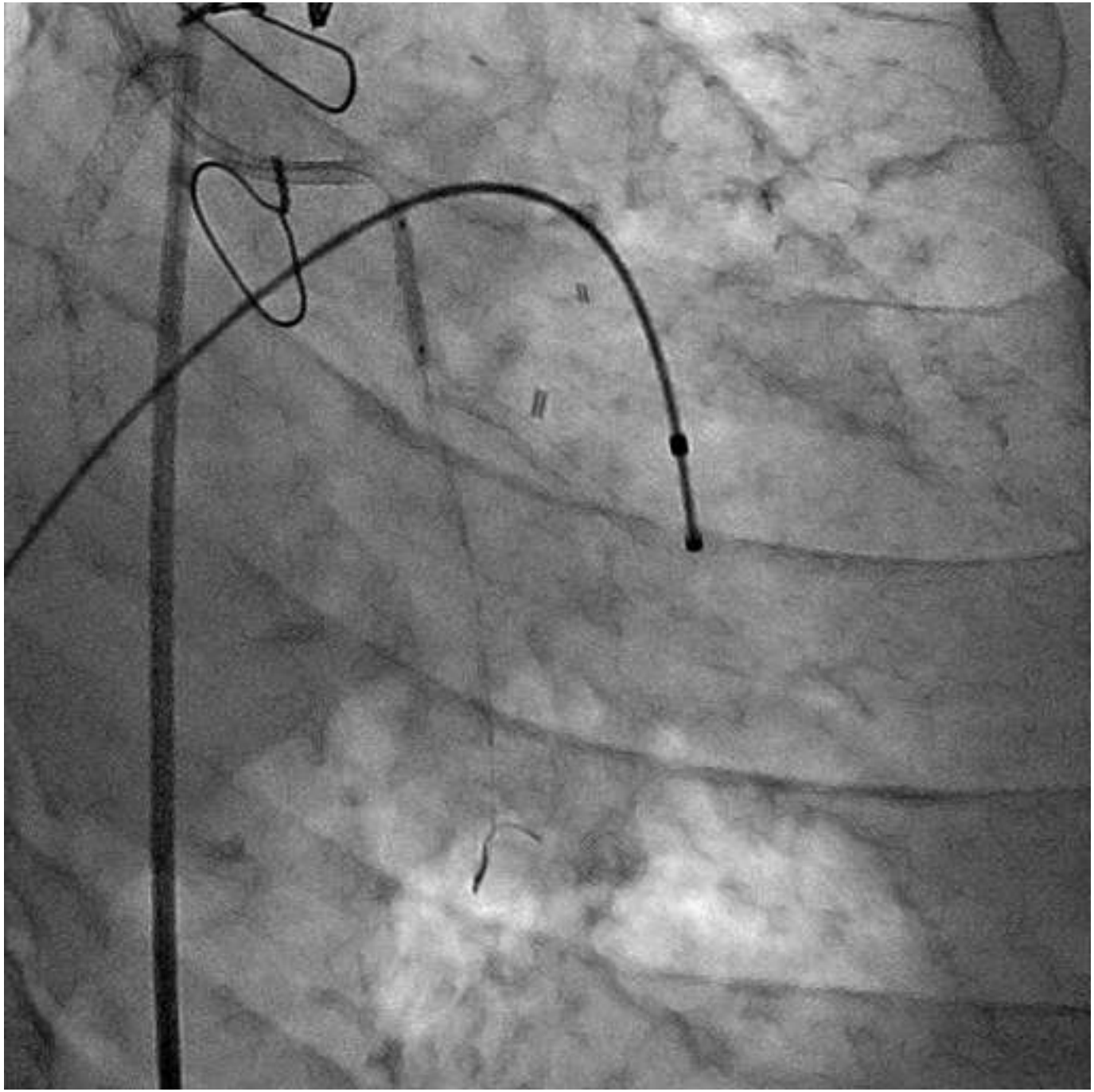

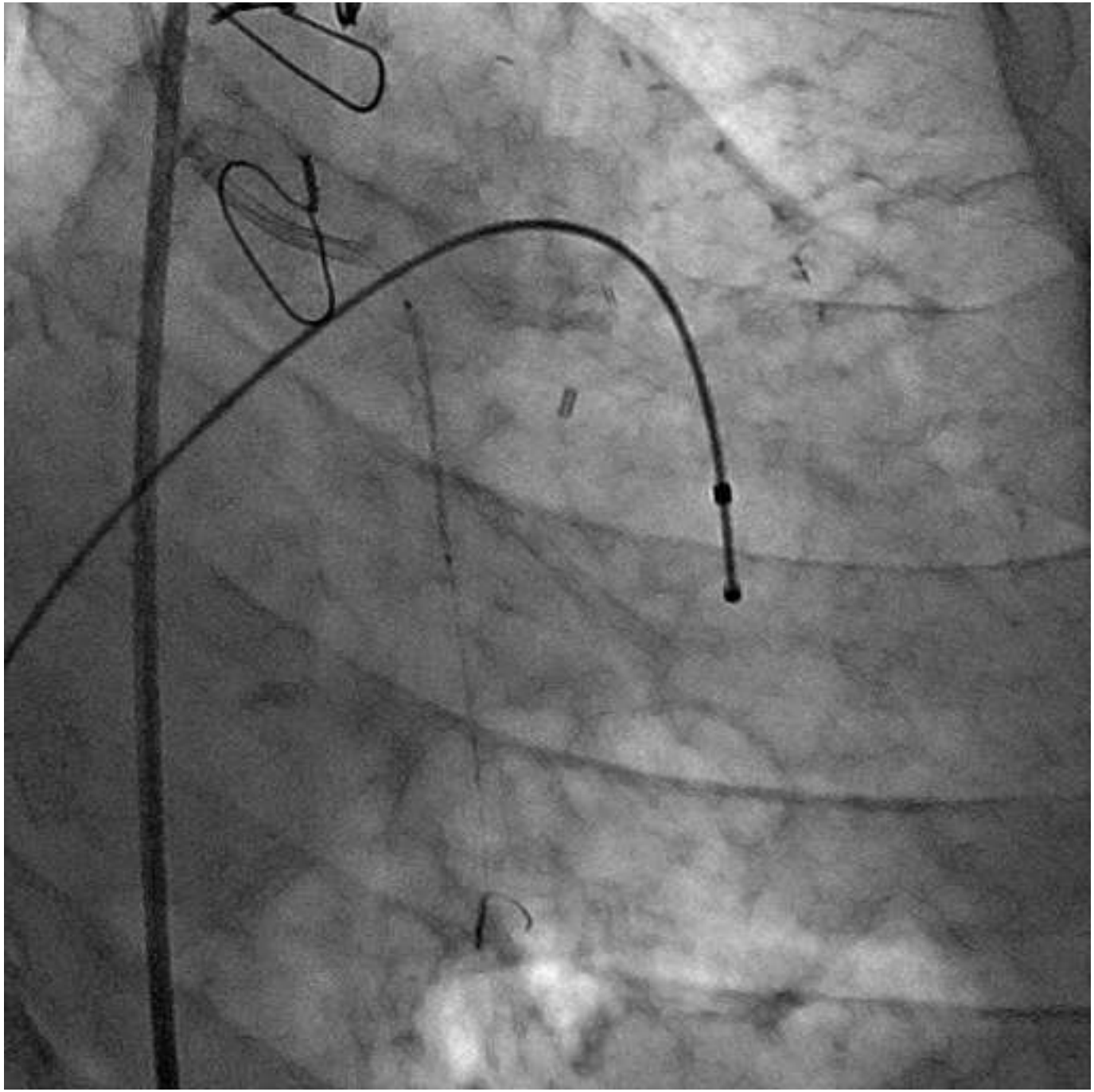

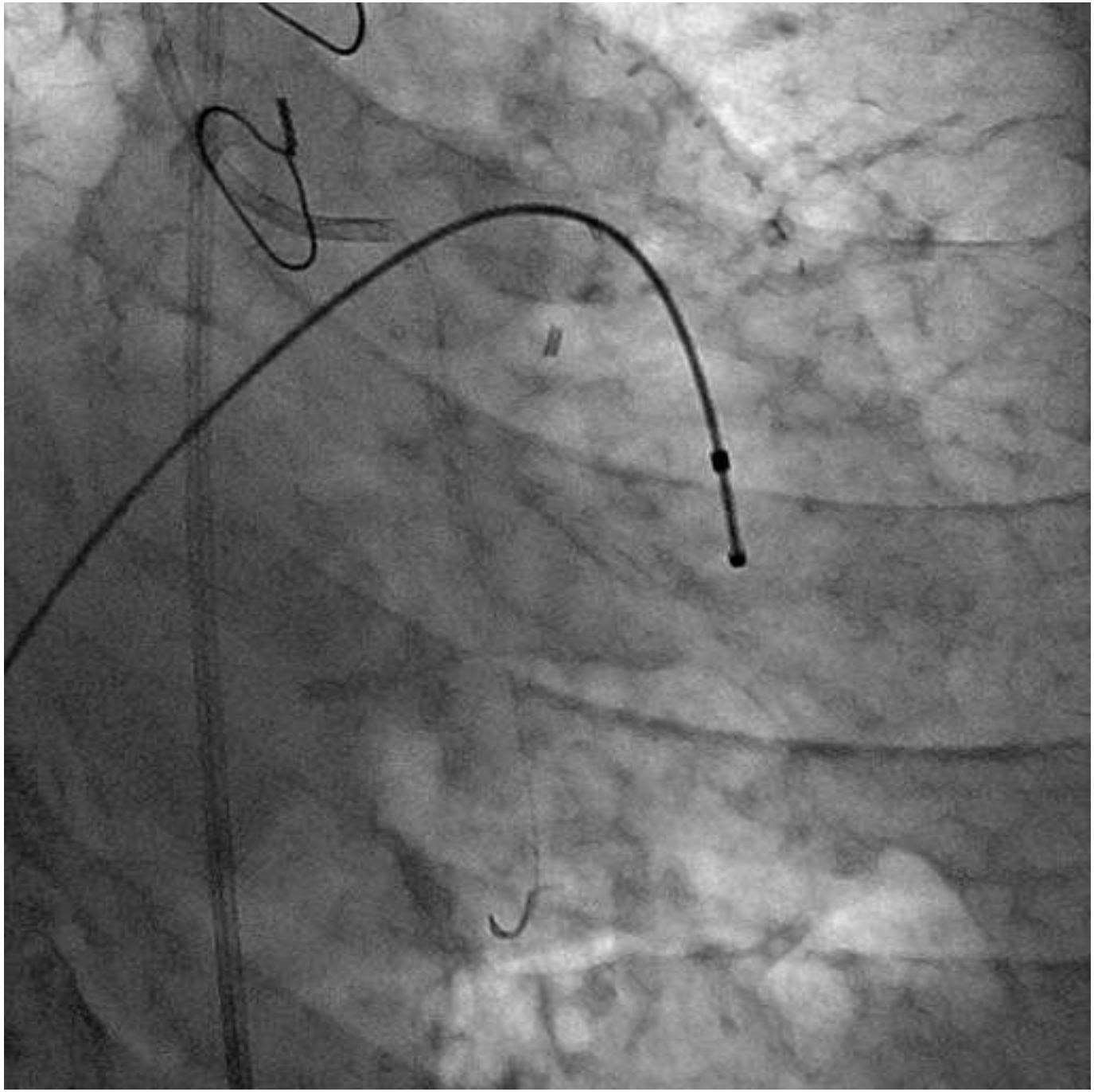

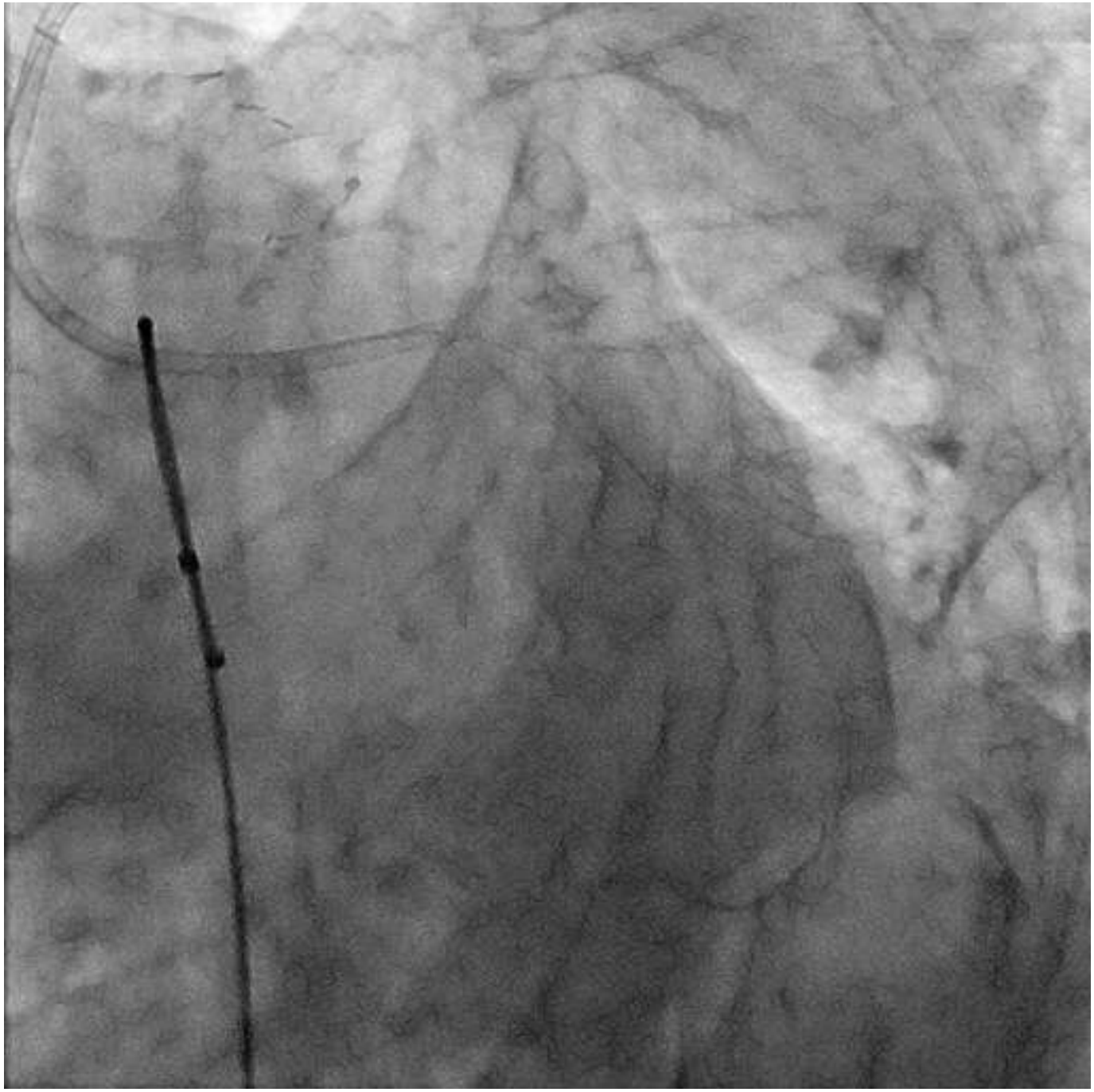

Conclusiones

- No se intervino el puente de MII a DA debido a que este territorio no tiene viabilidad
- El paciente evolucionó satisfactoriamente
- En pacientes con choque cardiogénico se debe intervenir todos los vasos con lesiones significativas, sin problema a utilizar rotablator en mas de un vaso en una sola intervención

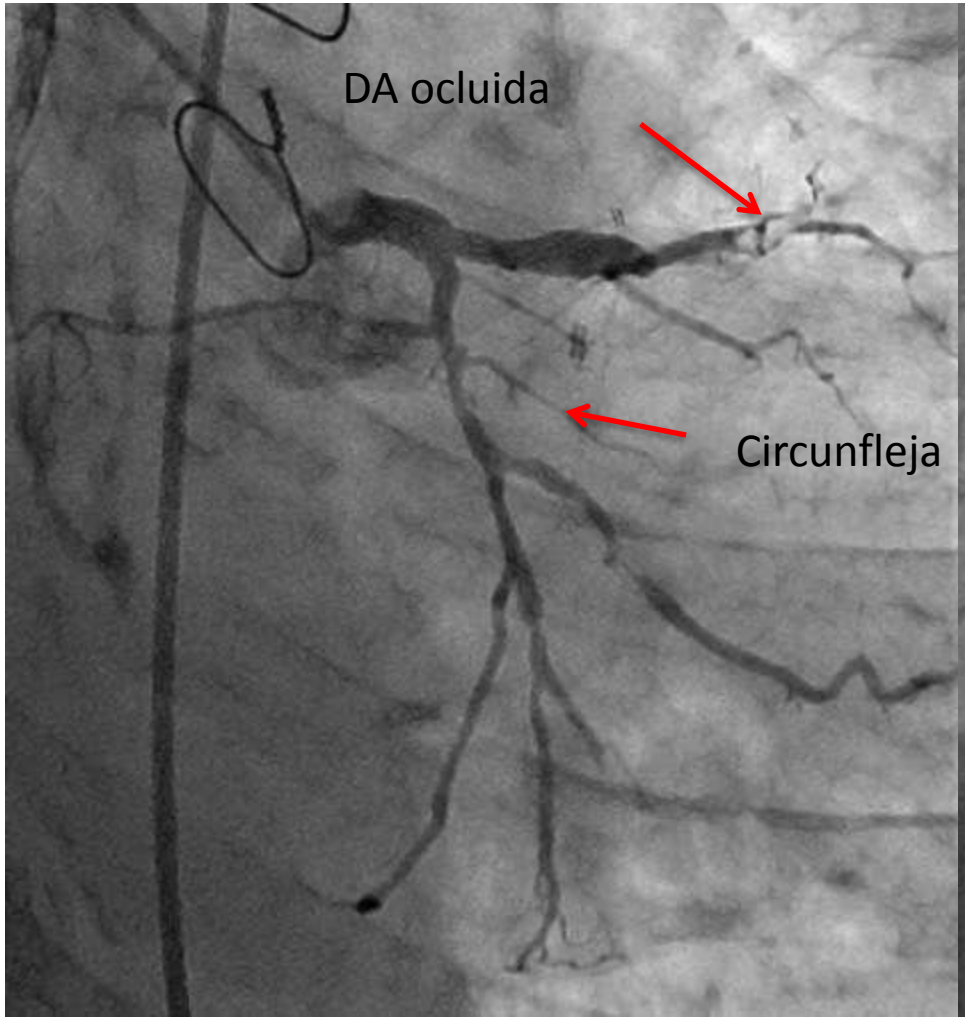
DA ocluida
Circunfleja

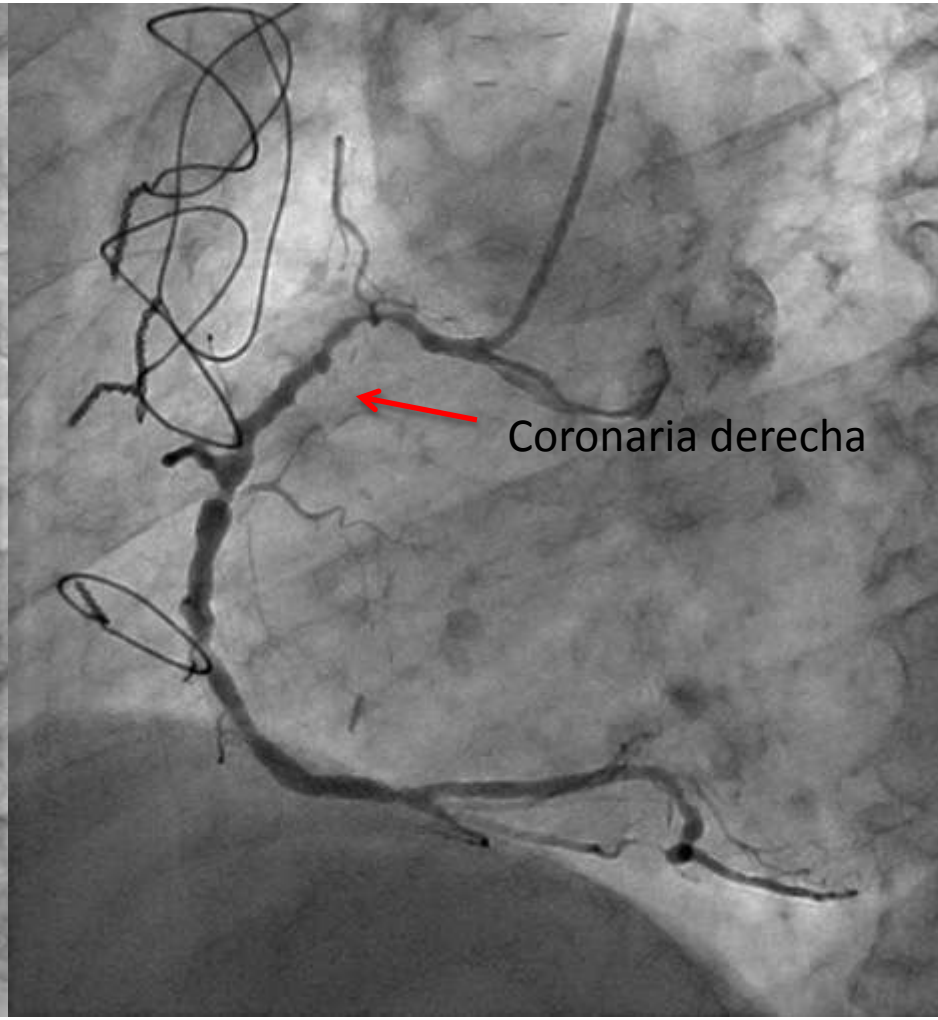
Coronaria derecha

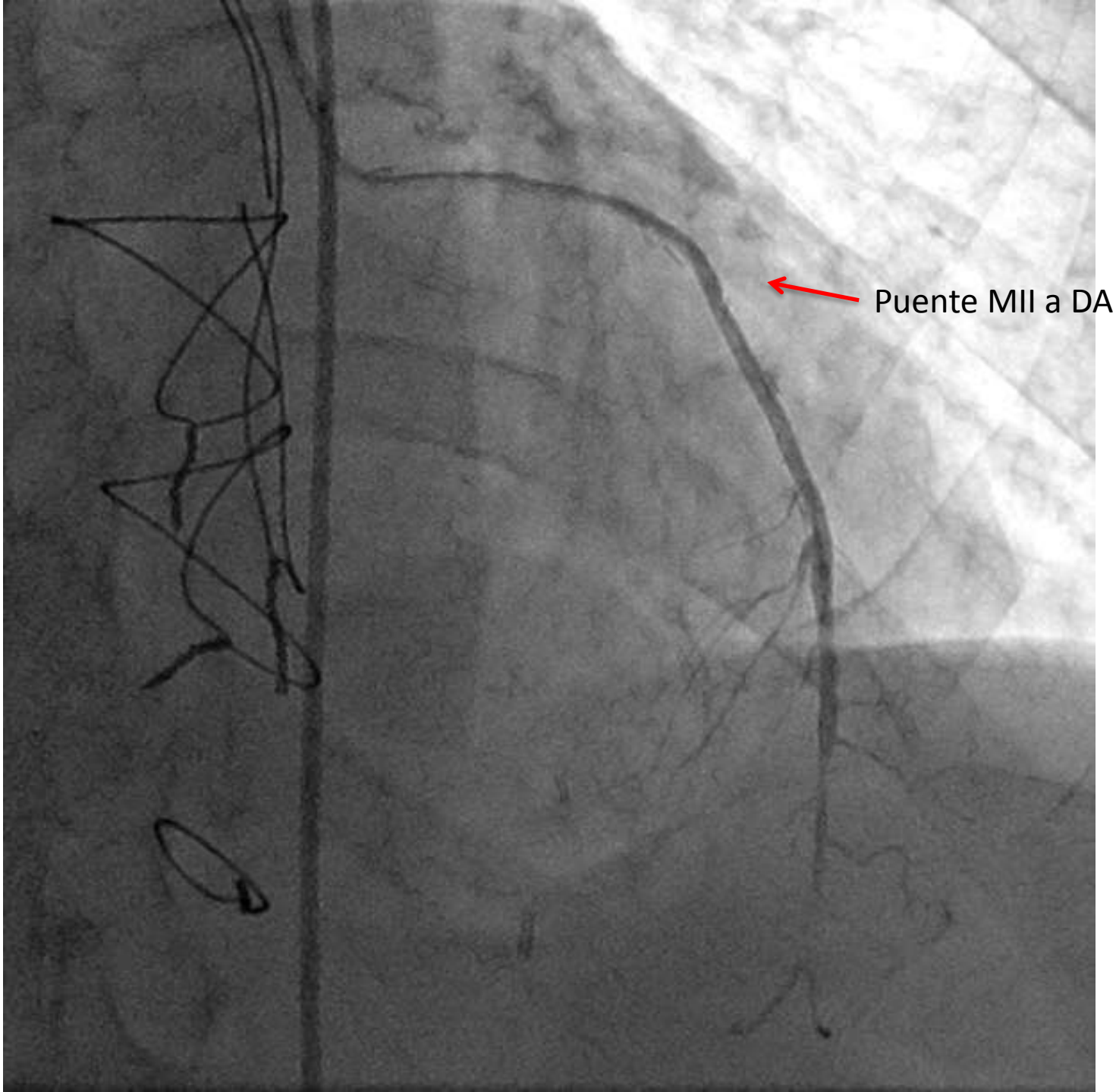
Puente MII a DA

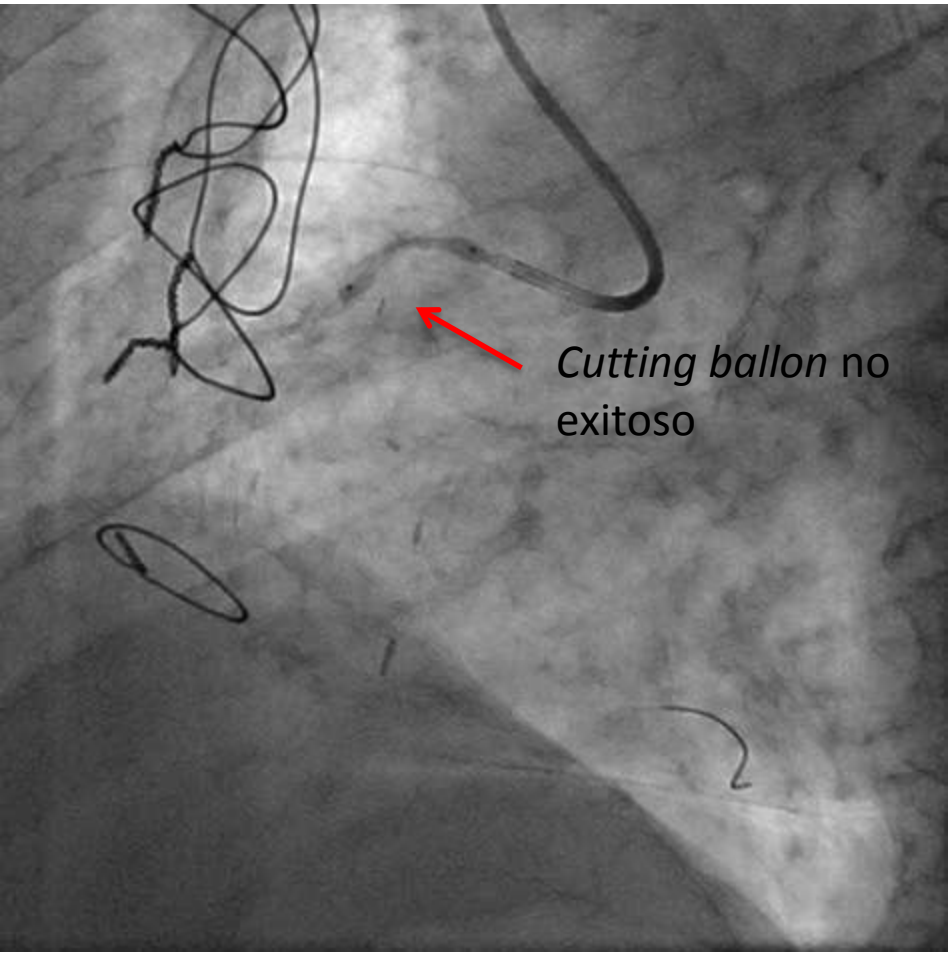
Cutting ballon no exitoso

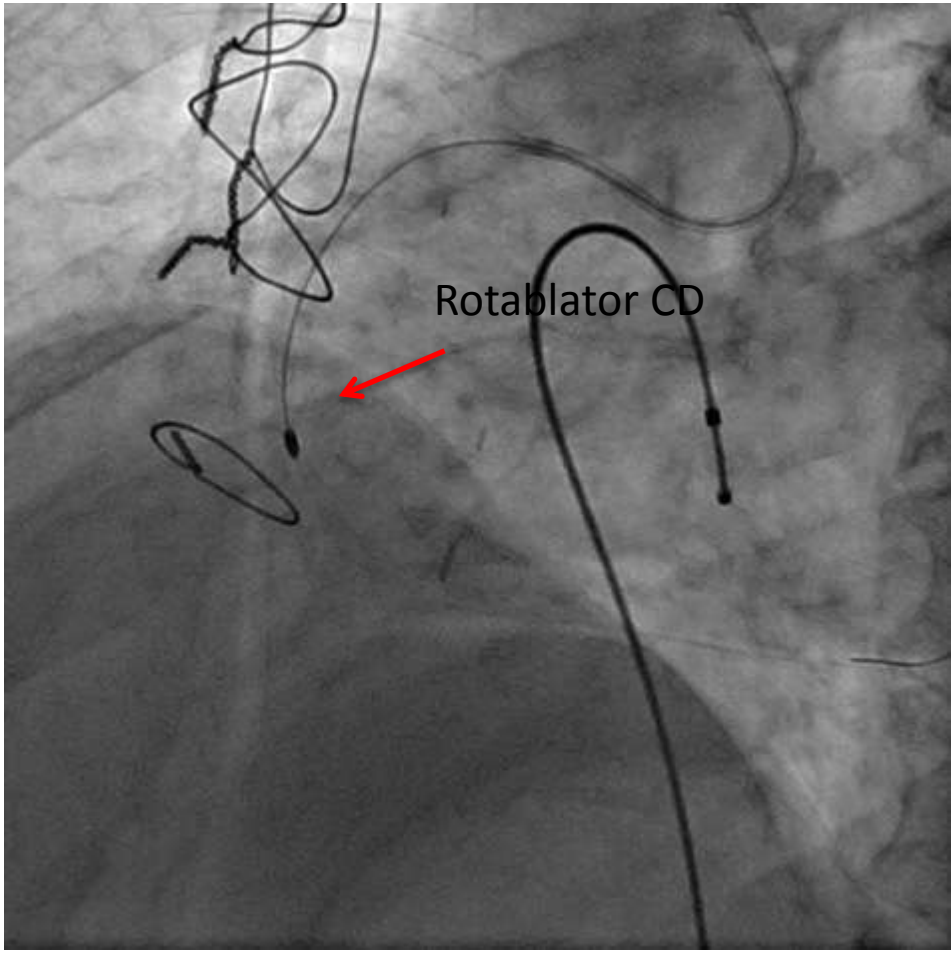
Rotablator CD

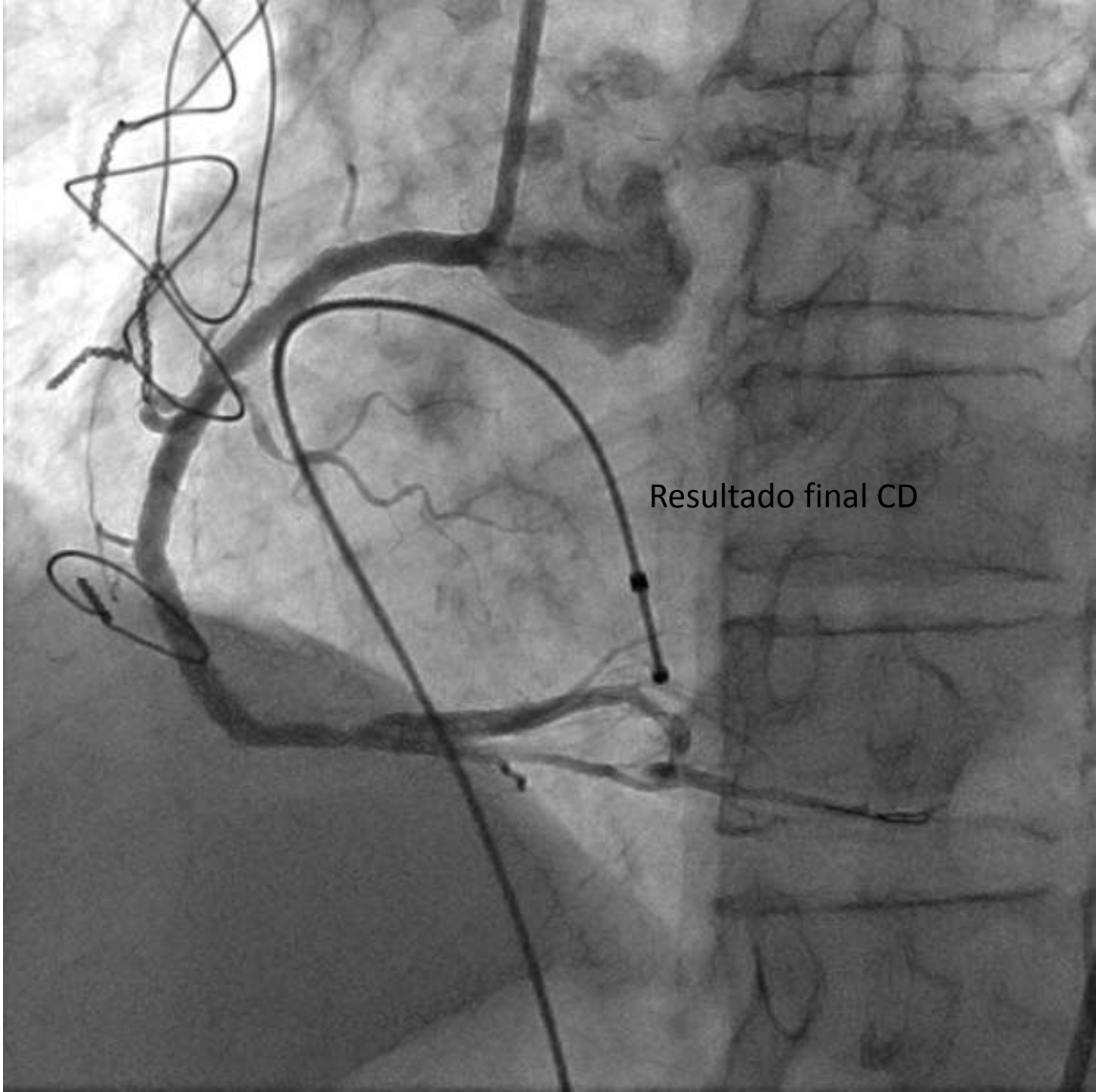
Resultado final CD

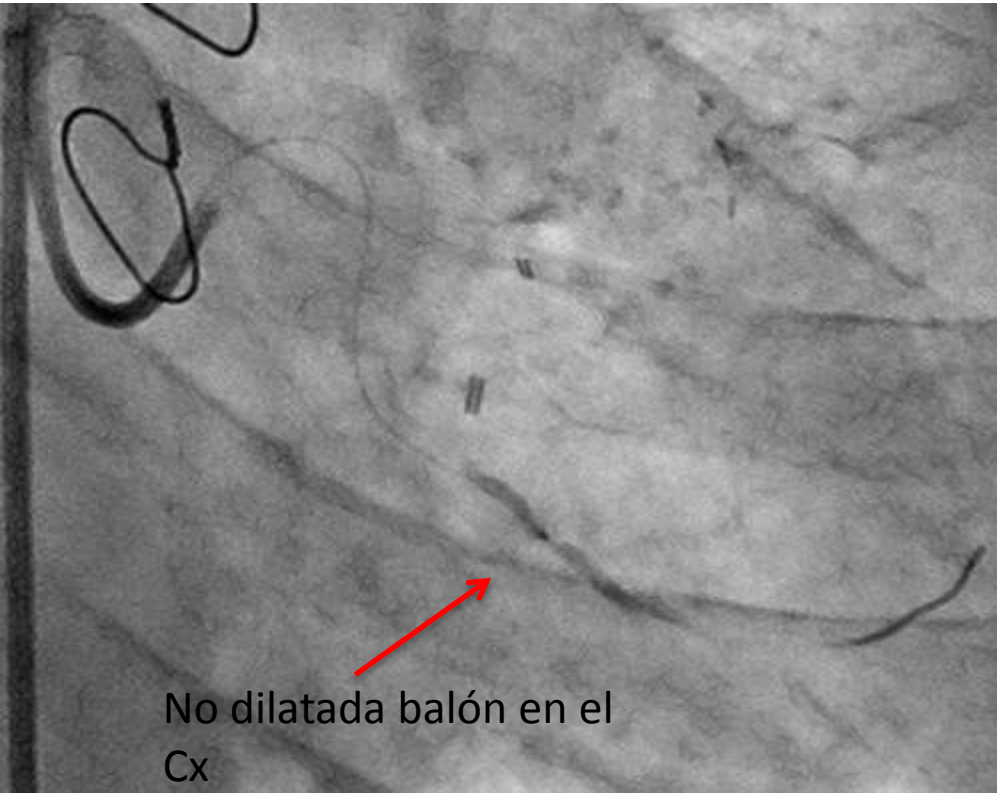
No dilatada balón en el
Cx

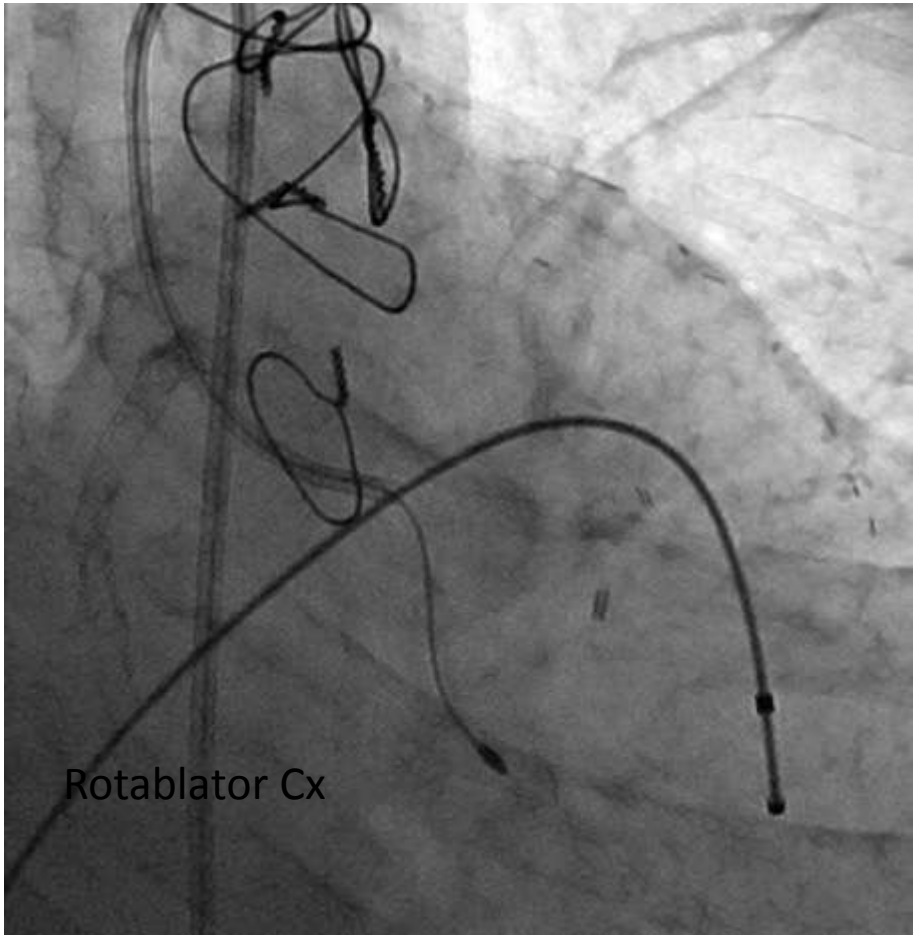
Rotablator Cx

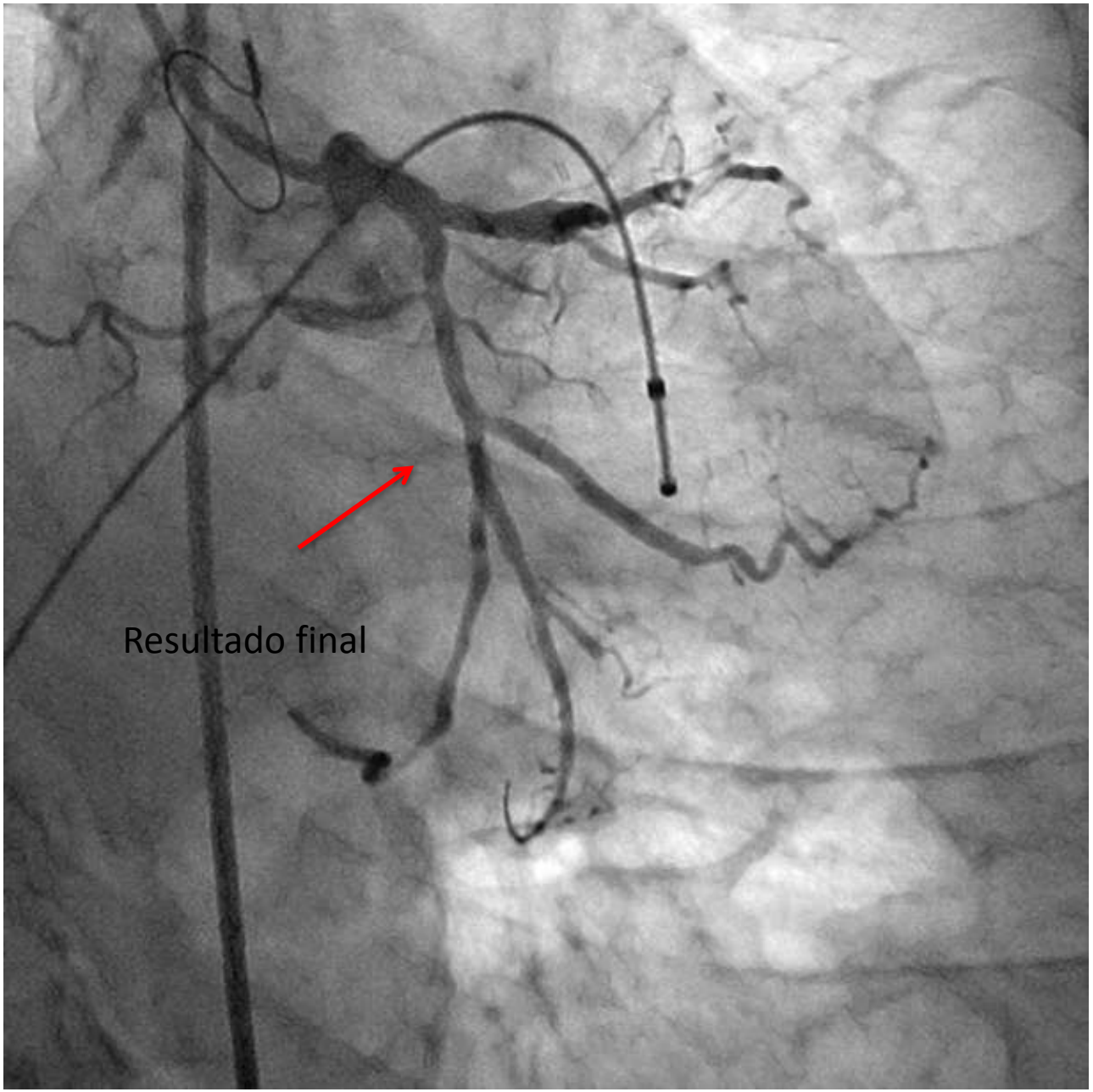
Resultado final