



Utilidad de la ATC en la Cardiología Intervencionista

Dr. Gabriel Maluenda
Hospital Clínico San Borja Arriaran/Universidad de Chile
Clínica Alemana, Santiago

TEMARIO

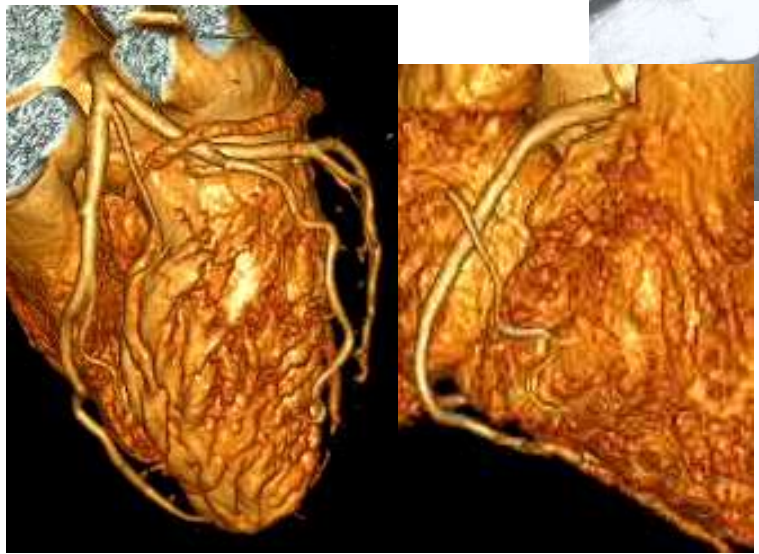
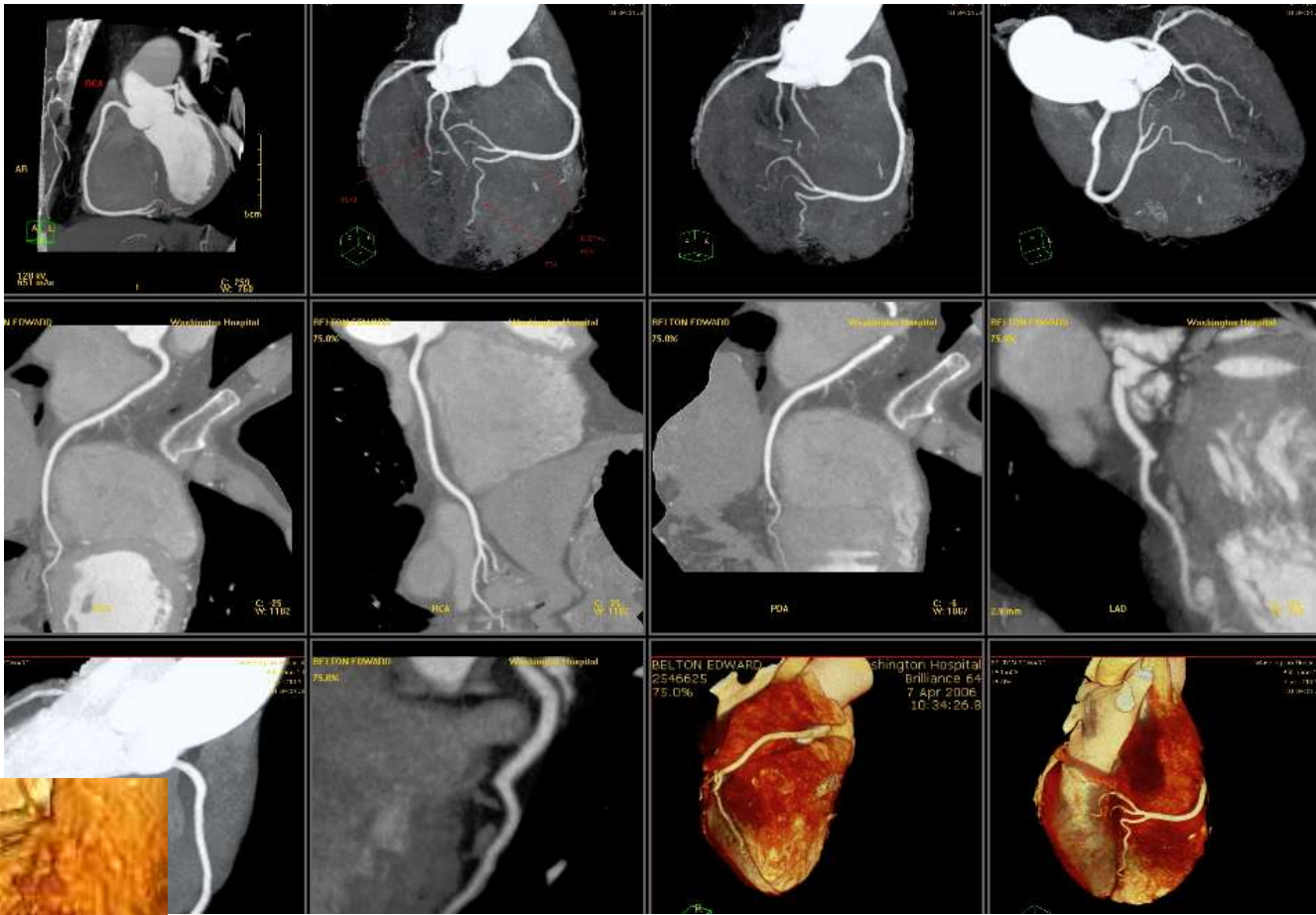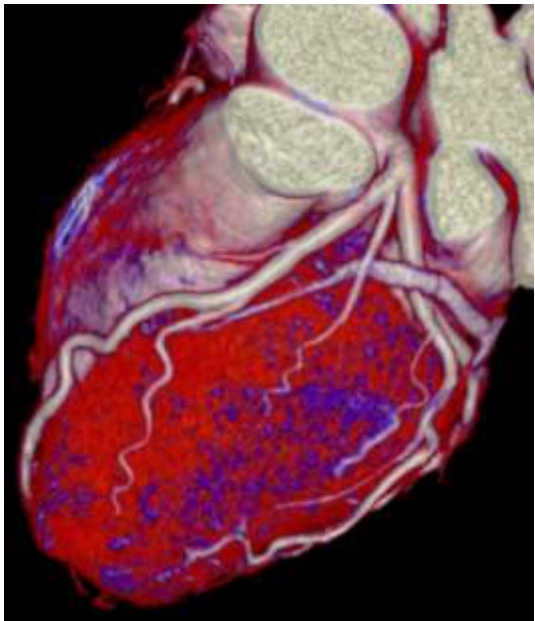- VENTAJAS ANGIO-TOMOGRFIA CARDIACA (ATC)
- INDICACIONES APROPIADAS
“appropriateness criteria”
- ROL EN DOLOR TORACICO AGUDO
- ROL EN OCLUSIONES CORONARIAS CRÓNICAS
- ROL EN REEMPLAZO VALVULAR AORTICO PERCUTANEO

VENTAJAS

- Sensibilidad y especificidad entre 95-99% en pacientes con coronarias normales
- Elevado VPN, permite excluir enfermedad coronaria (pacientes de riesgo bajo/intermedio)

ATC evita estudio invasivo en:

- Dolor torácico persistente de etiología no aclarada
- Test no invasivos no concluyentes
- Pacientes de riesgo bajo/intermedio
- ECG no interpretable
- Paciente no ejercitable
- Pacientes asintomáticos de alto riesgo
- Miocardiopatía



Ejemplos estudios normales

Criterios de indicaciones apropiadas

Journal of the American College of Cardiology
© 2010 by the American College of Cardiology Foundation
Published by Elsevier Inc.

Vol. 56, No. 22, 2010
ISSN 0735-1097/\$36.00
doi:10.1016/j.jacc.2010.07.005

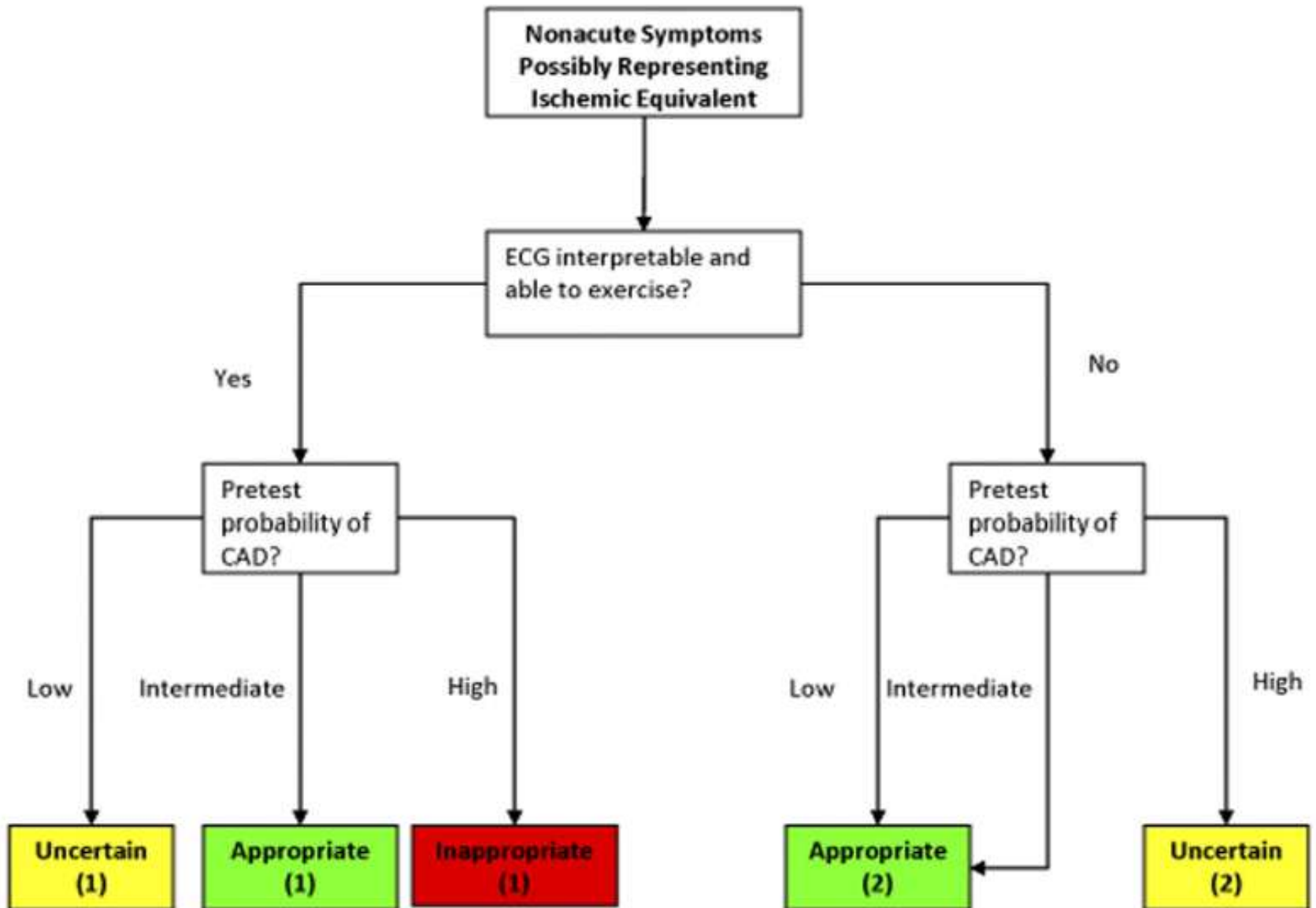
APPROPRIATE USE CRITERIA

ACCF/SCCT/ACR/AHA/ASE/ASNC/NASCI/SCAI/SCMR 2010 Appropriate Use Criteria for Cardiac Computed Tomography

A Report of the American College of Cardiology Foundation Appropriate Use Criteria Task Force, the Society of Cardiovascular Computed Tomography, the American College of Radiology, the American Heart Association, the American Society of Echocardiography, the American Society of Nuclear Cardiology, the North American Society for Cardiovascular Imaging, the Society for Cardiovascular Angiography and Interventions, and the Society for Cardiovascular Magnetic Resonance

Indicaciones Apropriadas

- Dolor torácico, probabilidad **pretest baja-intermedia**, ECG no interpretable o incapacidad para ejercitar
- Puentes coronarios en pacientes sintomáticos
- Stents en troco coronario izquierdo
- Anatomía previo a re-operación cardiaca
- Sospecha de anatomía coronaria anómala
- Falla cardiaca de reciente inicio
- Evaluación-descarte de disección/aneurisma aorta torácica y/o embolia pulmonar
- Masa-tumor cardiaco, o afección pericárdica cuando eco y RNM técnicamente limitados



Indicaciones Inapropiadas

Pacientes sintomáticos con:

- Probabilidad pre-test alta de EC
- Elevación de ST o enzimas positivas
- Isquemia en prueba de stress

Contraindicaciones

Fibrilación auricular

Bigeminismo, trigeminismo, bloqueo AV de alto grado

Asma severo

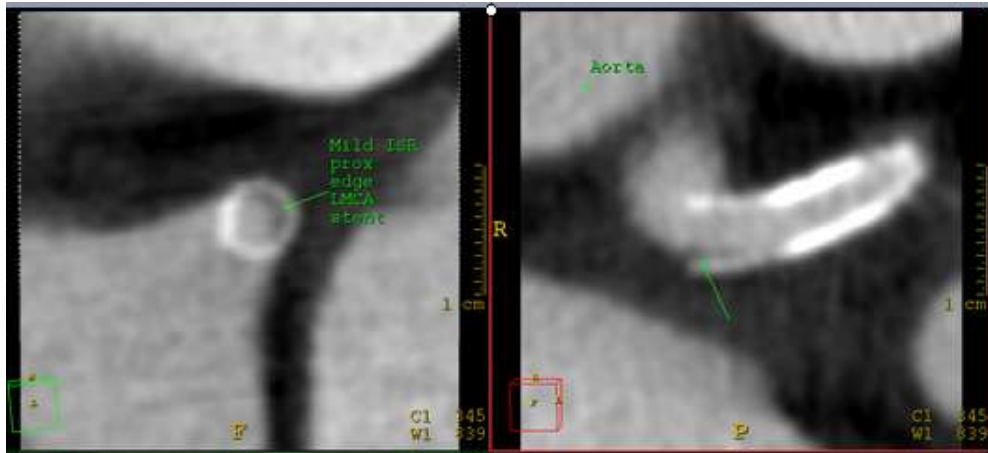
Calcificación coronaria severa (SC > 400 UH)

Falla renal (creatinina > 1.8)

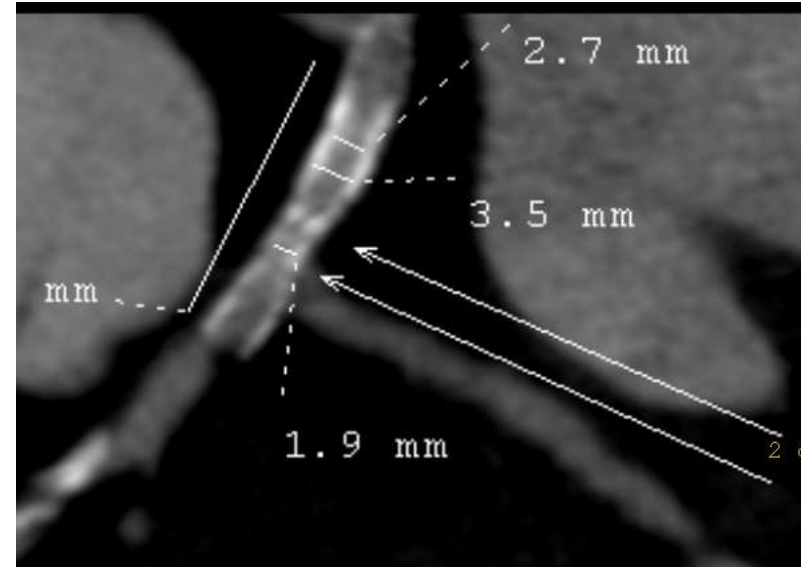
Reacción alérgica a contraste severa conocida

Obesidad mórbida (IMC > 40)

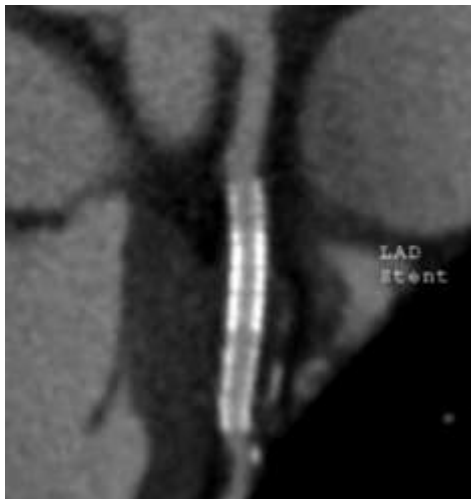Evaluación de stents > 3 mm



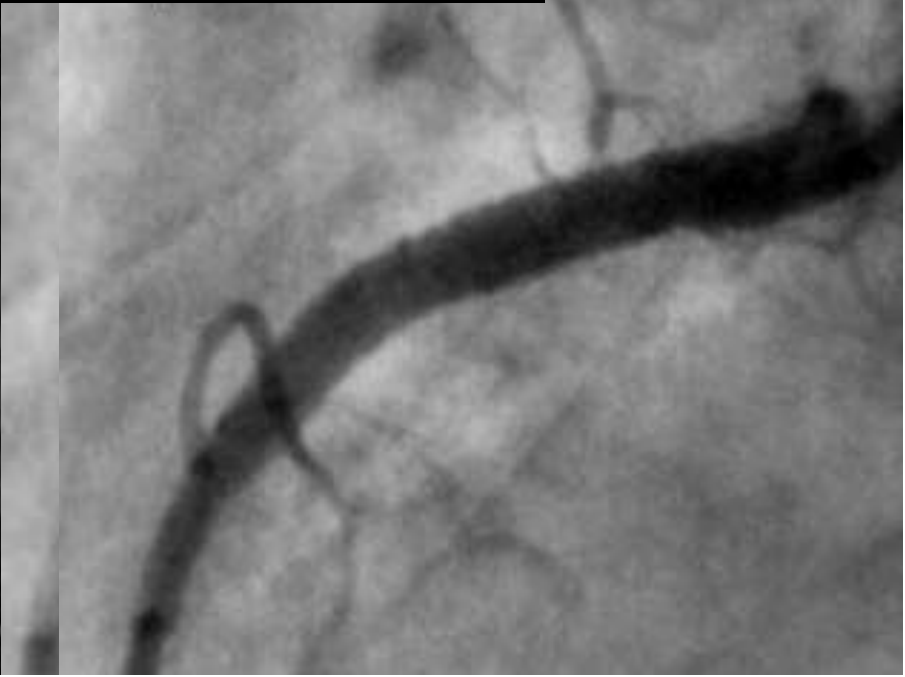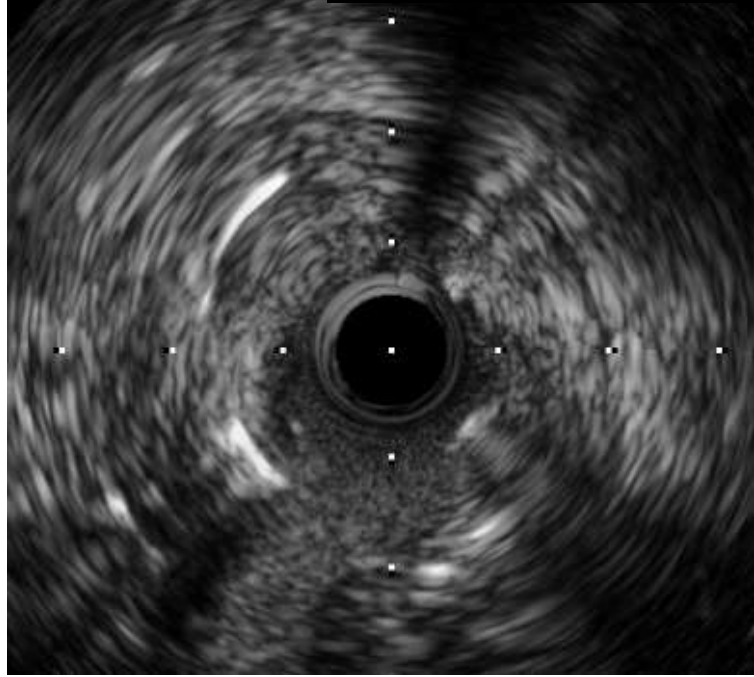
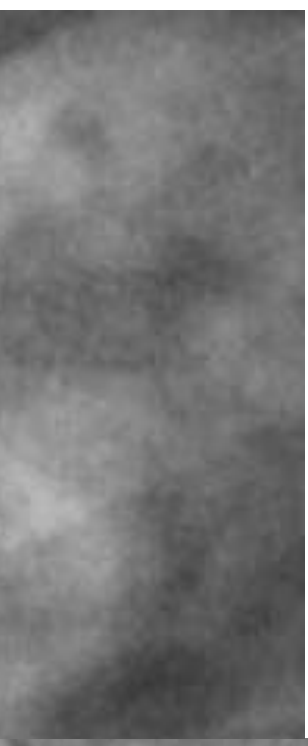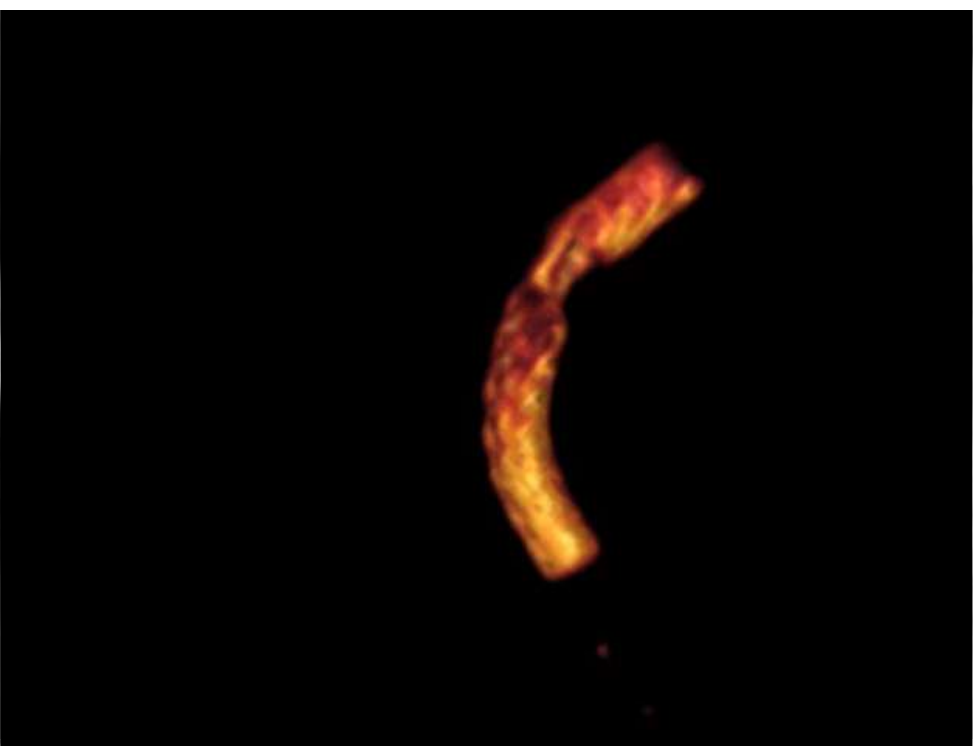
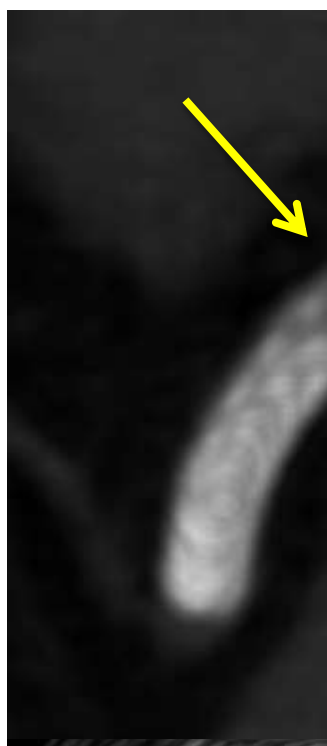
Restenosis leve de cabo proximal en TCI

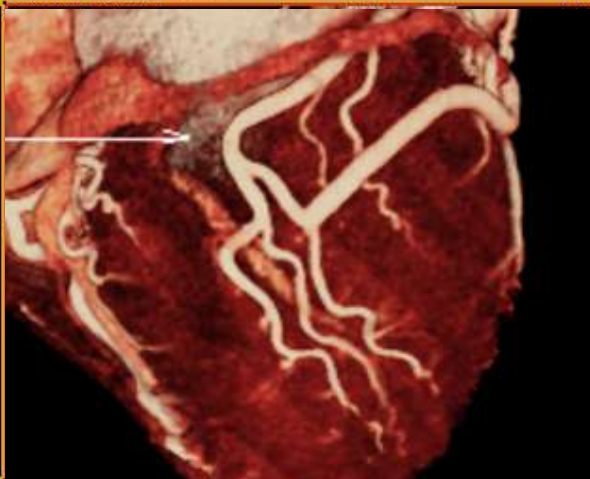
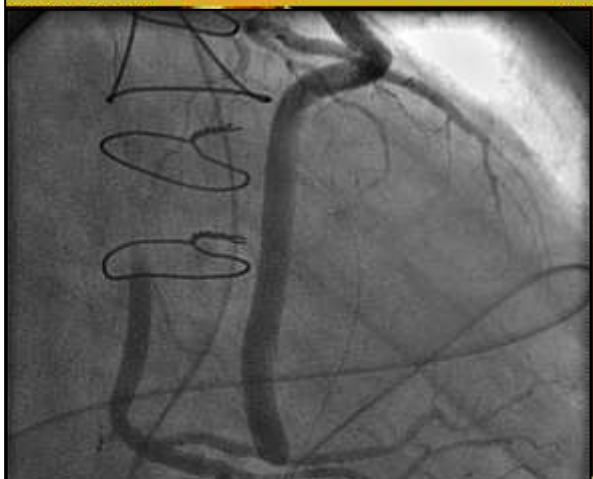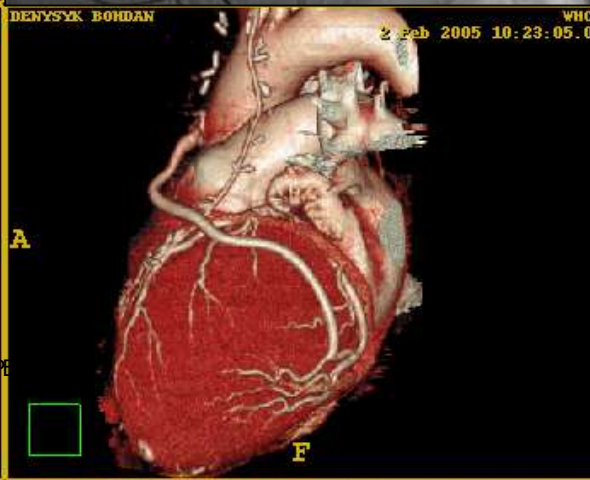
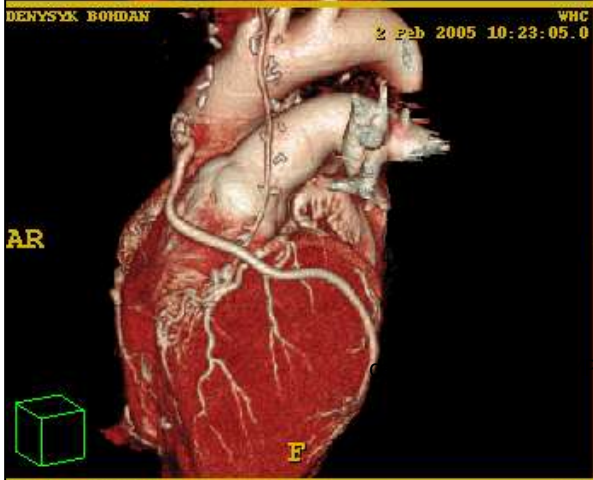
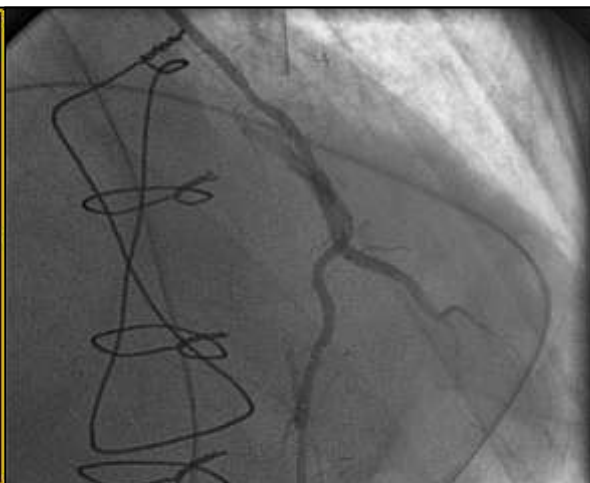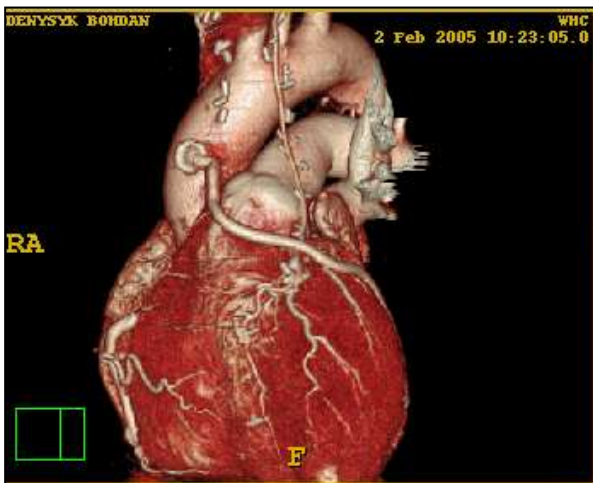


Stent subexpandido

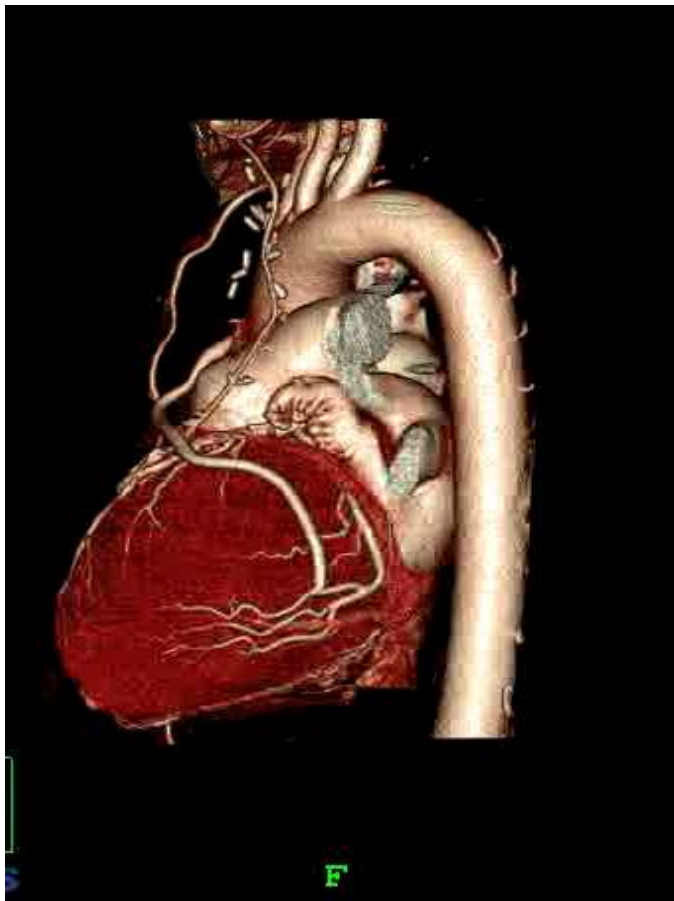


Stent permeable en ADA proximal

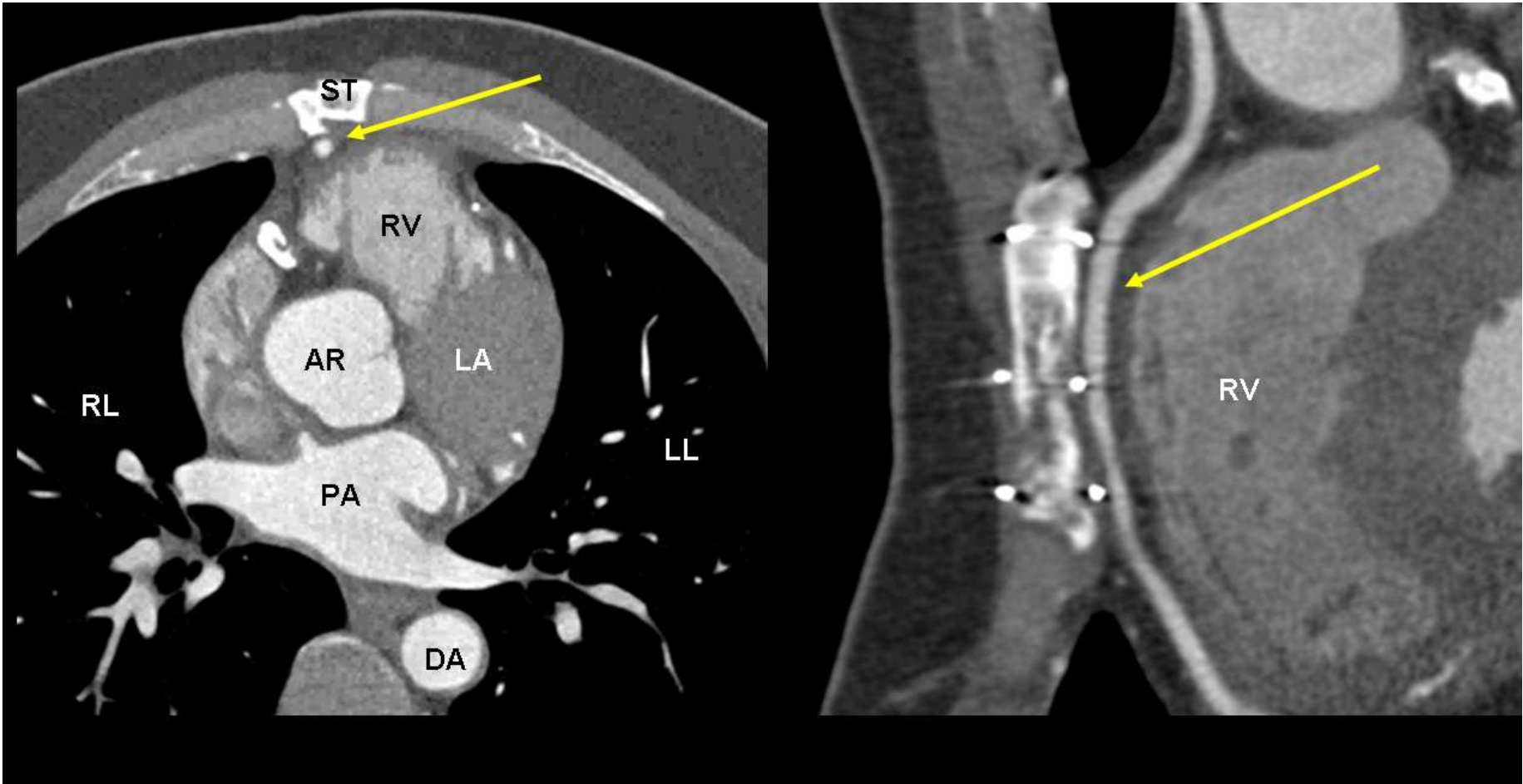




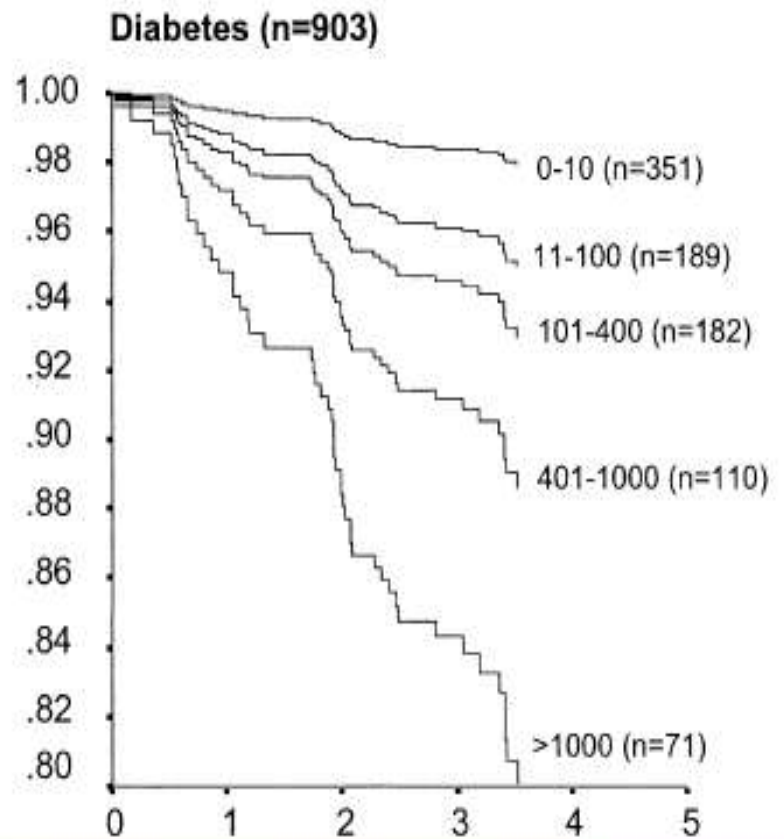
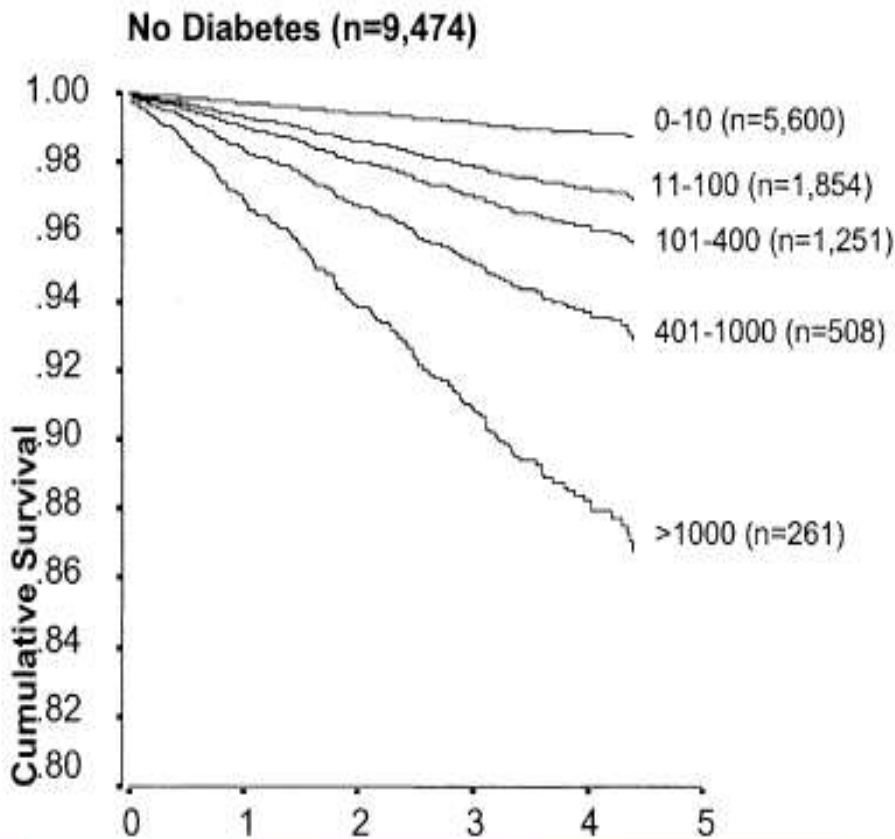
**Excelente método
para evaluar
permeabilidad de
puentes**



Caso alto riesgo de re-operación

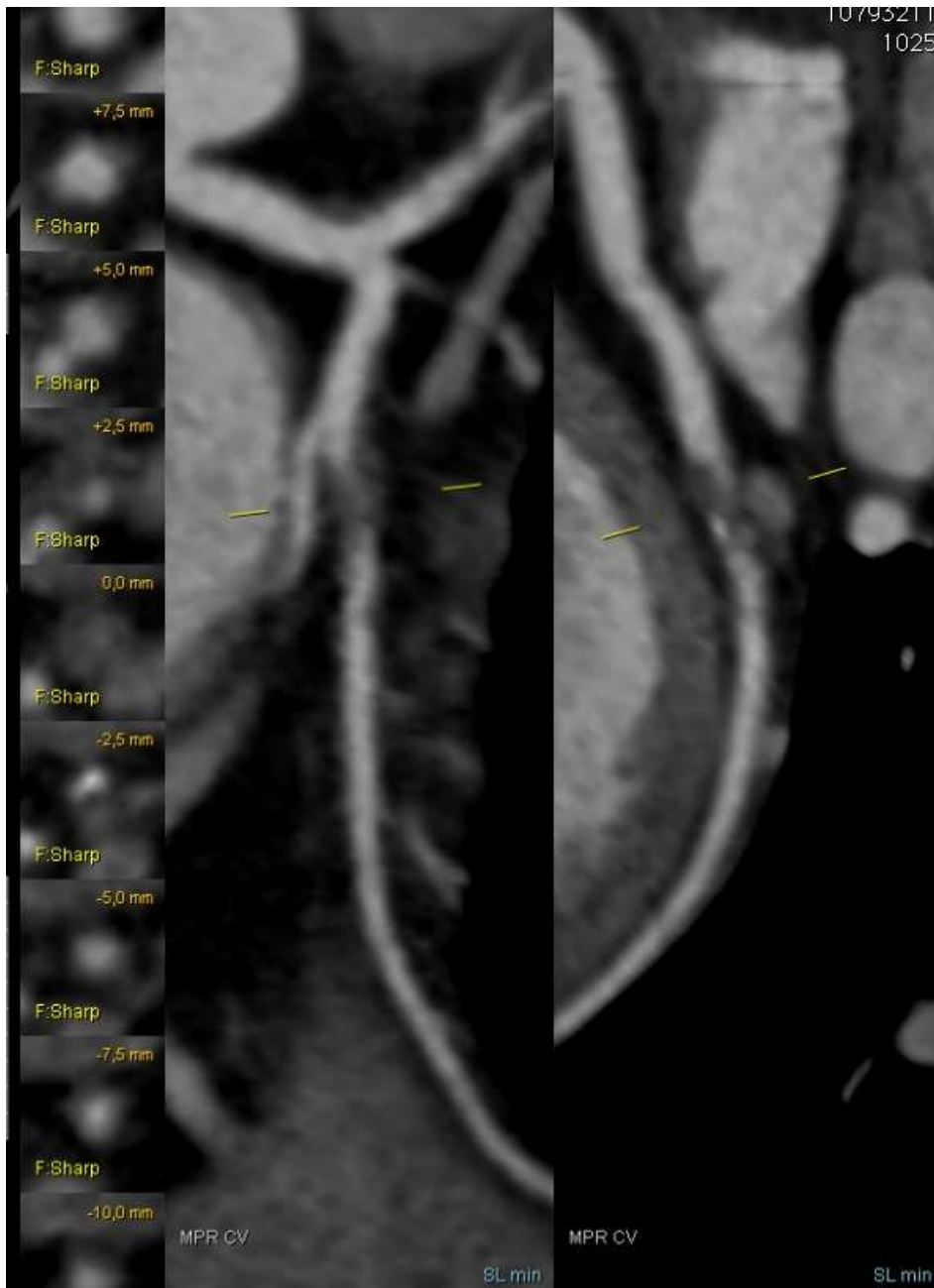


Score Calcio & Mortalidad a 5 años



DOLOR TORACICO AGUDO

- **«Triple rule out»** de condiciones con riesgo vital
 - Isquemia/infarto miocárdico
 - Disección aortica
 - Embolia pulmonar aguda
- **Adecuado** en pacientes de **riesgo bajo** para SCA, **enzimas/ECG negativas**
 - en que se prefiere descartar EC significativa
 - troponinas negativas <4-6 horas de evolución de síntomas



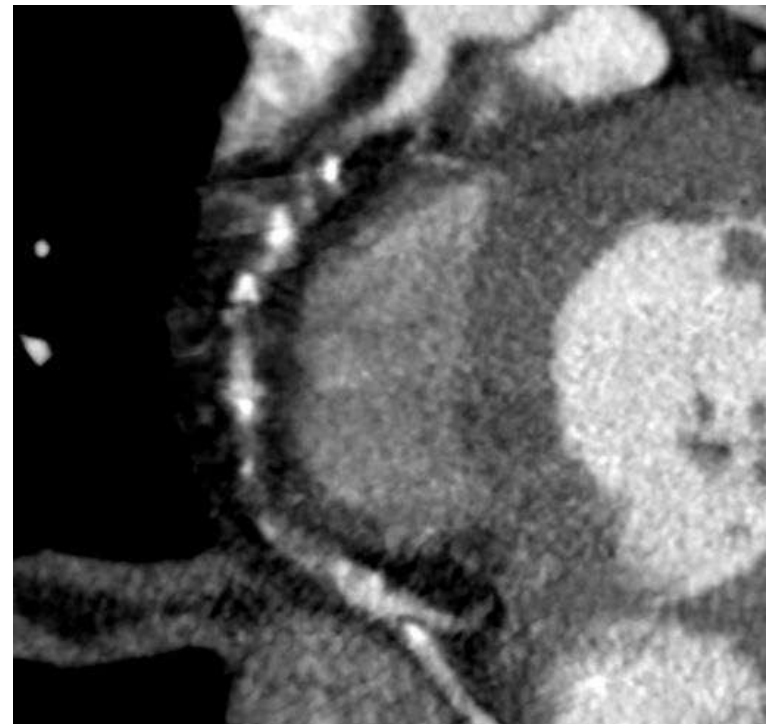
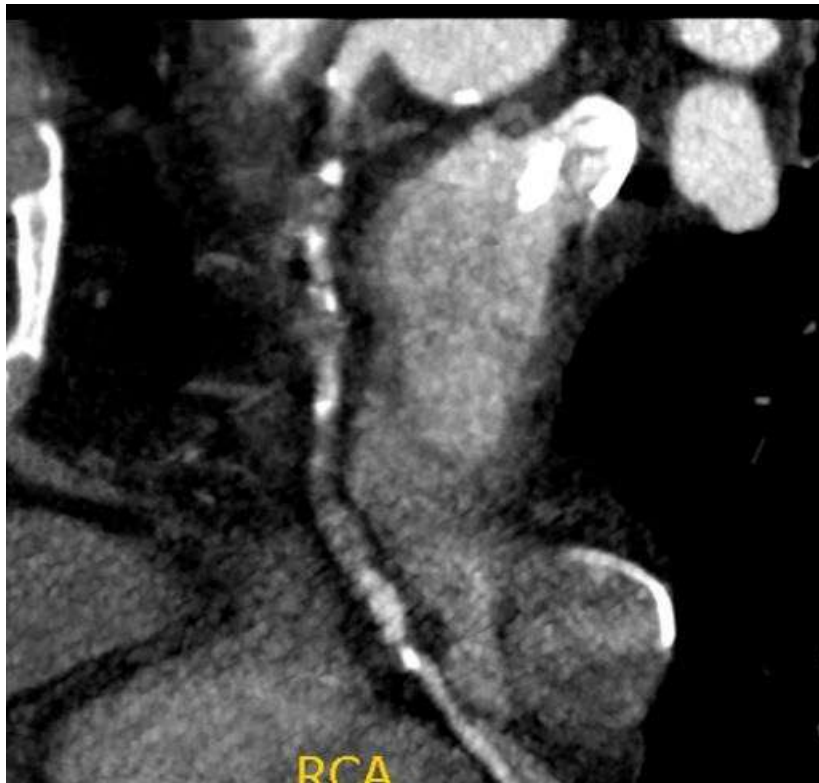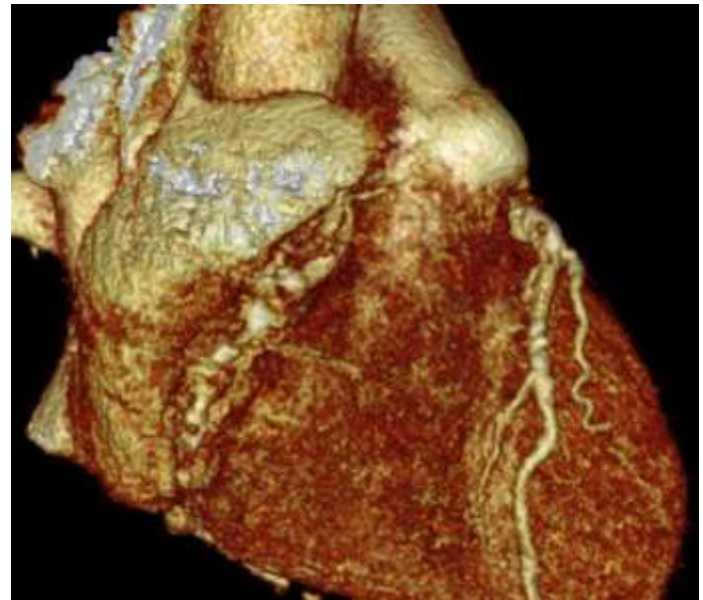
CASO SCA CX PROXIMAL

Paciente de 61 años
Tabaquismo
Dolor anginoso irradiado a
cuello de 30 minutos de
duración, que cede
espontáneamente.

ECG normal y Troponinas
iniciales negativas.

ACT: Lesión aguda en
Circunfleja proximal,
confirmada en coronariografía.

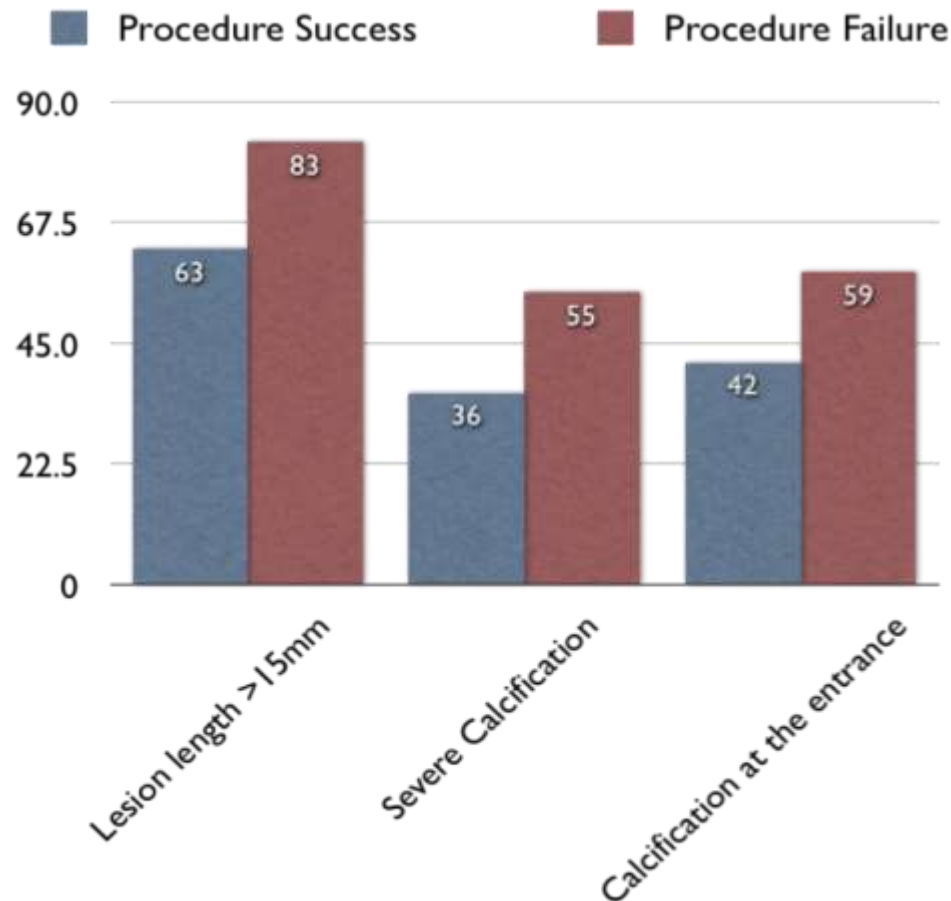
ATC coronario para guiar PTCA de oclusiones totales

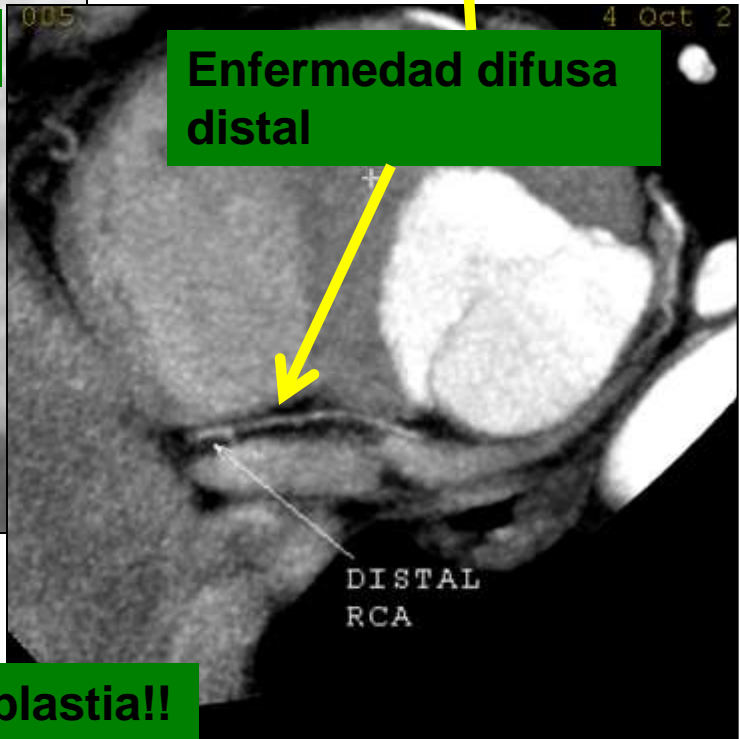
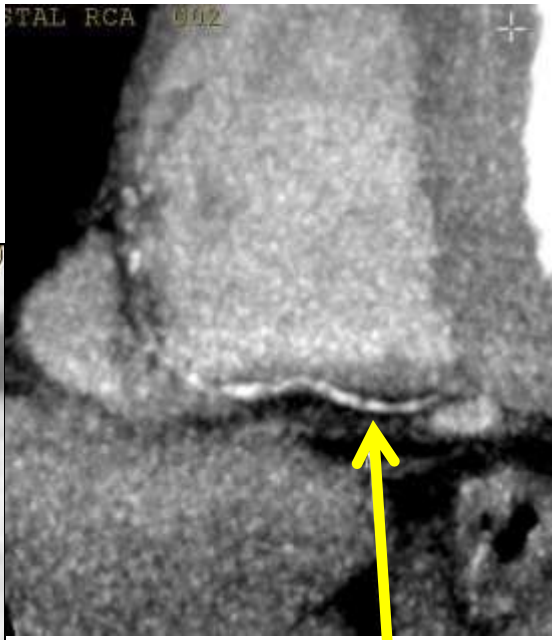
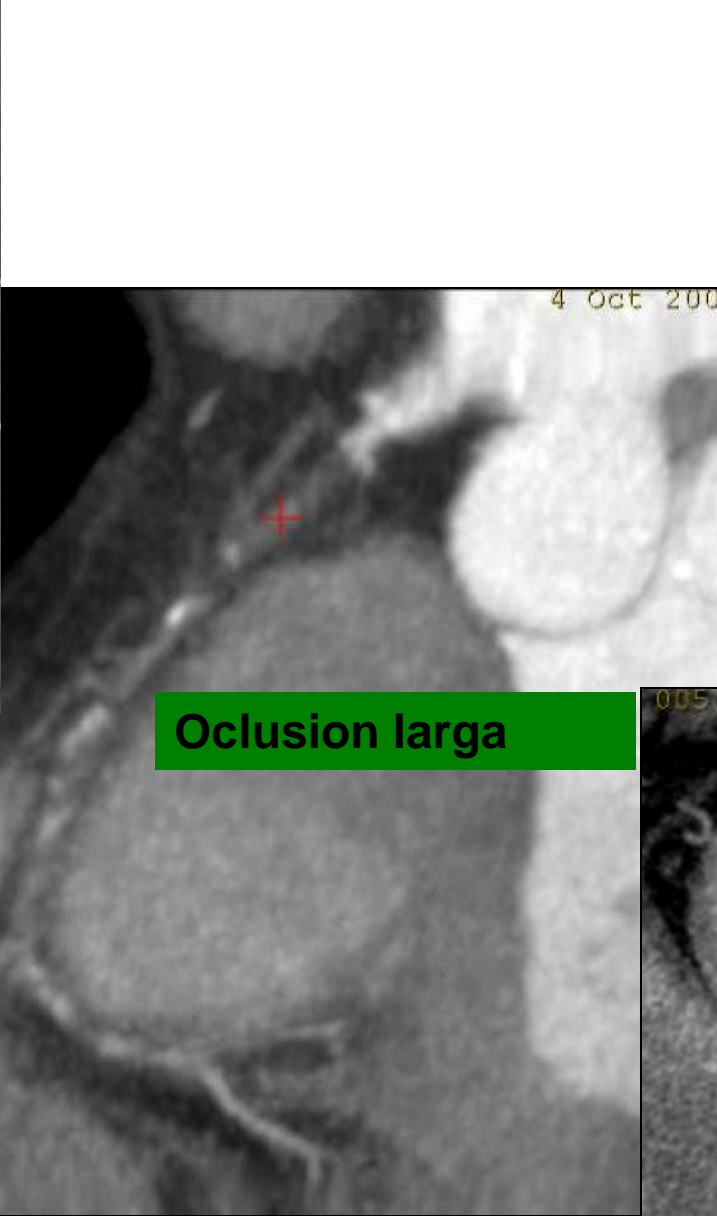


Utilidad de ATC en oclusiones totales

- Planificación de intervención
- Predicción de resultados de procedimiento
- Prevención de complicaciones
- Reducción de tiempo de procedimiento
contraste/radiación
- Integración de imágenes 3D a tiempo real
- Perfusión/viabilidad

Predictores de falla de intervención CTTO registry





ACD 100% proximal

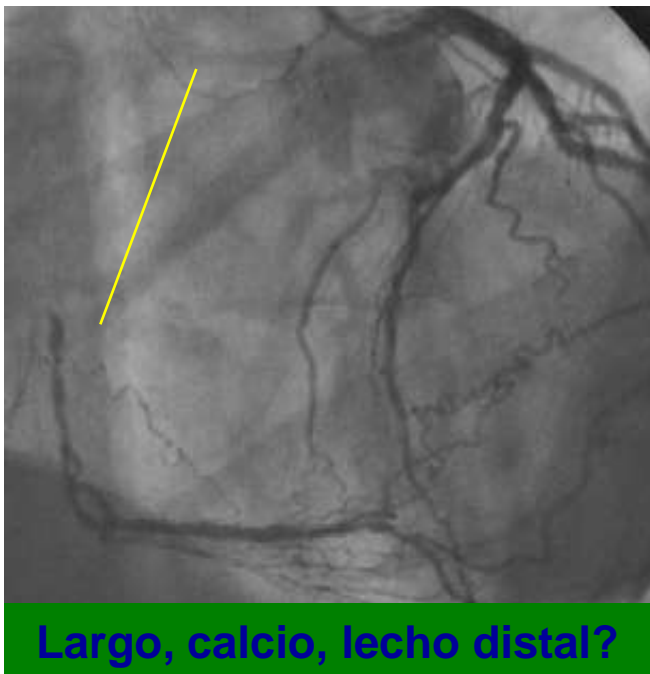
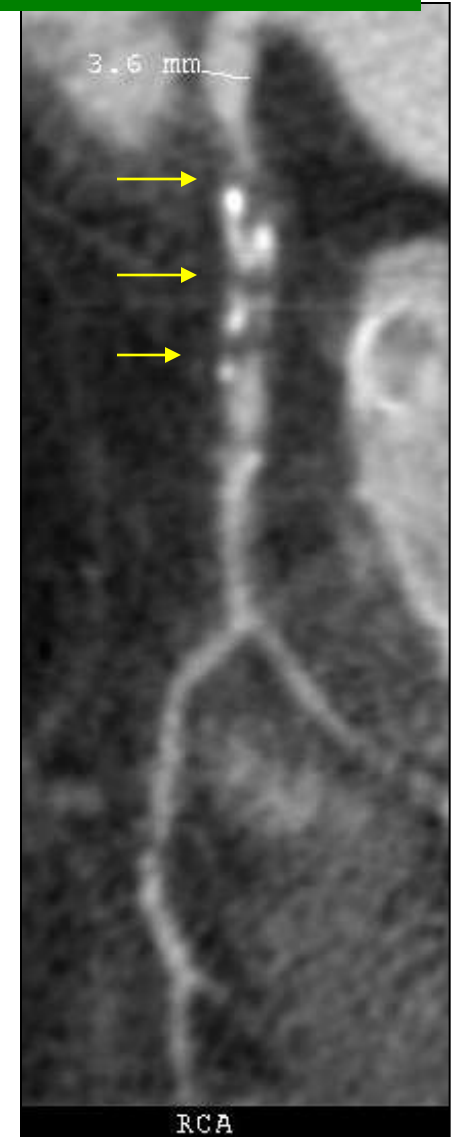
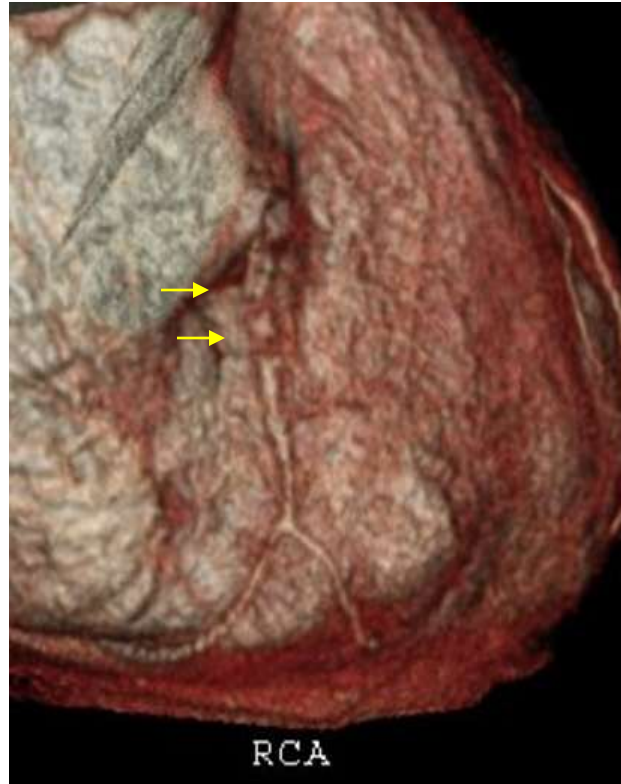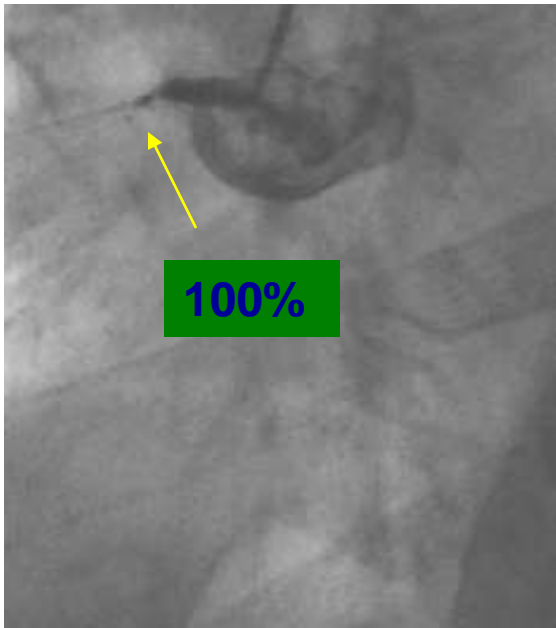
- Largo ?
- Calcio ?
- Lecho distal?

Oclusion larga

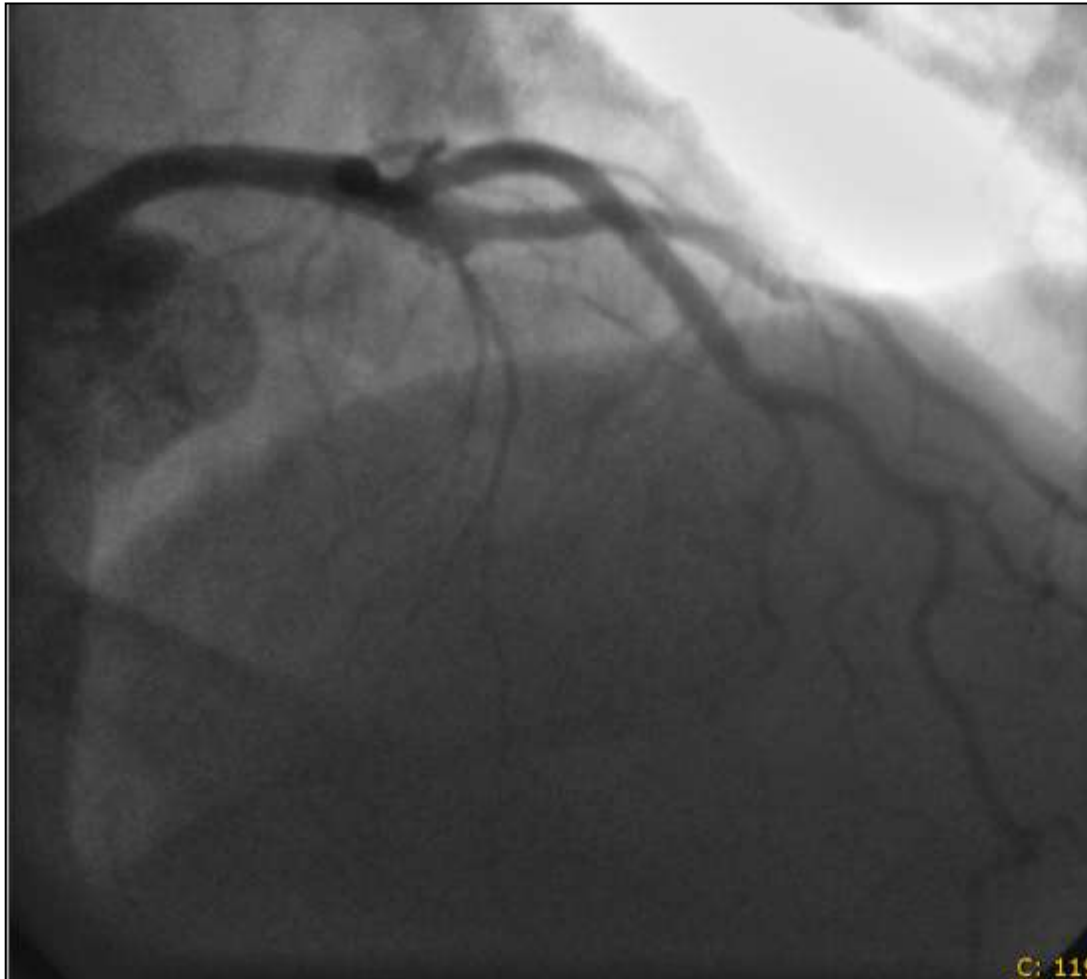Enfermedad difusa distal

NO buen candidato para angioplastia!!

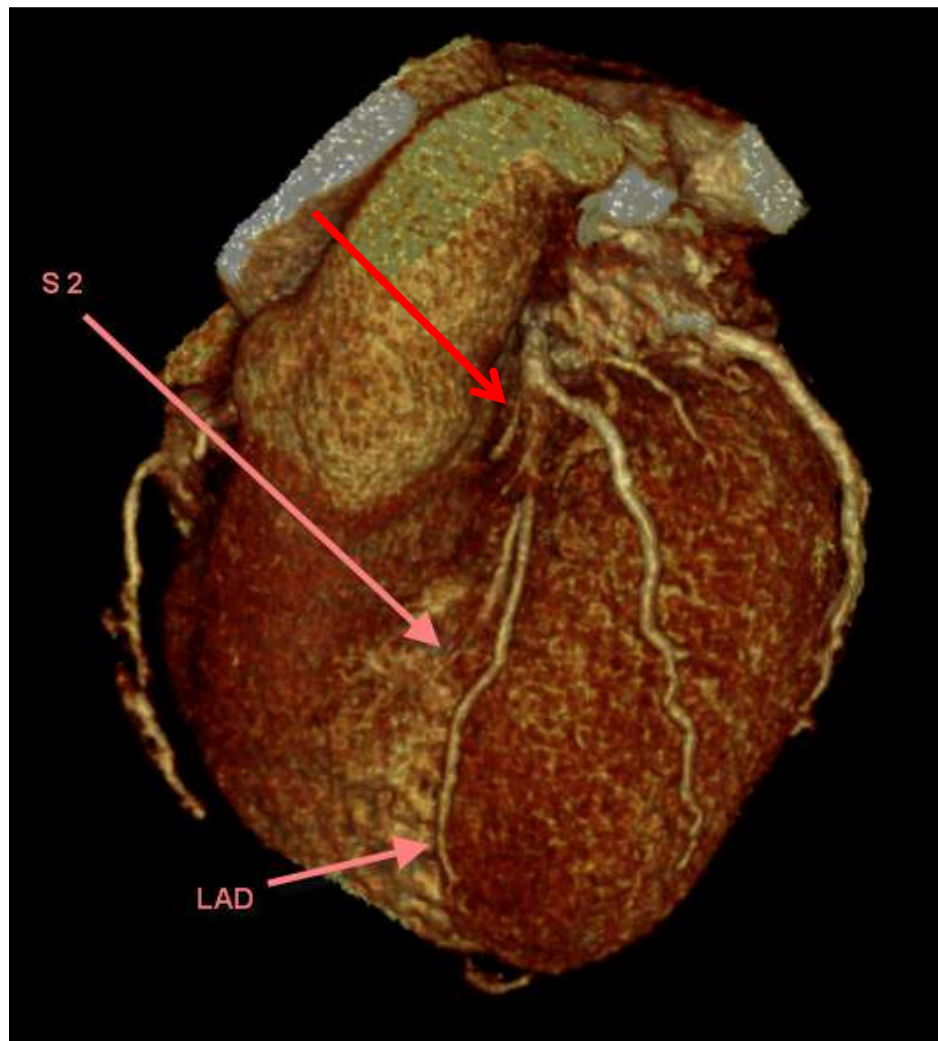
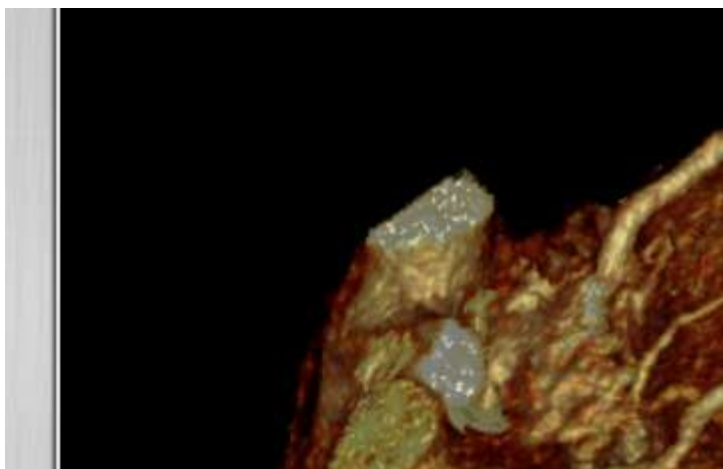
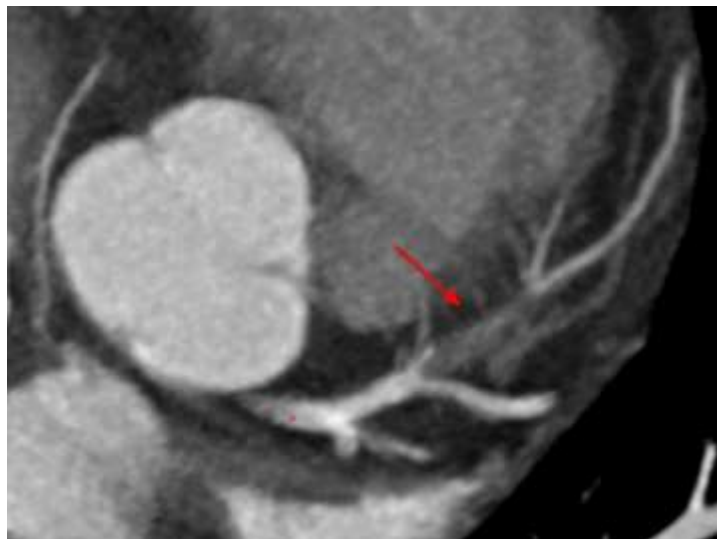
Oclusion corta, vaso de buen tamaño, calcificacion moderada

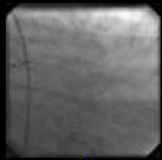


Oclusión total de ADA proximal

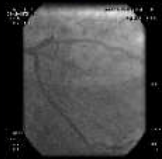


Oclusión corta no calcificada de ADA proximal





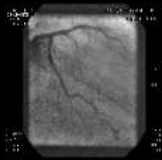
3



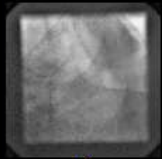4



5



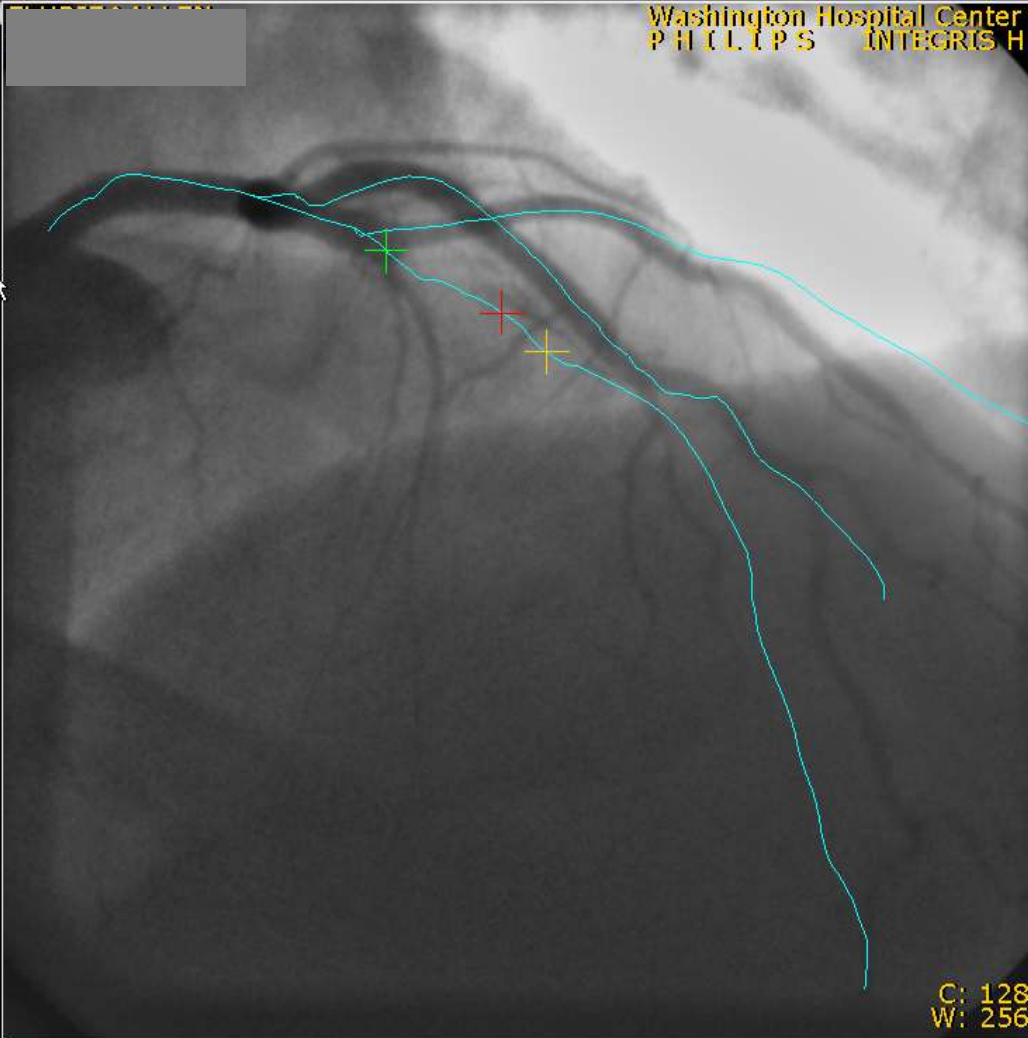
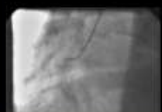
6



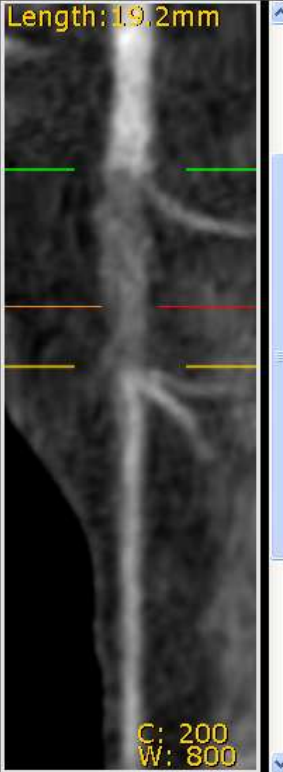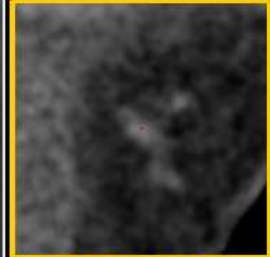
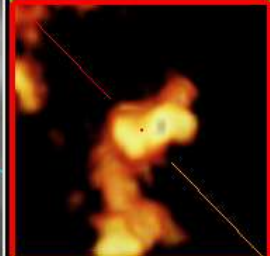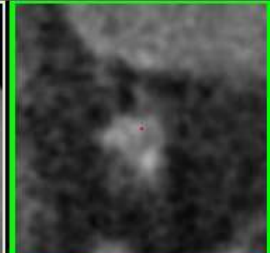
7



8



C: 128
W: 256



C: 200
W: 800

R

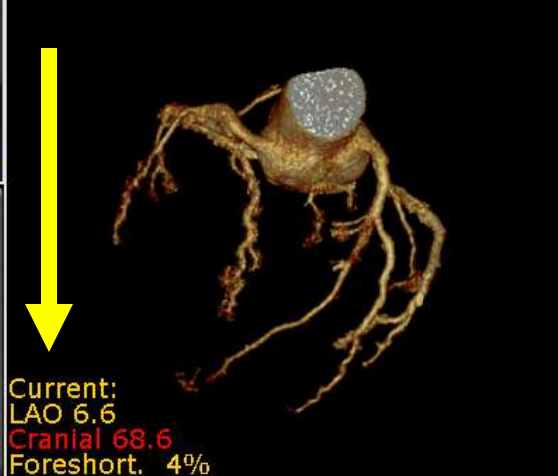
Angiography View

Registration

- Left Coronary
- Right Coronary
- Pick Coronary

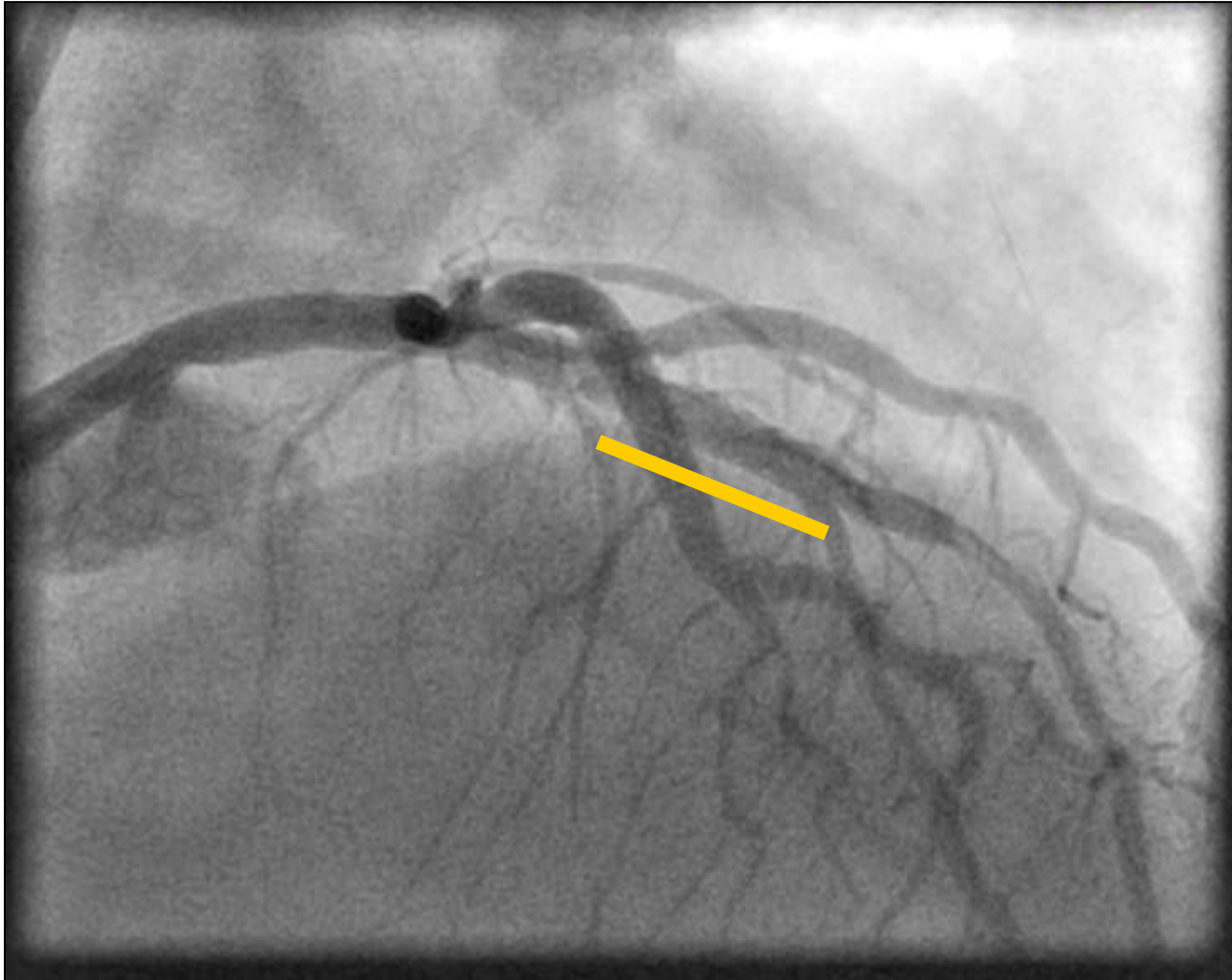
CT View

C-arm Orientation



Current:
LAO 6.6
Cranial 68.6
Foreshort. 4%

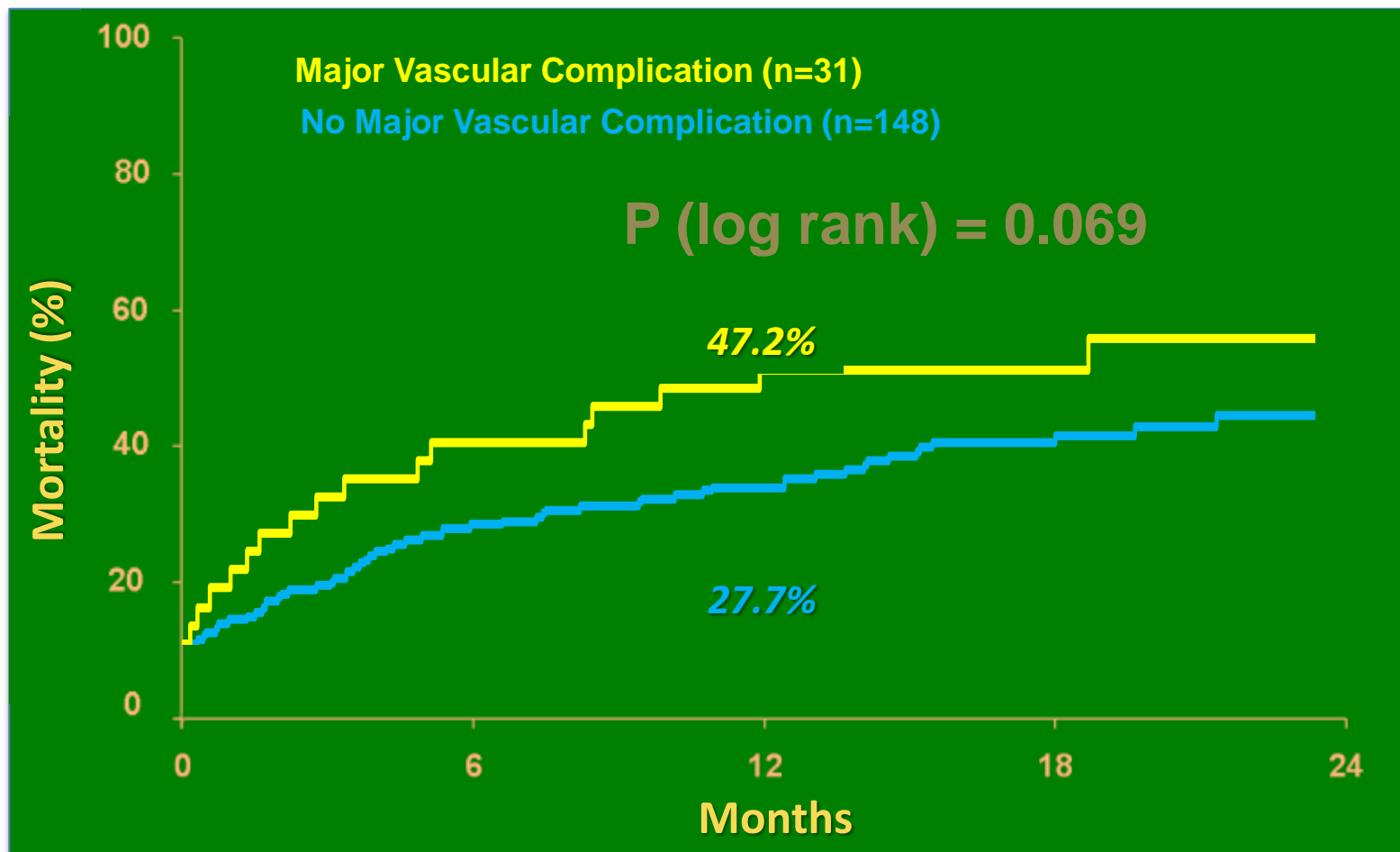
Resultado final



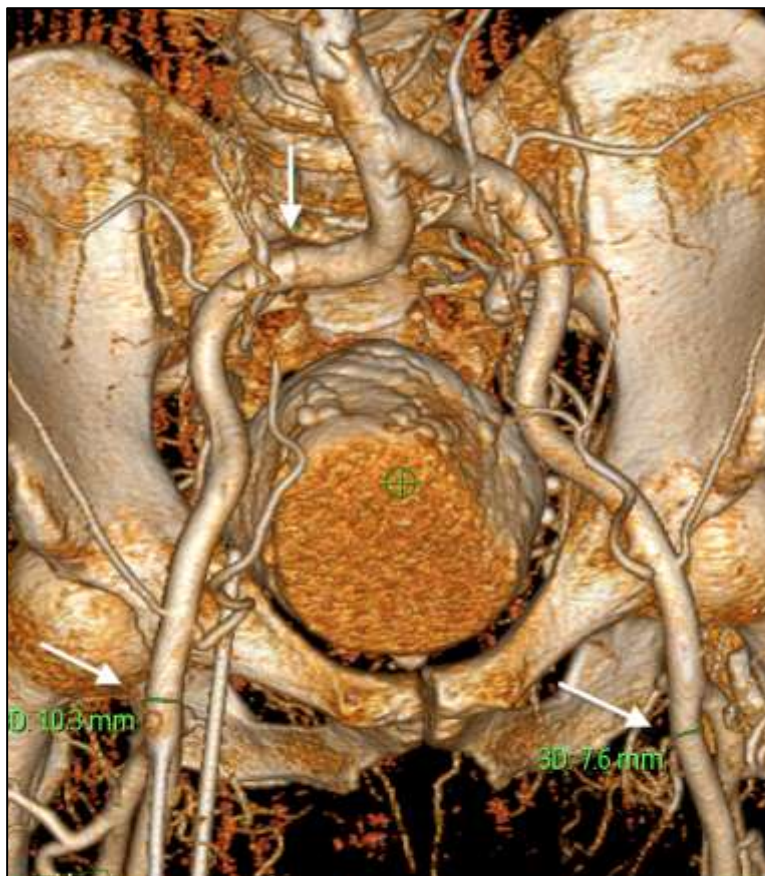
Rol de ATC en Reemplazo valvular aórtico percutáneo

- Acceso ilio-femoral
- Tamaño de anillo/protesis
- Mejor proyección para implante
- Acceso trans-apical (re-operados)

Mortalidad & complicación vascular en PARTNER trial



Evaluación de acceso ilio-femoral con pigtail en aorta




- Pigtail 4F en aorta abdominal bajo renales
- Mezcla de 20cc contraste + 60 cc de solución salina (bolus)
- Inyectar a 4 cc/seg por 10 segundos

9.3 x 9.3 mm



8.7 x 9.4 mm



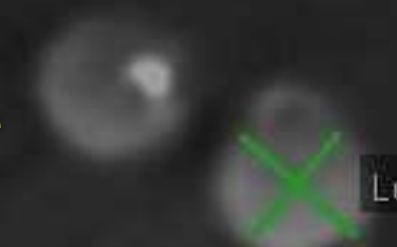9.9 x 7.5 mm



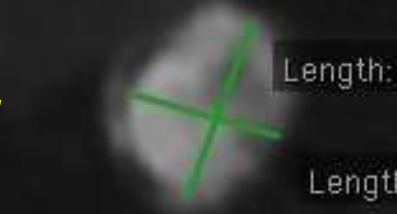
7.1 x 7.1 mm



10.0 x 11.4 mm



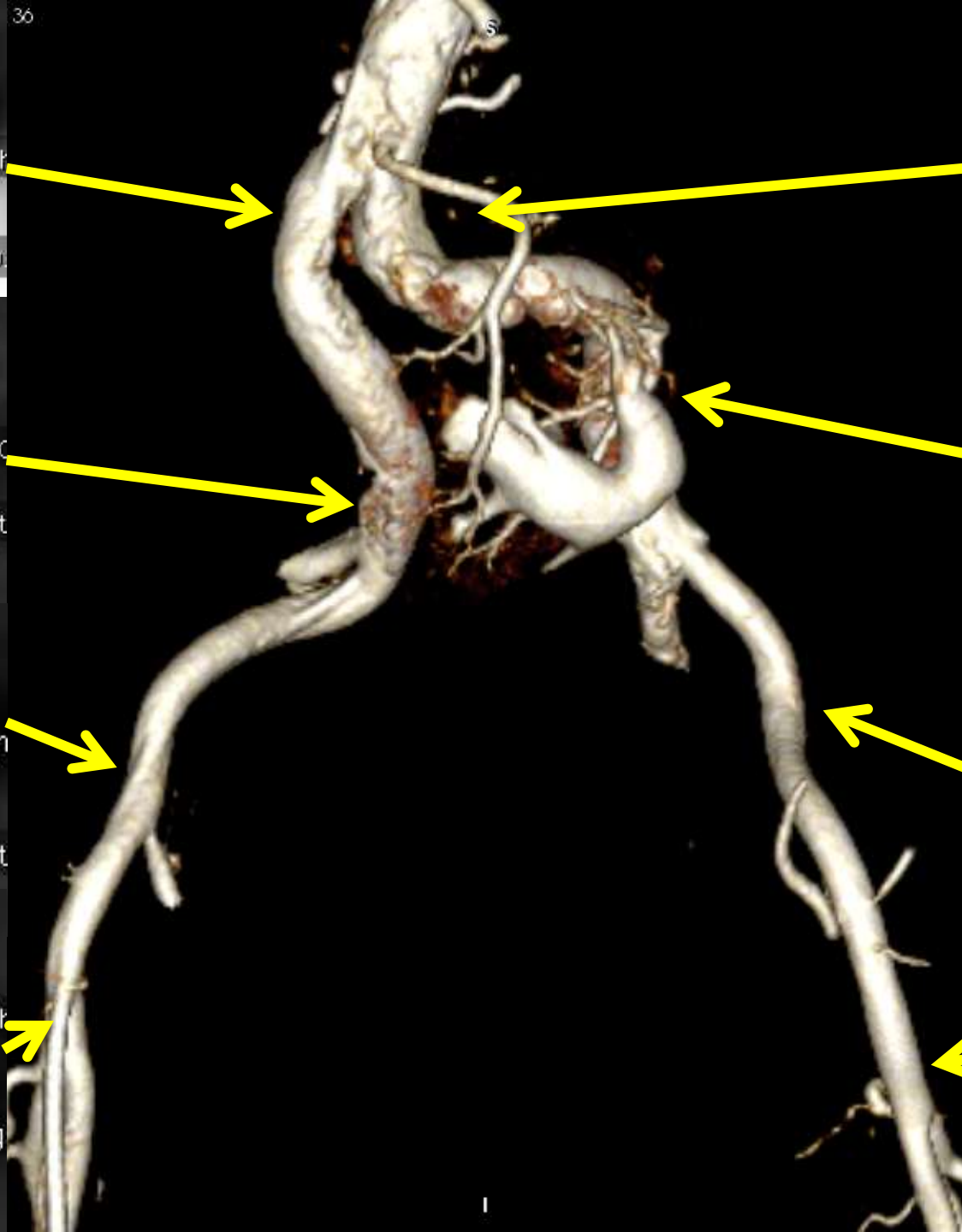
13.4 x 10.9 mm



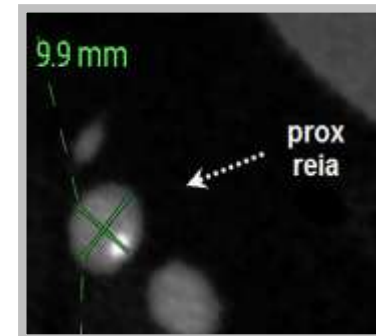
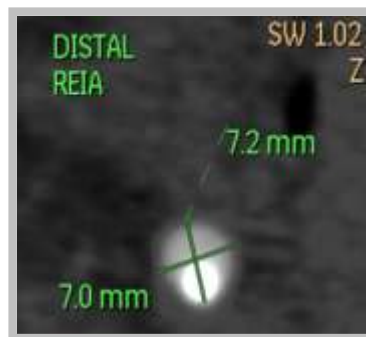
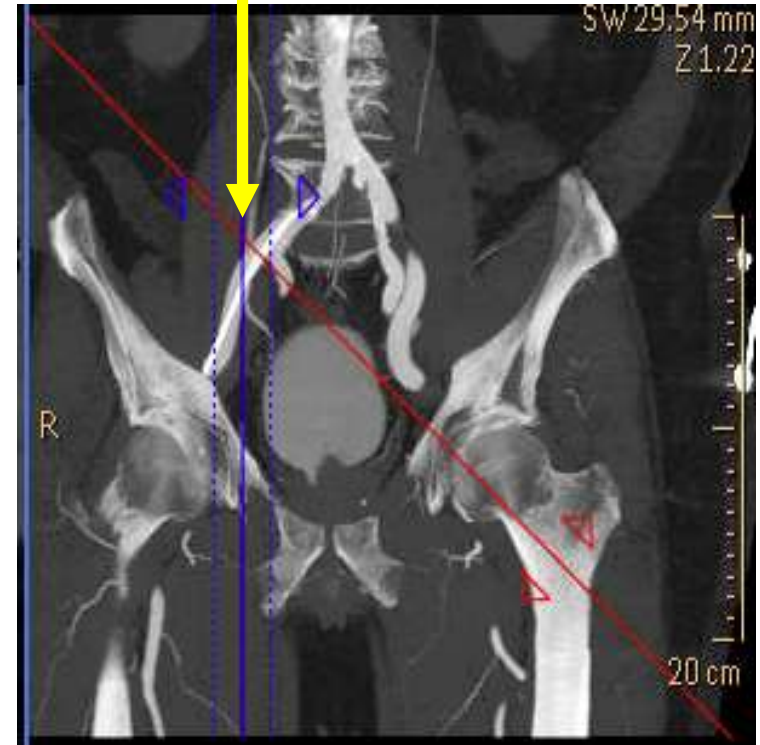
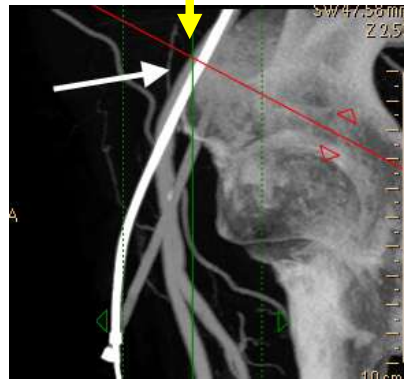
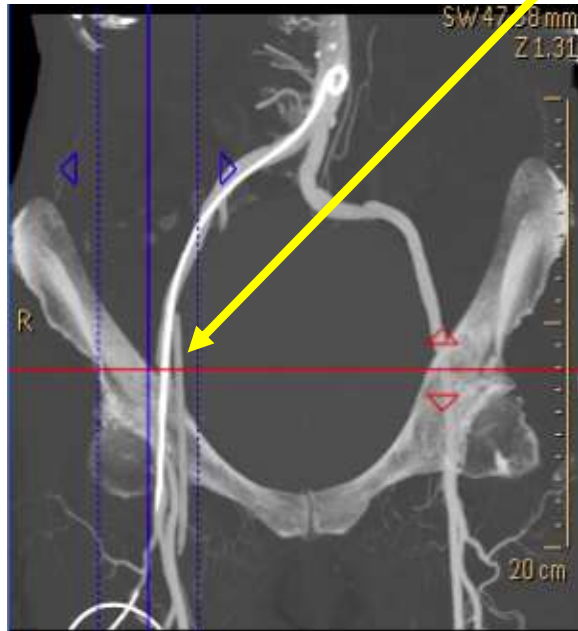9.0 x 8.9 mm



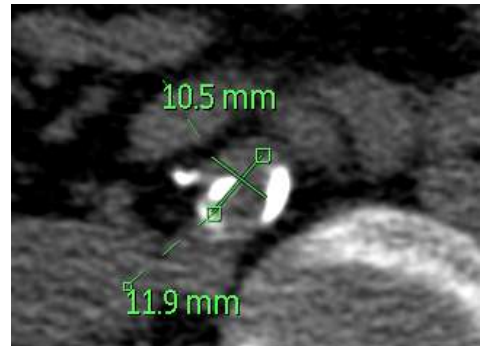
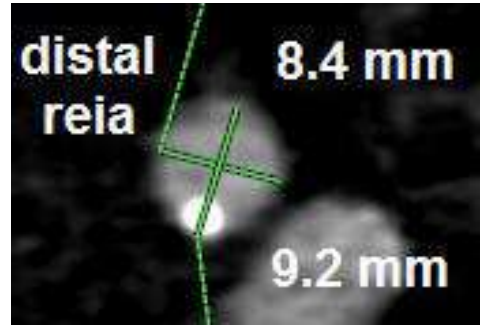
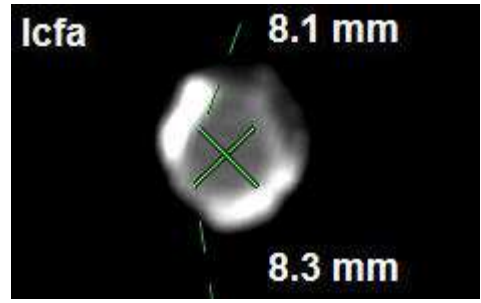
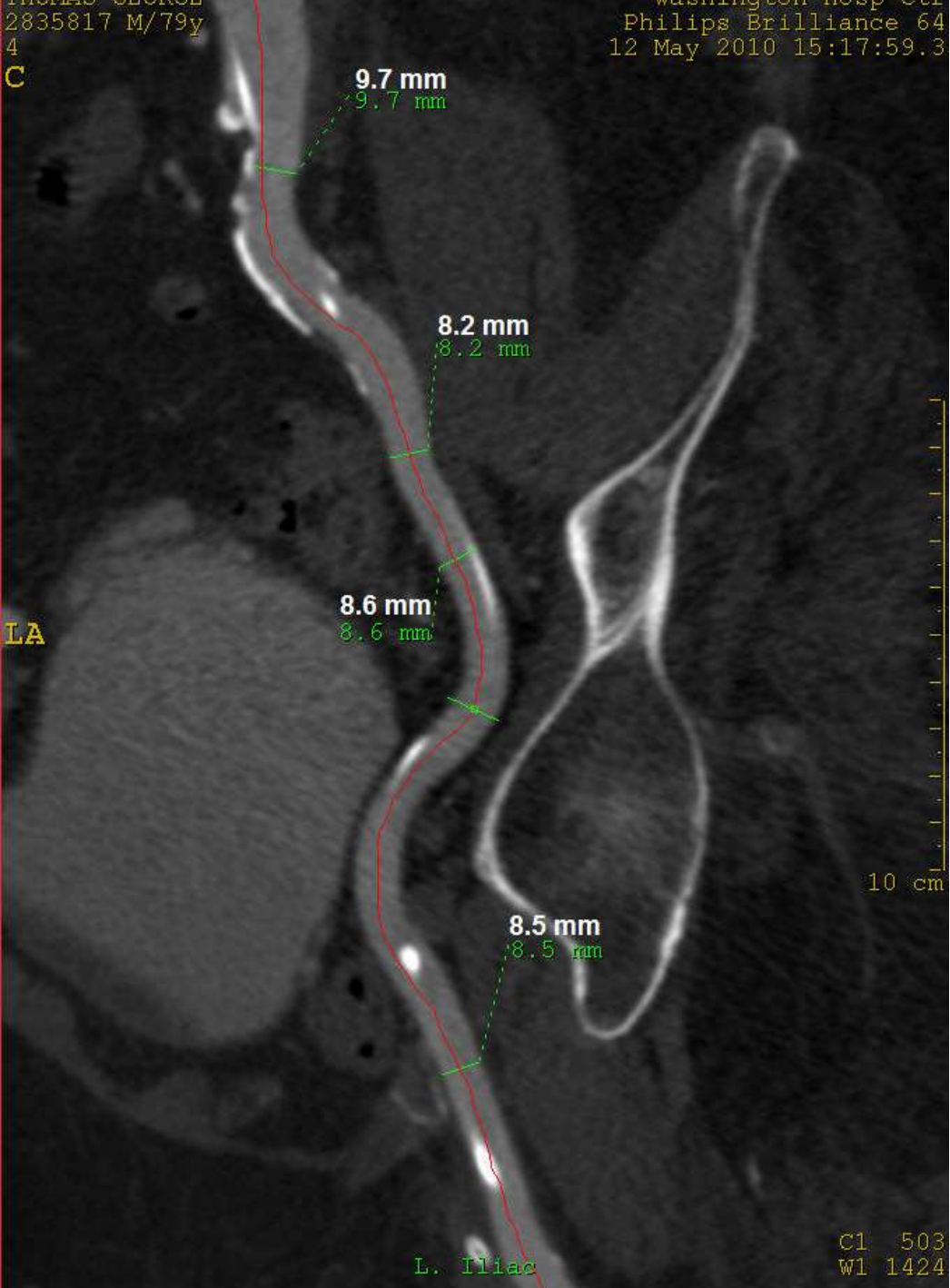7.2 x 8.6 mm



Diámetros deben ser obtenidos en cortes axiales perpendiculares a eje mayor de vaso

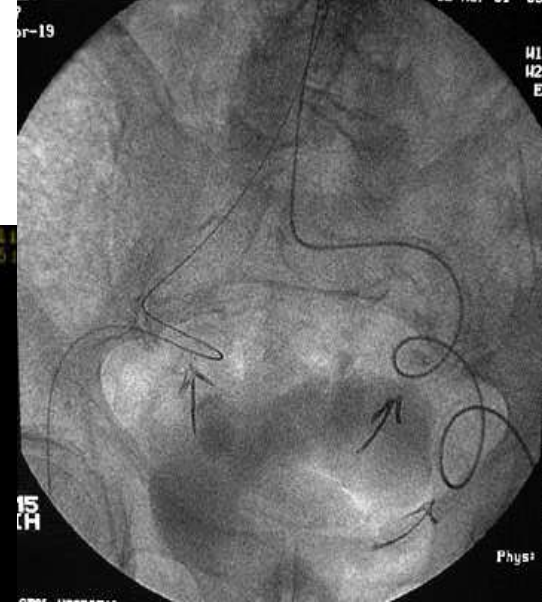
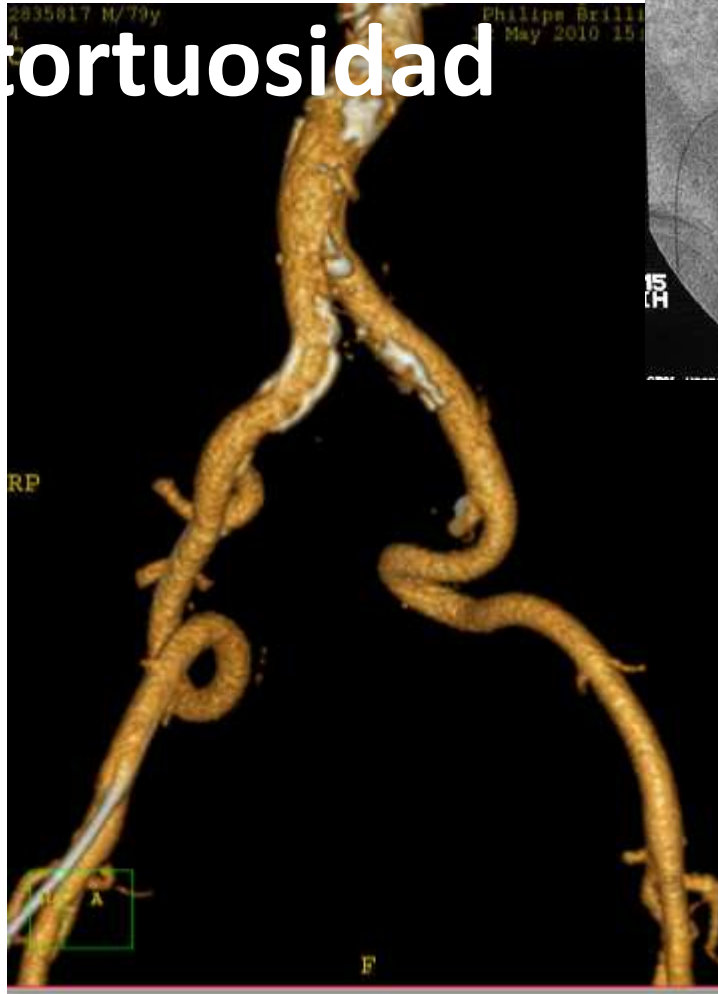
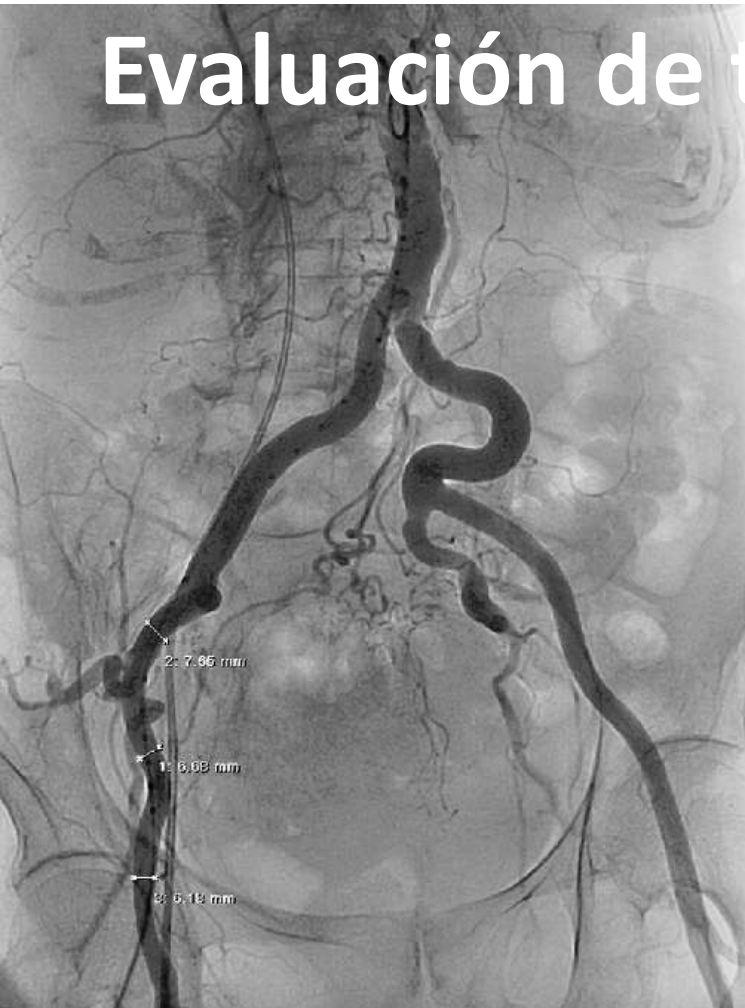
LA

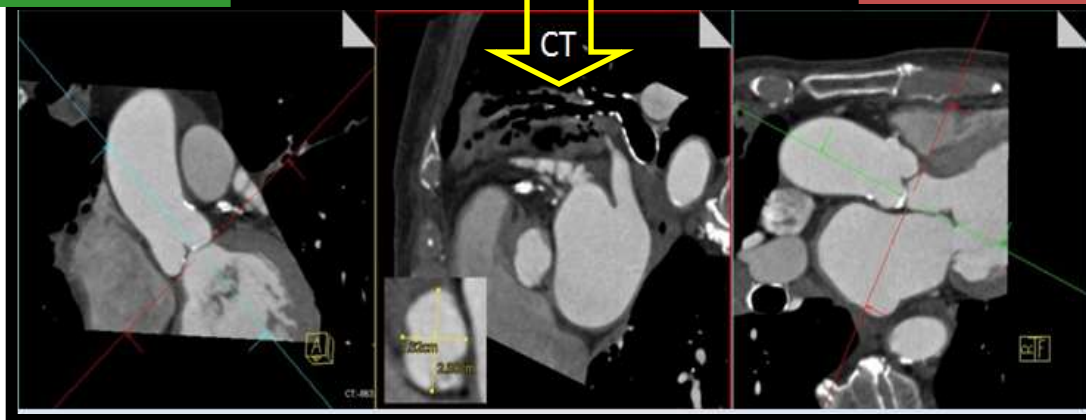
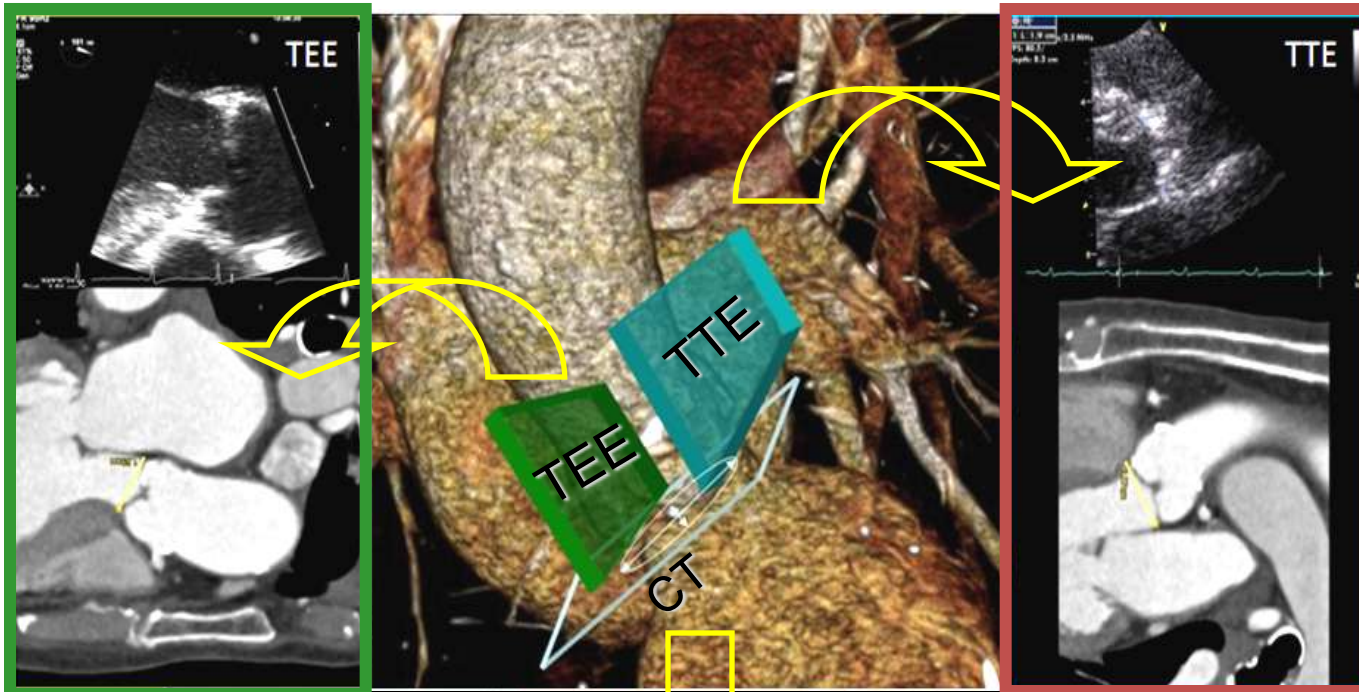


**Mediciones de lumen
deben excluir calcio**

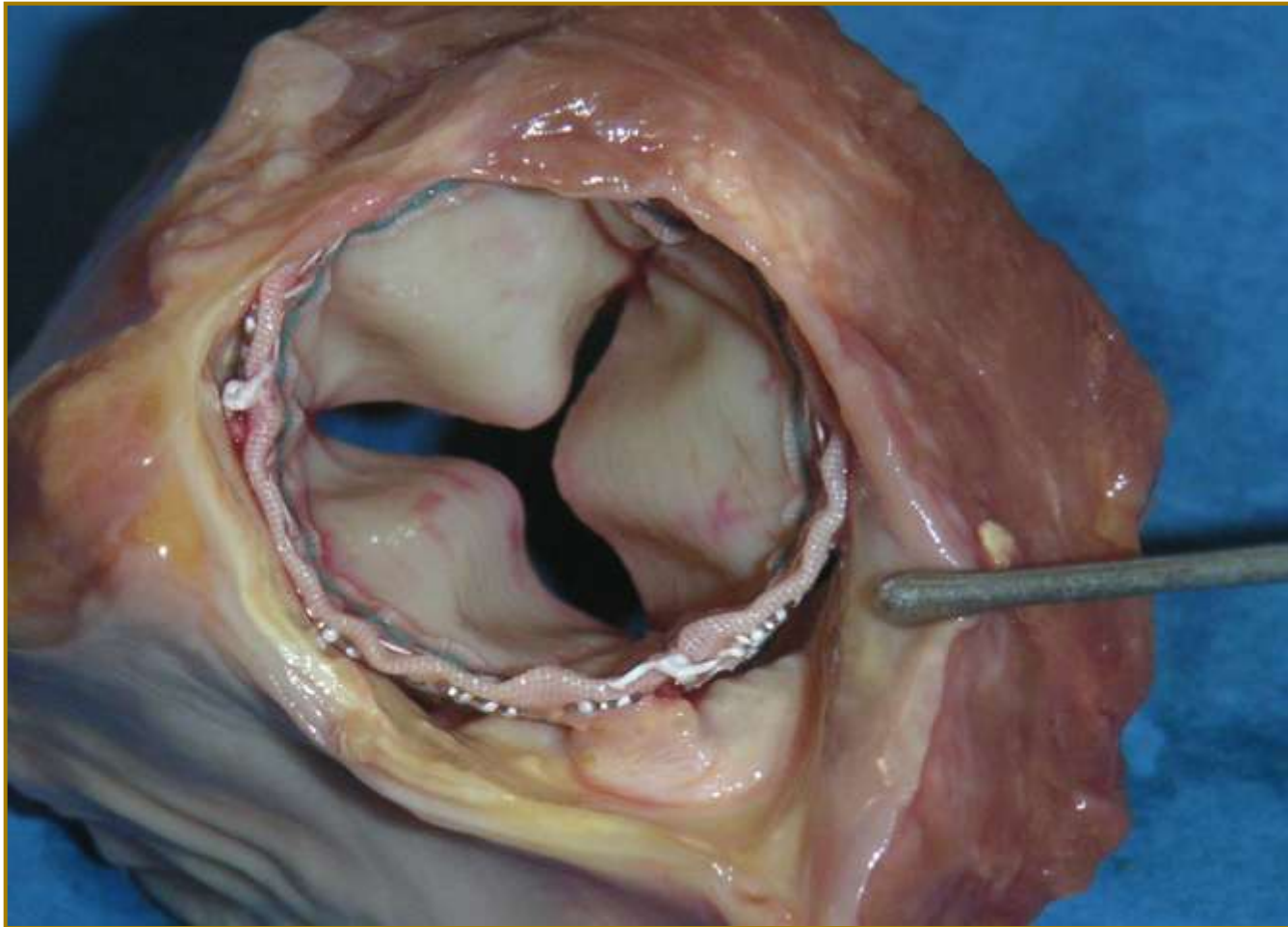
Evaluación de tortuosidad



Angulaciones agudas pueden prevenir/dificultar avance de sistema de liberación, especialmente en vasos severamente calcificados

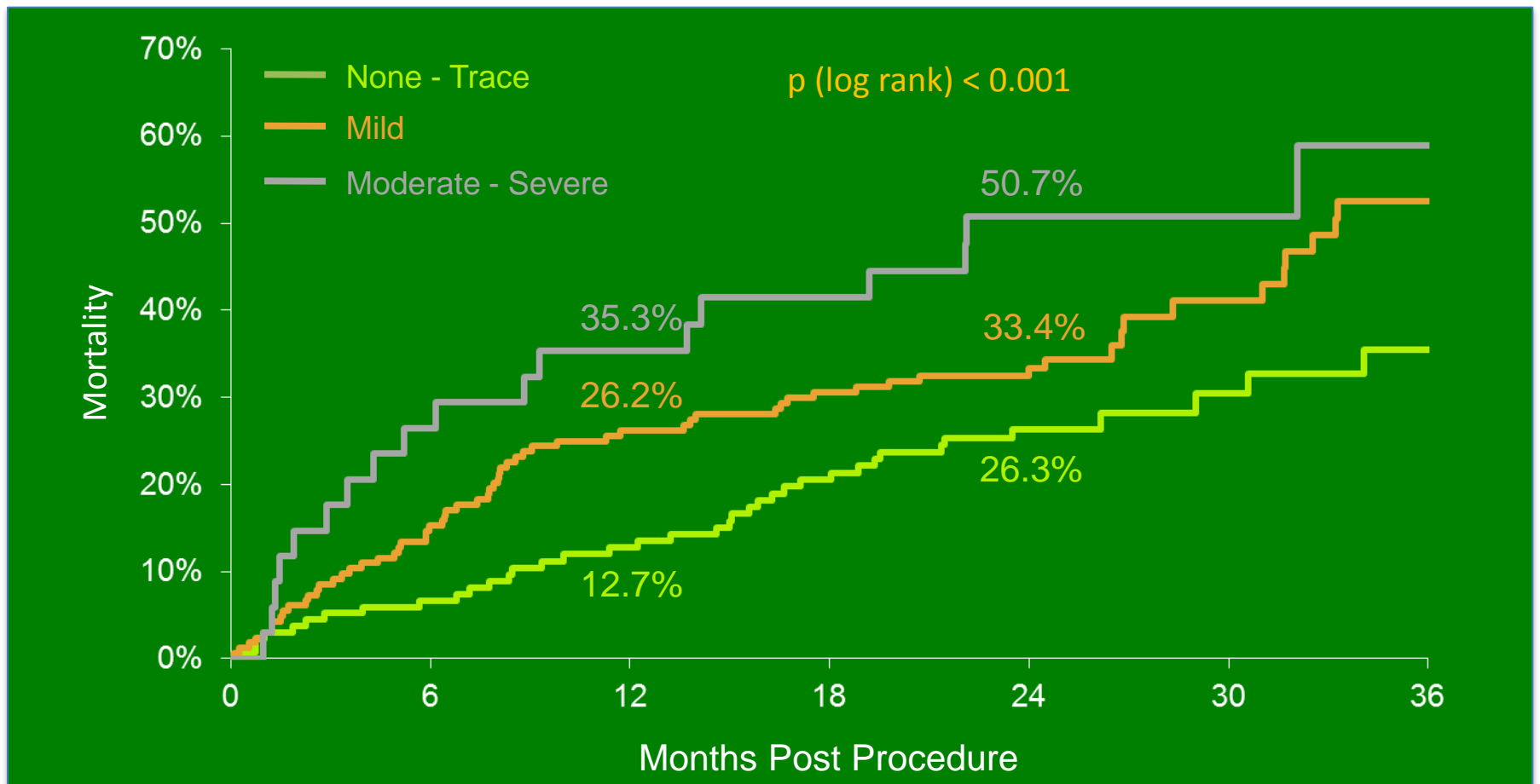


Regurgitacion Para-valvular

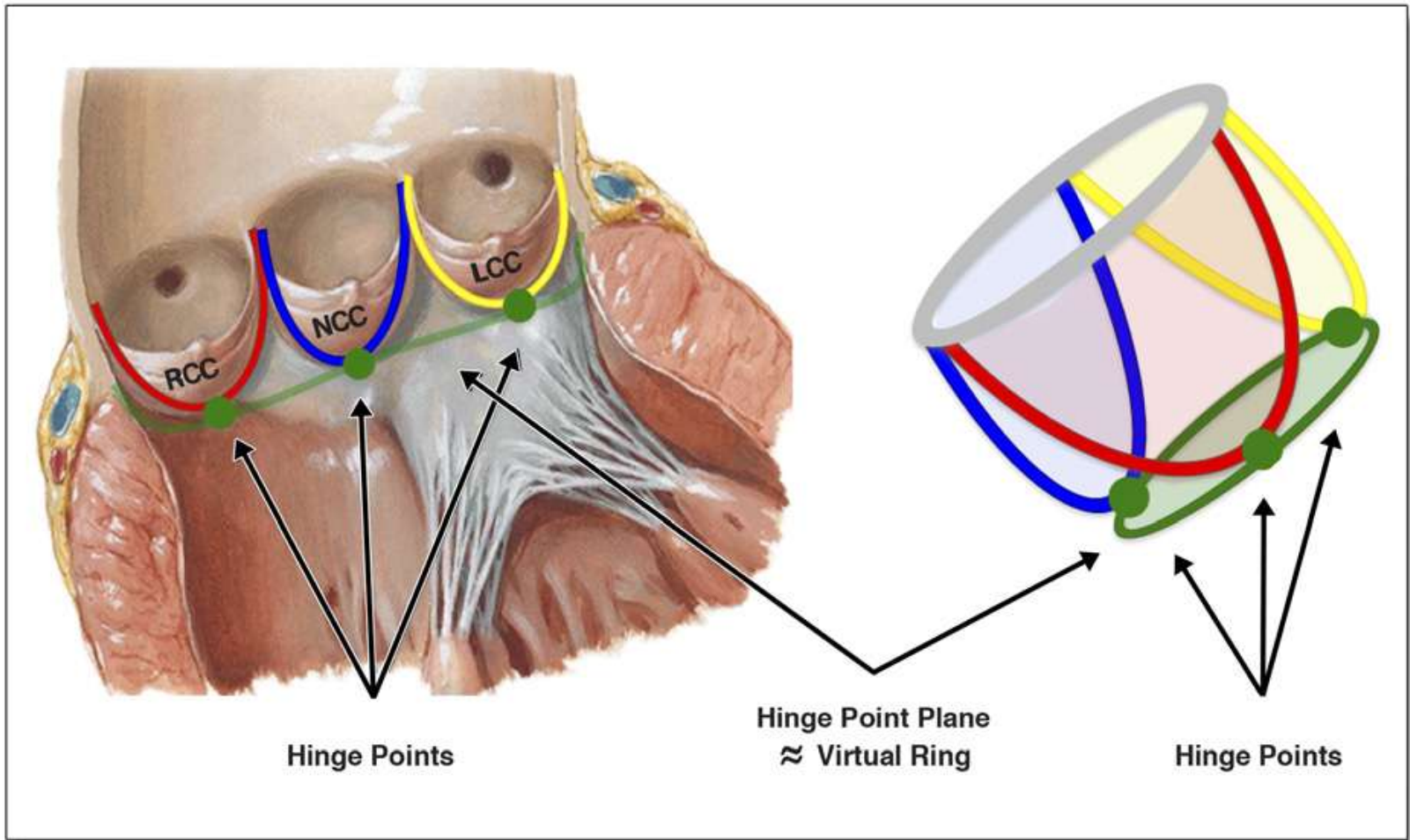


Insuficiencia aortica & Mortalidad

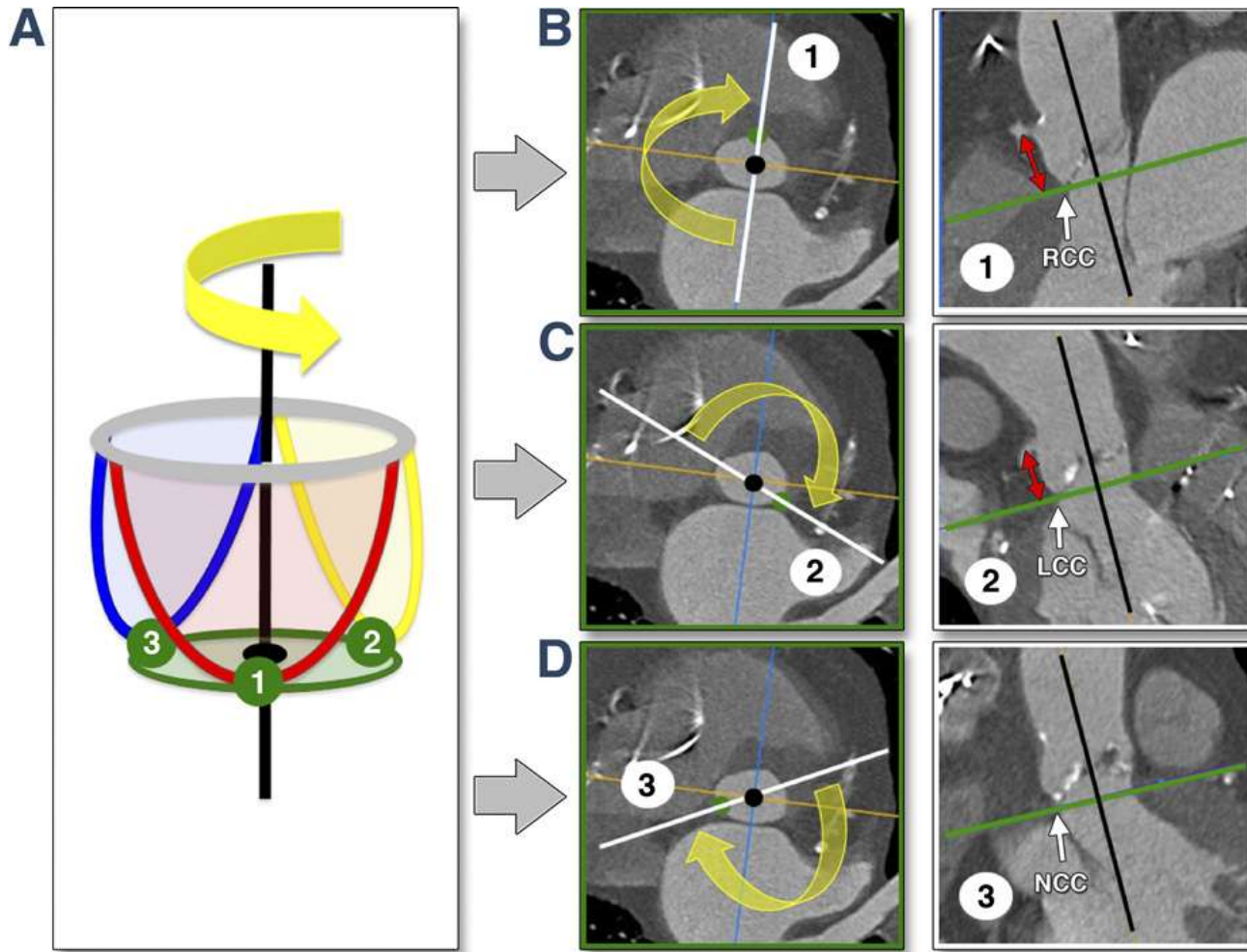
PARTNER trial



ANATOMIA NORMAL DEL ANILLO



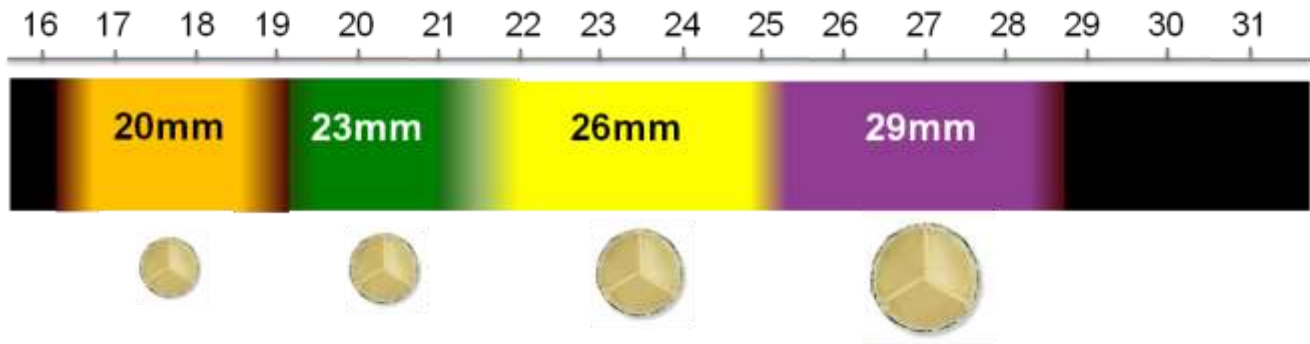
Regla de 'turn around' para reconstrucción de anillo



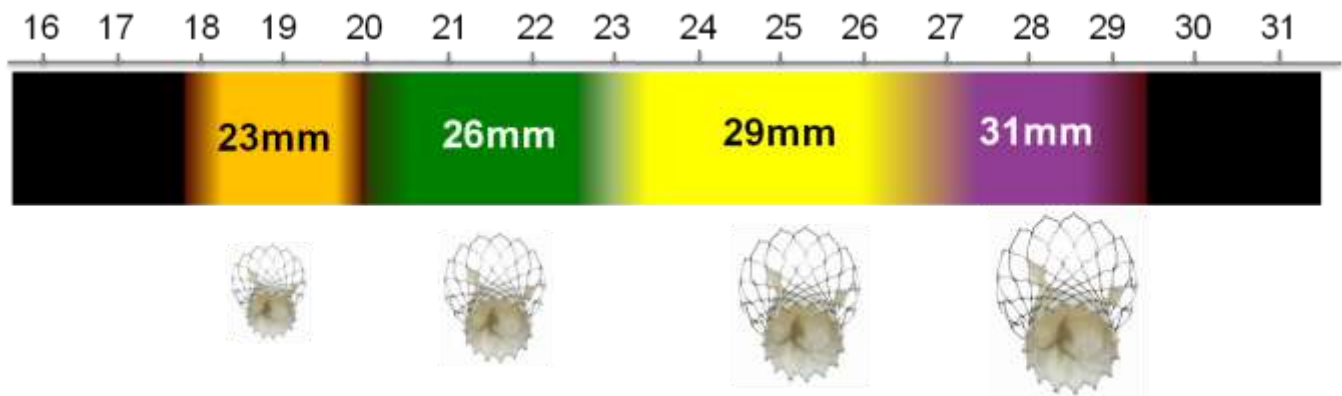
Tamaño de raíz aortica y eleccion de protesís

Annulus Diameter in mm

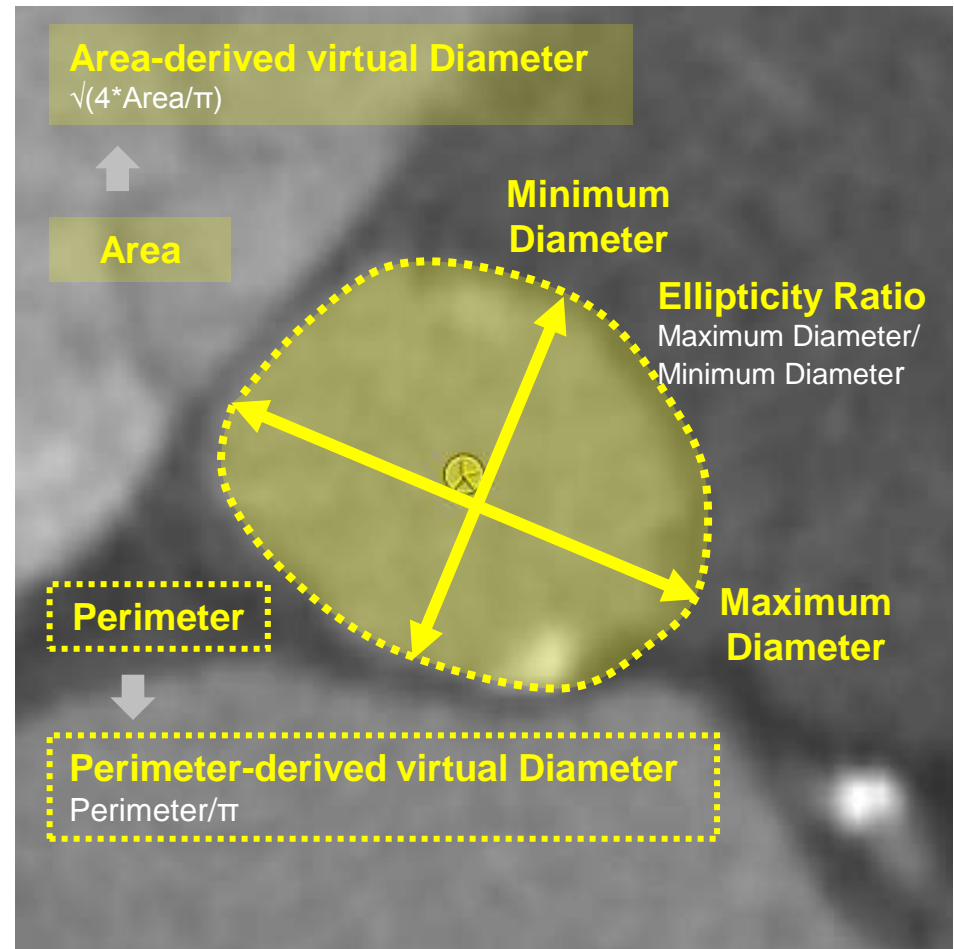
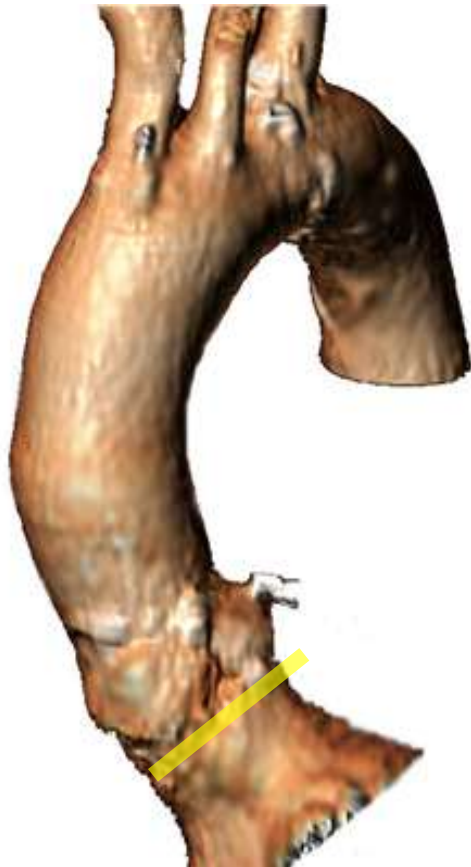**Edwards
SAPIEN XT**



**Medtronic
CoreValve**



New Sizing Concepts



Aortic Annulus Diameter Determination by Multidetector Computed Tomography

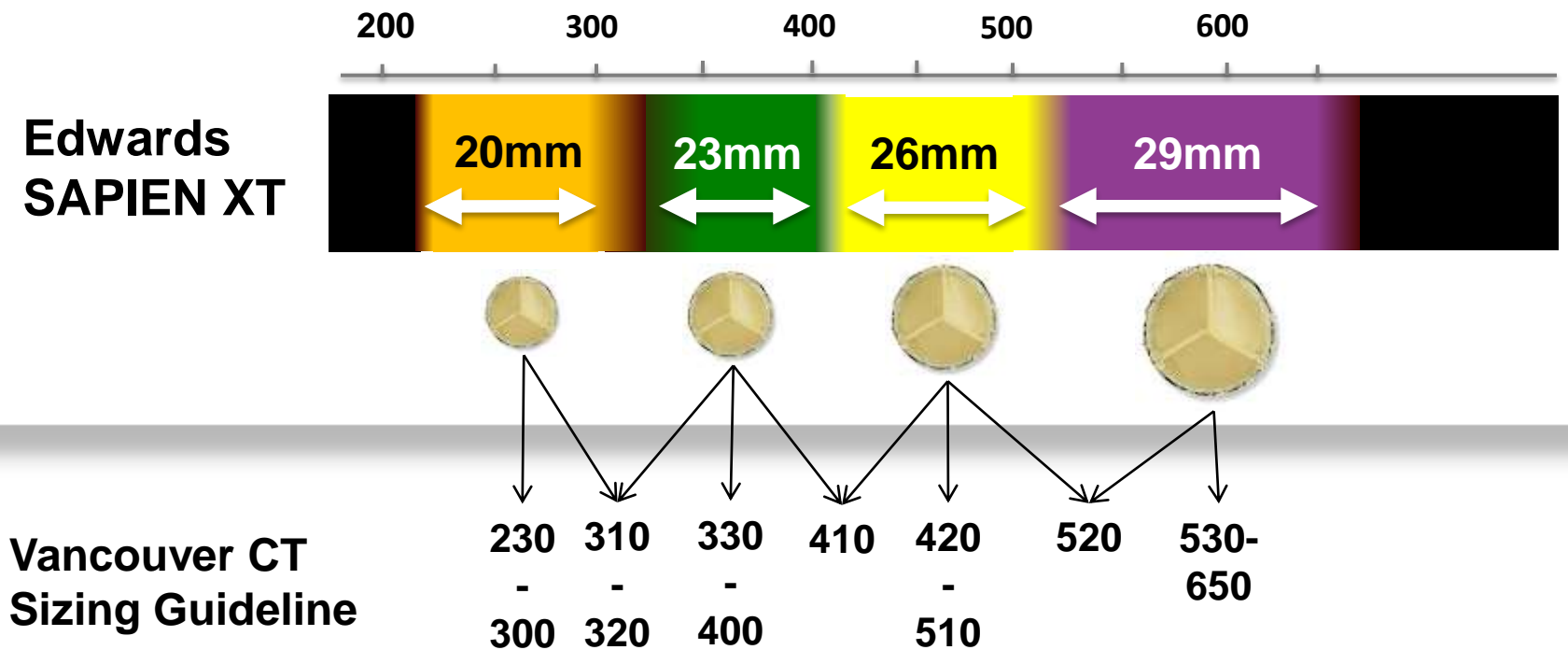
Reproducibility, Applicability, and Implications for Transcatheter Aortic Valve Implantation

MDCT annular measurement	ICC	95% CI
Mean diameter	0.87	0.79 -0.90
Area	0.86	0.65-0.90
Long diameter	0.77	0.71-0.83
Short diameter	0.70	0.49-0.82

Cross-Sectional Computed Tomographic Assessment Improves Accuracy of Aortic Annular Sizing for Transcatheter Aortic Valve Replacement and Reduces the Incidence of Paravalvular Aortic Regurgitation

Outcomes	All Studied Patients (n = 136)	2D TEE-Guided Annular Sizing (n = 96)	Cross-Sectional CT-Guided Annular Sizing (n = 40)	p Value
PV AR				0.001
None	41 (30.1)	23 (24)	18 (45)	
Trivial or mild	71 (52.2)	52 (54.1)	19 (47.5)	
Mild-moderate	9 (6.6)	8 (8.3)	1 (2.5)	
Moderate	12 (8.8)	10 (10.4)	2 (5)	
Moderate-severe	3 (2.2)	3 (3.1)	0	
Severe		0	0	
PV AR > mild	24 (17.6)	21 (21.9)	3 (7.5)	0.045
Need for bail-out valve-in-valve	1 (0.7)	1 (1)	0	0.52
Annular rupture	1 (0.7)	1 (1)	0	0.52
Prosthesis instability (rocking)	1 (0.7)	1 (1)	0	0.52
Peri-procedural mortality	4 (3)	3 (3.2)	1 (2.5)	0.82

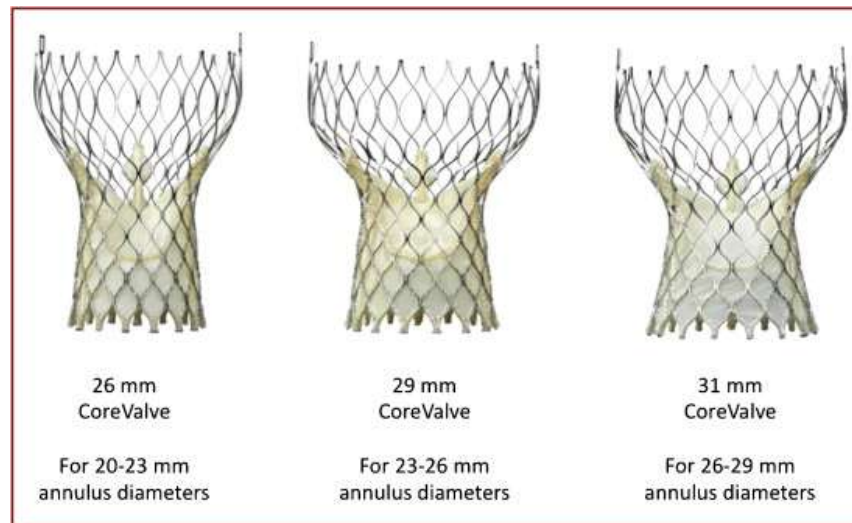
TAVR Device Selection Based on Annulus Area

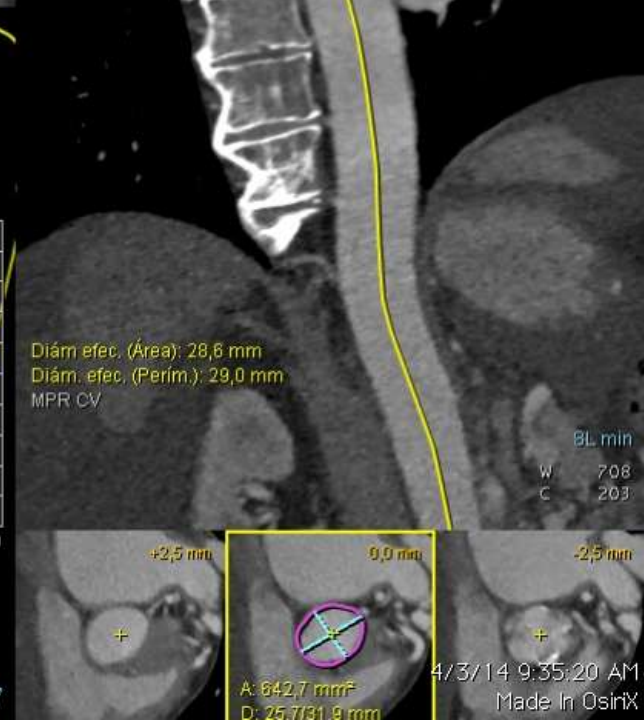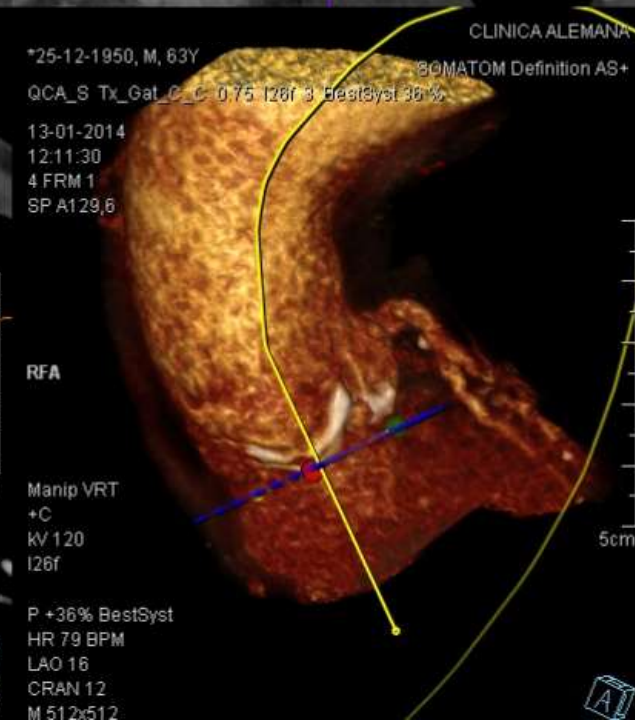
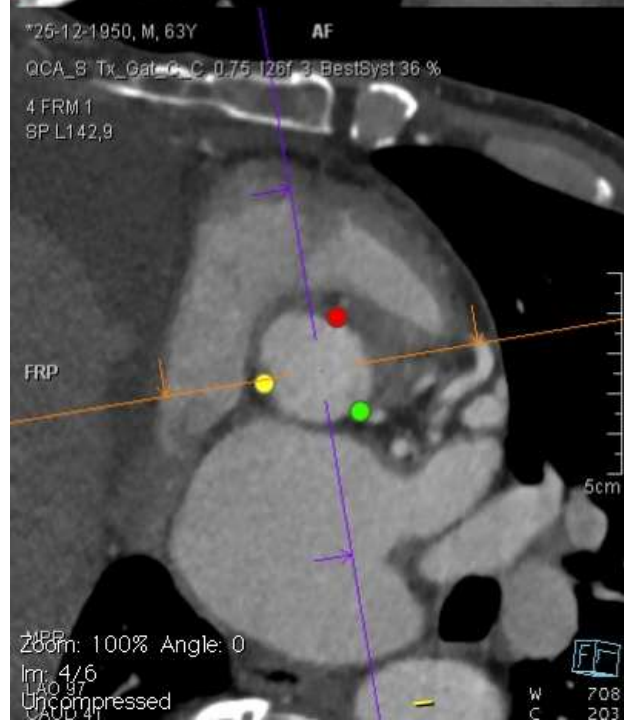
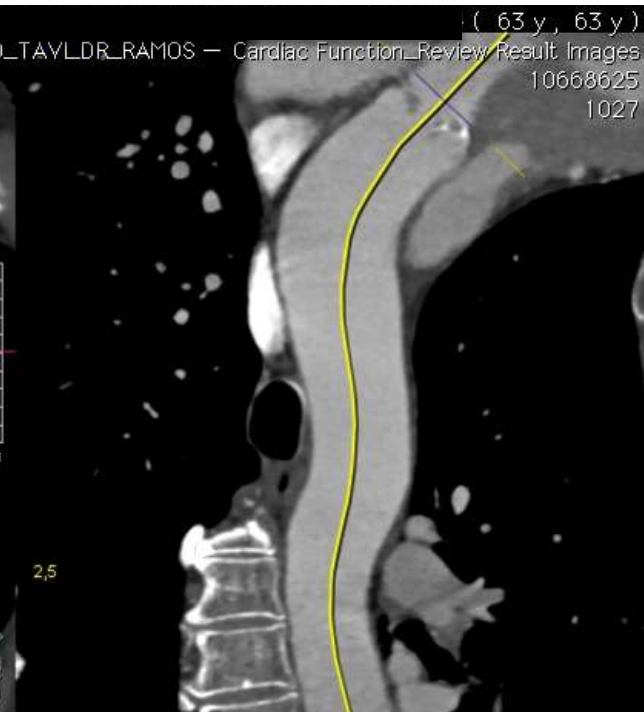
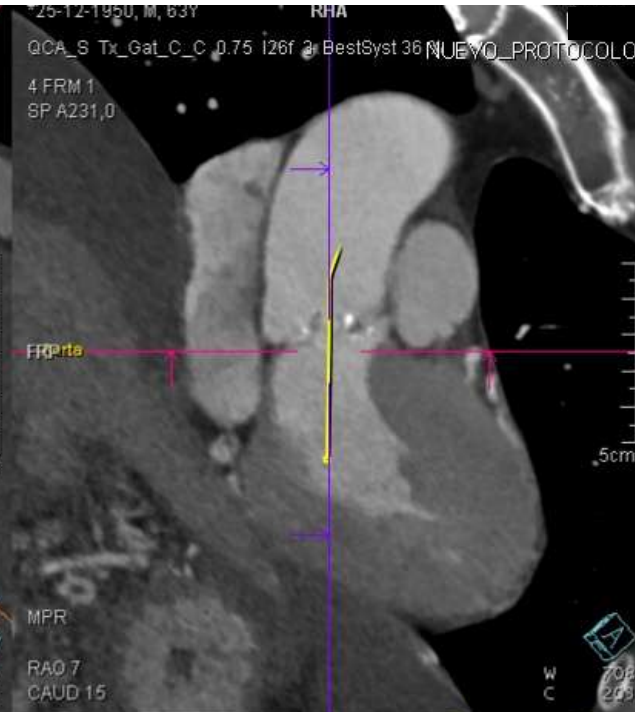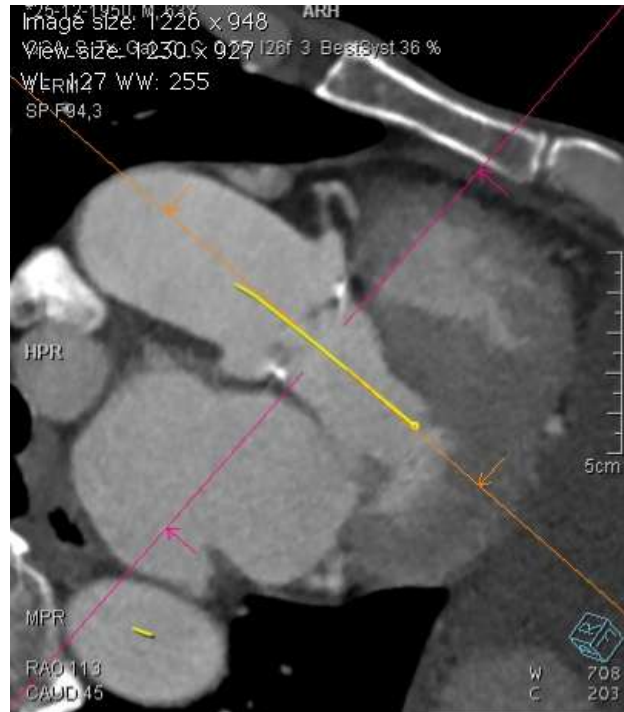


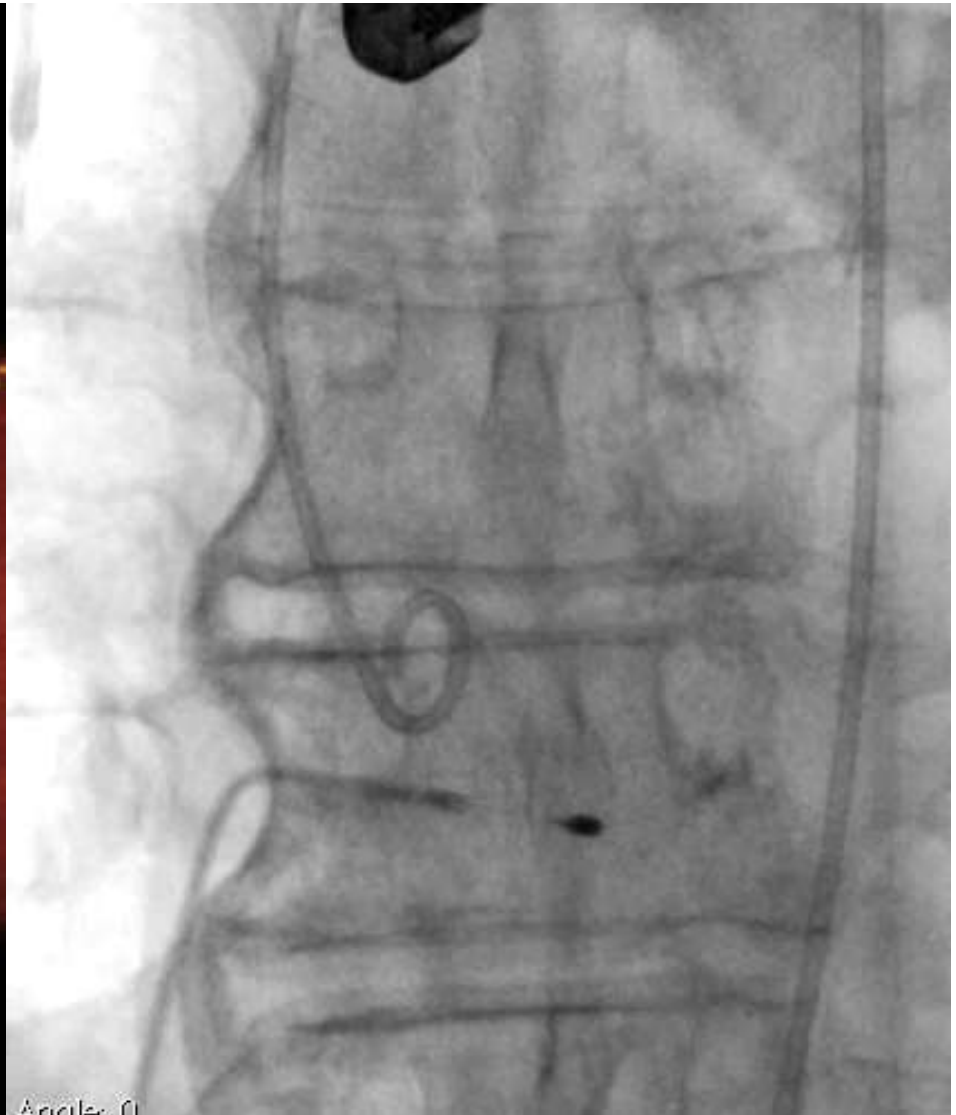
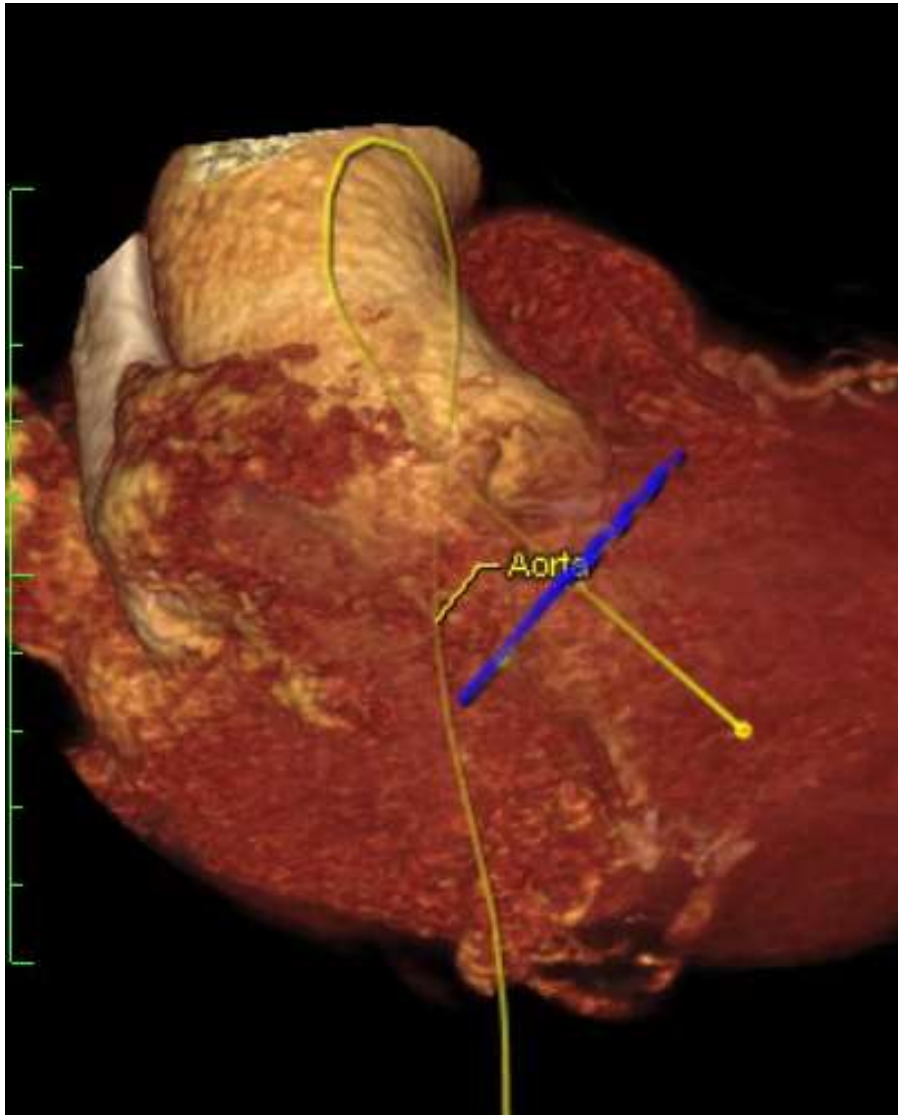
Elección del tipo protesis

La evidencia reciente recomienda al Perimetro y Area en la Doble oblicua axial para seleccionar la valvula

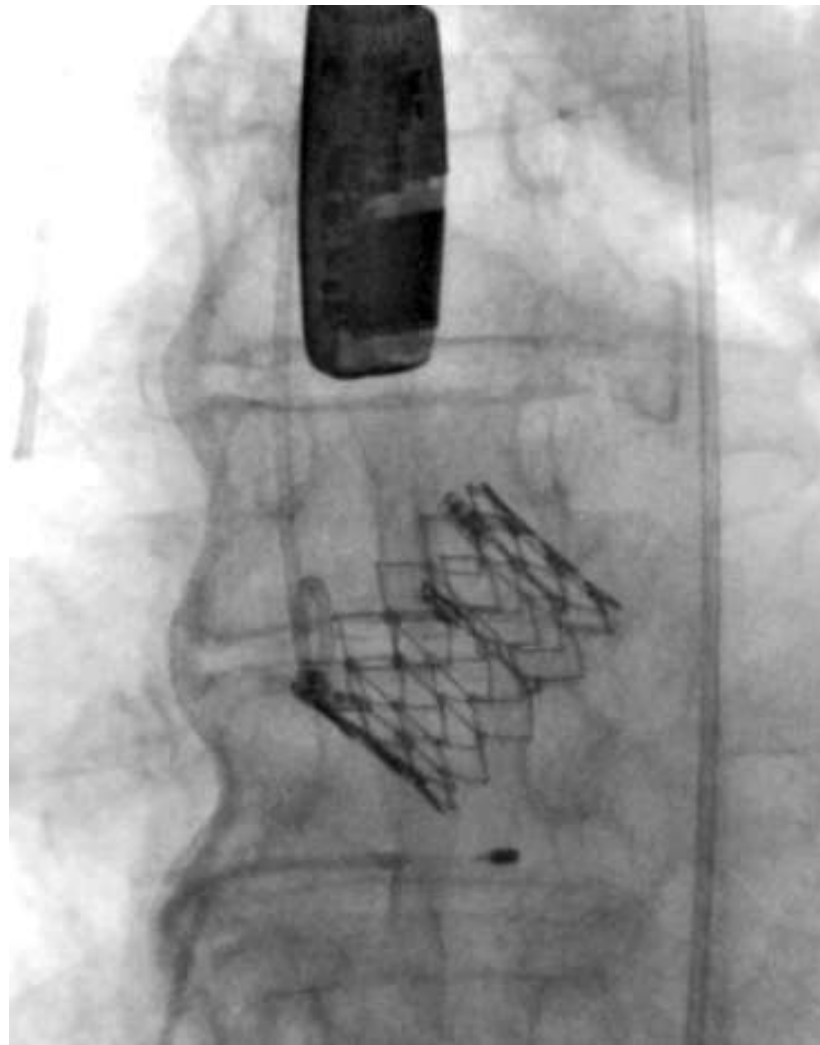
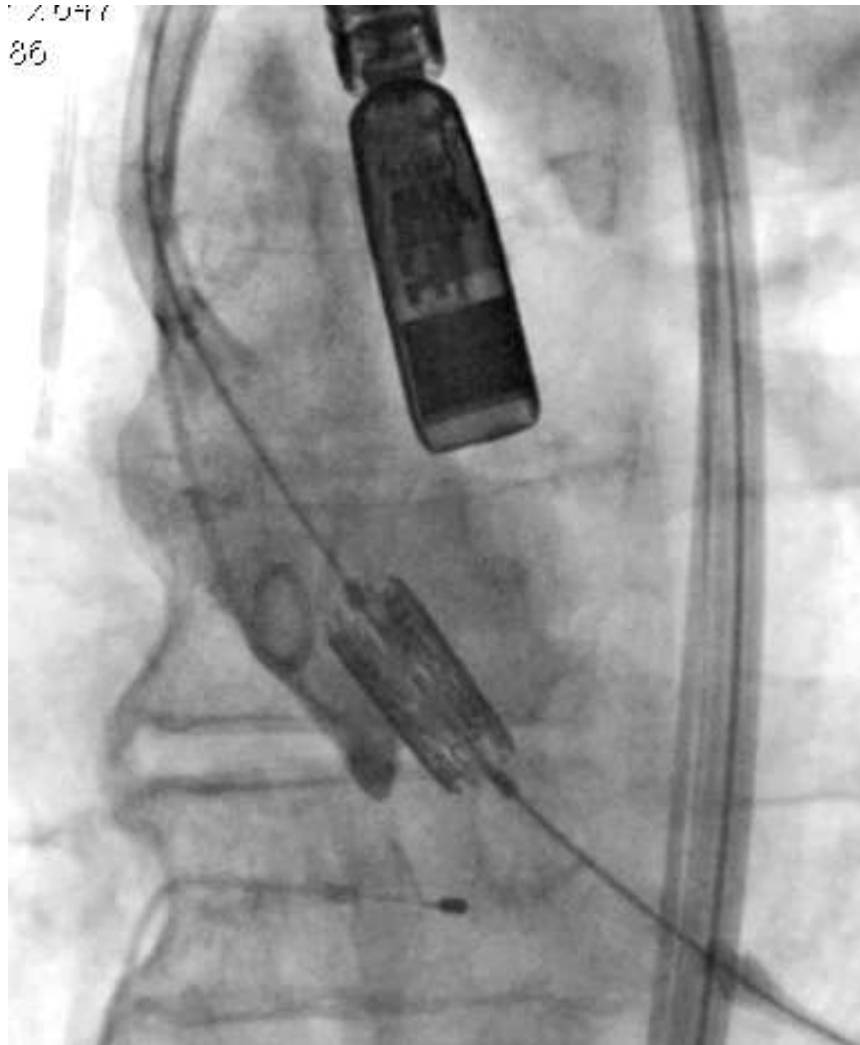
	Diameter Range (mm)	Perimeter Range (mm)	Area Range (mm ²)
23	18 - 20	56.5 - 62.8	254.5 - 314.2
26	20 - 23	62.8 - 72.3	314.2 - 415.5
29	23 - 27	72.3 - 84.8	415.5 - 572.6
31	26 - 29	81.7 - 91.1	530.9 - 660.5





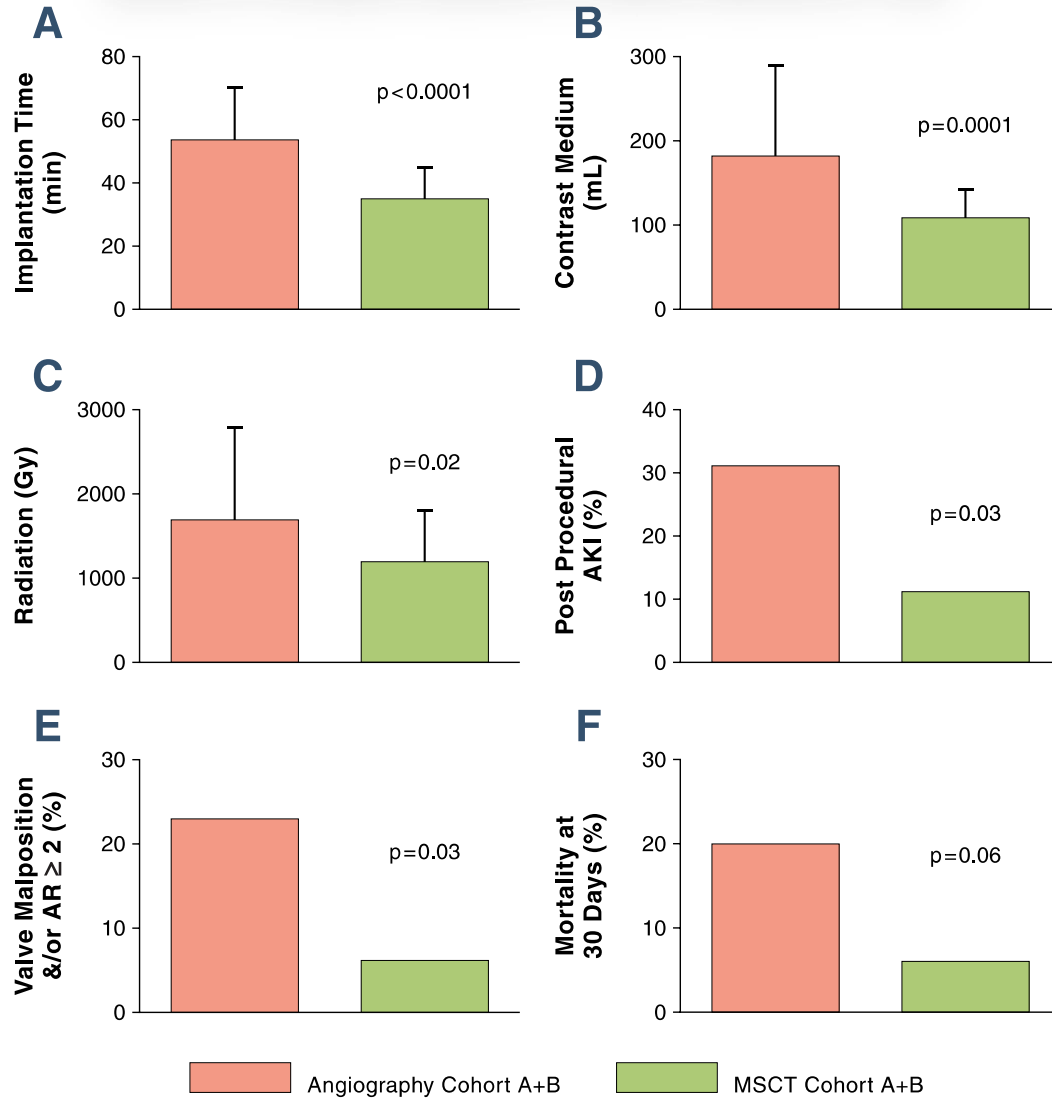


172.0477
86

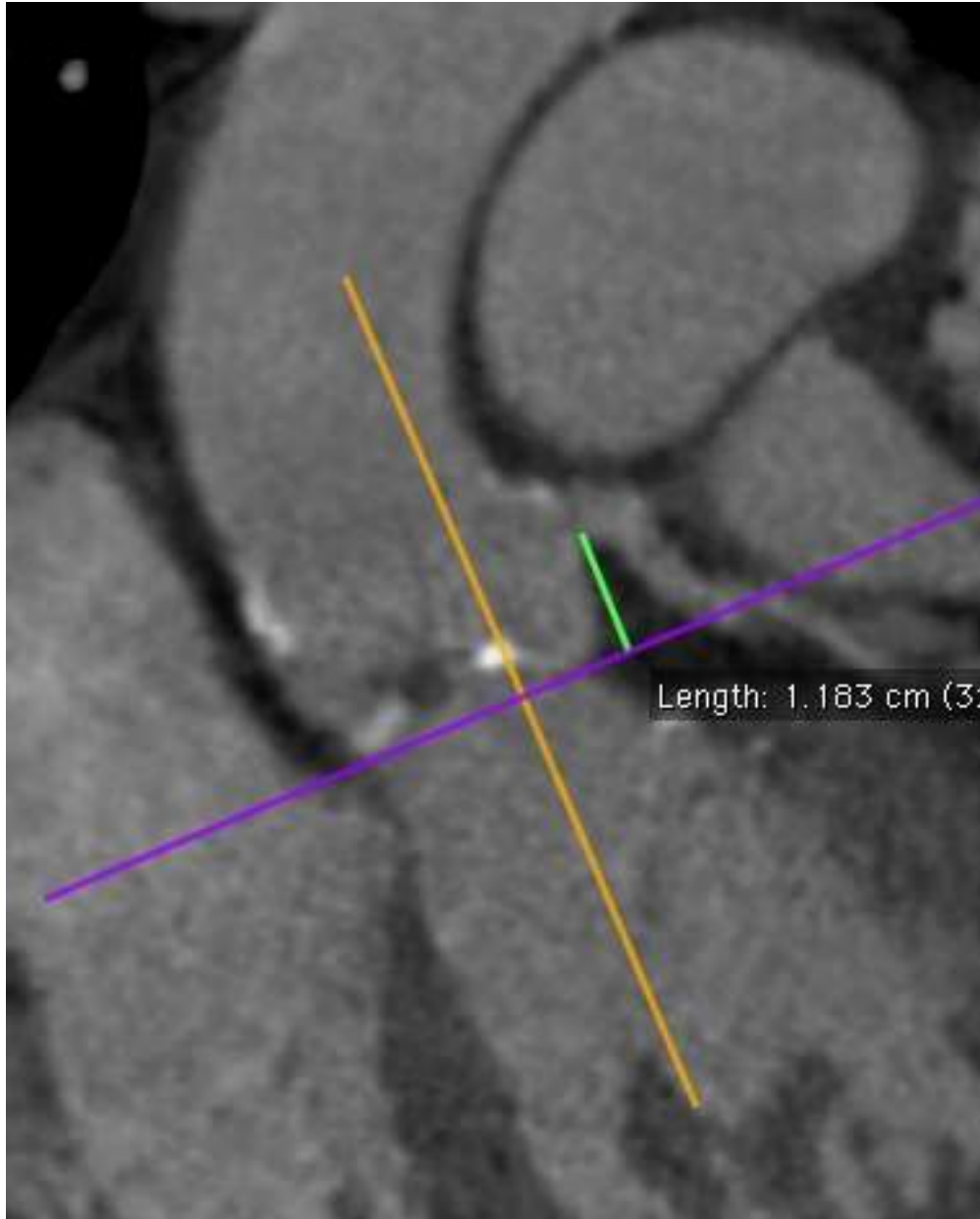


Automated 3D Analysis of Pre-Procedural MDCT to Predict Annulus Plane Angulation and C-Arm Positioning

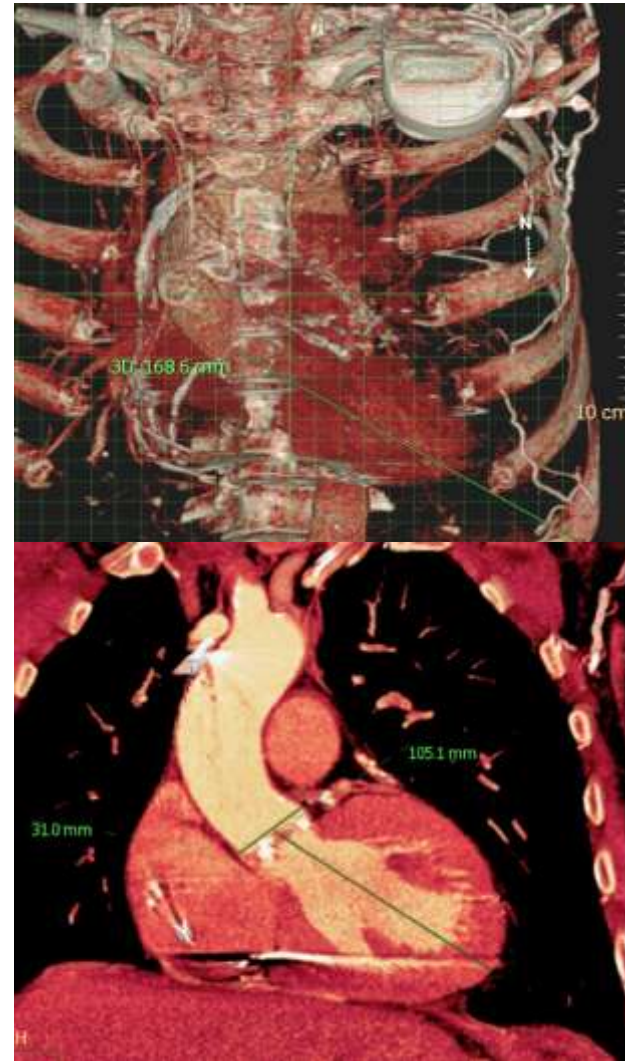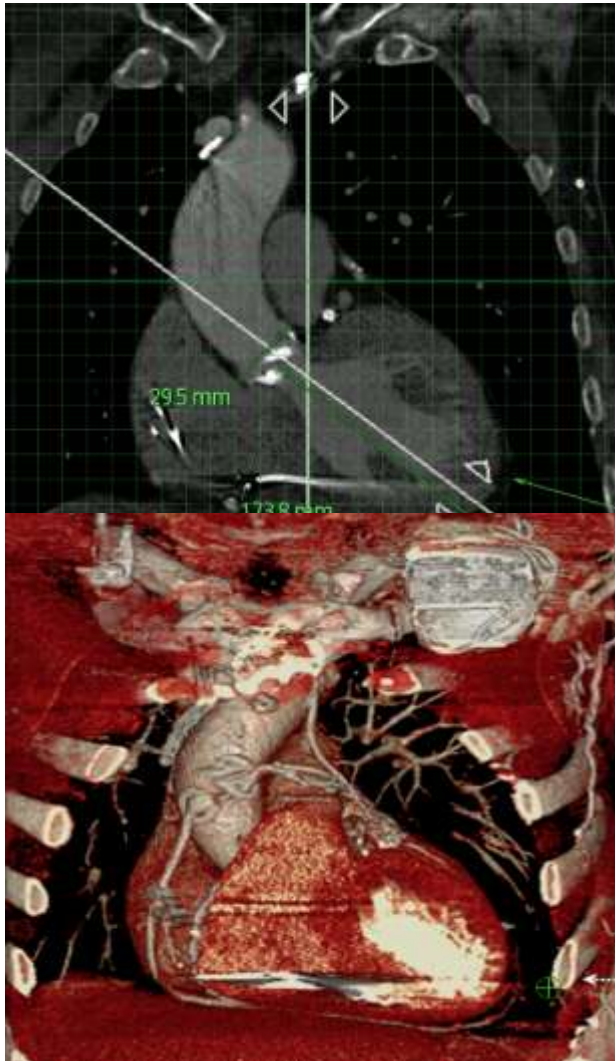
Benefit on Procedural Outcome in Patients Referred for TAVR



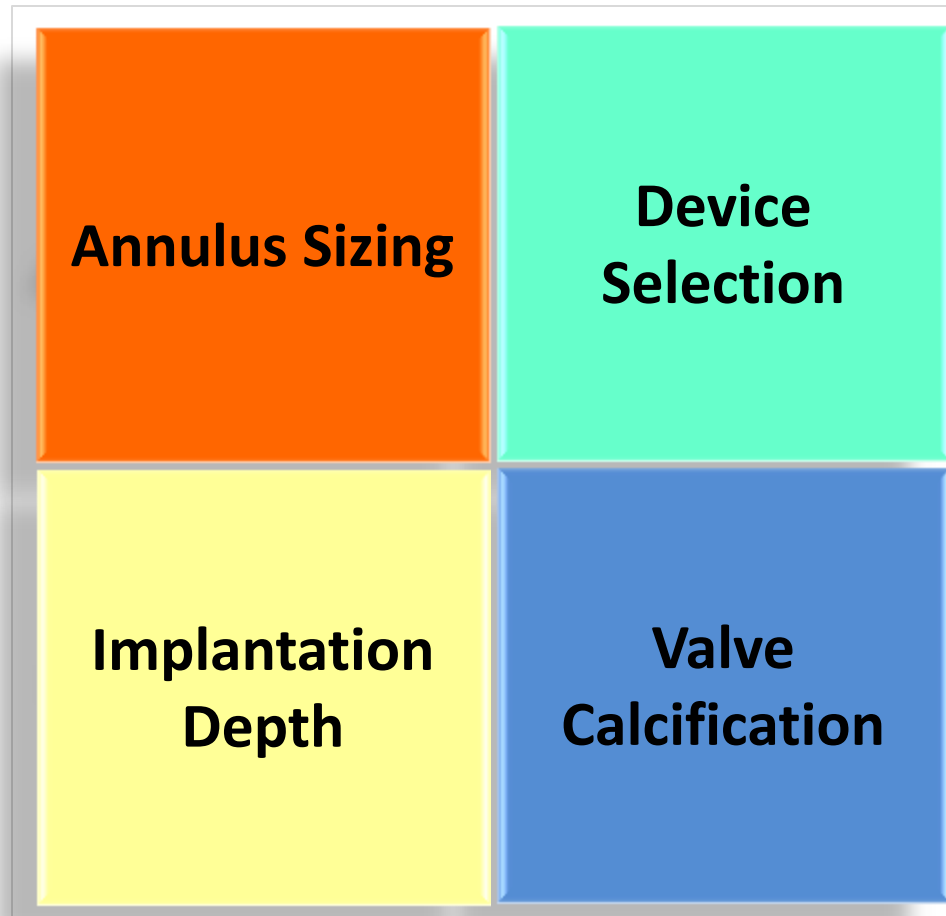
Distancia LM –
anillo 12 mm



Planificación de vía trans-apical



TAVR - Perfect Implant



CONCLUSIONES

- La ATC es test de gran ayuda para el “tamizaje” negativo de pacientes con riesgo bajo/intermedio para EC
- La ATC es particularmente util para planificacion de oclusiones coronarias cronicas
- La ATC es indispensable para estudio y planificacion del reemplazo valvular aortico percutaneo