Effect of high-intensity statin therapy on atherosclerosis in non-infarct related coronary arteries: a serial intravascular ultrasonography study

IBIS-4 (Integrated Biomarkers and Imaging Study)

Lorenz Räber, Masanori Taniwaki, Serge Zaugg
Henning Kelbaek, Marco Roffi, Lene Holmvang
Stephane Noble, Giovanni Pedrazzini, Aris Moschovitis
Thomas F. Lüscher, Christian M. Matter, Patrick W. Serruys
Peter Jüni, Hector M. Garcia Garcia, Stephan Windecker

Bern University Hospital, Switzerland

Speaker's name: Lorenz Räber, MD

☐ **I have the following** potential conflicts of interest to report:

- ☐ Research contracts
- ☐ Consulting
- ☐ Employment in industry
- ☐ Stockholder of a healthcare company
- ☐ Owner of a healthcare company
- ☐ Other(s):

☒ **I do not have any potential conflict of interest**

The IBIS-4 trial was supported by the **Swiss National Science Foundation** and an **unrestricted grant by Volcano Europe, Belgium** and **Biosensors S.A., Switzerland**.

Background

- Statins potently reduce cardiovascular events and IVUS studies have shown that high intensity statin therapy results in atheroma regression in stable CAD patients.
- Acute STEMI remain have not been included in IVUS regression studies despite their higher risk for recurrent events and high frequency of vulnerable plaques typically extending beyond the culprit lesion.
- Plaque phenotype is relevant in the pathogenesis of future events. Therefore, it is of interest to study changes in plaque composition in response to high-intensity statin therapy.

Hypothesis

Coronary atherosclerosis regression can be achieved by the highest dose of rosuvastatin therapy (40 mg daily) in the proximal segments of non-infarct related arteries of STEMI patients within 13 months.

Similarly, a reduction of RF-IVUS defined necrotic core and a decrease in the frequency of high risk plaque (thin cap fibroatheromas) can be achieved.

1161 Acute STEMI Patients
1:1 Randomization
Biomatrix vs. BMS
(COMFORTABLE AMI)
11 international sites
Inclusion 9/2009 - 1/2011

103 Acute STEMI Patients

Proximal part (>40 mm)
2 major non-IRA vessels

5 Sites (N=103)

Bern (60)
Copenhagen (21)
Geneva (13)
Lugano (6)
Zurich (3)

Rosuvastatin
20 mg
over 2 Weeks

Rosuvastatin
40mg
over 13 Mo

BL

FUP

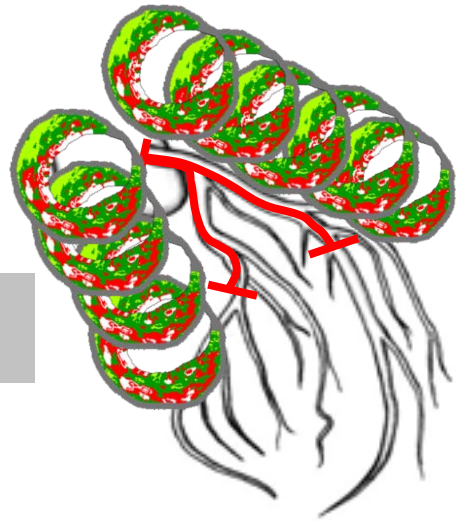

1° Endpoint @ 13mo
Change in % Atheroma Volume
Change in % Necrotic Core

PRIMARY IVUS AND RF-IVUS ENDPOINT

1° IVUS EP Percent Atheroma Volume

43.95 ± 9.66 %

43.02 ± 9.82 %

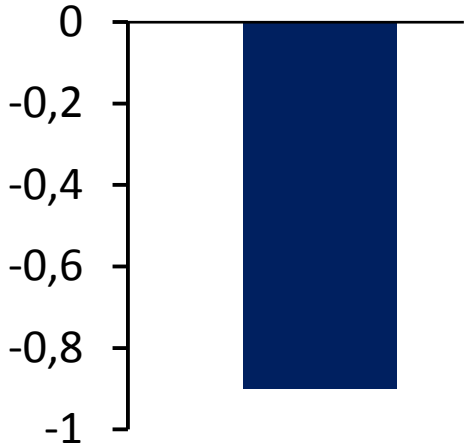

-0.9% (-1.56 to -0.25)
P=0.007

1° RF-EP Change Percent Necrotic Core

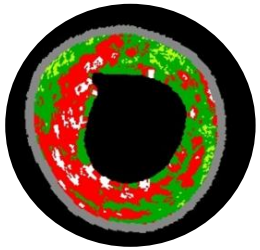

Baseline

21.14 ± 7.43 %

Δ -0.05 % (-1.05 to 0.96), p=0.93



13 Months F/U

21.02 ± 7.04 %

RF-IVUS Lesion Phenotype Analysis

82 serially assessed patients with 146 analysed vessels

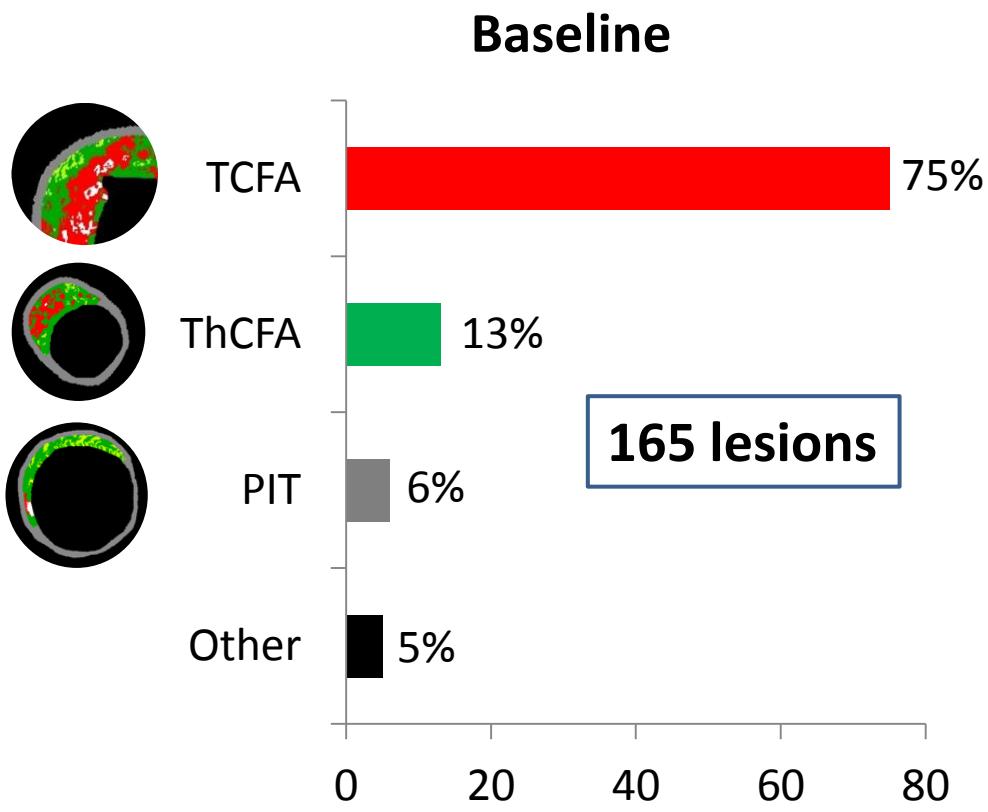

Other: fibrocalcific, fibrotic
1 lesion was not present at BL but at FUP

CONCLUSIONS

- The proximal segments of non-IRA of STEMI patients feature a high atherosclerotic plaque burden with the majority of lesions characterized as thin-cap fibroatheromas.
- High-intensity statin therapy throughout 13 months is associated with a significant reduction of coronary atherosclerosis.
- High-intensity statin therapy did not change the proportion of necrotic core and plaque phenotypes.

European Heart Journal
doi:10.1093/eurheartj/ehu373

Imaging

Effect of high-intensity statin therapy on atherosclerosis in non-infarct-related coronary arteries (IBIS-4): a serial intravascular ultrasonography study

Lorenz Räber[1], Masanori Taniwaki[1], Serge Zaugg[2], Henning Kelbæk[3], Marco Roffi[4], Lene Holmvang[3], Stephane Noble[4], Giovanni Pedrazzini[5], Aris Moschovitis[1], Thomas F. Lüscher[6], Christian M. Matter[6], Patrick W. Serruys[7], Peter Jüni[8], Hector M. Garcia-Garcia[7], and Stephan Windecker[1], for the IBIS 4 (Integrated Biomarkers and Imaging Study-4) Trial Investigators (NCT00962416)

[1]Department of Cardiology, Bern University Hospital, 3010, Bern, Switzerland; [2]Clinical Trials Unit, Bern University, Bern, Switzerland; [3]Cardiac Catheterization Laboratory, Rigshospitalet, Copenhagen, Denmark; [4]Division of Cardiology, University Hospital, Geneva, Switzerland; [5]Cardiocentro Ticino, Lugano, Switzerland; [6]Cardiology Department, University Hospital Zurich, Zurich, Switzerland; [7]Cardialysis BV, Rotterdam, The Netherlands; and [8]Institute of Social and Preventive Medicine, University of Bern, Bern, Switzerland

Received 14 July 2014; revised 8 August 2014; accepted 12 August 2014

This paper was guest edited by Filippo Crea (Università Cattolica del Sacro Cuore, Rome, Italy, filippo.crea@rm.unicatt.it).

Aim The effect of long-term high-intensity statin therapy on coronary atherosclerosis among patients with acute ST-segment elevation myocardial infarction (STEMI) is unknown. The aim of this study was to quantify the impact of high-intensity statin therapy on plaque burden, composition, and phenotype in non-infarct-related arteries of STEMI patients undergoing primary percutaneous coronary intervention (PCI).

Methods and results Between September 2009 and January 2011, 103 STEMI patients underwent intravascular ultrasonography (IVUS) and radiofrequency ultrasonography (RF-IVUS) of the two non-infarct-related epicardial coronary arteries (non-IRA) after successful primary PCI. Patients were treated with high-intensity rosuvastatin (40 mg/day) throughout 13 months and serial intracoronary imaging with the analysis of matched segments was available for 82 patients with 146 non-IRA. The primary IVUS end-point was the change in per cent atheroma volume (PAV). After 13 months, low-density lipoprotein cholesterol (LDL-C) had decreased from a median of 3.29 to 1.89 mmol/L ($P < 0.001$), and high-density lipoprotein cholesterol (HDL-C) levels had increased from 1.10 to 1.20 mmol/L ($P < 0.001$). PAV of the non-IRA decreased by −0.9% (95% CI: −1.56 to −0.25, $P = 0.007$). Patients with regression in at least one non-IRA were more common (74%) than those without (26%). Per cent necrotic core remained unchanged (−0.05%, 95% CI: −1.05 to 0.96%, $P = 0.93$) as did the number of RF-IVUS defined thin cap fibroatheromas (124 vs. 116, $P = 0.15$).

Conclusion High-intensity rosuvastatin therapy over 13 months is associated with regression of coronary atherosclerosis in non-infarct-related arteries without changes in RF-IVUS defined necrotic core or plaque phenotype among STEMI patients.

Keywords Intravascular Ultrasound • Radiofrequency • Statin • Atherosclerosis • ST-elevation myocardial infarction

*Corresponding author. Tel: +41 31 632 88 97, Fax: +41 31 632 47 30, Email: stephan.windecker@insel.ch

Published on behalf of the European Society of Cardiology. All rights reserved. © The Author 2014. For permissions please e-mail: journals.permissions@oup.com.