Aplicaciones Clínicas de la Tomografia de Coherencia Óptica.

¿Aporta más qué el IVUS?

SOCIEDAD LATINOAMERICANA DE CARDIOLOGIA INTERVENCIONISTA

XXII Jornadas SOLACI

La Paz – Noviembre/2013

Ultrasonido Intracoronario

Cardiología Intervencionista

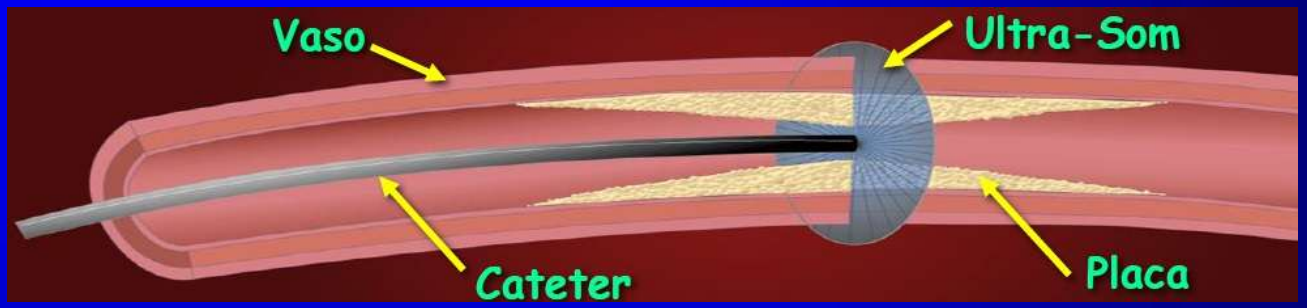

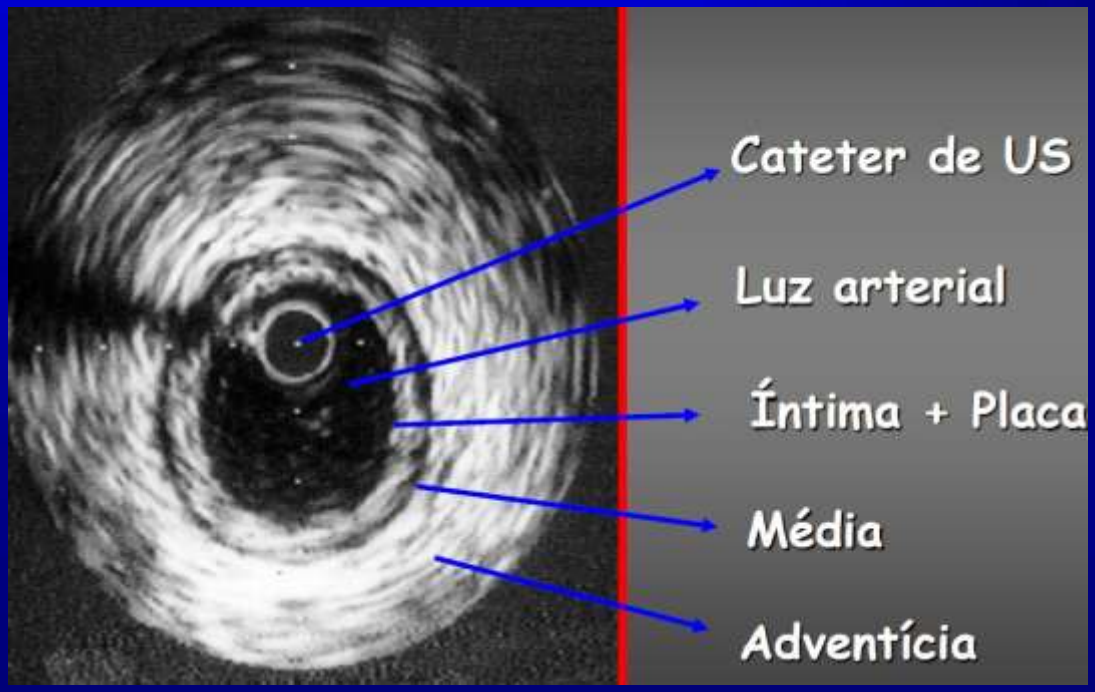



Stents Coronarios
Optimización del Implante

Intracoronary Stenting Without Anticoagulation Accomplished With Intravascular Ultrasound Guidance

Antonio Colombo, MD; Patrick Hall, MD; Shigeru Nakamura, MD; Yaron Almagor, MD; Luigi Maiello, MD; Giovanni Martini, CCP; Antonio Gaglione, MD; Steven L. Goldberg, MD; Jonathan M. Tobis, MD

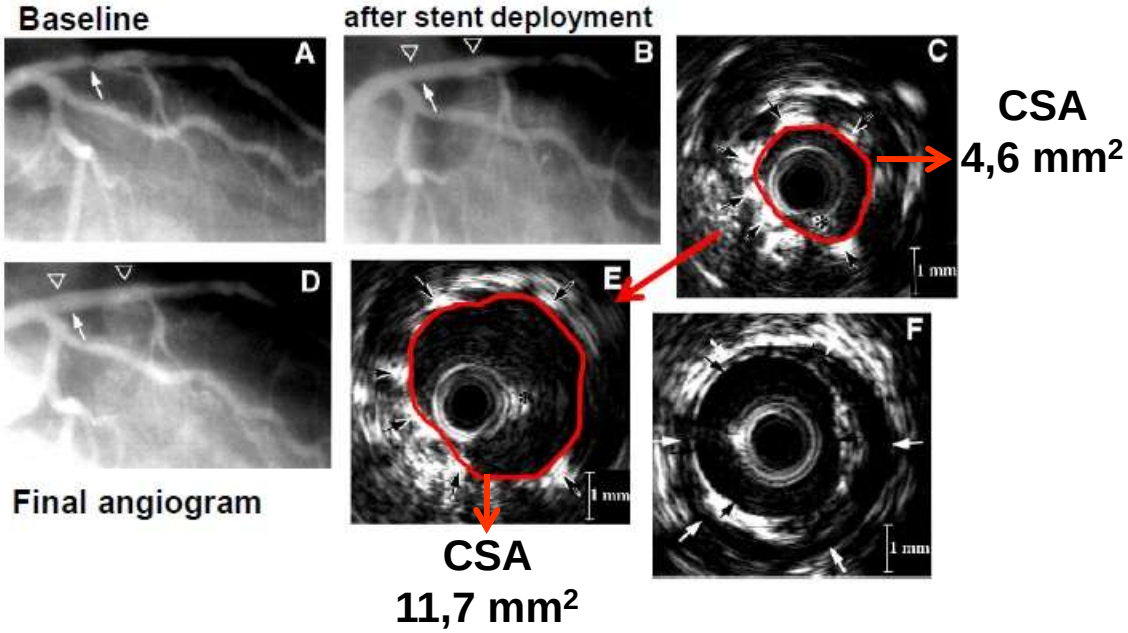

Despite this aggressive inflation approach, 40% of the stents with an acceptable angiographic result still required additional dilatation with higher pressures or, less commonly, a dilatation with a larger balloon

Colombo A. Circulation 1995;91:1076

Ultrasonido Intracoronario

Datos Qualitativos

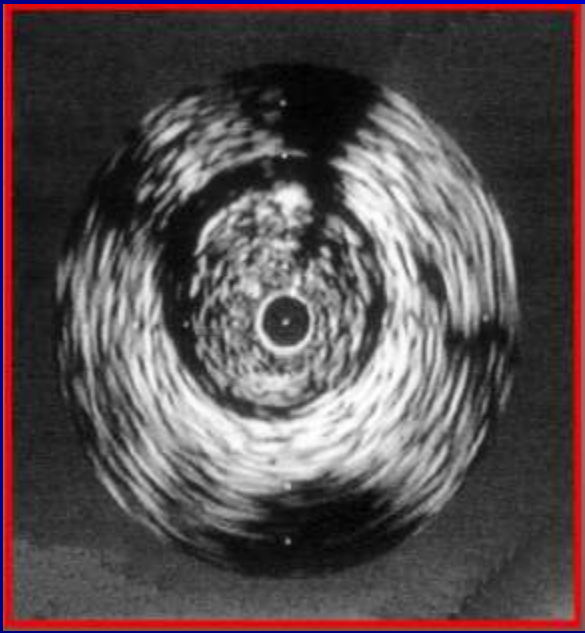

Lipídica

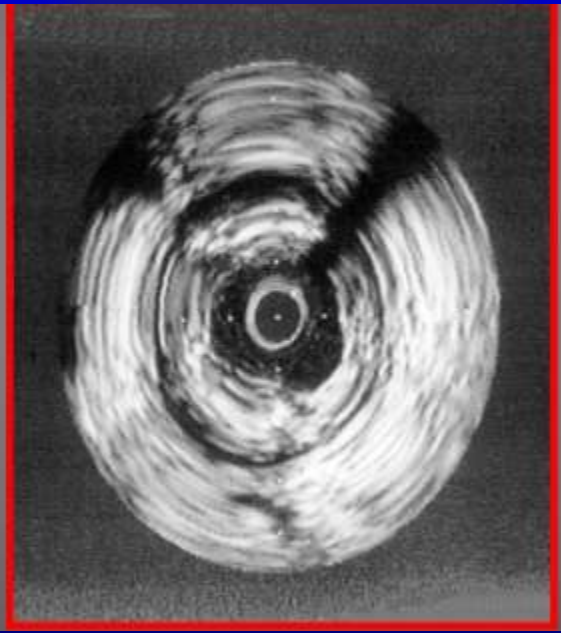

Fibrótica

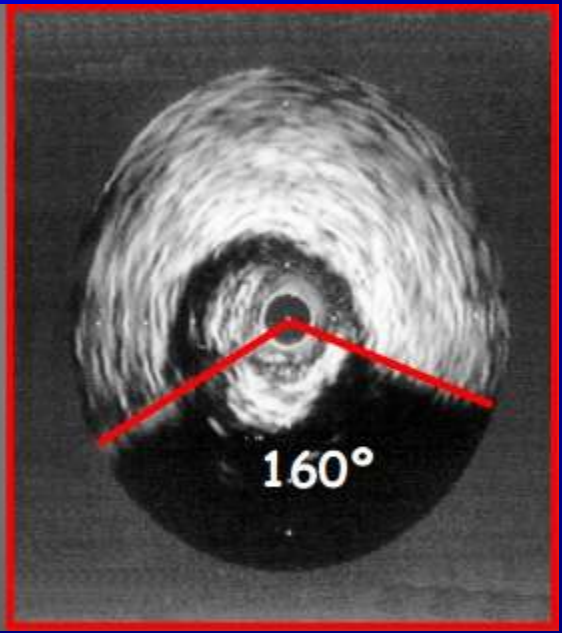

Calcificada

Ultrasonido Intracoronario

Datos Cuantitativos

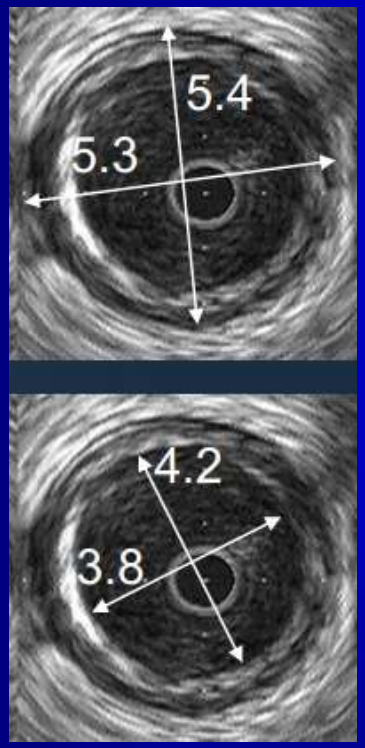

Diámetro del Vaso

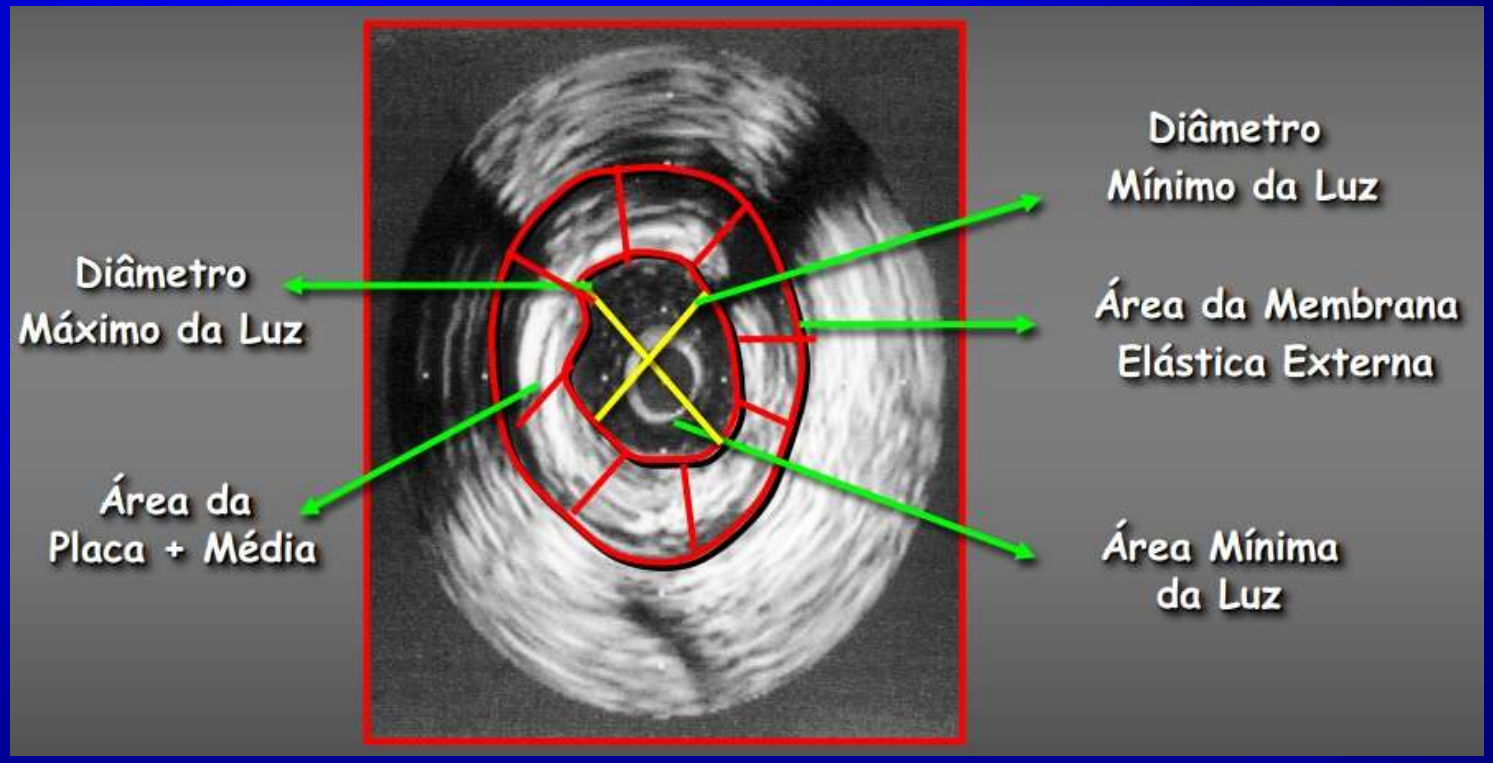

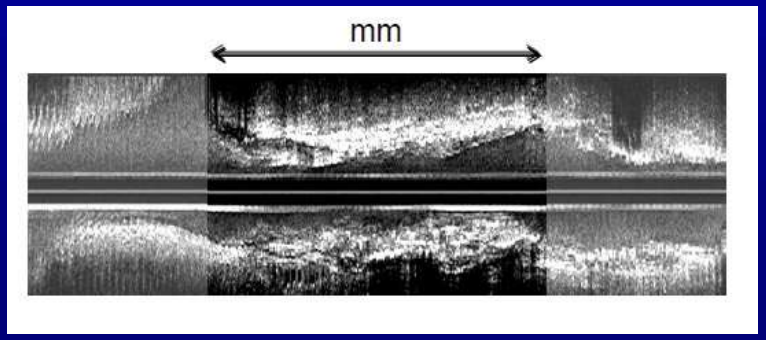

Extensión de la Lesión

Ultrasonido Intracoronario

Evaluación de Lesiones Intermediarias

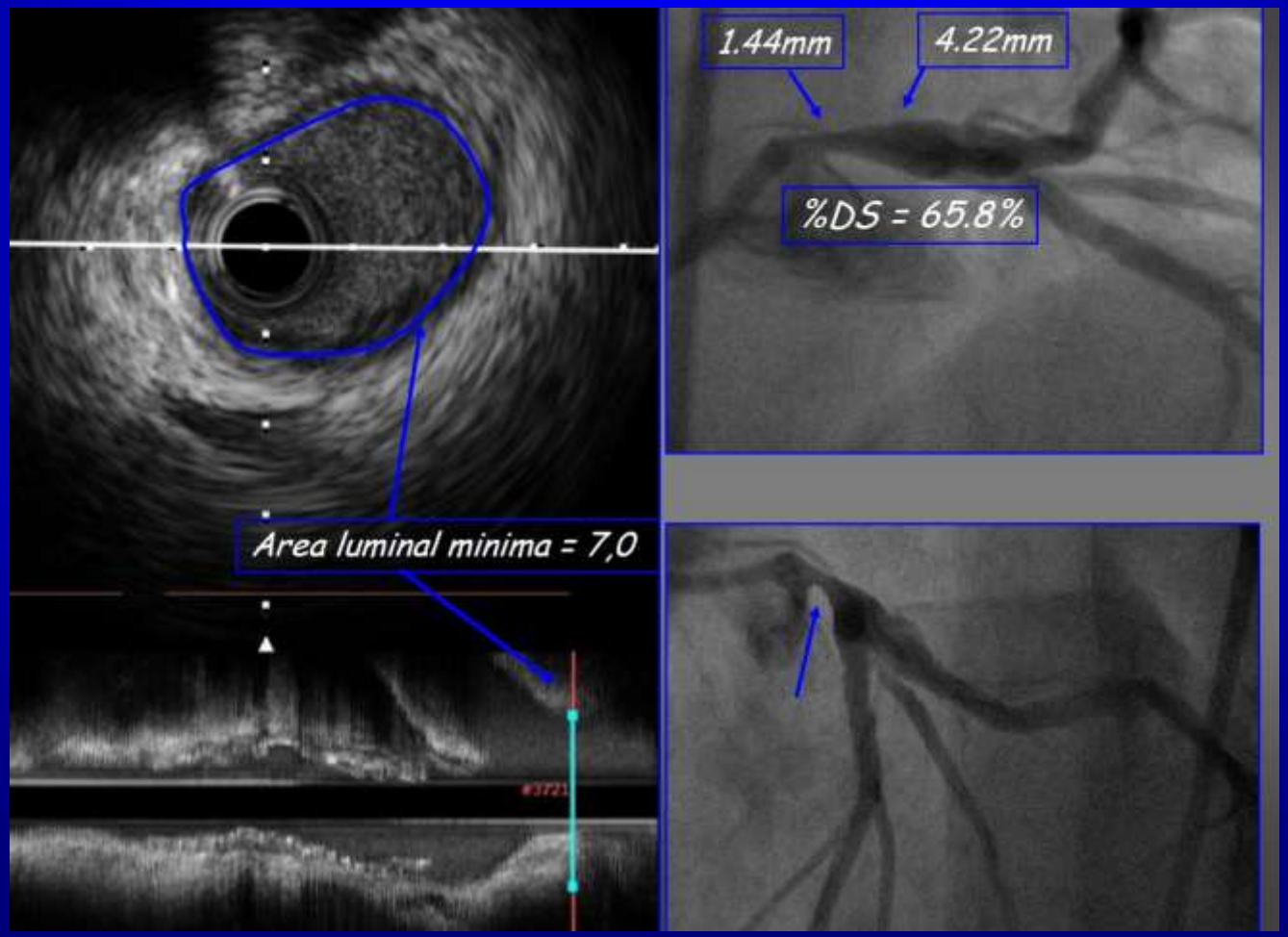

MAIN COMPARE REGISTRY

IVUS en el TCI - Mortalidad

n = 756 ICP TCI

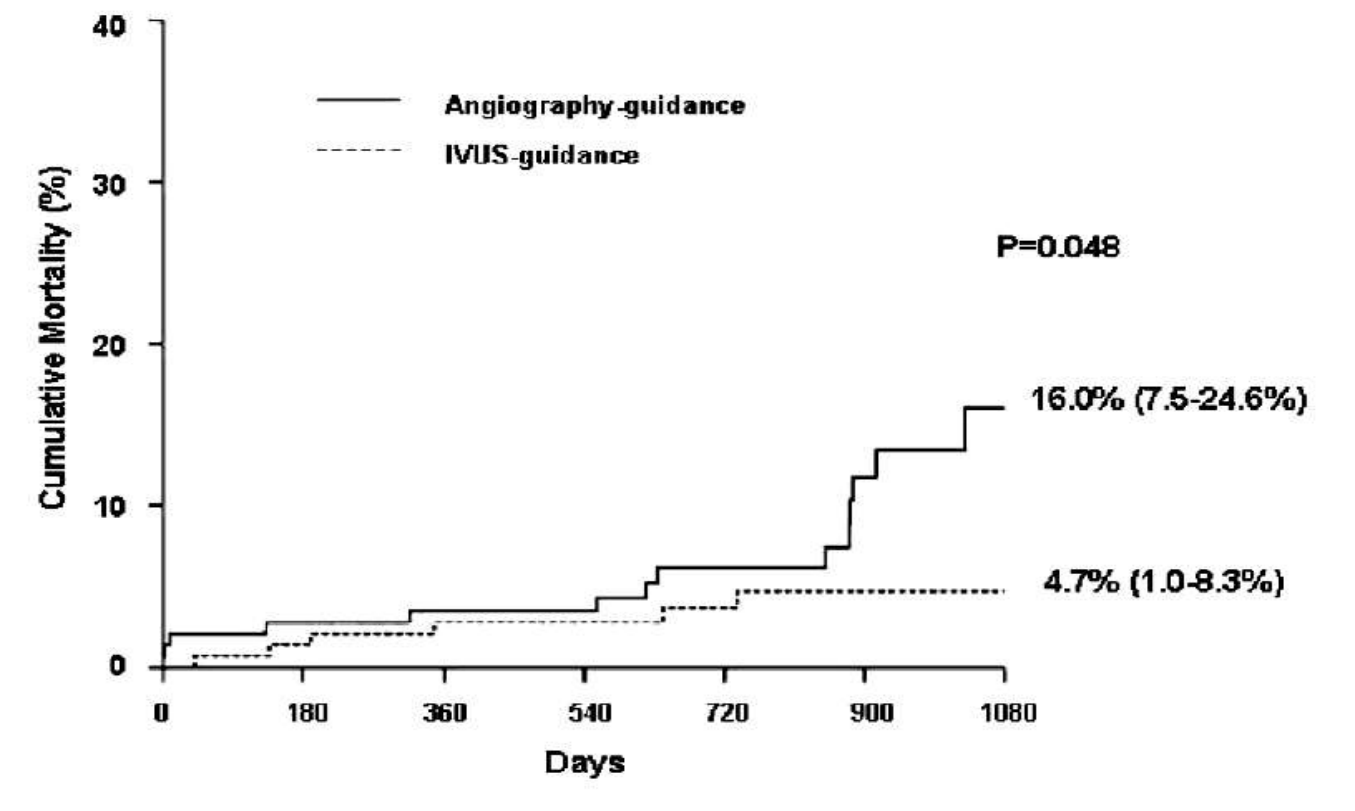

DES n = 145 matched pairs

Park S-J Circ Cardiovasc Intervent 2009;2:167-177

ICP en el TCI

Técnica de Mini-Crush

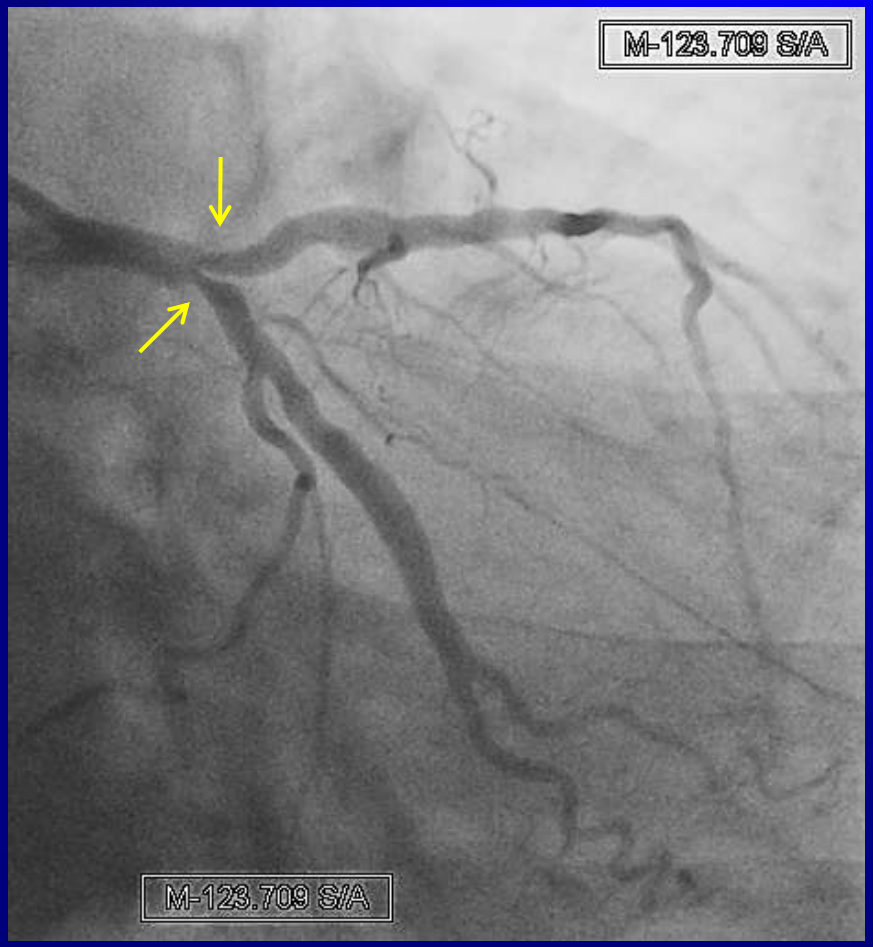

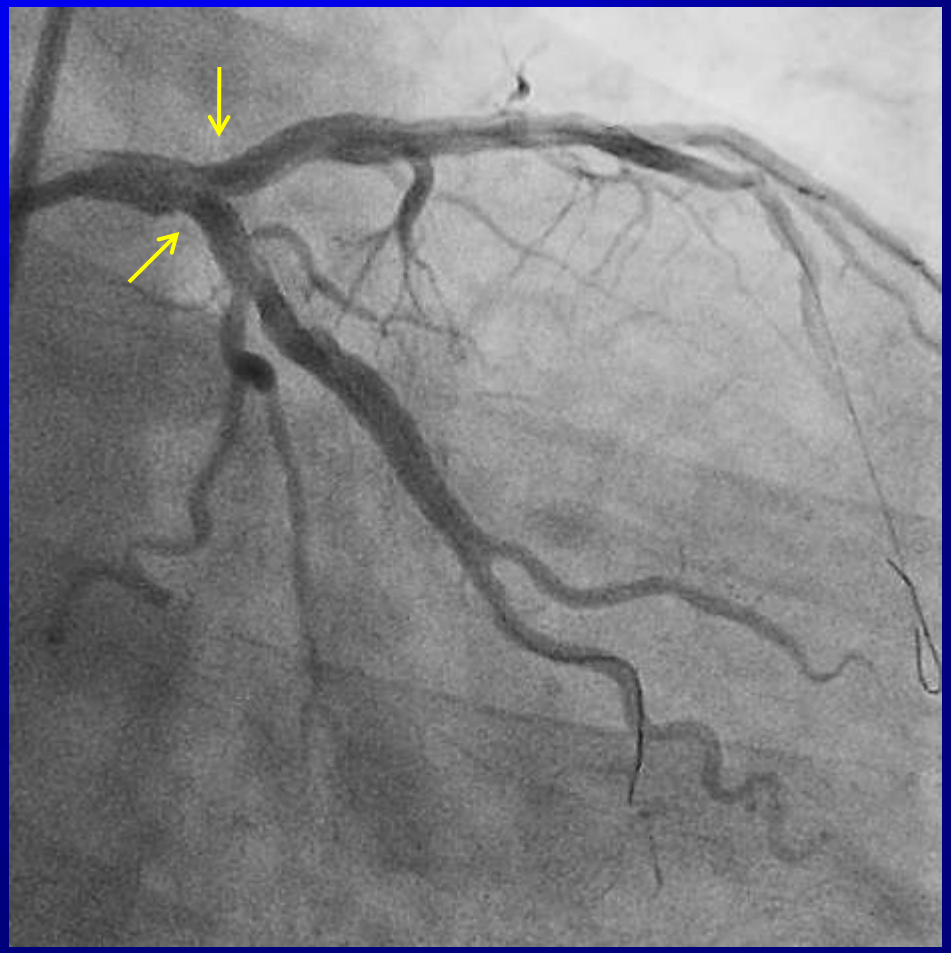

Tratamento Percutáneo do TCI

Ultrasonido Intracoronário

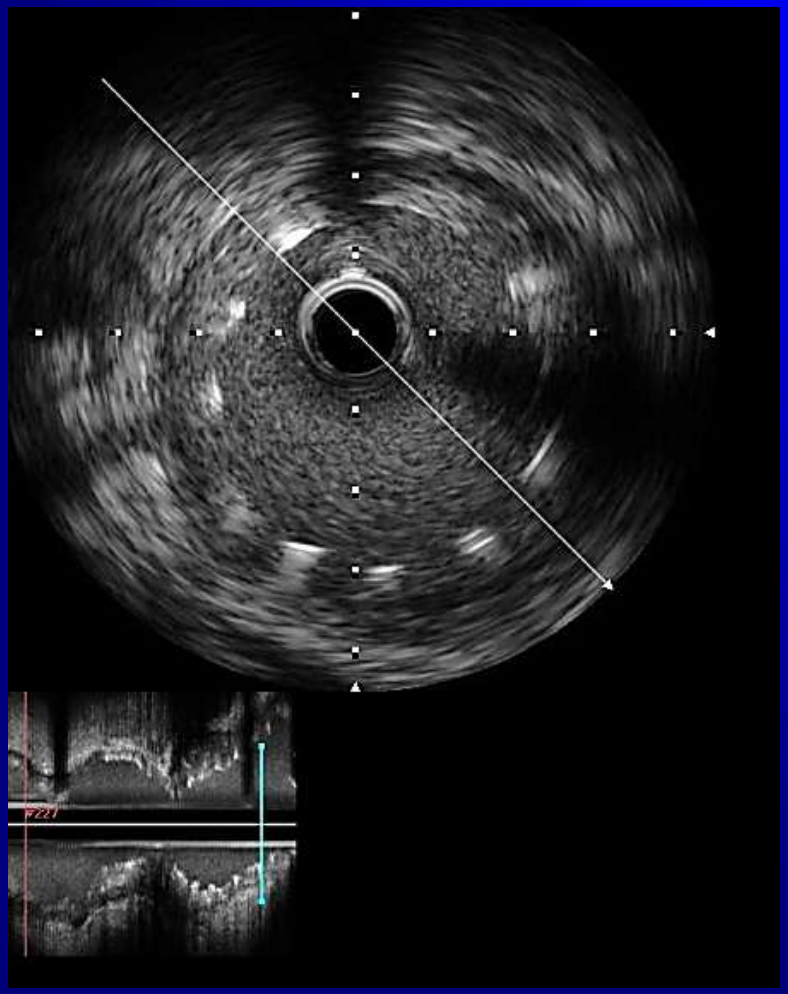

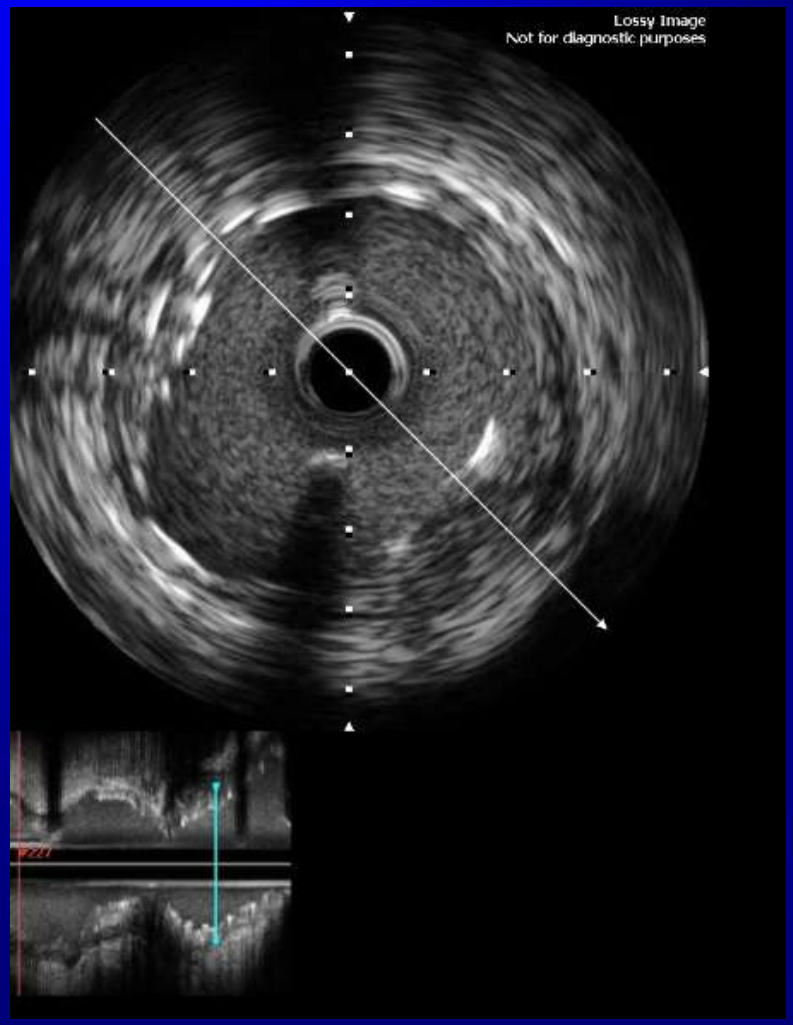

Tomografía de Coherencia Óptica (OCT)

Equipo de OCT



Cateter de Imagen

Dispositivo para Retroceder
25 mm/s

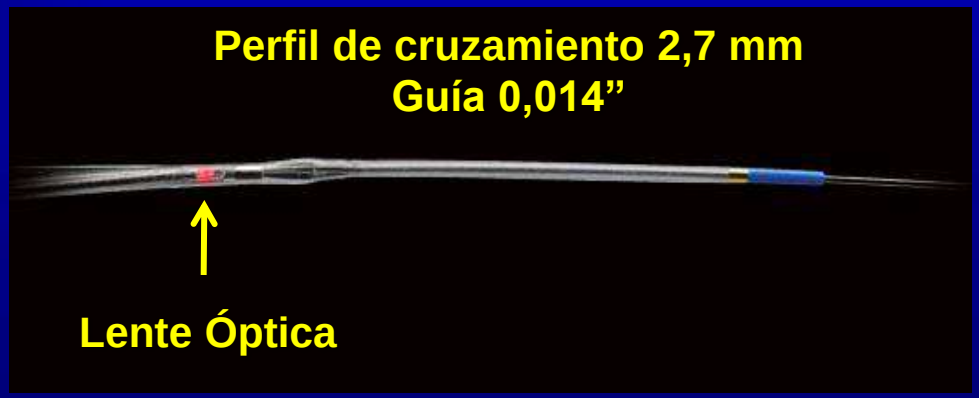

Parte Distal del Catéter

Consola de imagen
Fuente de Energía

Tomografía de Coherencia Óptica (OCT)

Definición

- **Es una modalidad de imagen invasiva, que utiliza haz luminosos (espectro ≈ infrarroja), con alta resolución axial (10-15µm) posibilitando visualizar micro-estructuras y materiales biológicos próximo a nivel histológico, mediante la medición del retardo de ecos ópticos reflejados de lo tejido investigado**

Tomografía de Coherencia Óptica

Técnica

- Fibra óptica envuelta por una vaina transparente, compatible con catéter 6 F
- Anticoagulación con heparina
- Nitroglicerina intracoronaria (100 a 200 µg)
- Posicionar o catéter 5 a 10 m distal a la región de interés
- Inyección de contraste (8 a 20ml) para retirar el flujo sanguíneo coronario (Hemoglobina – dispersa/atenúa la luz)

Comparación IVUS vs OCT

Penetración Tecidual y Resolución Espacial

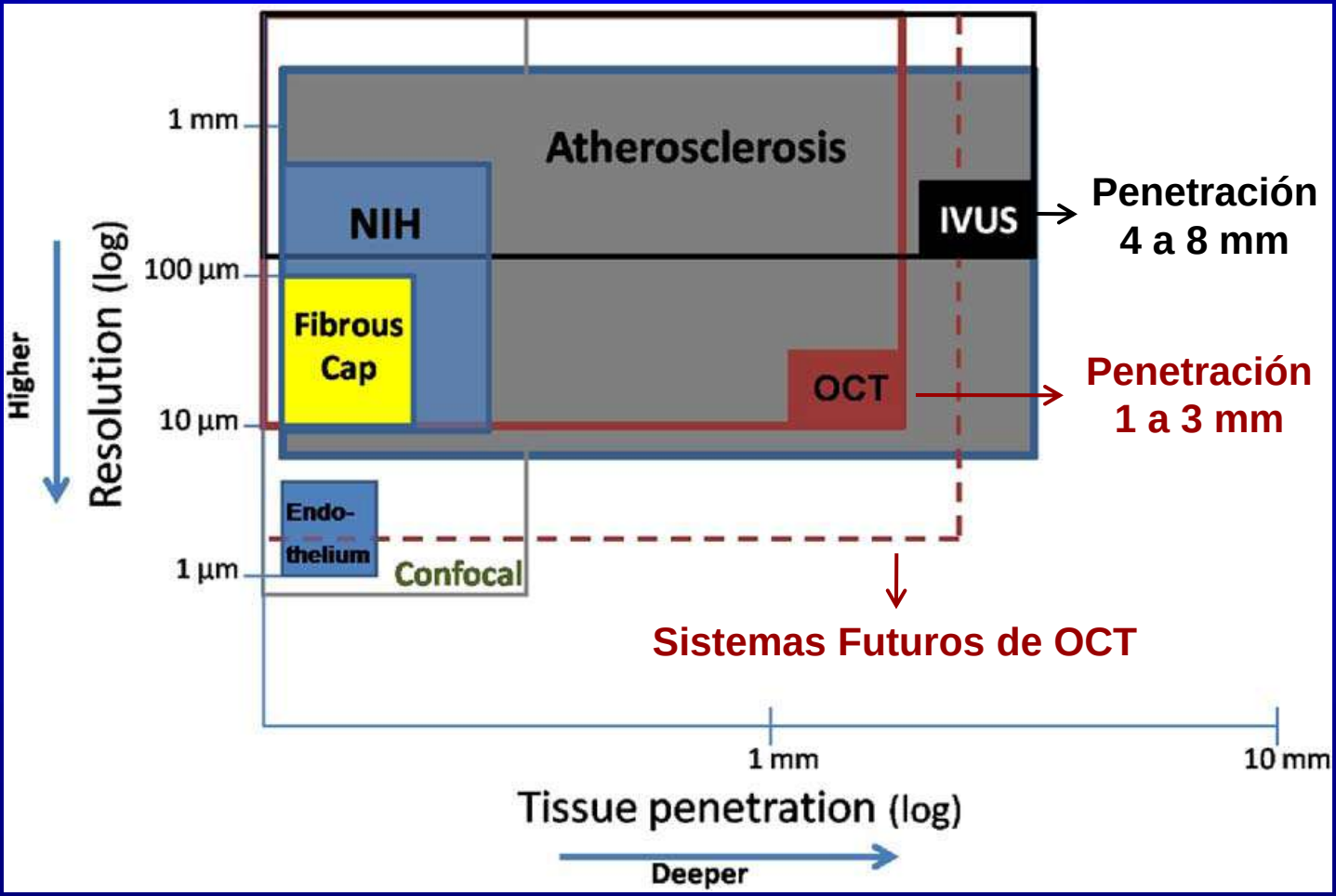

Bezerra H.B. J Am Coll Cardiol Intv 2009;2:1035-1046

Tomografía de Coherencia Óptica

Selección de Pacientes – Criterios Anatómicos

- **Puede ser utilizado en: bifurcaciones, segmentos proximales, lesiones ostiales de las arterias descendente anterior, circunfleja, porciones distales y cuerpo del TCI, injertos venosos o arteriales.**

- **Limitaciones**

- **Lesiones ostiales: TCI, CD y enjertos vasculares (necesidad de cateterización del ostium del vaso → eficiente "flush" vascular)**
- **Vasos con diámetro > 10mm - grande volumen de contraste y perdida de parte de la circunferencia vascular**

Tomografía de Coherencia Óptica

Vaso Coronario Normal

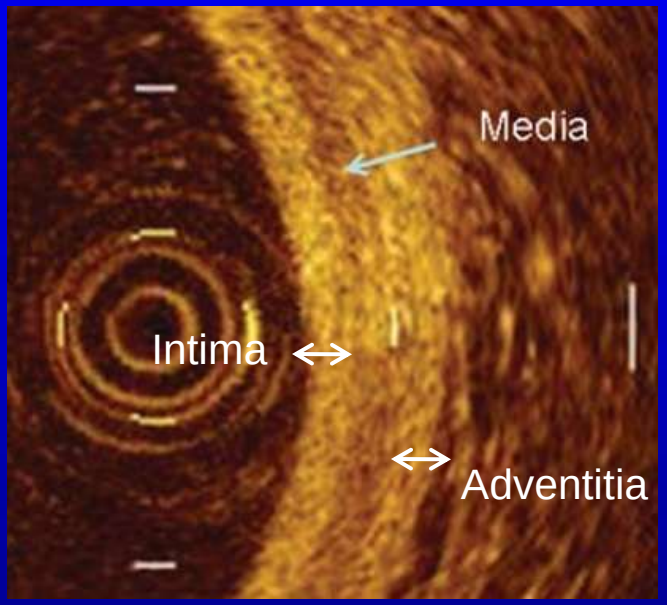

Alta precisión para visualizar las 3 camadas de la arteria

Íntima e Adventicia – alta intensidad de señal

Media – baja intensidad

Tomografía de Coherencia Óptica

Estadios Iníciales de Espesamiento de la Intima

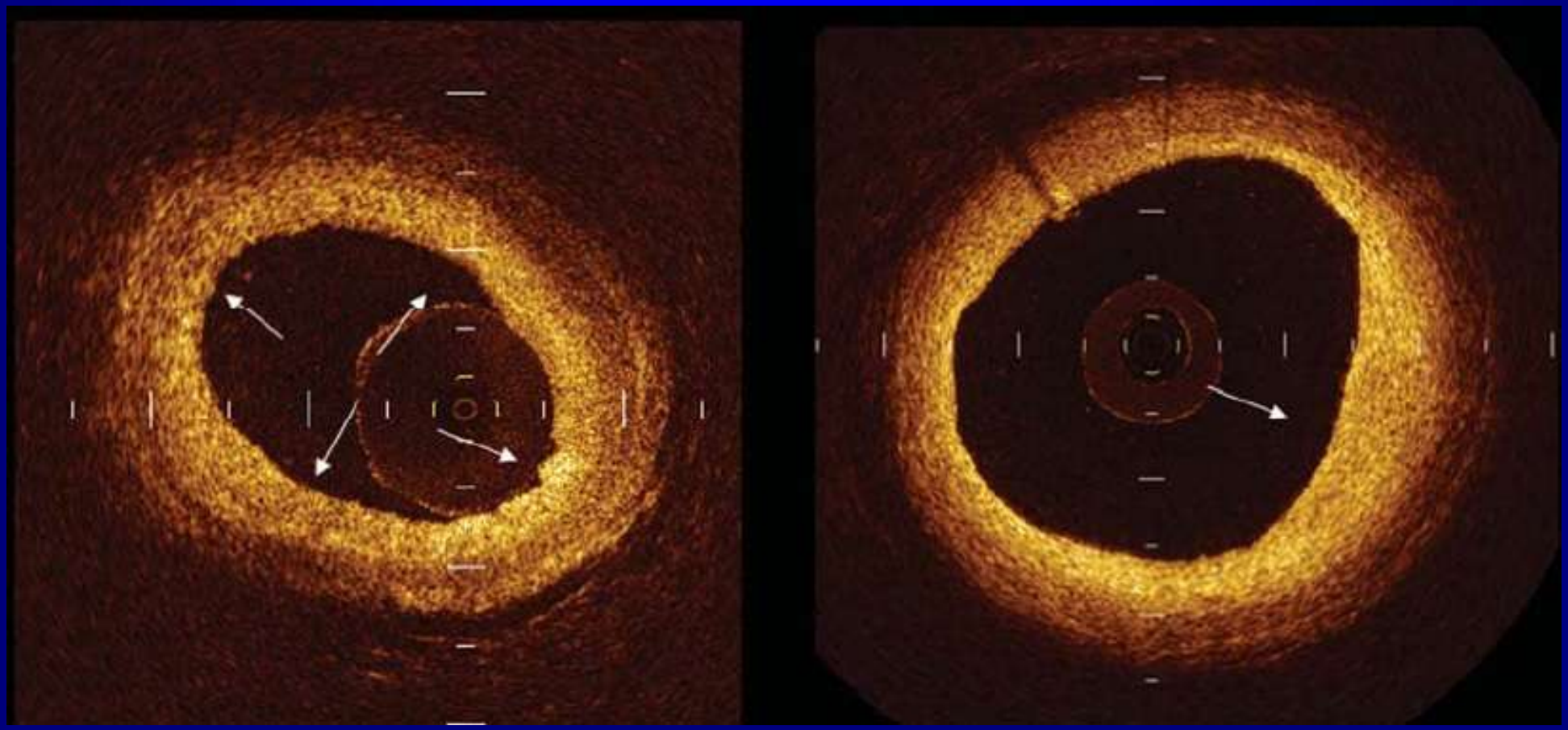

Difuso **Localizado**

Tomografía de Coherencia Óptica

Morfología de la Placa Aterosclerótica

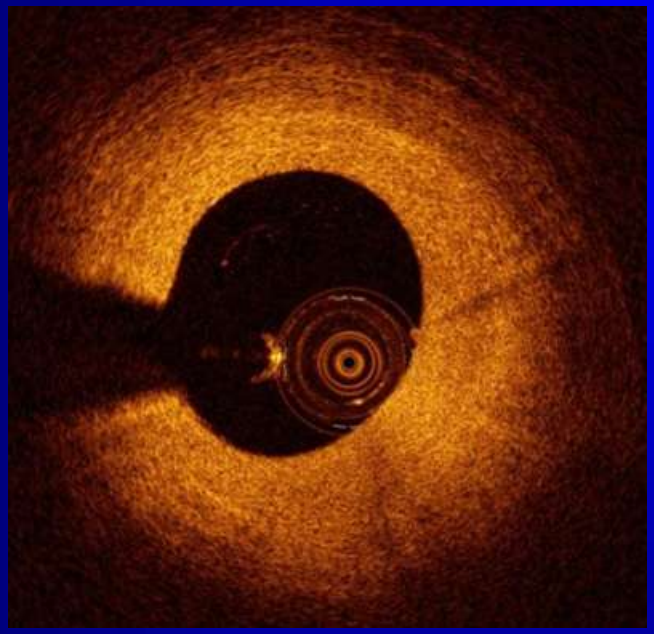

Fibrótica
Alta intensidad de señal
Homogéneo

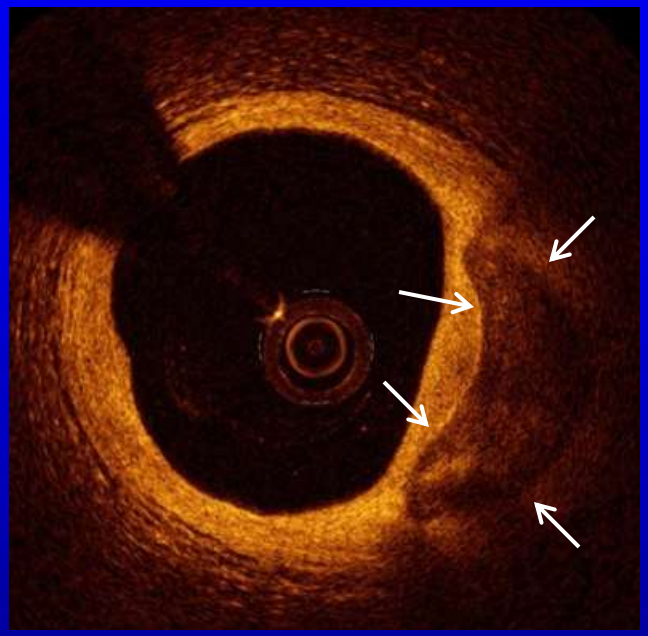

Fibrocalcificada
Baja intensidad de señal
Bordes bien definidos

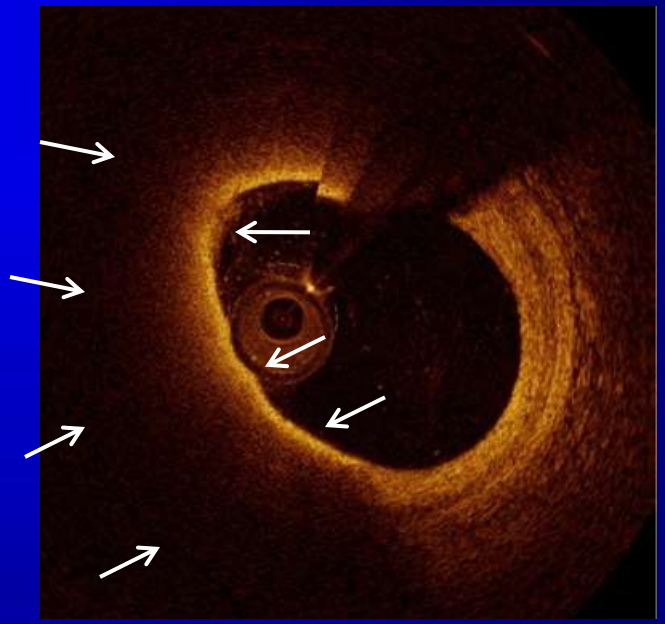

Lipídica
Baja intensidad de señal
Bordes imprecisos
Separada de la luz por una capa fibrótica (alta intensidad)

Tomografía de Coherencia Óptica

Identificación de la Placa Vulnerable

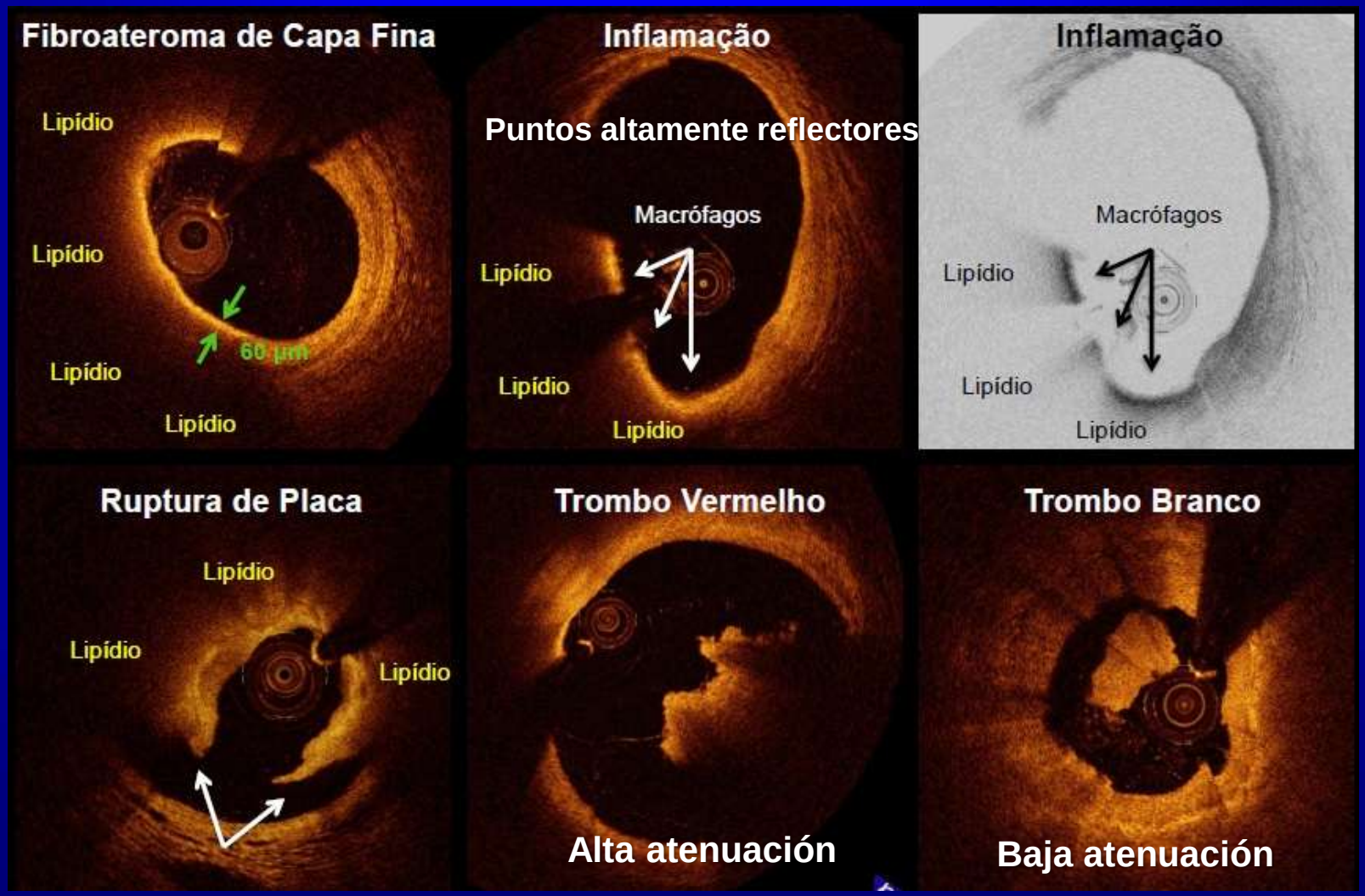

Tomografía de Coherencia Óptica

Morfologia de la Placa Vulnerable

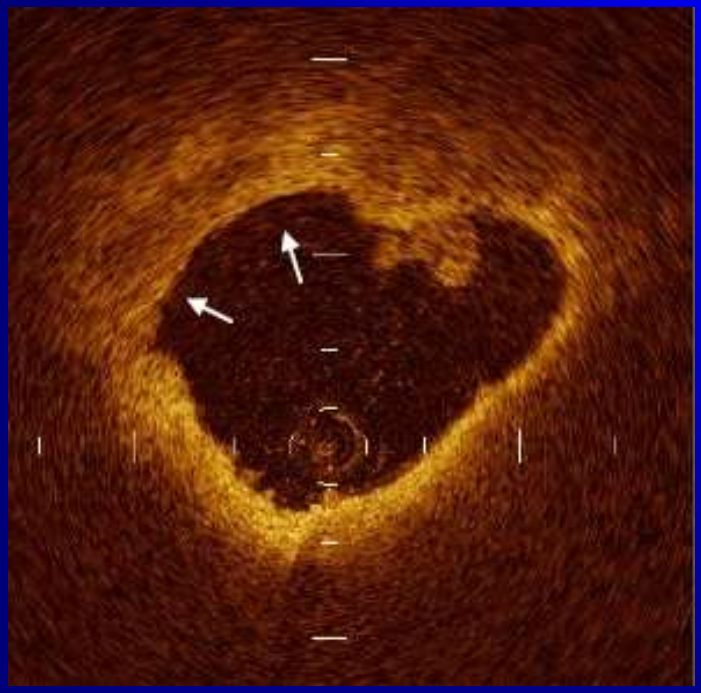

Erosión de la Capa Fibrótica

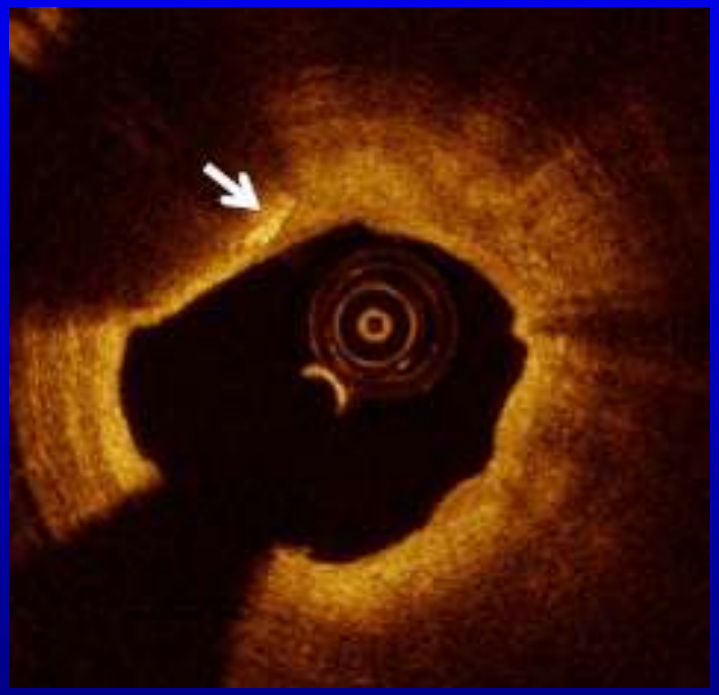

Cristales de Colesterol

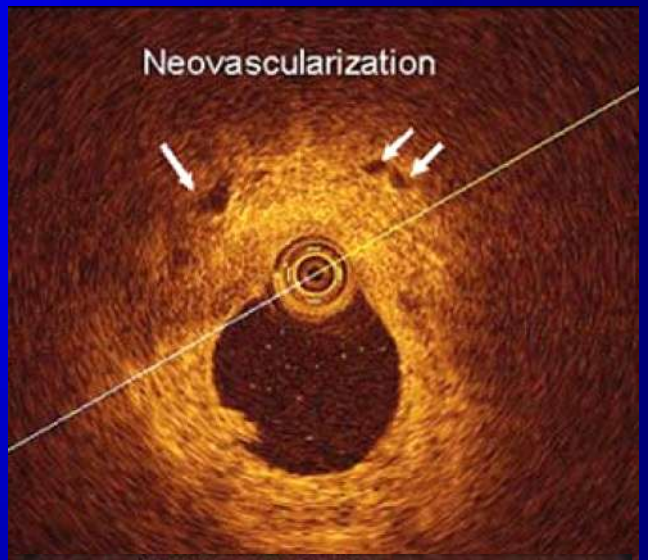

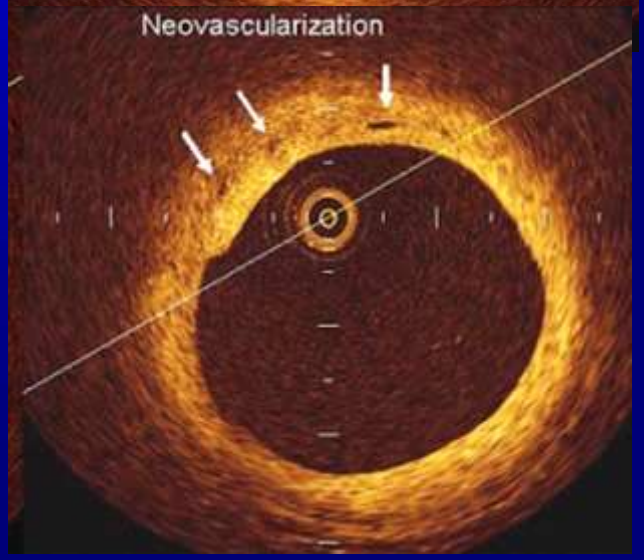

Tomografía de Coherencia Óptica
Preditores de Progresión de Lesiones

n = 69 lesiones no culpables angiografía 7 meses después ICP
Progresión en 13 pacientes (3 SCA)

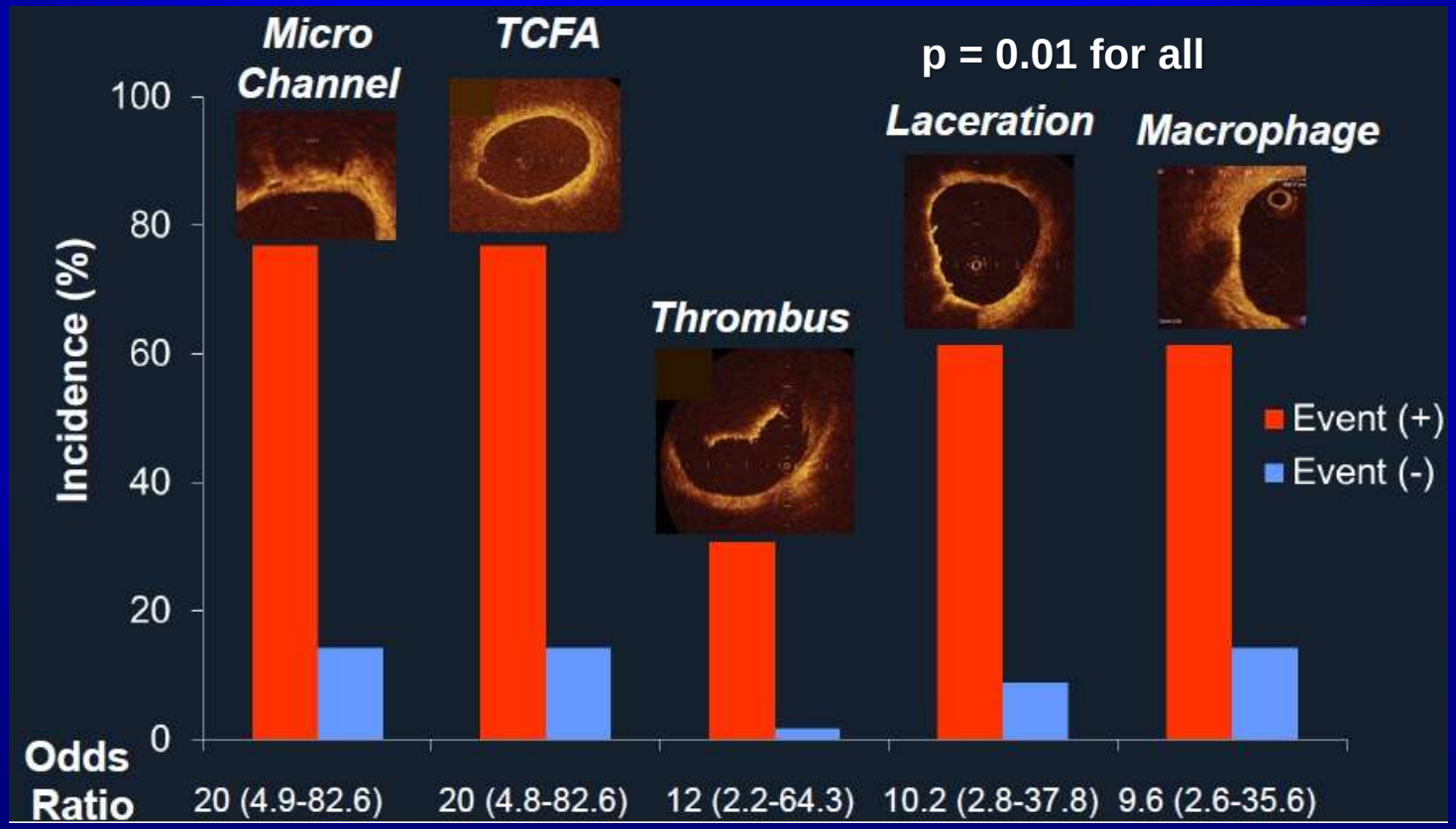

Uemura S. Eur Heart J 2012;33:78-85

Evaluación de las Lesiones Coronarias

ANGIO vs IVUS vs OCT

n = 100 pacientes con DAC 5 centros

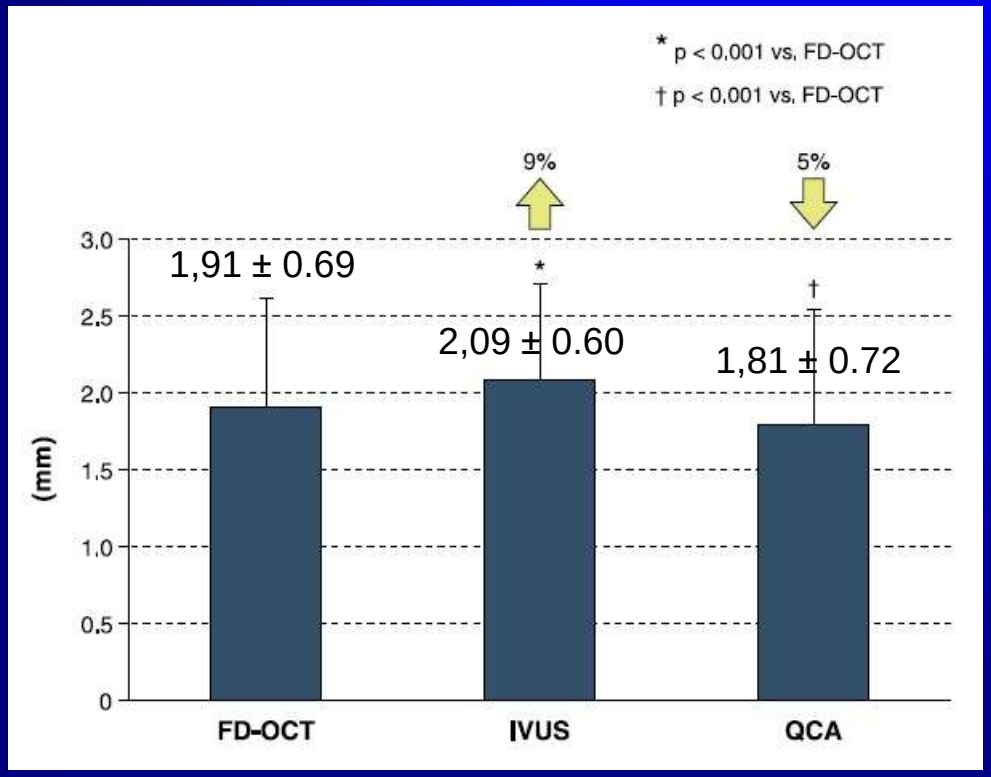

Diámetro Luminal Mínimo

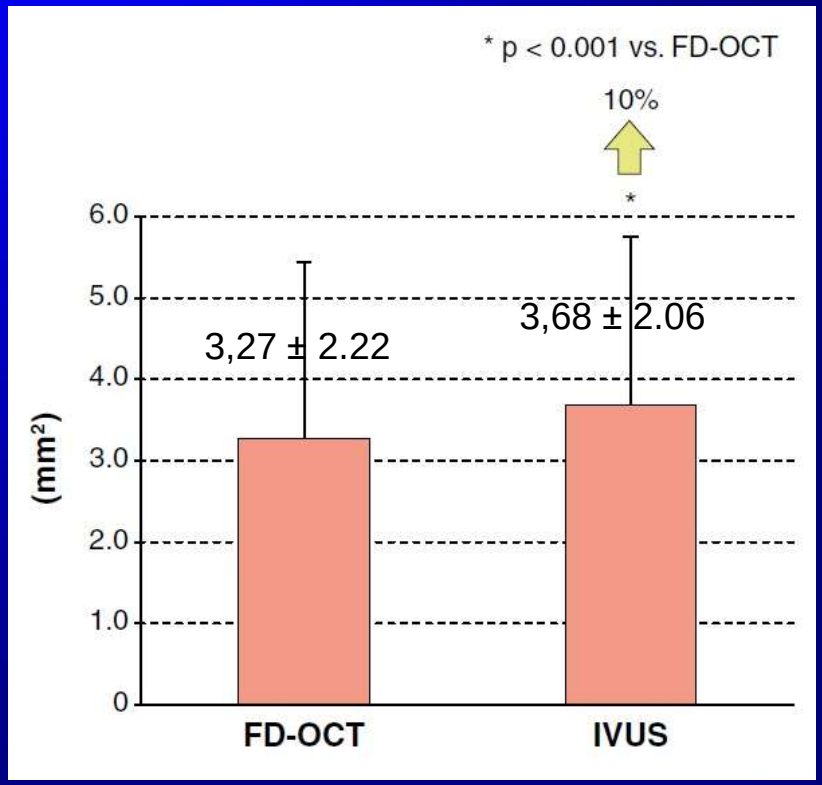

Área Luminal Mínima*

*** r = 0.95, p<0,001 mean difference 0.41 mm²**

Kubo T. J Am Coll Cardiol Img 2013;6:1095-1104

Evaluación de las Lesiones Coronarias

OCT vs IVUS vs OCT

Modelo Plástico (Politetrafluoroetileno)

Diámetro = 3.08 mm Área = 7.45 mm^2

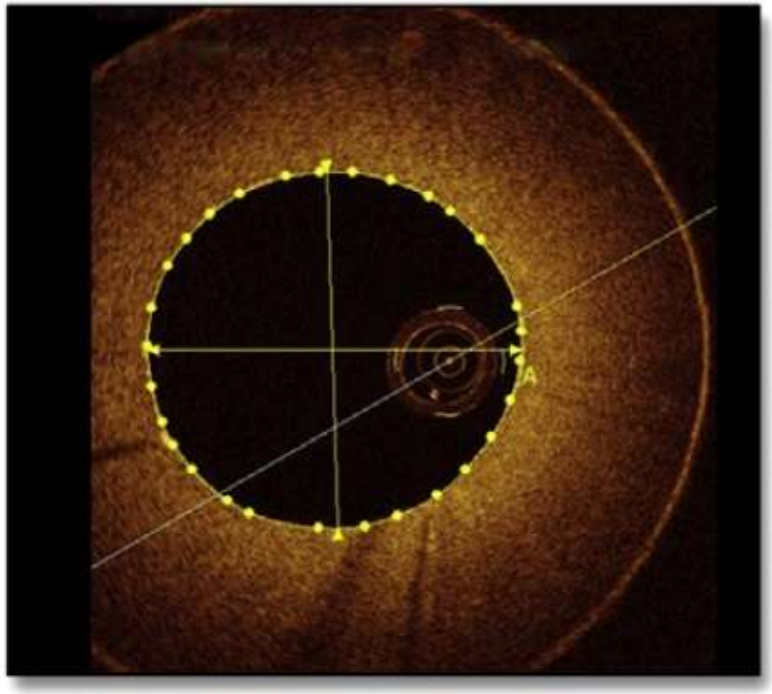

Area (mm^2) = 7.37

Diameter (mm): Min = 2.99; Max = 3.14; Mean = 3.06

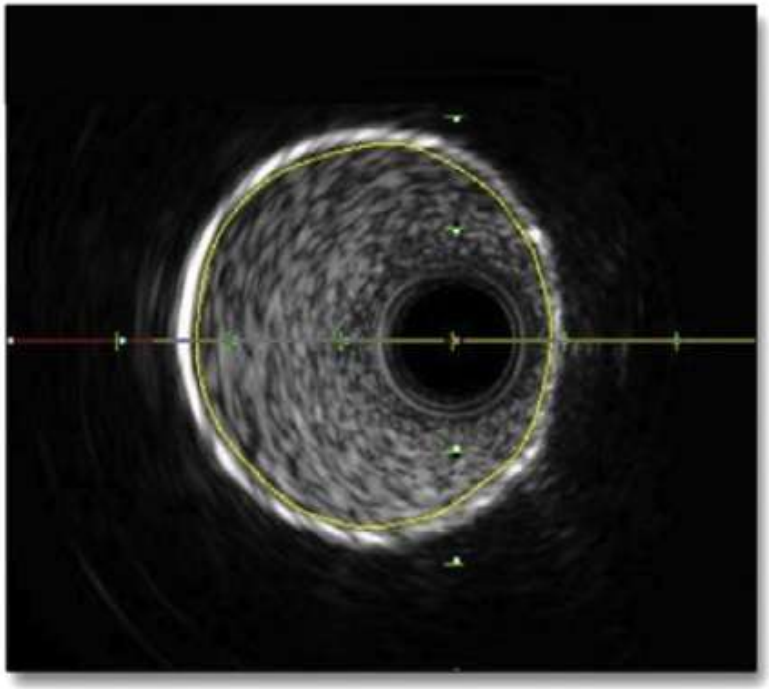

Area (mm^2) = 8.35

Diameter (mm): Min = 3.13; Max = 3.43; Mean = 3.27

Kubo T. J Am Coll Cardiol Img 2013;6:1095-1104

Tomografía de Coherencia Óptica
Evaluación de Lesiones Moderadas

n = 28 lesiones FFR ≤ 0,80

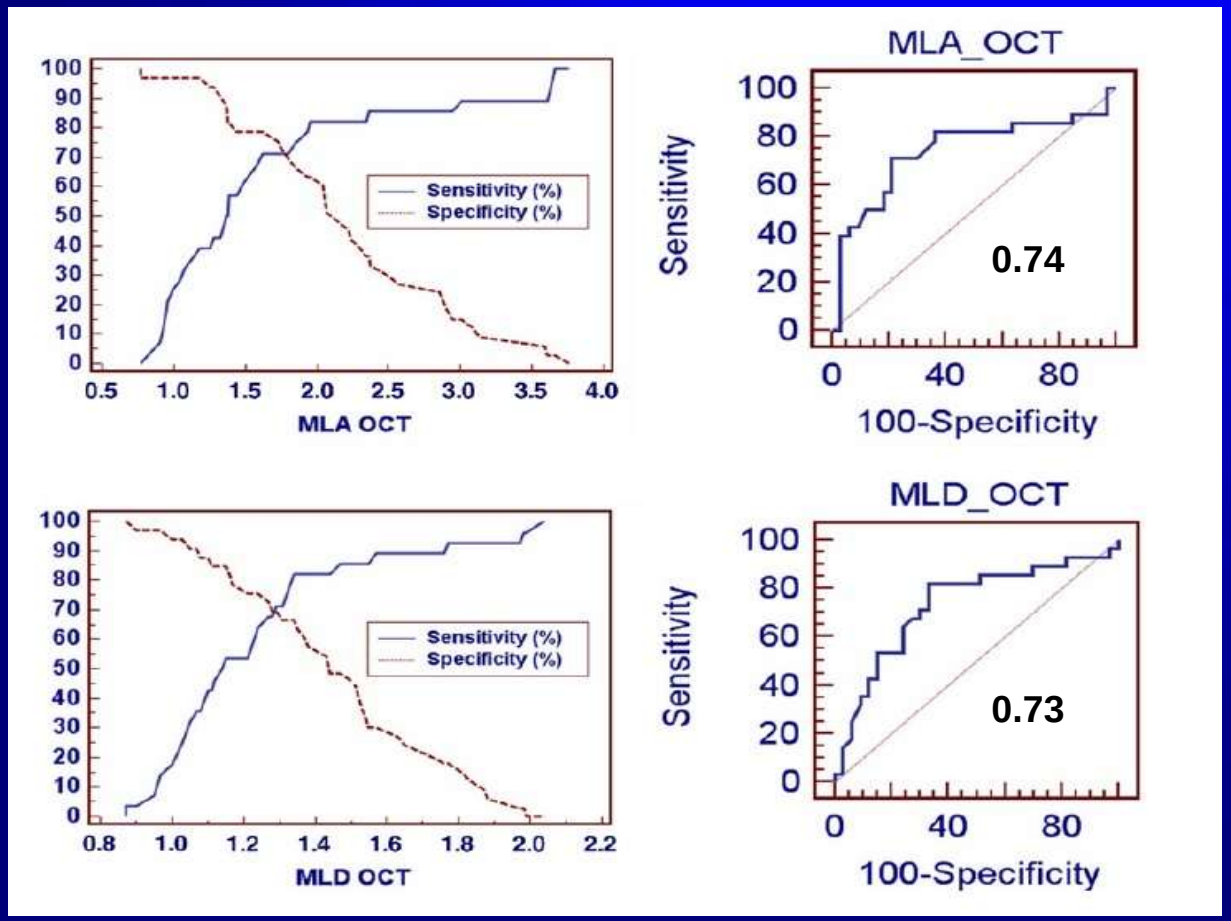

ALM < 1,95 mm²

Sensibilidad - 82%

Especificidad – 63%

VPP – 66%

VPN – 80%

Precisión – 72%

DLM < 1,34 mm

Sensibilidad - 82%

Especificidad – 67%

VPP – 68%

VPN – 81%

Precisión – 73%

Gonzalo N. J Am Coll Cardiol 2012;59:1080-1089

Tomografía de Coherencia Óptica
Evaluación de Lesiones Moderadas

n = 28 lesiones FFR ≤ 0,80

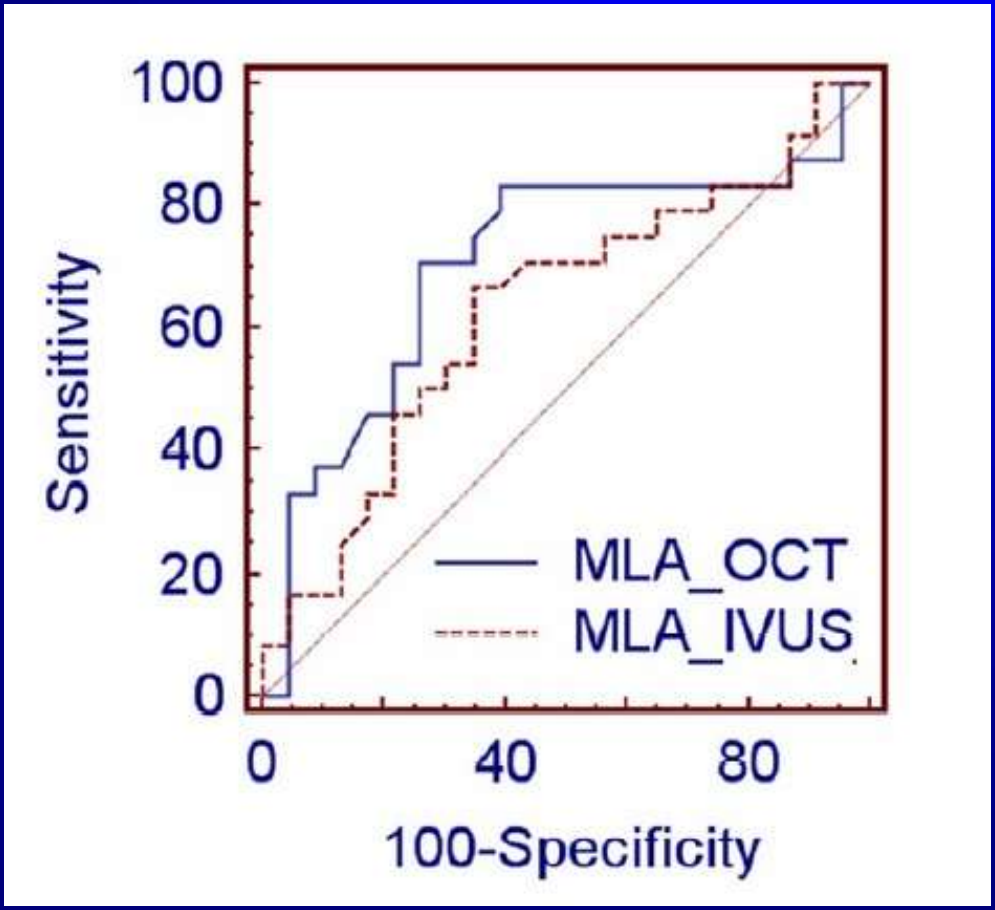

OCT

AUC 0.70;95%CI:0.55 to 0.83

IVUS

AUC 0.63;95%CI:0.47 to 0.77

p = 0.19

Gonzalo N. J Am Coll Cardiol 2012;59:1080-1089

Tomografía de Coherencia Óptica

Evaluación de los Resultados Inmediatos

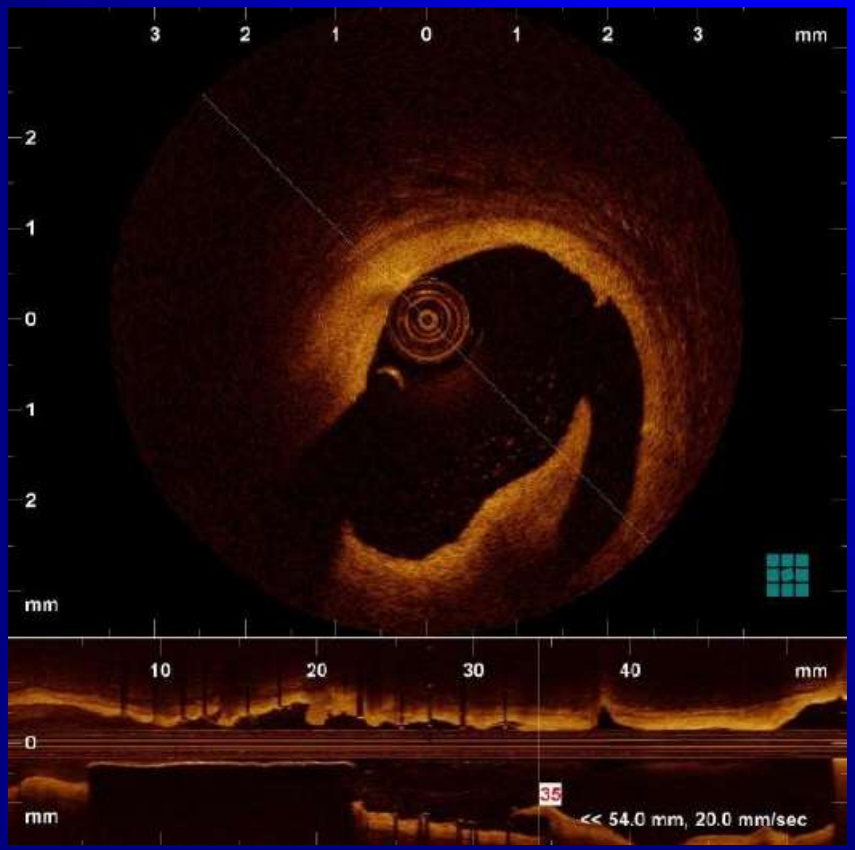

Disección de Borde

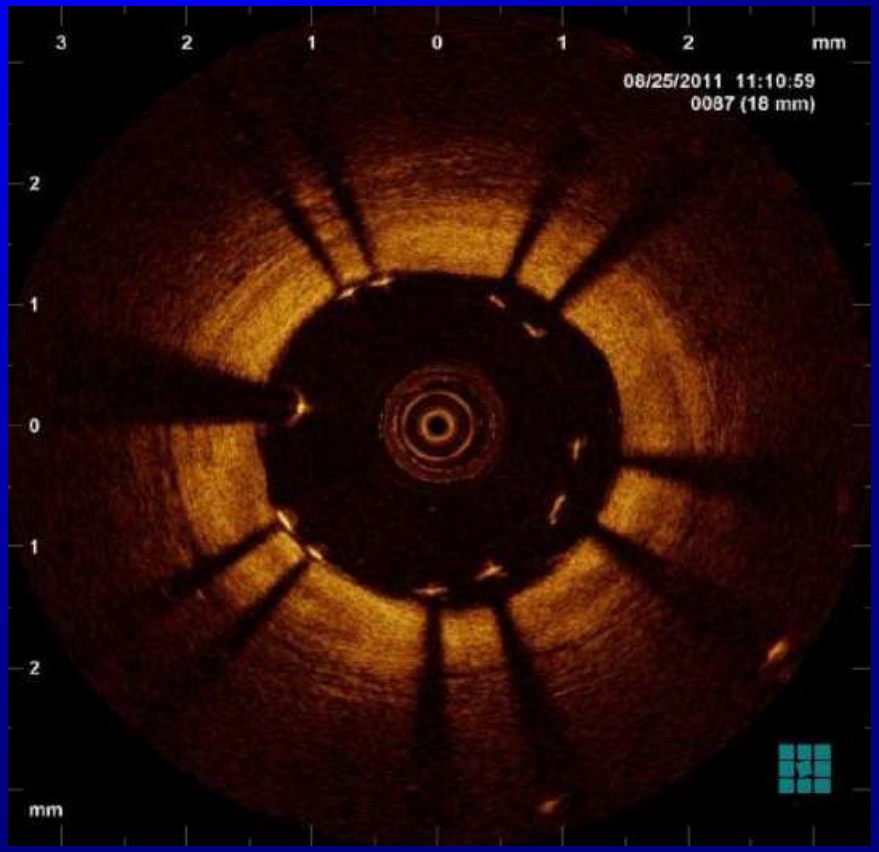

Incompleta Oposición

Tomografía de Coherencia Óptica

Evaluación de los Resultados Inmediatos

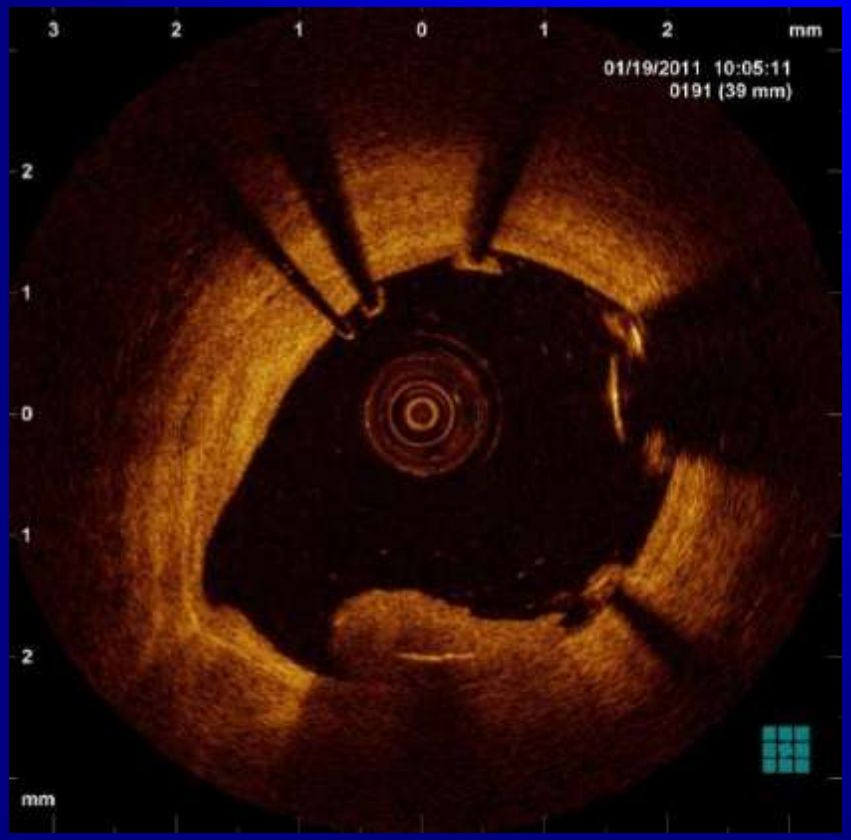

Trombo “In-Stent”

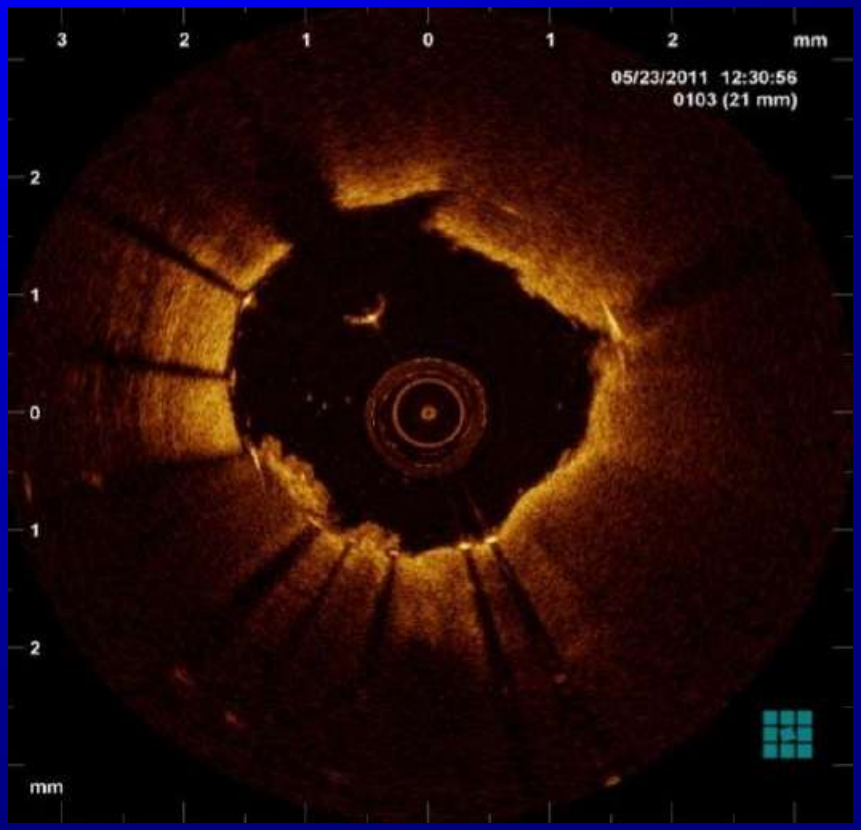

Prolapso de la Placa

Resultados Subótimos Pós Stents

Evaluación OCT vs IVUS

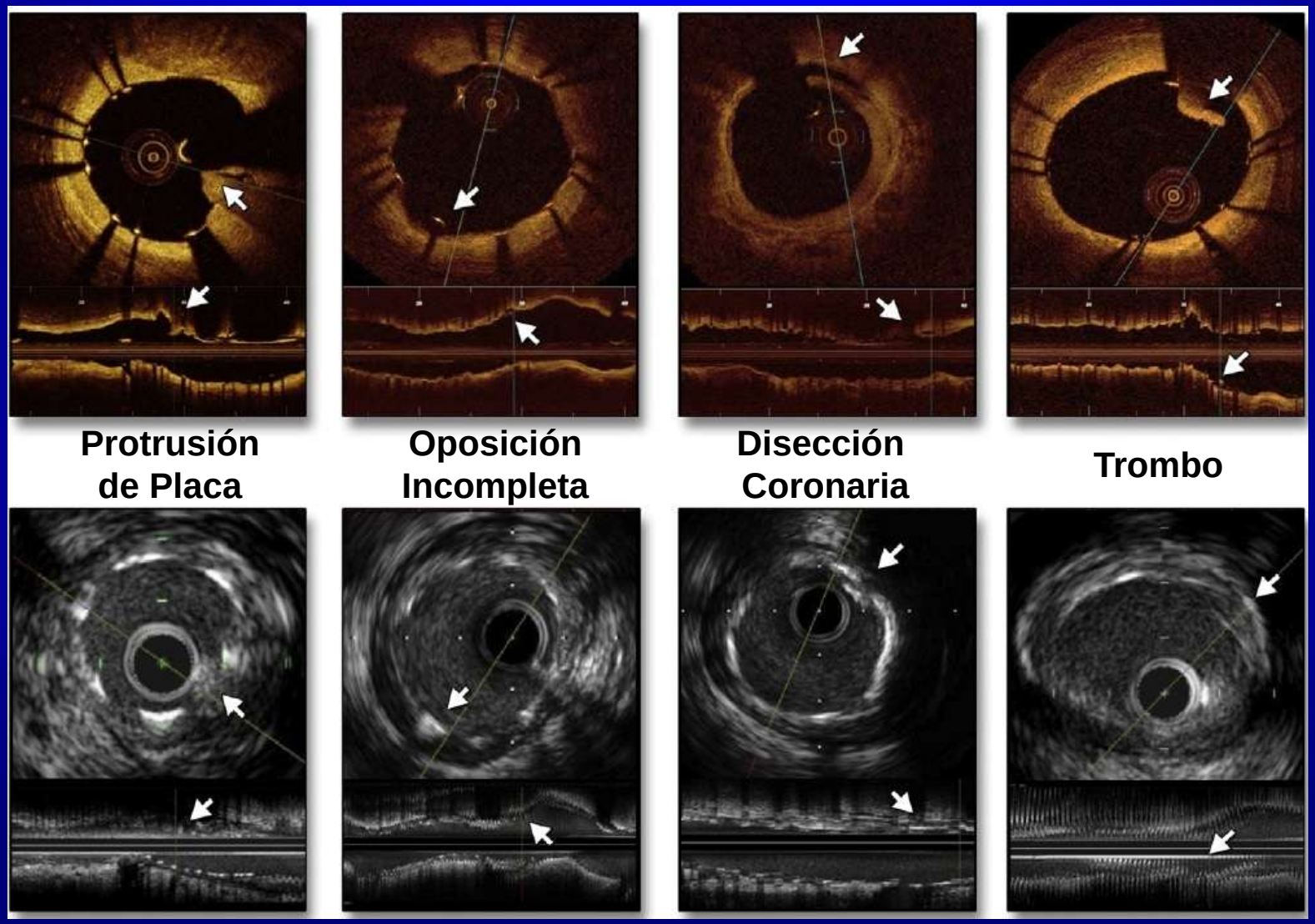

CLI – OPCI REGISTRY

OCT vs Angio para Guiar la ICP

n = 670 3 centros Italianos 2009 a 2011

	Angiographic group (n=335)	OCT group (n=335)	*p*-value
Age, years	67.0±11.5	64.8±11.5	0.016
Female gender	82 (24.5%)	73 (21.8%)	0.409
Hypertension	244 (73.8%)	253 (75.5%)	0.427
Diabetes mellitus	97 (29.0%)	81 (24.2%)	0.162
Smoking status			0.063
Never smoked	146 (43.6%)	167 (49.9%)	
Previously smoked	76 (22.7%)	53 (15.8%)	
Current smoking	113 (33.7%)	115 (34.3%)	
Family history of coronary artery disease	245 (73.1%)	230 (68.7%)	0.202
Dyslipidaemia	176 (53.3%)	214 (64.5%)	0.002
Prior myocardial infarction	72 (21.5%)	76 (22.7%)	0.709
Prior percutaneous coronary intervention	78 (23.5%)	115 (34.3%)	0.002
Prior coronary artery bypass grafting	29 (8.7%)	22 (6.6%)	0.308
Admission diagnosis			0.005
ST-elevation myocardial infarction	123 (36.7%)	86 (25.7%)	
Non-ST-elevation acute coronary syndrome	85 (25.4%)	112 (33.4%)	
Stable coronary artery disease	127 (37.9%)	137 (40.9%)	
Left ventricular ejection fraction, %	52.8±10.4	53.8±10.2	0.303

	Angiographic guidance group (n=335)	Angiographic plus OCT guidance group (n=335)	*p*-value
Number of diseased vessels			0.007
1	159 (47.9%)	122 (36.8%)	
2	108 (32.8%)	144 (43.4%)	
3	68 (19.3%)	69 (19.6%)	
Left main disease	8 (2.4%)	22 (6.6%)	0.009
American College of Cardiology/American Heart Association type B2/C lesion	287 (86.7%)	244 (72.8%)	<0.001
PCI on left anterior descending	179 (53.4%)	204 (60.9%)	0.050
Multivessel PCI	52 (15.5%)	78 (23.3%)	0.011
Stent length per patient (mm)	26.0±15.6	29.0±16.6	0.024
Drug-eluting stent usage	146 (43.6%)	212 (63.3%)	<0.001
Stent overlap	25 (7.5%)	49 (14.6%)	0.003
Maximum balloon diameter (mm)	3.0±0.5	3.1±0.4	0.037
Maximum dilation pressure (ATM)	16.7±2.5	16.7±2.8	0.823
Contrast (mL)	220±56	240±74	0.784

Prati F. Eurointervention 2012;8:823-829

CLI – OPCI REGISTRY

OCT vs Angio para Guiar la ICP

	Angiographic plus OCT guidance group (n=335)
Number of vessels assessed with OCT	
1	266 (79.4%)
2	65 (19.4%)
3	4 (1.2%)
OCT on left anterior descending	170 (50.7%)
OCT pullbacks	3.8±1.7
OCT findings	
Edge dissection	47 (14.2%)
Lumen narrowing	9 (2.8%)
Stent malapposition	99 (29.7%)
Stent underexpansion	38 (11.4%)
Thrombus	73 (22.0%)
Further intervention after OCT	116 (34.7%)
Stenting	42 (12.6%)
Balloon dilatation	74 (22.1%)

Prati F. Eurointervention 2012;8:823-829

CLI – OPCI REGISTRY

OCT vs IVUS para Guiar la ICP

	Angiographic guidance group (n=335)	Angiographic plus OCT guidance group (n=335)	*p*-value
In-hospital events			
Cardiac death	3 (0.9%)	2 (0.6%)	1.0
Non-fatal myocardial infarction	22 (6.5%)	13 (3.9%)	0.118
Events at 1-year follow-up			
Death	23 (6.9%)	11 (3.3%)	0.035
Cardiac death	15 (4.5%)	4 (1.2%)	0.010
Myocardial infarction	29 (8.7%)	18 (5.4%)	0.096
Target lesion repeat revascularisation	11 (3.3%)	11 (3.3%)	1.0
Definite stent thrombosis	2 (0.6%)	1 (0.3%)	1.0
Cardiac death or myocardial infarction	43 (13.0%)	22 (6.6%)	0.006
Cardiac death, myocardial infarction, or repeat revascularisation	50 (15.1%)	32 (9.6%)	0.034

Muerte Cardíaca/IAM

Modelo

Multivariado de Regresión

OR = 0.49 [0.25 – 0.96], p = 0.037

Análisis Score de Propensión

OR = 0.37 [0.10 – 0.96], p = 0.050

Prati F. Eurointervention 2012;8:823-829

Tomografía de Coherencia Óptica

Evaluación Alejada de la ICP

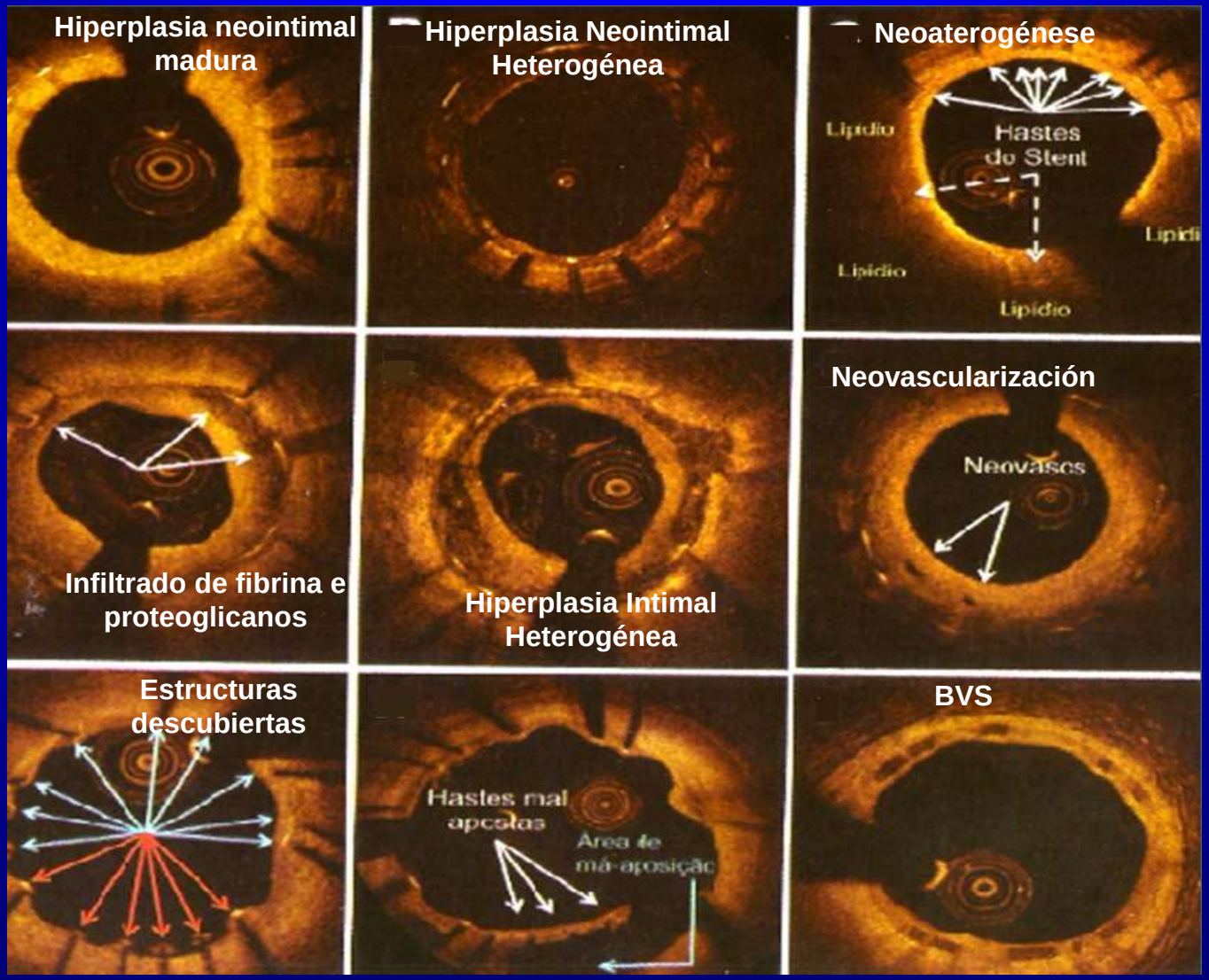

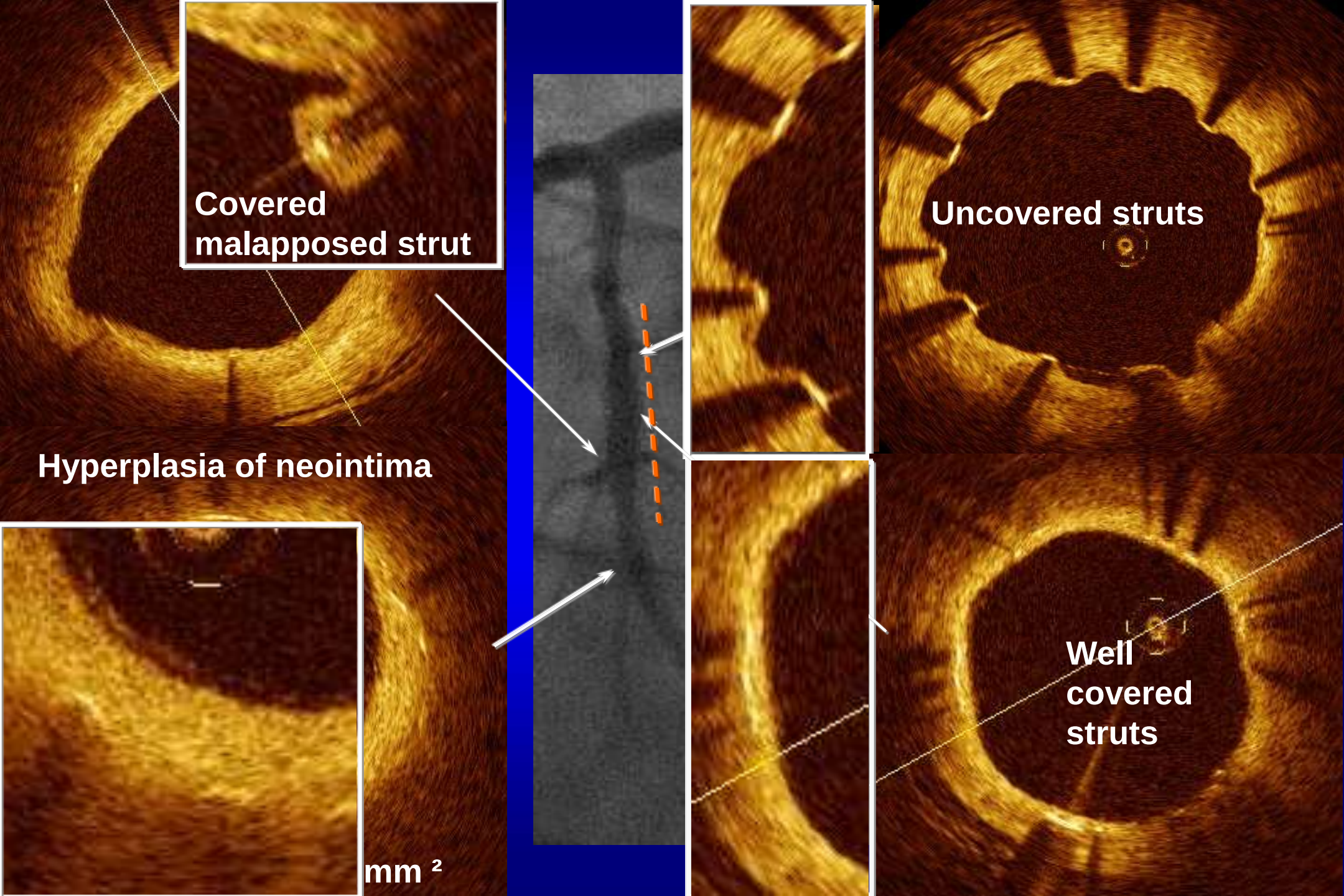
Covered
malapposed strut
Uncovered struts
Hyperplasia of neointima
Well
covered
struts
mm ²

Tomografía de Coherencia Óptica

Evaluación Alejada de la ICP

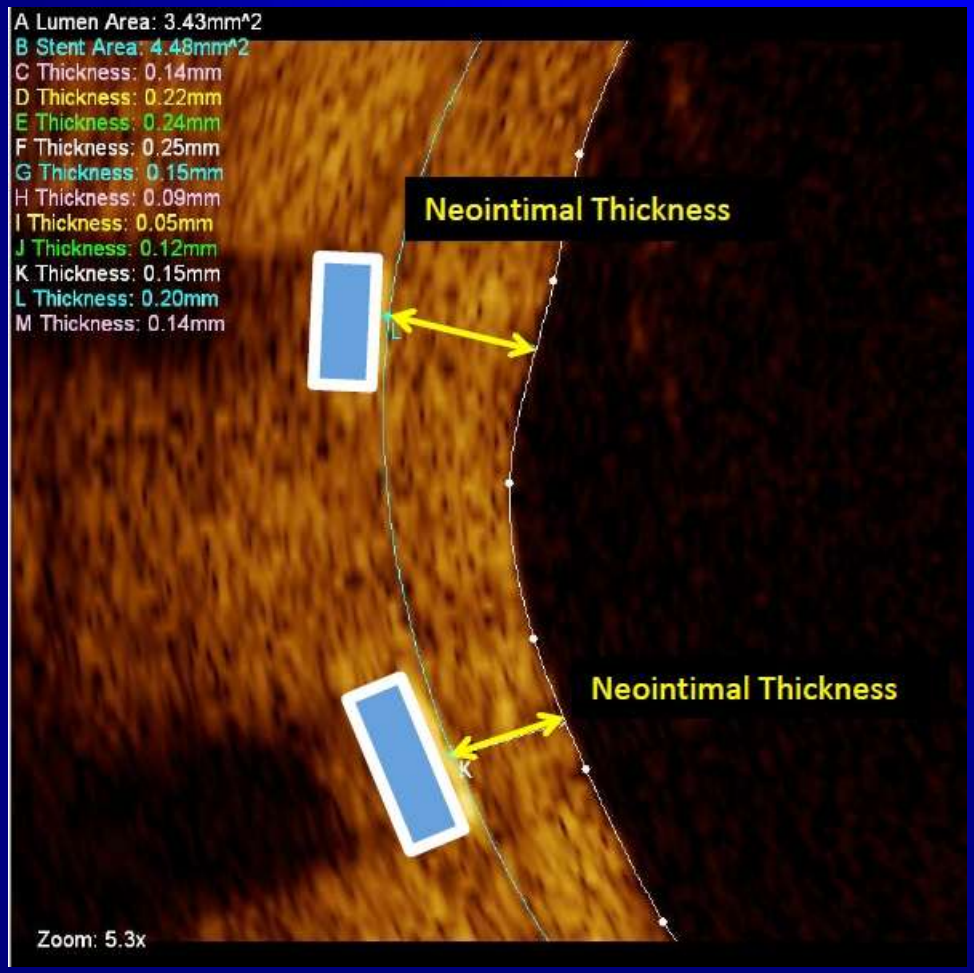

Stent "struts" cubierta

Espesura de la neoíntima > 20 µm

Stent "struts" descubierta

Espesura de la neoíntima > 20 µm

Percentage of Uncovered Struts

Difference 1.4%, 95% CI 0.0 to 3.7%, p=0.06

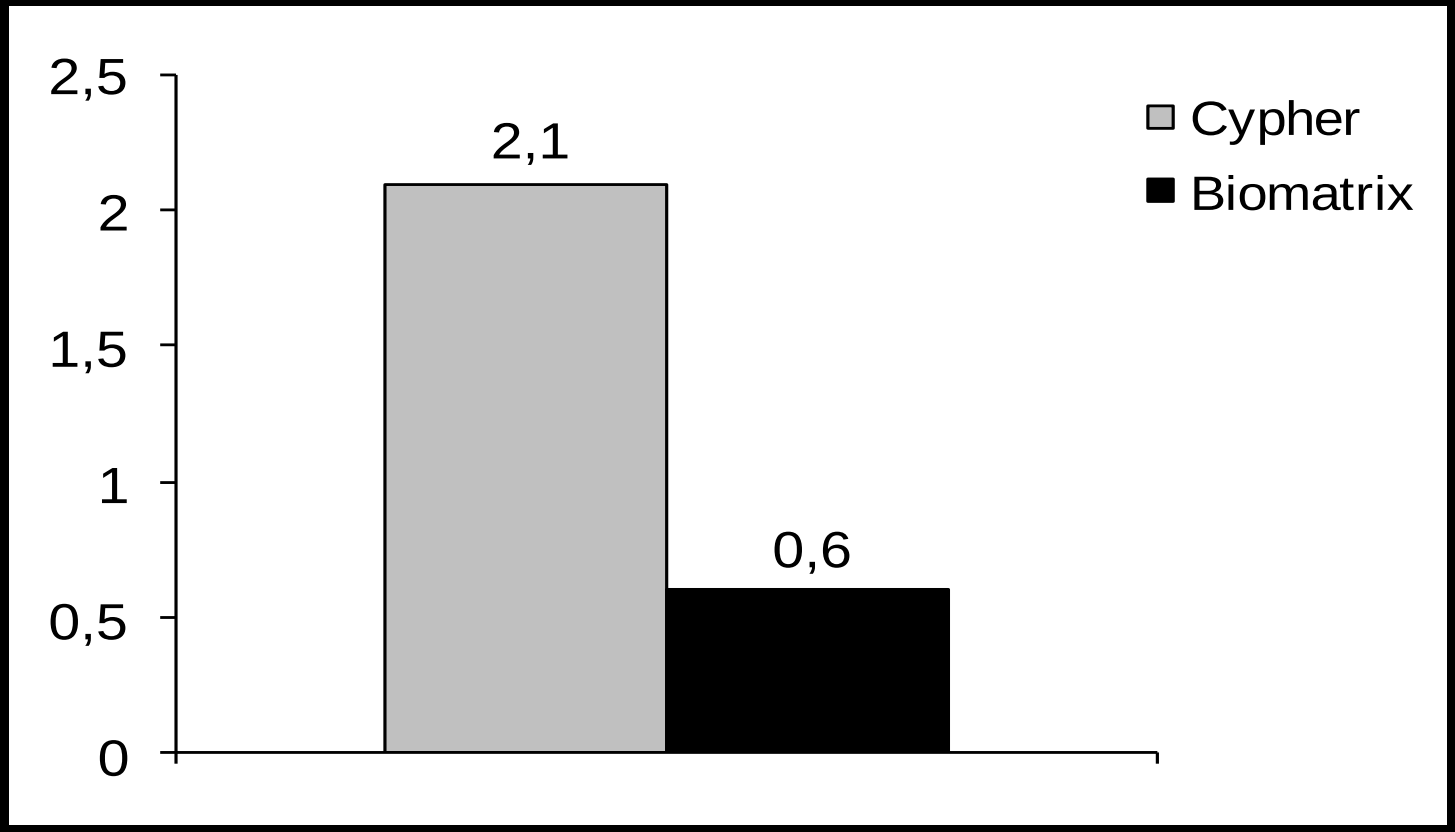

Barlis P. Eur Heart J 2010;31:165-176

Distribution of uncovered struts within lesions

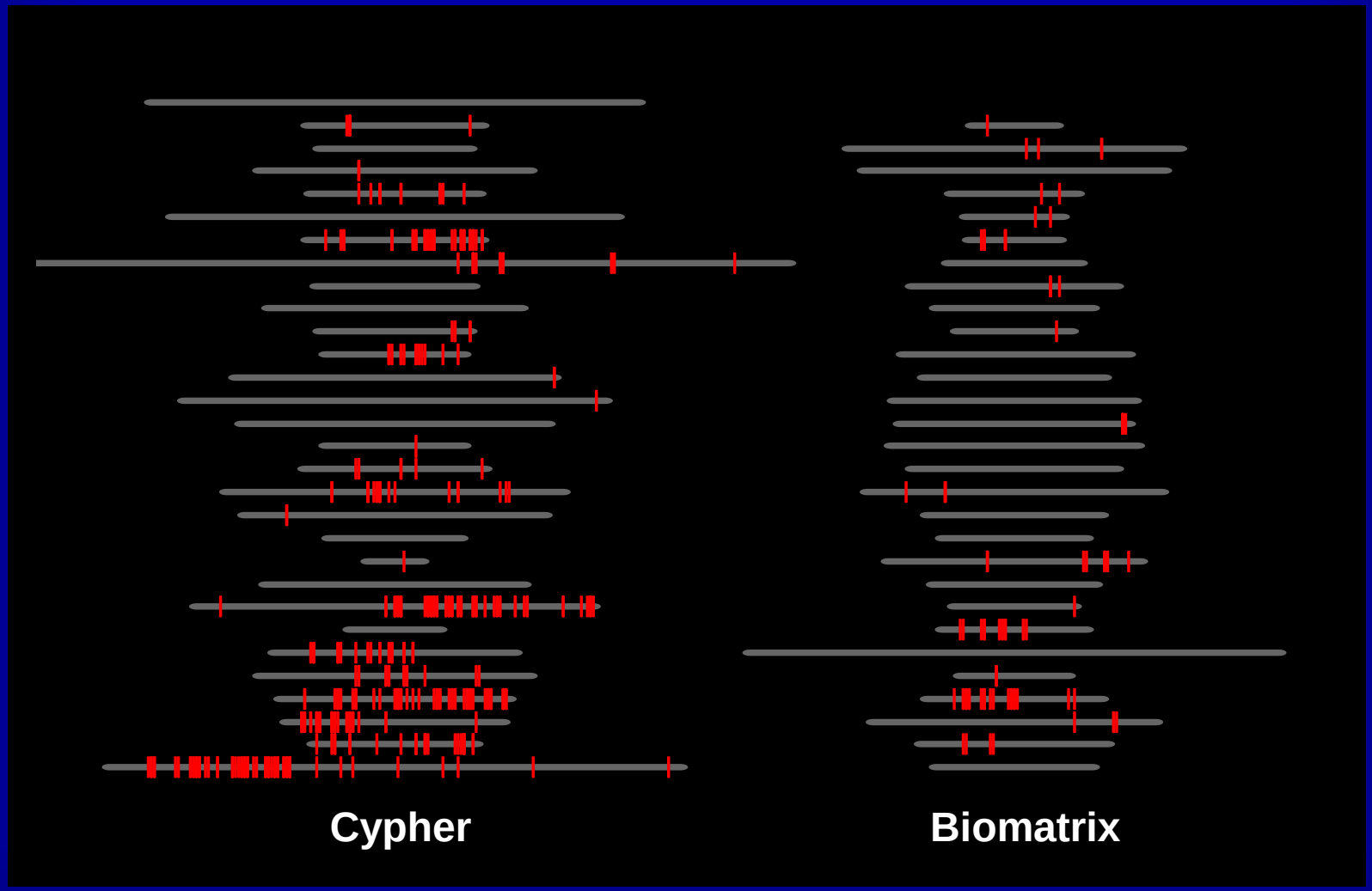

Barlis P. Eur Heart J 2010;31:165-176

LEADERS TRIAL

OCT Imagens de Cobertura das Hastes

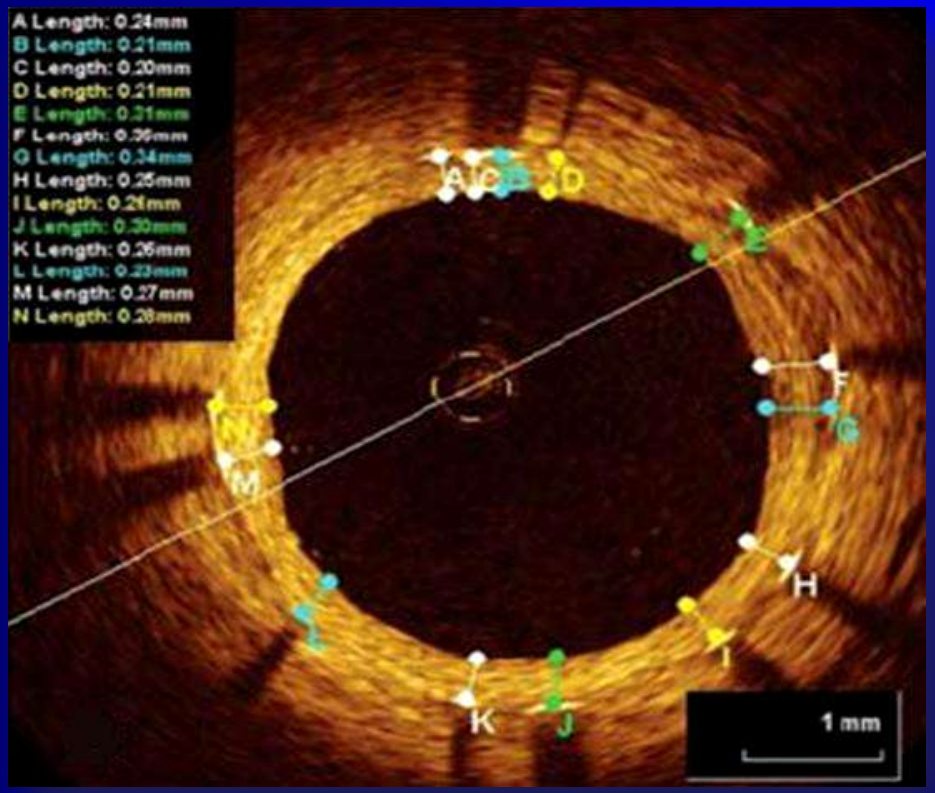

BES - 9 m

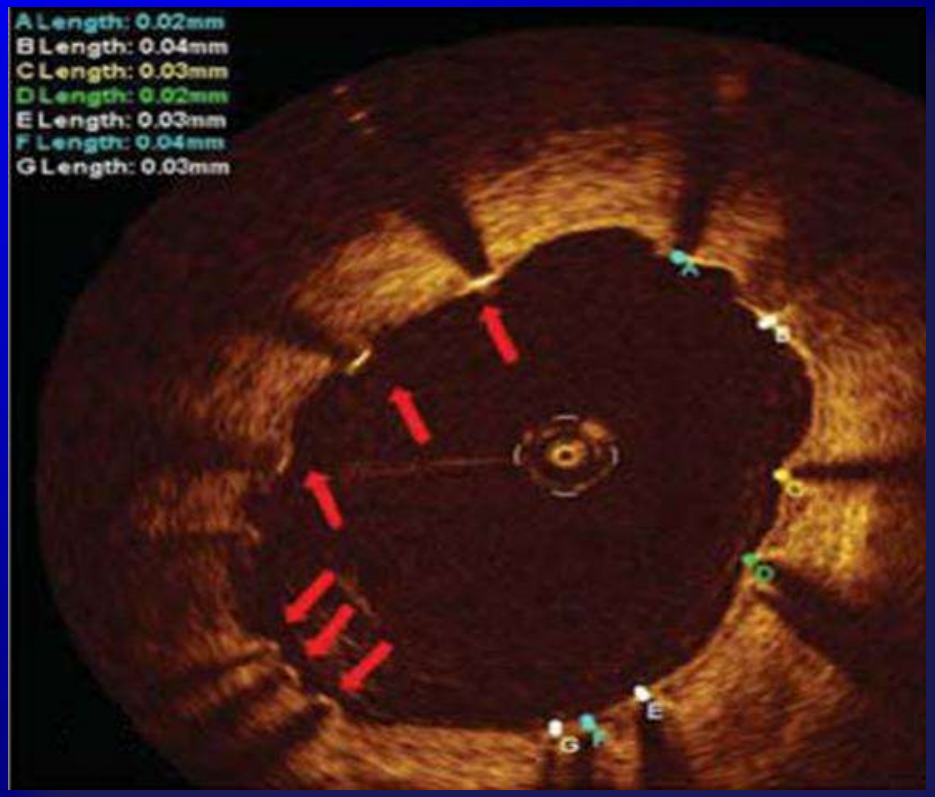

SES – 9 m

Barlis P. Eur Heart J 2010; 31:165–176

Tomografía de Coherencia Óptica

BVS – 10 años

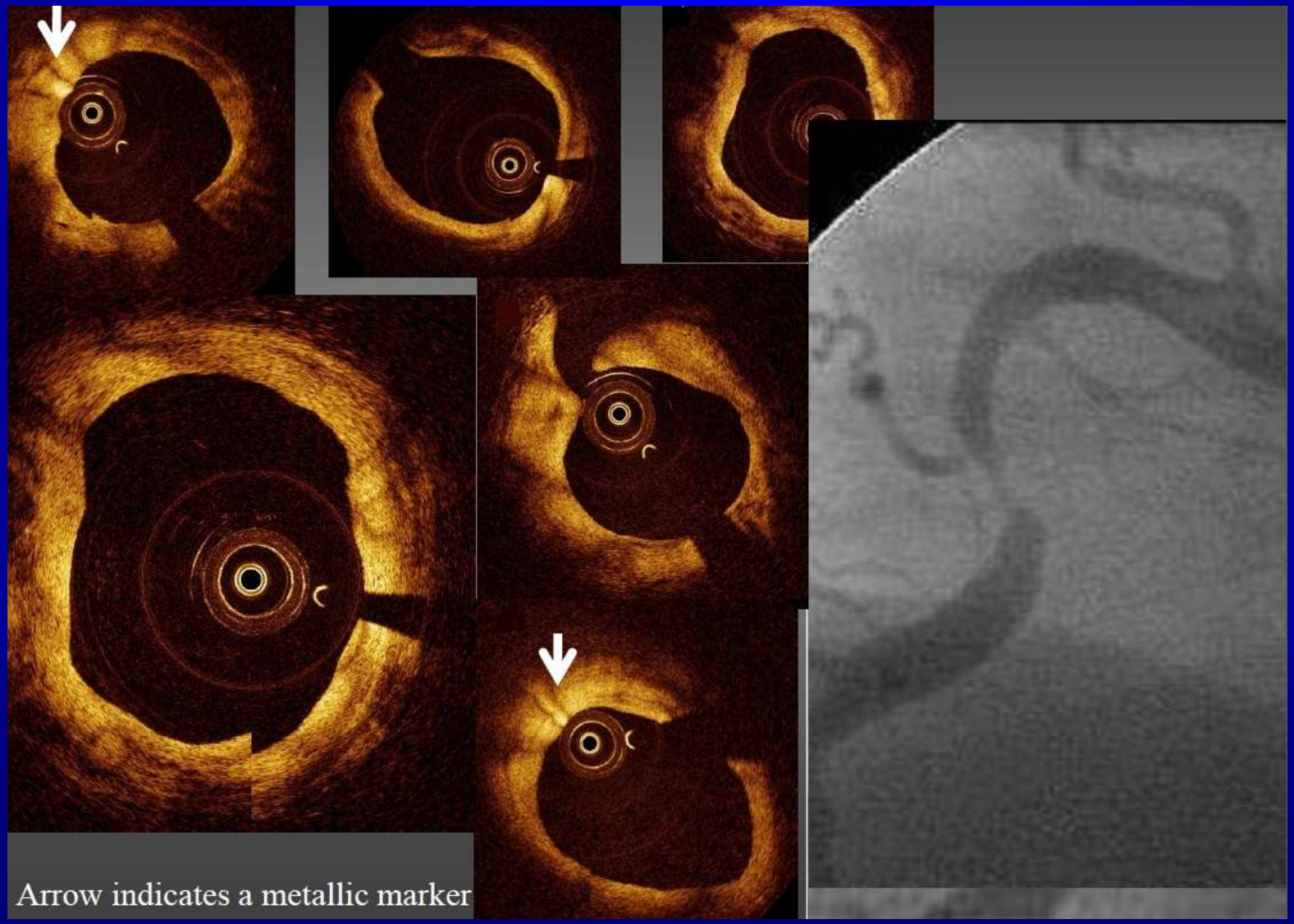

IVUS vs OCT

Comparación

	OCT	IVUS
Resolution	+++	++
Penetration	++	+++
Calcification	+++	+++
Thrombus	+++	++
Plaque characterisation	+++	++
Stent expansion & malapposition	+++	++
Stent coverage	++	+
Left Main:		
Bifurcation	++	++
Ostium	+	++

Tomografía de Coherencia Óptica

Conclusiones

- La OCT puede demostrar la superficie de la placa aterosclerótica e la presencia de trombo más claramente que el IVUS, y puede explicar los síntomas actuales e predecir eventos futuros.
- La OCT permite una evaluación mas precisa del implante de stents. Sin embargo, su impacto en la reducción alejada de eventos clínicos, necesita estudios posteriores.

Tomografía de Coherencia Óptica

Conclusiones

- **Aunque el OCT sea una poderosa herramienta para la evaluación del interior vascular, es relativamente pobre para evaluación de estructuras más profundas, lo que limita su papel para la evaluación de la regresión del volumen de ateroma, que requiere una estimación precisa del tamaño del buque y remodelación.**