INTERVENCIONISMO CORONARIO EN VENAS CENTRALES

Dr. Jorge Villegas

Cardiólogo Intervencionista

Profesor: F.U.C.S.

Jefe de Hemodinmia Hospital Universitario Clínica San Rafael.

INTRODUCCION

- La frecuencia del Síndrome de Vena Cava Superior esta en aumento.
- Secundarios a procesos malignos o benignos.
- Intervenciones nefrológicas (diálisis) electrofisiológicas (dispositivos de estimulación ventricular) y cuidado intensivo (catéteres venosos centrales).

Semin Intervent Radiol 2011;28:32–38.

ETIOLOGIA

Origen maligno:

- Carcinoma broncogénico de pulmón: de células pequeñas, epidermoide, adenocarcinoma, y de células grandes
- Linfomas no Hodking y raramente los Hodking
- •Carcinoma de mama, timoma y tumor
- de células germinales.
- Tumores metastásicos de mama, testículo,
- Colon.

Causas benignas:

- Bocio endotorácico
- Sarcoidosis
- Trombosis asociadas a catéteres intracavales o marcapasos
- Síndrome de Behcet
- Mediastinitis fibrosa (idiopática o asociada a Histoplasmosis)

Revista de Posgrado de la VIa Cátedra d 26 e Medicina - N° 147 – Julio 2005

PERCUTANEOUS STENTING OF SUPERIOR VENA CAVA SYNDROME: TREATMENT OUTCOME IN PATIENTS WITH BENIGN AND MALIGNANT ETIOLOGY

Table 1. Etiologies of Superior Vena Cava Syndrome

Etiology	n *(%)*
Benign SVCS (n = 16; 29%)	
Chronic indwelling hemodialysis catheter	11 (20)
Portacath/central venous catheter	3 (5)
Pacemaker/defibrillator	1 (2)
Mediastinal fibrosis	1 (2)
Malignant SVCS (n = 40; 71%)	
Small cell carcinoma of the lung	16 (29)
Squamous cell carcinoma of the lung	15 (27)
Large cell carcinoma of the lung	4 (7)
Mesothelioma	2 (4)
Thymoma	2 (4)
Embryonic carcinoma	1 (2)

SVCS = superior vena cava syndrome.

Vascular. Vol. 15, No. 5. pp. 314-321, 2(H)7

BENIGN SUPERIOR VENA CAVA SYNDROME: STENTING IS NOW THE FIRST LINE OF TREATMENT

Table I. Primary causes of benign superior vena cava syndrome in 70 patients

Causes	*Total (n=70), No. (%)*	*Surgical (n=42), No. (%)*	*Endovascular (n = 28), No. (%)*	*P**
Mediastinal fibrosis	31 (44)	22 (52)	9 (32)	.14
Sclerosing mediastinal fibrosis	16 (23)	13 (31)	3 (11)	.08
Histoplasmosis	12 (17)	6 (14)	6 (21)	.52
Mediastinal granulomatous disease	2 (3)	2 (5)	0 (0)	.51
Postradiation	1 (1)	1 (2)	0 (0)	>.99
Venous thrombosis	38 (54)	19 (45)	19 (68)	.09
Indwelling catheter/pacemaker wire	33 (47)	14 (33)	19 (68)	.007
Ventriculoatrial shunt	2 (3)	2 (5)	0 (0)	.51
Hypercoagulable state	1 (1)	1 (2)	0 (0)	>.99
Idiopathic	2 (3)	2 (5)	0 (0)	.51
Surgical excision	1 (1)	1 (2)	0 (0)	>.99

*Fisher's exact test, two-tail *P* comparing surgical and endovascular intervention.

J Vasc Surg 2008;47:372-80.)

BENIGN SUPERIOR VENA CAVA SYNDROME: STENTING IS NOW THE FIRST LINE OF TREATMENT

Table II. Classification* and underlying etiology of 70 patients based on venographic pattern of superior vena cava stenosis/occlusion

Type	*Definition*	*Total (n = 70), No. (%)*	*Surgical (n = 42), No. (%)*	*Endovascular (n = 28), No. (%)*	*P*†
I	≤90% stenosis of the SVC with patency and antegrade flow of the azygos–right atrial pathway	6 (9)	3 (7) (mediastinal fibrosis, 3)	3 (11) (mediastinal fibrosis, 1; venous thrombosis, 2)	.67
II	>90% stenosis or occlusion of the SVC with patency and antegrade flow in the azygos–right atrial pathway	16 (23)	4 (10) (mediastinal fibrosis, 3; idiopathic, 1)	12 (43) (mediastinal fibrosis, 3; venous thrombosis, 9)	.003
III	>90% stenosis or occlusion of the SVC with reversal of azygos blood flow	28 (40)	15 (36) (mediastinal fibrosis, 7; venous thrombosis, 8)	13 (46) (mediastinal fibrosis, 5; venous thrombosis, 8)	.46
IV	Occlusion of the SVC and one or more of the major caval tributaries including the azygos systems	20 (28)	20 (47) (mediastinal fibrosis, 9; venous thrombosis, 8; hypercoagulable state, 1; prior surgery, 1; idiopathic, 1)	0 (0)	< .0001

SVC, Superior vena cava.
*Stanford and Doty.[12]
†Fisher exact test, two-tail *P*.

J Vasc Surg 2008;47:372-80.)

ENDOVASCULAR MANAGEMENT OF CHRONIC UPPER EXTREMITY DEEP VEIN THROMBOSIS AND SUPERIOR VENA CAVA SYNDROME

Table 1 Risk Factors for Upper Extremity and Central Venous Thrombosis

Central venous catheter
Pacemaker
Hypercoagulable syndromes
Malignancy
Extrinsic compression
Tumor invasion (Pancoast)
Injection of sclerosing medications
Trauma
Radiation

Table 2 Imaging Features of Chronic Venous Thrombosis

Occluded, string-like vessel
Linear intraluminal webs
Mural irregularity and thickening
Stenoses
Hyperechoic intraluminal filling defects (ultrasound)
Dilated, well-developed collateral drainage

Semin Intervent Radiol 2011;28:32–38.

PERCUTANEOUS STENTING OF SUPERIOR VENA CAVA SYNDROME: TREATMENT OUTCOME IN PATIENTS WITH BENIGN AND MALIGNANT ETIOLOGY

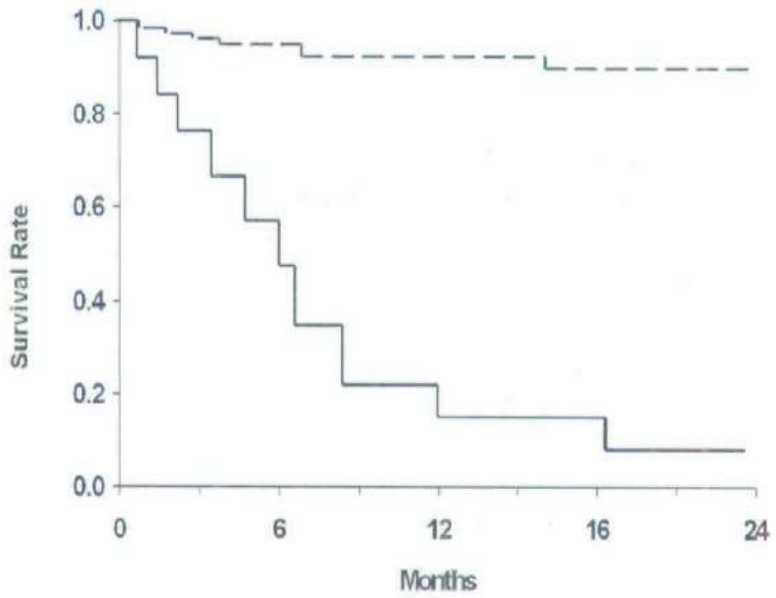

Figure 2. Kaplan-Meier survival curves of patients with malignant (*solid line*) and benign (*dotted line*) superior vena cava syndrome.

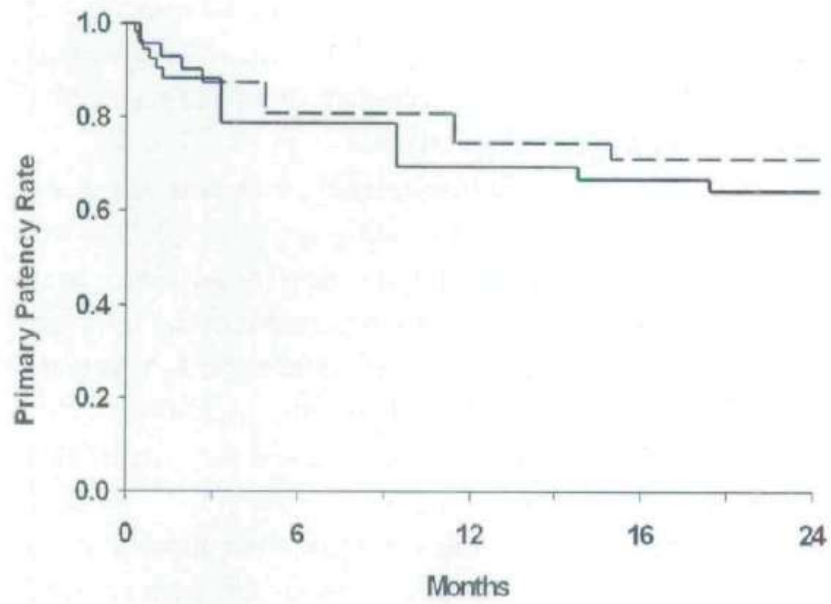

Figure 3. Primary stent patency rates of patients with malignant (*solid line*) and benign (*dotted line*) superior vena cava syndrome.

Vascular. Vol. 15, No. 5. pp. 314-321, 2(H)7

VENA CAVAL THROMBOSES

Table 3 Patients with unexplained dyspnea in whom final diagnosis was VC thrombosis without PE[a]

Case	Age (y)	Sex	Identifiable risk factors	Symptom	Finding	Diagnostic methods	Diagnosis
1 HK	35	F	No	Dyspnea, perioral cyanosis with exercise	Tachypnea, perioral cyanosis	Vena cavagraphy	Primary IVC thrombosis
2 NY	32	F	Smoking	Exertional dyspnea	Tachypnea, bilateral rhonchi	Doppler US, echocardiography	Primary IVC thrombosis
3 AE	53	F	No	Exertional dyspnea	Tachypnea	Vena cavagraphy, Doppler US	Primary IVC thrombosis, PH
4 MA	22	F	Surgery for ovary cyst, in 2 wk, BD	Dyspnea	Tachypnea, abdominal swelling with collateral veins, bilateral pretibial edema	MR venography, Doppler US	BD
5 KB	69	M	Smoking	Dyspnea	Tachypnea	Indirect spiral CT venography	Sarcoidosis (stage I), PH
6 NS	55	M	Lung cancer, COPD	Dyspnea	Tachypnea	Indirect spiral CT venography	Lung cancer, COPD
7 HÇ[b]	27	M	BD, smoking	Dyspnea	Tachypnea, oral aphthous lesions, systolic murmur over mitral area	Spiral CT venography	BD
8 SB	19	M	BD	Dyspnea, fever	Tachypnea, bilateral pretibial edema, temperature 38°C	MR venography	BD, external iliac vein thrombosis
9 ND	66	M	Lung cancer, smoking	Left calf pain	Finger clubbing, decreased breathing sounds on both lungs	Indirect spiral CT venography, Doppler US	Lung cancer, femoral and popliteal vein thrombosis

COPD indicates chronic obstructive pulmonary disease.

[a] Normal pulmonary spiral CT angiograms and nondiagnostic pulmonary scans (near-normal V/Q scanning or low-probability V/Q scanning according to the Prospective Investigation of Pulmonary Embolism Diagnosis criteria).

[b] Patient with superior VC thrombosis.

Journal of Critical Care (2010) 25, 336–342

BENIGN SUPERIOR VENA CAVA SYNDROME: STENTING IS NOW THE FIRST LINE OF TREATMENT

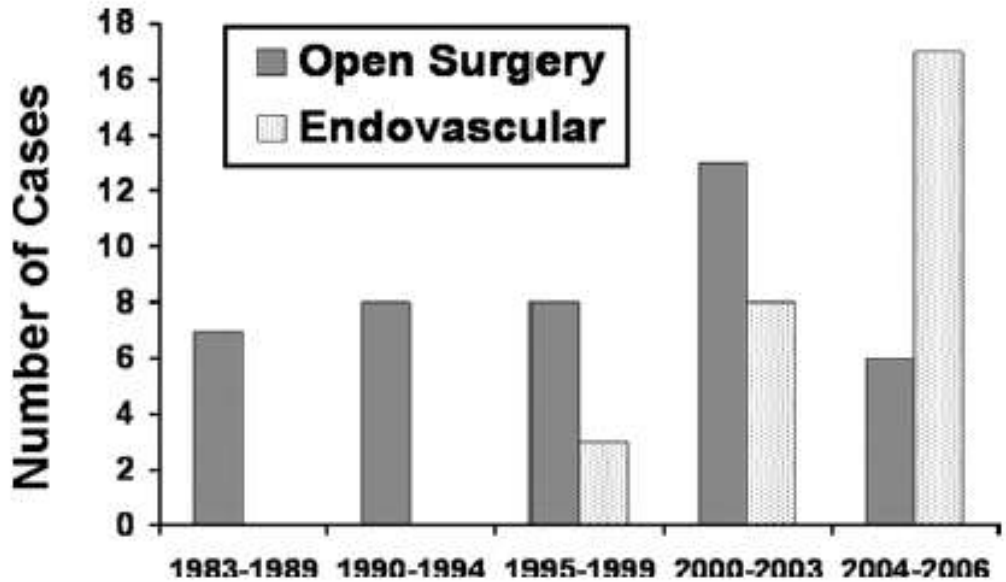

Fig 1. Treatment modalities in 70 consecutive patients with benign superior vena cava syndrome over 23 years.

J Vasc Surg 2008;47:372-80

BENIGN SUPERIOR VENA CAVA SYNDROME: STENTING IS NOW THE FIRST LINE OF TREATMENT

Table III. Procedural details of 42 patients with open surgical reconstruction and 28 patients with endovascular repair

Type of repair	*Patients, No.*	*(%)*
Open surgical reconstruction		
Autologous vein	28	67
Spiral saphenous vein	22	52
Straight grafts	(19)	(43)
Bifurcated grafts	(2)	(5)
Straight graft + reimplantation opposite innominate vein	(1)	(2)
Femoral vein	6	14
Iliocaval allograft	1	2
Expanded polytetrafluoroethylene	13	31
Total	42	100
Endovascular repair		
Catheter-directed thrombolysis with PTA	2	7
Catheter-directed thrombolysis with stenting	3	11
PTA	4	14
Stenting	19	68
Total	28	100
Location of PTA or stenting		
SVC	19	68
SVC and innominate vein	5	18
Innominate vein	3	11
SVC and internal jugular vein	1	3
Type of stent		
Wallstent (Boston Scientific, Natick, Mass)	6	21
S.M.A.R.T (Cordis, Piscataway, NJ)	6	21
Palmaz (Cordis, Piscataway, NJ)	5	18
Viabahn (W.L. Gore, Newark, Del)	3	11
Lumminexx (C.R. Bard, Covington, Ga)	1	3
Protégé (eV3 Inc, Plymouth, Minn)	1	3

PTA, Percutaneous transluminal angioplasty; *SVC*, superior vena cava.

J Vasc Surg 2008;47:372-80.)

BENIGN SUPERIOR VENA CAVA SYNDROME: STENTING IS NOW THE FIRST LINE OF TREATMENT

Table IV. Thirty-day complication rate after open surgical reconstruction or endovascular repair for superior vena cava syndrome

Complication	*Patients, No.*
Surgical	8
Mediastinal hematoma requiring evacuation	1
Deep venous thrombosis	2
Pulmonary embolus	1
Prolonged mechanical ventilation	2
Pericardial effusion requiring drainage	1
Tracheostomy, prolonged mechanical ventilation, pleural effusion requiring drainage, pneumonia	1
Endovascular	1
Arm hematoma	1

J Vasc Surg 2008;47:372-80.)

BENIGN SUPERIOR VENA CAVA SYNDROME: STENTING IS NOW THE FIRST LINE OF TREATMENT

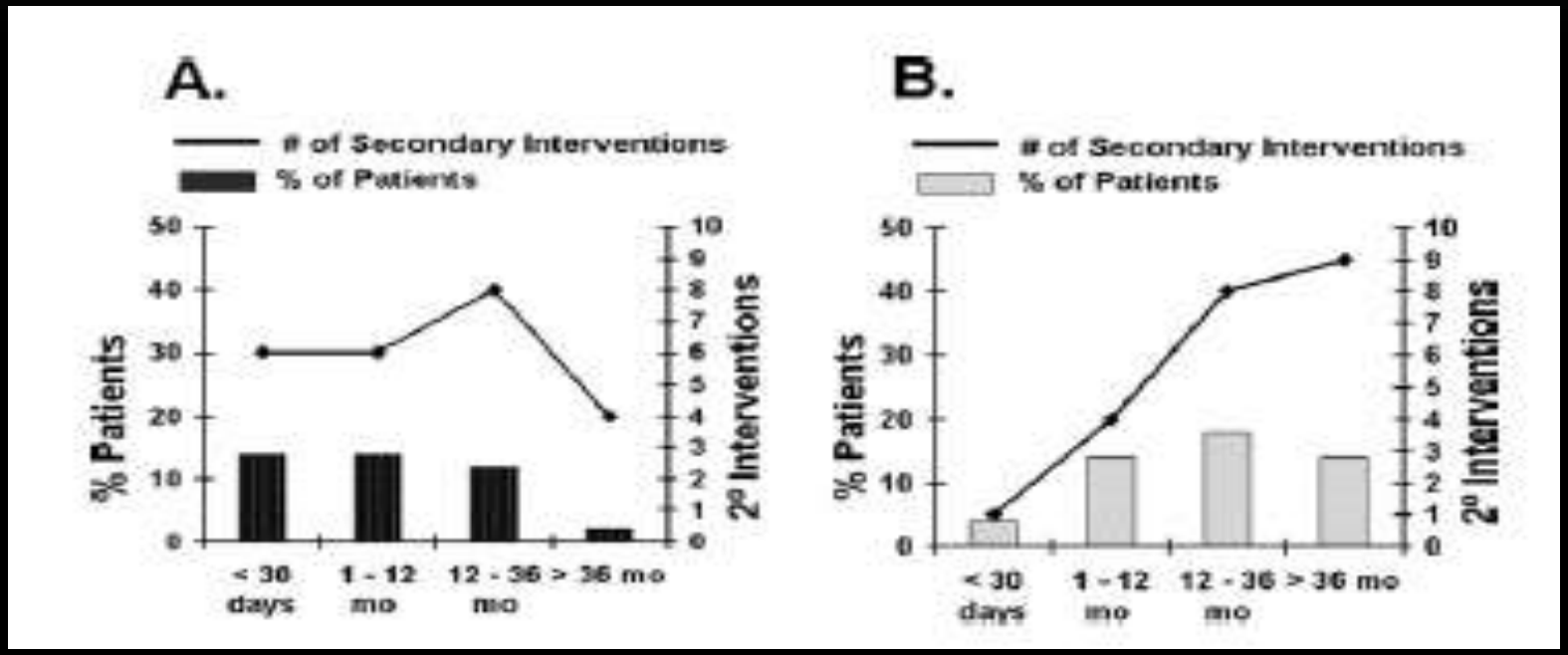

Fig 2. Secondary interventions required to maintain patency in **(A)** the open surgical group (n 42) and **(B)** the endovascular group (n 28). The bars represent the percentage of patients in each group, and the line graphs represent the total number of interventions. Secondary interventions in the surgical group include new superior vena cava bypass grafts in two patients after occlusion of the primary grafts.

J Vasc Surg 2008;47:372-80.)

BENIGN SUPERIOR VENA CAVA SYNDROME: STENTING IS NOW THE FIRST LINE OF TREATMENT

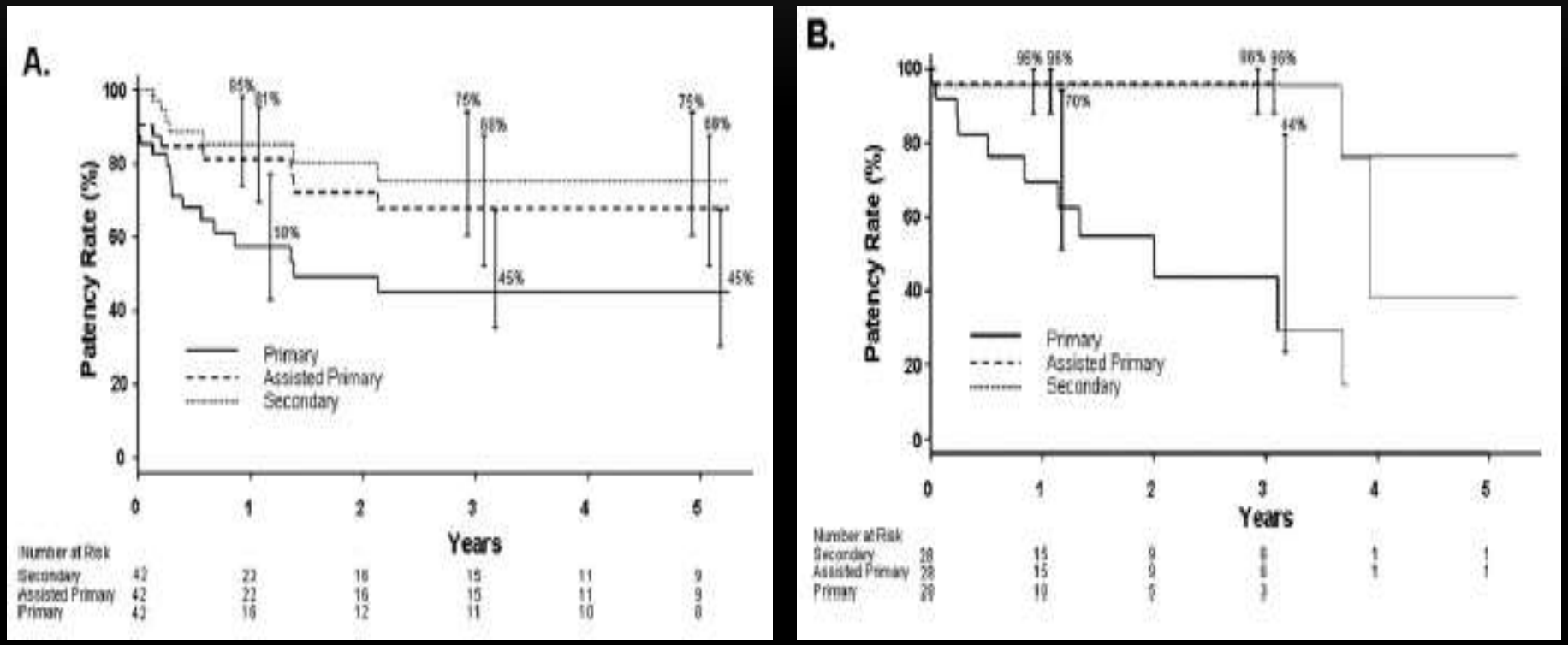

Fig 3. A, Cumulative primary, assisted primary, and secondary patency rates at 1, 3, and 5 years of open surgical reconstruction (n 42). Range bars represent the standard error of the mean 10%. **B,** Cumulative primary, assisted primary, and secondary patency rates at 1 and 3 years of endovascular repair (n 28). Range bars represent the standard error of the mean 10%.

J Vasc Surg 2008;47:372-80.)

BENIGN SUPERIOR VENA CAVA SYNDROME: STENTING IS NOW THE FIRST LINE OF TREATMENT

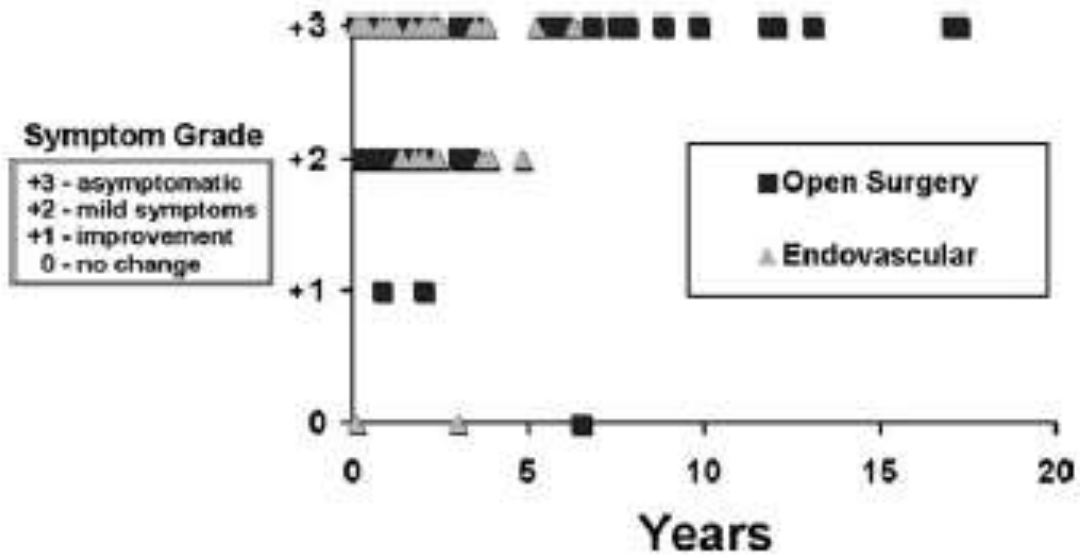

Fig 4. Grading of symptom relief at last clinical follow-up in patients undergoing open surgical reconstruction (n = 42) or endovascular repair (n = 28).

J Vasc Surg 2008;47:372-80.)

BENIGN SUPERIOR VENA CAVA SYNDROME: STENTING IS NOW THE FIRST LINE OF TREATMENT

Table V. Univariate analysis* of clinical and procedural risk factors on patency in patients undergoing open surgical reconstruction or endovascular repair

	Surgical patency					*Endovascular patency*				
		Primary		*Secondary*			*Primary*		*Secondary*	
Risk factor	*Patients, No*	*%*	*P*	*%*	*P*	*Patients, No.*	*%*	*P*	*%*	*P*
Sex										
Female	24	51	.70	70	.30	16	57	.78	92	0.69
Male	18	40		83		12	27		100	
Age										
<40	23	28	.06	74	.78	10	56[§]	.03	100	0.17
>40	19	68		78		18	78		94	
SVC obstruction type										
Type I/II	7	57	.15	100	.16	15	45	.88	92	0.27
Type III/IV	35	40		69		13	32[‖]		100	
Etiology										
Mediastinal fibrosis	22	43	.83	74	.84	9	29[‖]	.90	100	0.17
Central line/wire	16	50		81		19	63		94	
Prior endovascular intervention										
Yes	10	54[§]	.75	86	.94	...	...	...	...	...
No	27	49		75		...	...		...	
Type of bypass graft										
PTFE	13	23	.58	42	.35	...	...	...	...	...
Vein[†]	28	49		81		...	...		...	
Endovascular intervention[‡]										
PTA	...	...	...	...	...	4	42	0.31	88	0.02
Stenting	...	...		...		19	40		100	

SVC, superior vena cava; *PTFE*, polytetrafluoroethylene; *PTA*, percutaneous transluminal angioplasty.
*Log-rank test.
[†]Includes 28 vein grafts and 1 iliocaval allograft.
[‡]Includes 23 primary endovascular interventions and excludes 5 patients who underwent thrombolysis.
[§]Kaplan-Meier estimates of patency at only 1 year.
[‖]Kaplan-Meier estimates of patency at only 2 years.

J Vasc Surg 2008;47:372-80.)

PERCUTANEOUS TREATMENT OF SUPERIOR VENA CAVA SYNDROME CAUSED BY CHRONIC THROMBOSIS

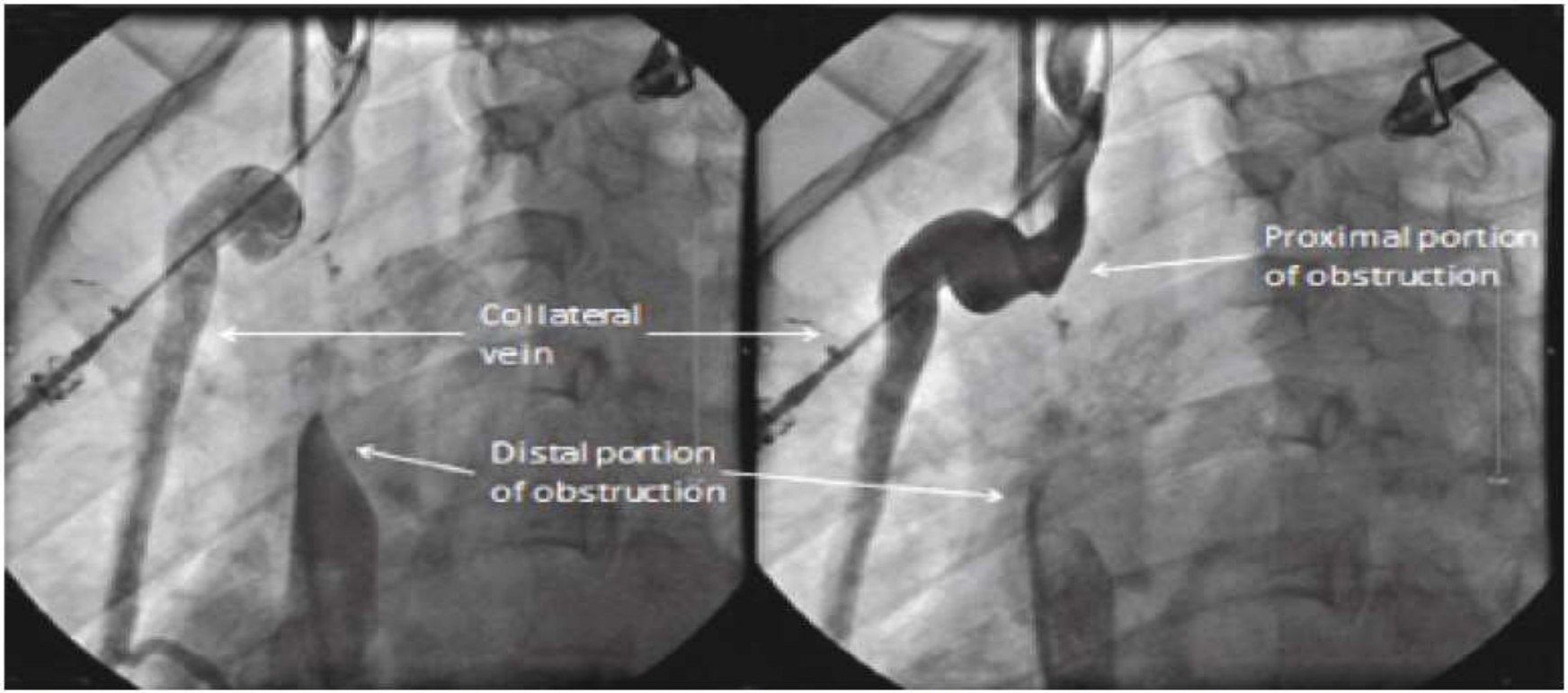

Figure 1. Nonsubtracted venography showing that chronic occlusion was of the superior vena cava. Venogram was performed with femoral and jugular vein approach.

Arch Turk Soc Cardiol 2014;42(1):76-79

ENDOVASCULAR RECANALIZATION OF SUPERIOR VENA CAVA, BRACHIOCEPHALIC, AND SUBCLAVIAN VENOUS OCCLUSIONS CAUSED BY NONMALIGNANT LESIONS

Table 1. Patient characteristics and outcomes following endovascular treatment

Patients	Age (years)	Etiology	Site	Procedural outcomes	Stent	Total follow-up time (months)	Primary patency (months)	Primary assisted patency (months)	Secondary patency (months)
1	63	Post-radio-therapy	R SV, BCV, SVC	Failure	No	7	0		
2	85	Hemo-dialysis	R SV, BCV	Success	Lumminexx 1:12/100	24	3		7
3	32	Hyper-coagulation	Bi BCV, SVC	Success	Lumminexx 2:14/60, 14/80	19	2		
4	68	Hemo-dialysis	L BVC, SVC	Success	Lumminexx 1:14/80	17	4	17	
5	57	Mediastinal fibrosis	SVC	Success	Lumminexx 1:14/60	16	16		
6	66	Hemo-dialysis	R BCV, SVC	Success	Lumminexx 1:14/80	14	14		
7	62	Hemo-dialysis	L SV, BCV	Success	Smart 1: 10/80	11	11		
8	78	Hemo-dialysis	L BVC	Success	Smart 1:14/40	11	11		
9	81	Hemo-dialysis	L BVC, SVC	Failure	No	9	0		
10	61	Hemo-dialysis	R SV, BVC	Success	Fluency 1: 10/80 Smart 1: 12/40	6	6		

R: right; L: left; SV: subclavian vein; BCV: brachiocephalic vein; SVC: superior vena cava; Stent: number and size (diameter/length in millimeters).

Chin Med J 2012;125(10):1767-1771

FOLLOW-UP RESULTS OF 71 PATIENTS UNDERGOING METALLIC STENT PLACEMENT FOR THE TREATMENT OF A MALIGNANT OBSTRUCTION OF THE SUPERIOR VENA CAVA



Fig. 1 a Spiral Z stent. b Modified Z stent. In vitro comparison of the spiral Z stent and the modified Gianturco Z stent. The spiral Z stent has more uniform expansile force throughout its effective length; is more compressible, thus allowing for the use of a smaller introductory catheter; and is more stable than the modified Z stent. Flexibility of both stent types is comparable

Cardiovasc Intervent Radiol (2007) 30:959–967

ENDOVASCULAR STENTING AS A FIRST CHOICE FOR THE PALLIATION OF SUPERIOR VENA CAVA SYNDROME

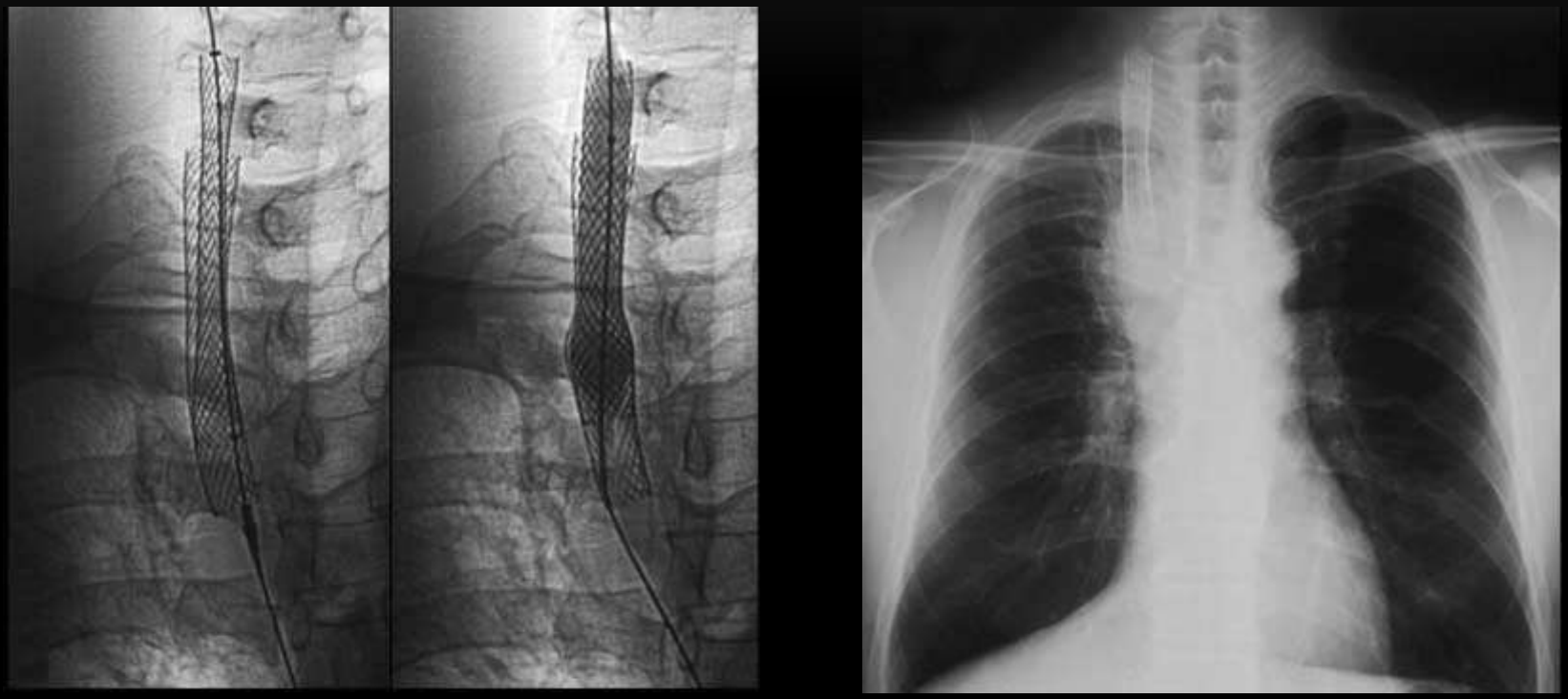

Fig. 1. (A) Venous Doppler of superior vena cava demonstrating near total obstruction (arrowheads) in the first stent (arrows), 2 weeks after the first procedure. (B) Fluoroscopic images show sequence of procedure for placement and balloon dilatation of 6 cm×14 mm the second stent through the first stent, across the lesion. (C) Radiography showing two stents placement, after the second procedure. Arrow and arrowhead indicate the upper ends of the second and first stent respectively.

J Korean Med Sci 2004; 19: 519-22

ENDOVASCULAR TREATMENT OF SVC SYNDROME FROM NEOPLASTIC ORIGIN: OF REVIEW OF 34 CASES

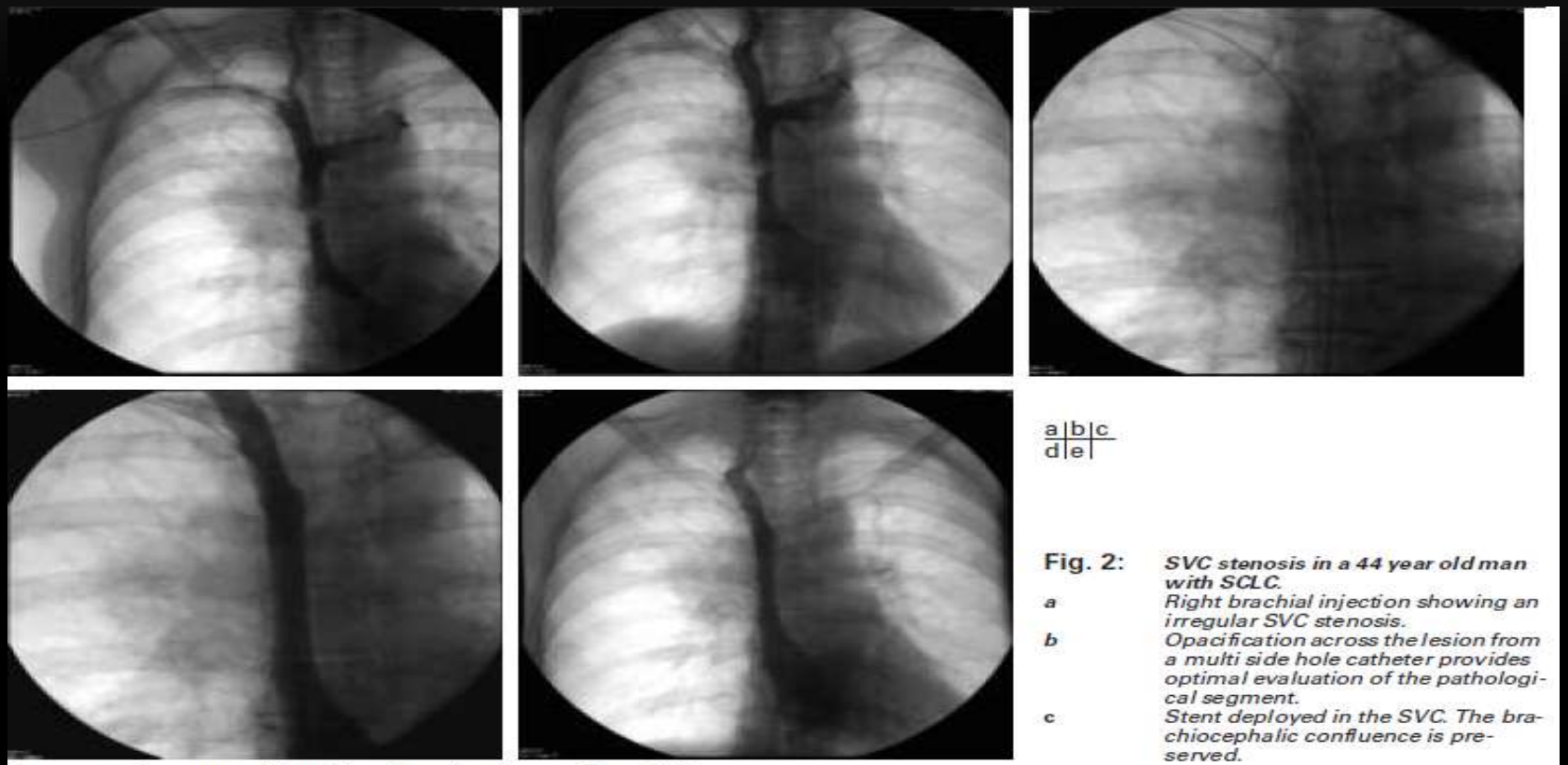

a|b|c
d|e

Fig. 2: ***SVC stenosis in a 44 year old man with SCLC.***

a *Right brachial injection showing an irregular SVC stenosis.*

b *Opacification across the lesion from a multi side hole catheter provides optimal evaluation of the pathological segment.*

c *Stent deployed in the SVC. The brachiocephalic confluence is preserved.*

d *Cavogram with guide catheter in place confirms SVC patency.*

e *Final venogram, after guide catheter withdrawal.*

J Radiol 2008;89:881-9

PERCUTANEOUS TREATMENT OF SUPERIOR VENA CAVA SYNDROME CAUSED BY CHRONIC THROMBOSIS

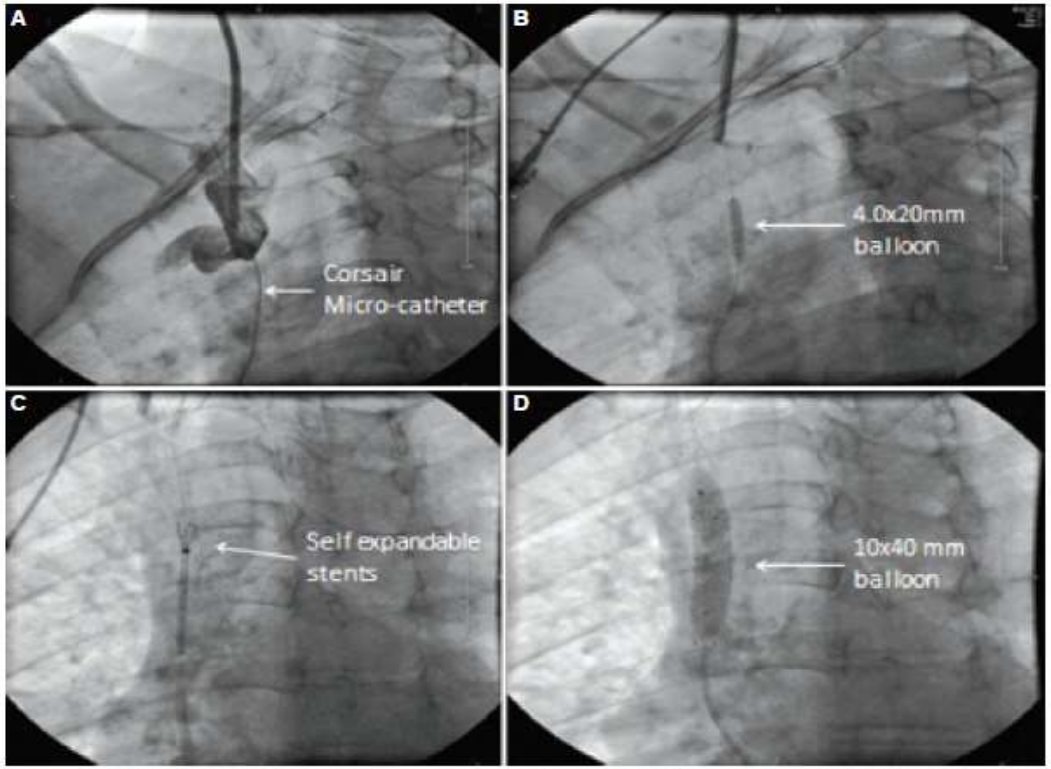

Figure 2. (**A**) Access was gained via a right femoral vein approach, and the lesion was crossed with guidewire and Corsair microcatheter; (**B**) the lesion was predilated prior to stent placement. (**C**) Two self-expanding stents were placed across the lesion, (**D**) and post-stenting balloon dilation was performed.

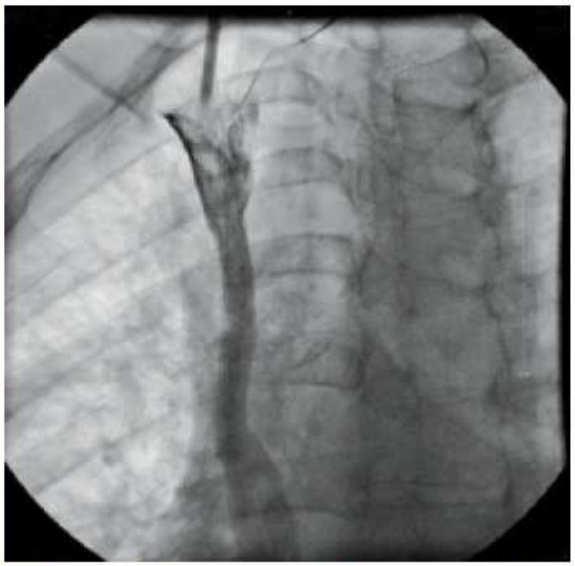

Figure 3. Final venogram showed restoration of wide patency to the SVC after balloon angioplasty and subsequent placement of the stent.

Arch Turk Soc Cardiol 2014;42(1):76-79

PERCUTANEOUS TREATMENT OF SUPERIOR VENA CAVA SYNDROME AFTER PACEMAKERS ELECTRODES IMPLANTATION AND/OR SURGICAL CORRECTION OF CONGENITAL HEART DISEASE

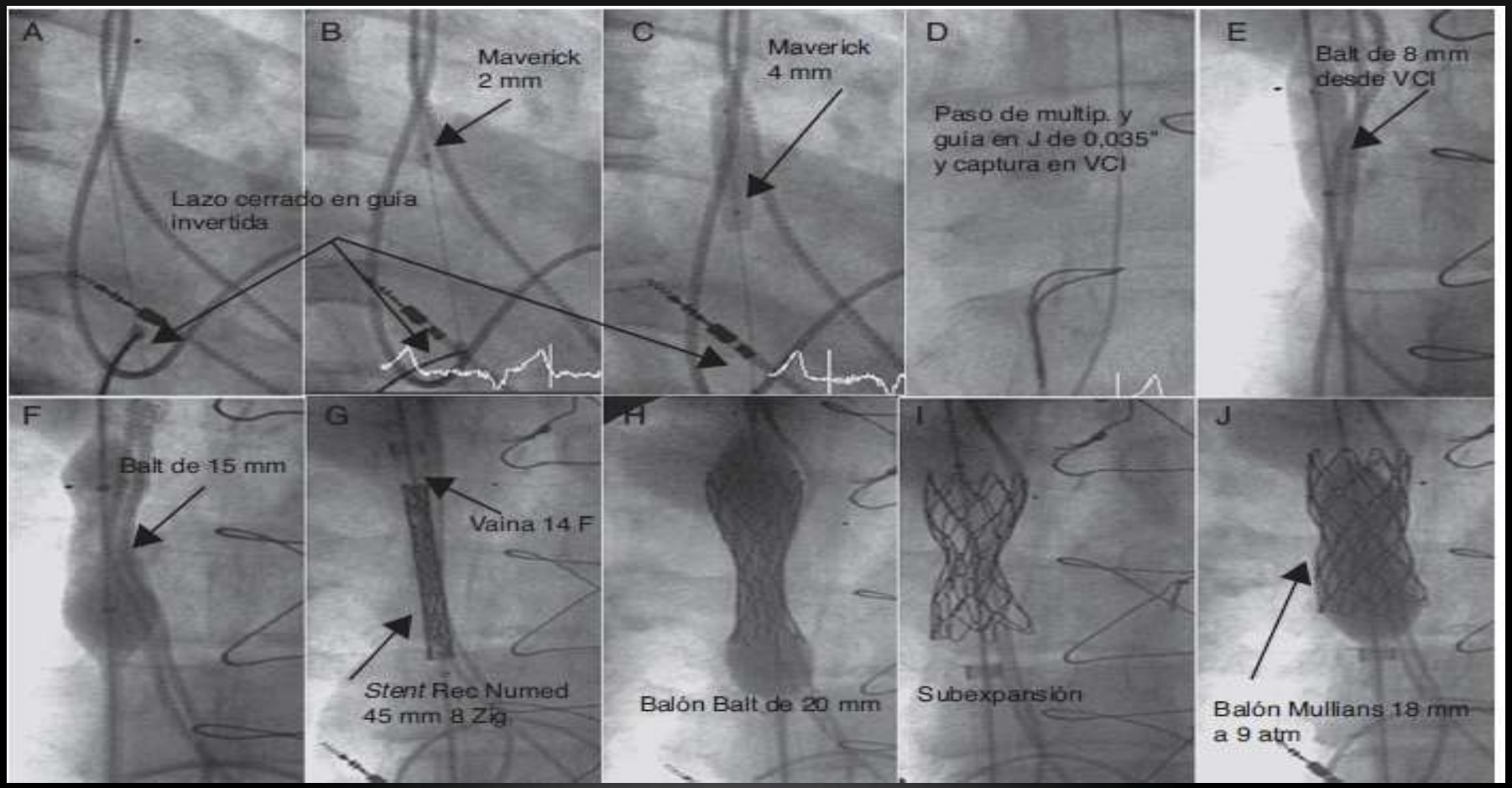

Rev Esp Cardiol. 2012;65(10):957–967

FOLLOW-UP RESULTS OF 71 PATIENTS UNDERGOING METALLIC STENT PLACEMENT FOR THE TREATMENT OF A MALIGNANT OBSTRUCTION OF THE SUPERIOR VENA CAVA

RECONSTRUCCION

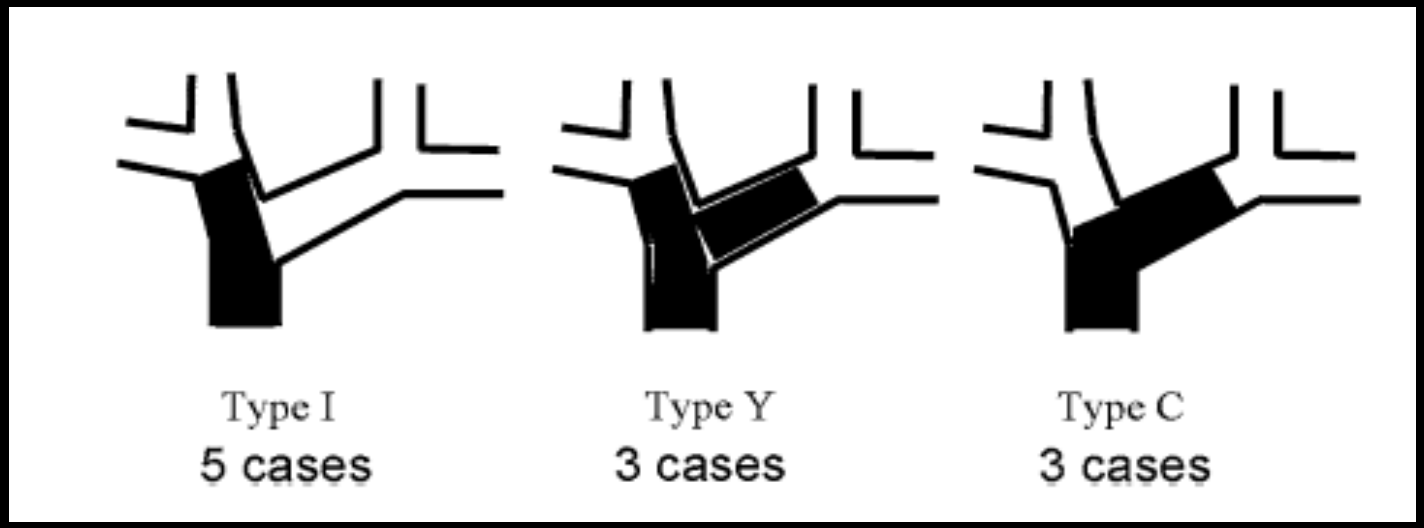

Fig. 6 Schematic of the three groups, according to the site of stent placement for bilateral BCV obstruction due to the extension of the tumor from the SVC

Cardiovasc Intervent Radiol (2007) 30:959–967

FOLLOW-UP RESULTS OF 71 PATIENTS UNDERGOING METALLIC STENT PLACEMENT FOR THE TREATMENT OF A MALIGNANT OBSTRUCTION OF THE SUPERIOR VENA CAVA

REINTERVENCION



Fig. 3 Prognosis of eight patients with recurrent SVCS after stent placement, including two patients (cases 3 and 4) treated without an additional stent, and six patients (cases 1, 2, and 5–9) treated with an additional stent for the recurrence of SVCS

Cardiovasc Intervent Radiol (2007) 30:959–967

DIALYSIS CATHETER-RELATED SUPERIOR VENA CAVA SYNDROME WITH PATENT VENA CAVA: LONG TERM EFFICACY OF UNILATERAL VIATORR STENT-GRAFT AVOIDING CATHETER MANIPULATION

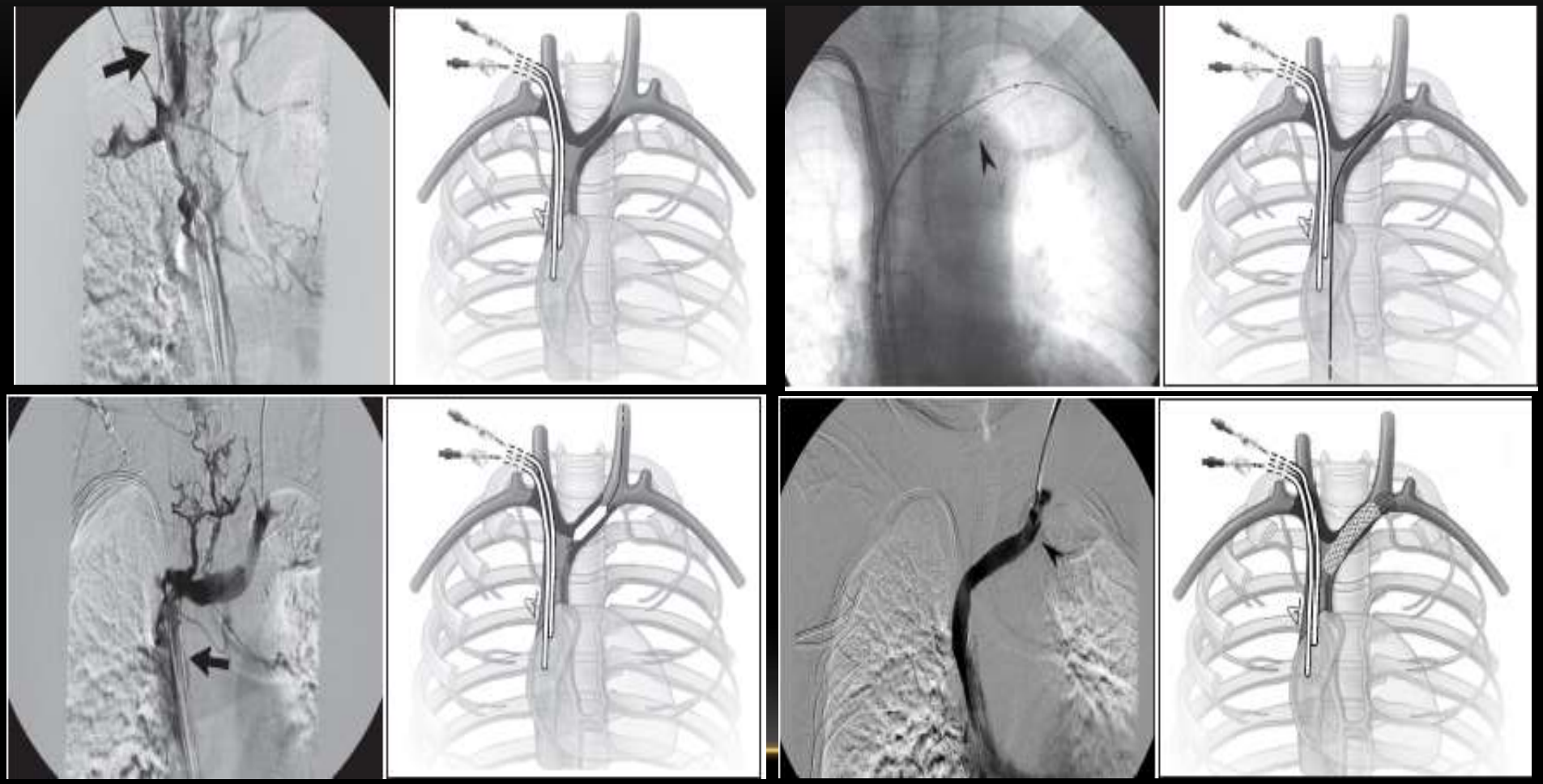

Korean J Radiol 15(3), May/Jun 2014

COMPLICACIONES

- Migración del stent
- Embolismo pulmonar.
- Procedimiento fallido.
- Dolor local.
- Edema pulmonar
- Taponamiento cardiaco.

Cardiovasc Intervent Radiol (2007) 30:959–967

CASO 1

Im: 1/61
Se: 1
ADONIAS AVILAN VENEGA
31998 80
15/07/1934
SALUDCOOP CL. JP
0110201410504
WL: 128 WW: 256 [D]
AP
01/10/2014 10:56:17 a.m

Im: 1/63
Se: 1
ADONIAS AVILAN VENEGAS
31998 80A
15/07/1934 M
SALUDCOOP CL. JPC
01102014105041
WL: 128 WW: 256 [D]
AP
01/10/2014 10:59:20 a.m.

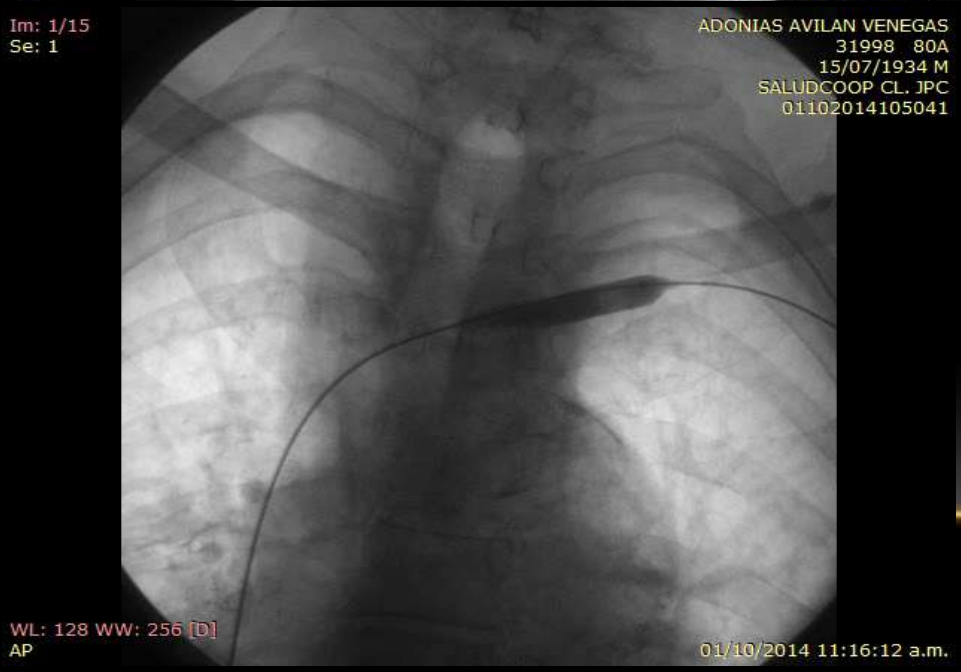
Im: 1/15
Se: 1
ADONIAS AVILAN VENEGAS
31998 80A
15/07/1934 M
SALUDCOOP CL. JPC
01102014105041
WL: 128 WW: 256 [D]
AP
01/10/2014 11:16:12 a.m.

Im: 1/42
Se: 1
ADONIAS AVILAN VENEGAS
31998 80A
15/07/1934 M
SALUDCOOP CL. JPC
01102014105041
WL: 128 WW: 256 [D]
AP
01/10/2014 11:17:32 a.m.

Im: 1/117
Se: 1
ADONIAS AVILAN VENEGA
31998 80
15/07/1934 M
SALUDCOOP CL. JP
0110201410504
WL: 128 WW: 256 [D]
AP
01/10/2014 11:19:30 a.m

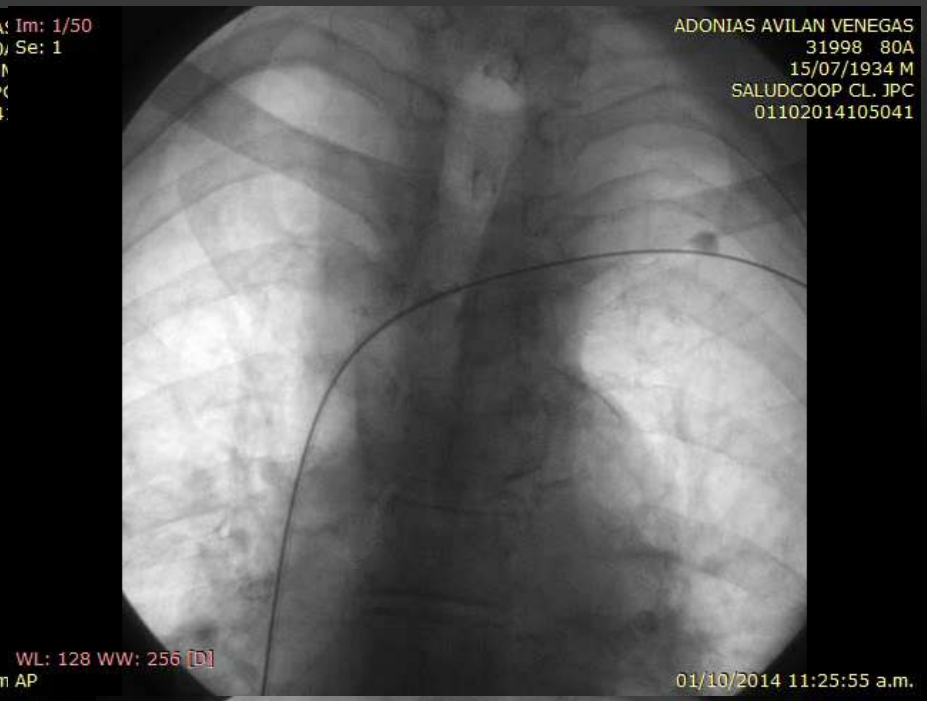
Im: 1/50
Se: 1
ADONIAS AVILAN VENEGAS
31998 80A
15/07/1934 M
SALUDCOOP CL. JPC
01102014105041
WL: 128 WW: 256 [D]
AP
01/10/2014 11:25:55 a.m.

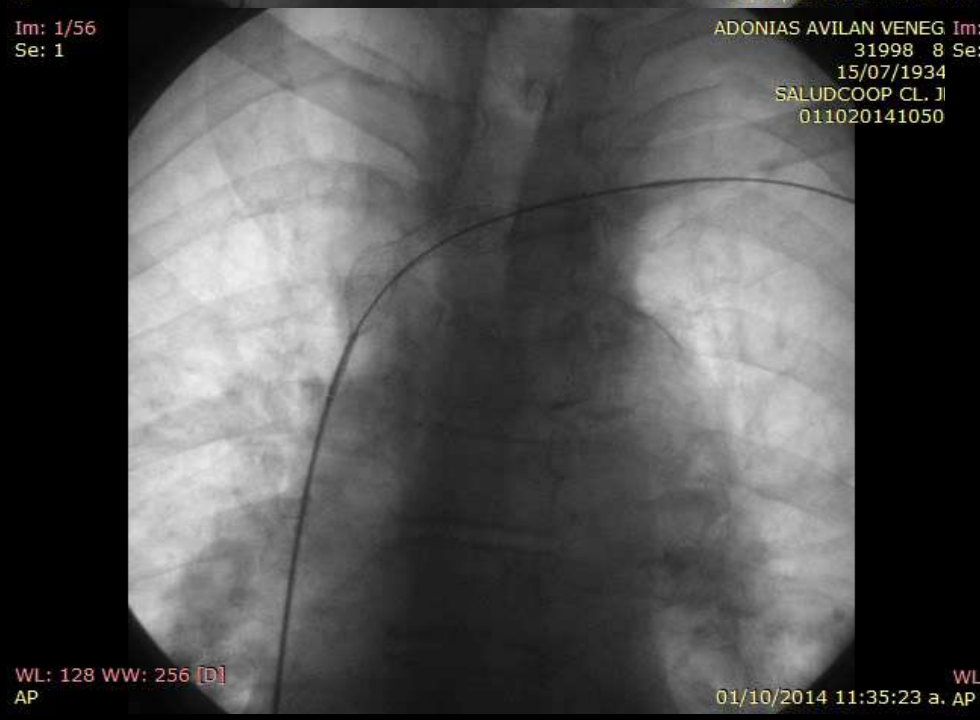
Im: 1/56
Se: 1
ADONIAS AVILAN VENEG
31998 8
15/07/1934
SALUDCOOP CL. J
011020141050
WL: 128 WW: 256 [D]
AP
01/10/2014 11:35:23 a.

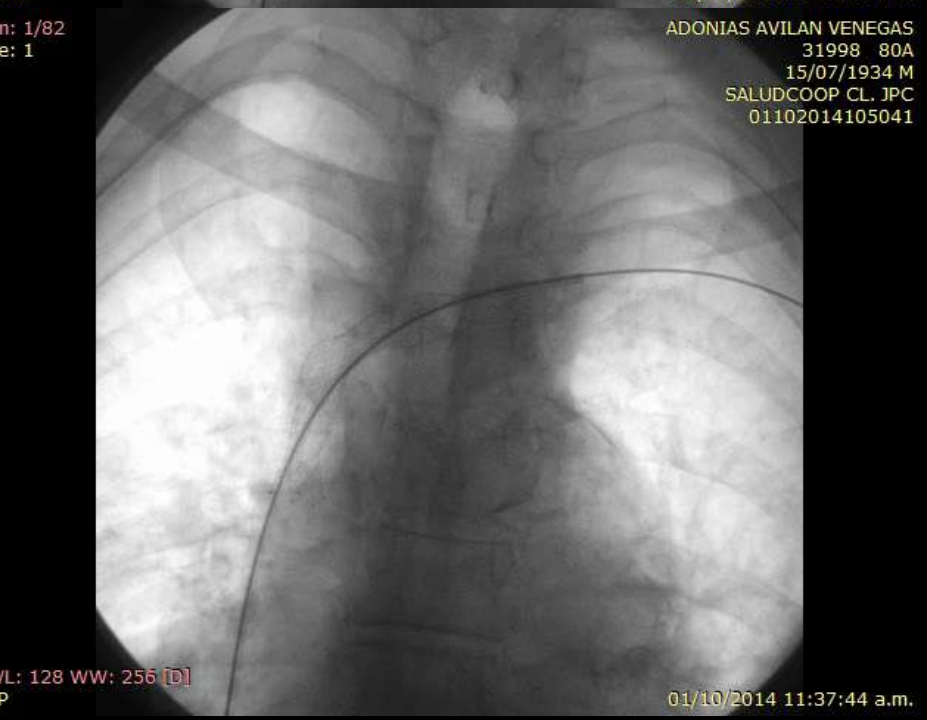
Im: 1/82
Se: 1
ADONIAS AVILAN VENEGAS
31998 80A
15/07/1934 M
SALUDCOOP CL. JPC
01102014105041
WL: 128 WW: 256 [D]
AP
01/10/2014 11:37:44 a.m.

CASO 2

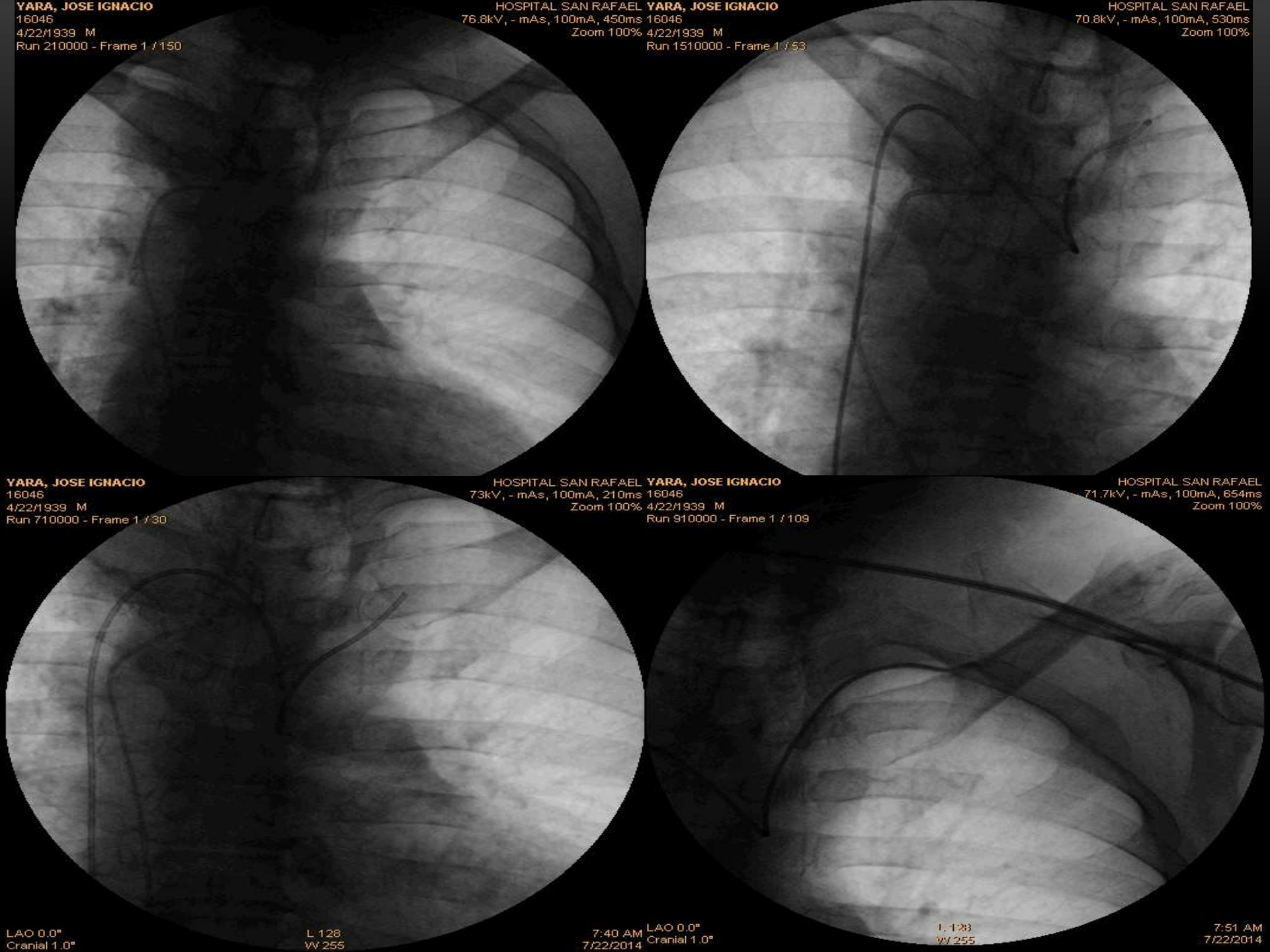
YARA, JOSE IGNACIO
16046
4/22/1939 M
Run 210000 - Frame 1 / 150
HOSPITAL SAN RAFAEL
76.8kV, - mAs, 100mA, 450ms
Zoom 100%
YARA, JOSE IGNACIO
16046
4/22/1939 M
Run 1510000 - Frame 1 / 53
HOSPITAL SAN RAFAEL
70.8kV, - mAs, 100mA, 530ms
Zoom 100%
YARA, JOSE IGNACIO
16046
4/22/1939 M
Run 710000 - Frame 1 / 30
HOSPITAL SAN RAFAEL
73kV, - mAs, 100mA, 210ms
Zoom 100%
YARA, JOSE IGNACIO
16046
4/22/1939 M
Run 910000 - Frame 1 / 109
HOSPITAL SAN RAFAEL
71.7kV, - mAs, 100mA, 654ms
Zoom 100%
LAO 0.0°
Cranial 1.0°
L 128
W 255
7:40 AM
7/22/2014
LAO 0.0°
Cranial 1.0°
L 128
W 255
7:51 AM
7/22/2014

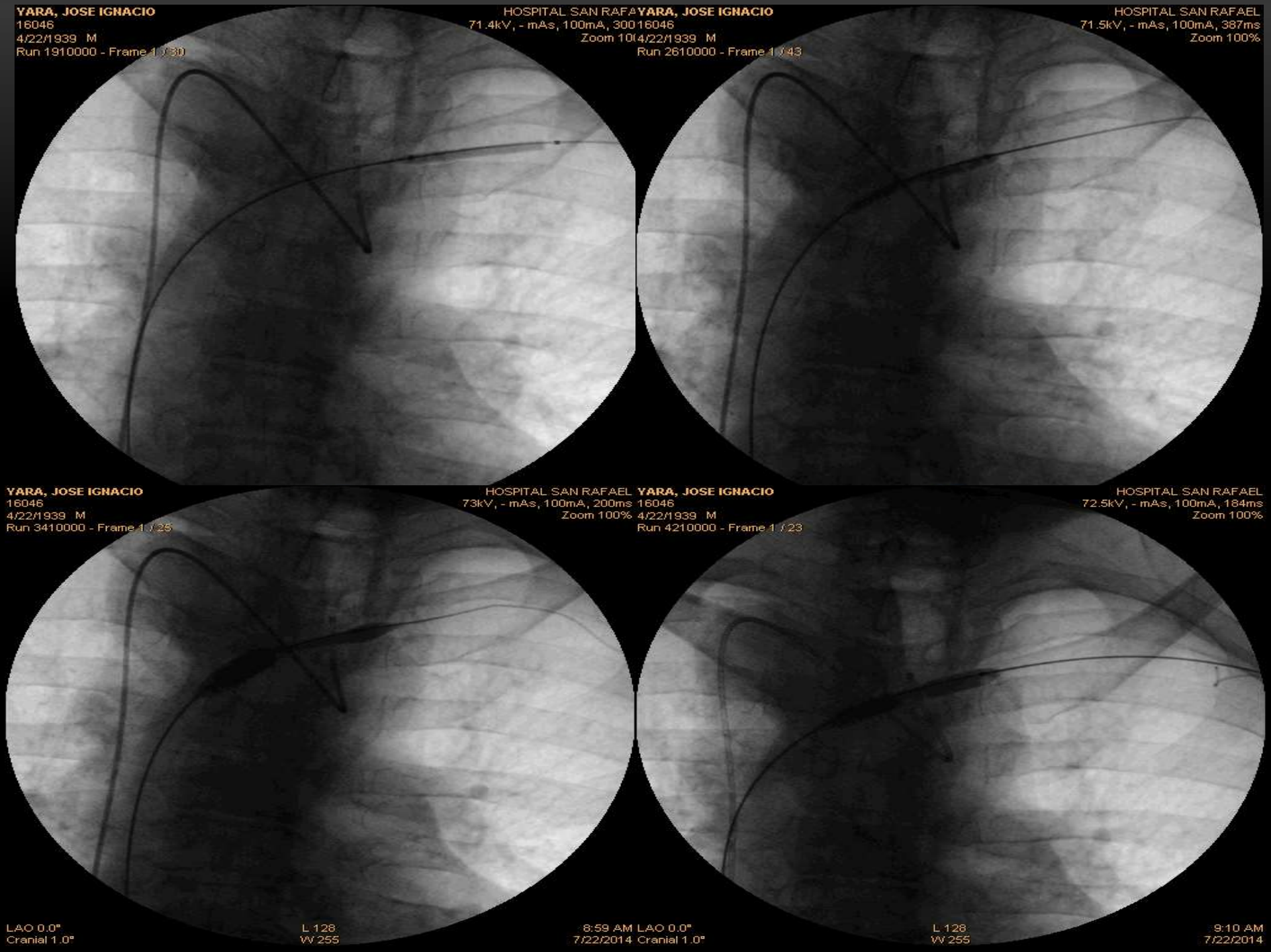
YARA, JOSE IGNACIO
16046
4/22/1939 M
Run 1910000 - Frame 1 / 30
HOSPITAL SAN RAFA
71.4kV, - mAs, 100mA, 300
Zoom 10
YARA, JOSE IGNACIO
16046
4/22/1939 M
Run 2610000 - Frame 1 / 43
HOSPITAL SAN RAFAEL
71.5kV, - mAs, 100mA, 387ms
Zoom 100%
YARA, JOSE IGNACIO
16046
4/22/1939 M
Run 3410000 - Frame 1 / 25
HOSPITAL SAN RAFAEL
73kV, - mAs, 100mA, 200ms
Zoom 100%
YARA, JOSE IGNACIO
16046
4/22/1939 M
Run 4210000 - Frame 1 / 23
HOSPITAL SAN RAFAEL
72.5kV, - mAs, 100mA, 184ms
Zoom 100%
LAO 0.0°
Cranial 1.0°
L 128
W 255
8:59 AM
7/22/2014
LAO 0.0°
Cranial 1.0°
L 128
W 255
9:10 AM
7/22/2014

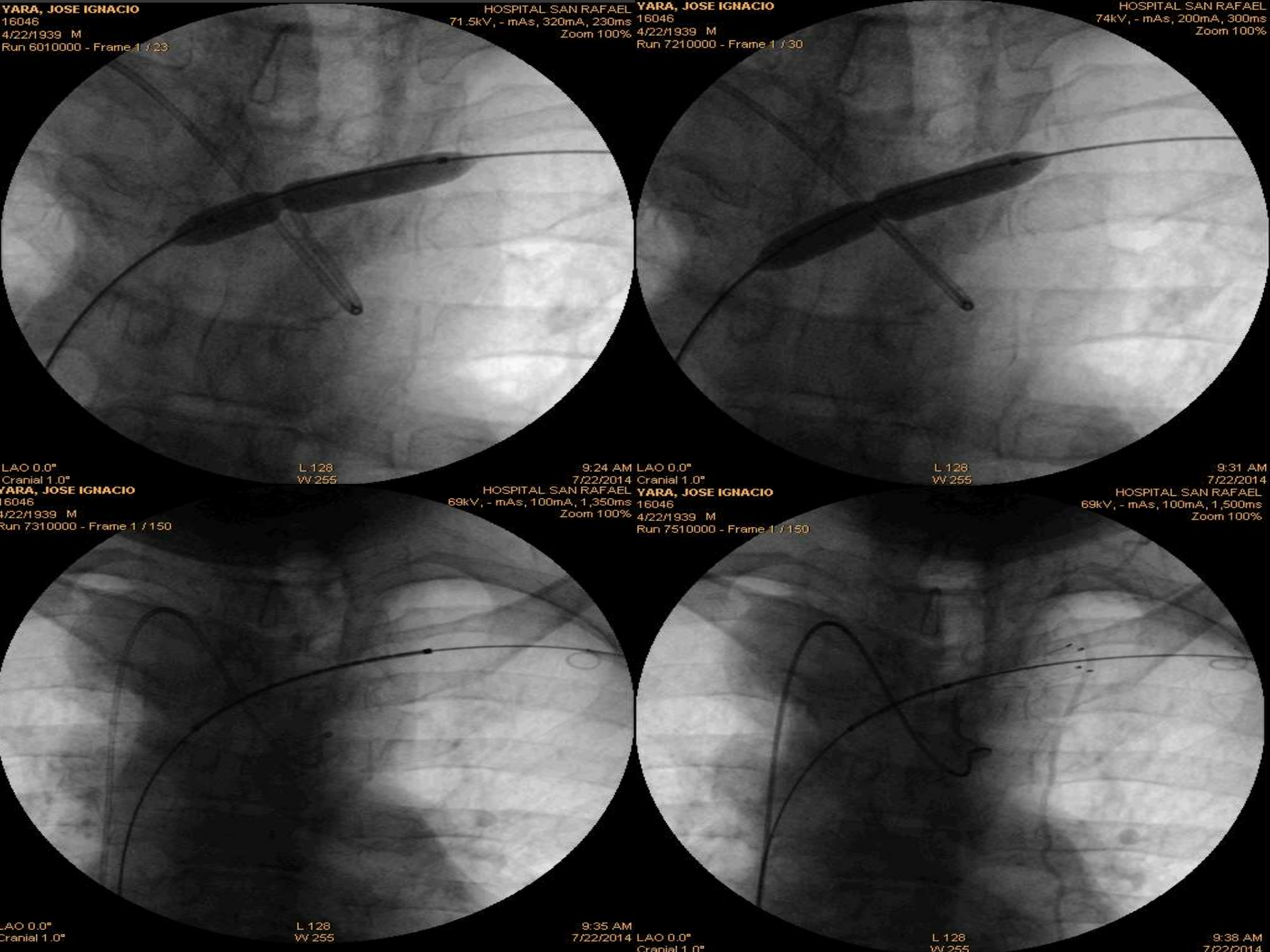
YARA, JOSE IGNACIO
16046
4/22/1939 M
Run 6010000 - Frame 1 / 23
HOSPITAL SAN RAFAEL
71.5kV, - mAs, 320mA, 230ms
Zoom 100%
LAO 0.0°
Cranial 1.0°
L 128
W 255
9:24 AM
7/22/2014
YARA, JOSE IGNACIO
16046
4/22/1939 M
Run 7210000 - Frame 1 / 30
HOSPITAL SAN RAFAEL
74kV, - mAs, 200mA, 300ms
Zoom 100%
LAO 0.0°
Cranial 1.0°
L 128
W 255
9:31 AM
7/22/2014
YARA, JOSE IGNACIO
16046
4/22/1939 M
Run 7310000 - Frame 1 / 150
HOSPITAL SAN RAFAEL
69kV, - mAs, 100mA, 1,350ms
Zoom 100%
LAO 0.0°
Cranial 1.0°
L 128
W 255
9:35 AM
7/22/2014
YARA, JOSE IGNACIO
16046
4/22/1939 M
Run 7510000 - Frame 1 / 150
HOSPITAL SAN RAFAEL
69kV, - mAs, 100mA, 1,500ms
Zoom 100%
LAO 0.0°
Cranial 1.0°
L 128
W 255
9:38 AM
7/22/2014

YARA, JOSE IGNACIO
16046
4/22/1939 M
Run 7610000 - Frame 1 / 121

HOSPITAL SAN RAFA
73.1kV, - mAs, 103mA, 1,210
Zoom 10

YARA, JOSE IGNACIO
16046
4/22/1939 M
Run 8010000 - Frame 1 / 55

HOSPITAL SAN RAFAEL
71.5kV, - mAs, 100mA, 550ms
Zoom 100%

YARA, JOSE IGNACIO
16046
4/22/1939 M
Run 8110000 - Frame 1 / 18

HOSPITAL SAN RAFAEL
70.7kV, - mAs, 100mA, 180ms
Zoom 100%

YARA, JOSE IGNACIO
16046
4/22/1939 M
Run 8210000 - Frame 1 / 90

HOSPITAL SAN RAFAEL
74.3kV, - mAs, 111mA, 900ms
Zoom 100%

LAO 0.0°
Cranial 1.0°
L 128
W 255
9:45 AM
7/22/2014

LAO 0.0°
Cranial 1.0°
L 128
W 255
9:54 AM
7/22/2014

GRACIAS