EVALUACION FUNCIONAL vs ANATOMICA DE LESIONES CORONARIAS

XIV Jornadas SOLACI 5ª Región Cono Sur

12 – 13 Mayo 2011

Asunción - Paraguay

Luis A. Mercado, MD, FACC
Centro Medico Quirúrgico
Boliviano Belga
Cochabamba - Bolivia

Exámenes en la Insuf. Coronaria

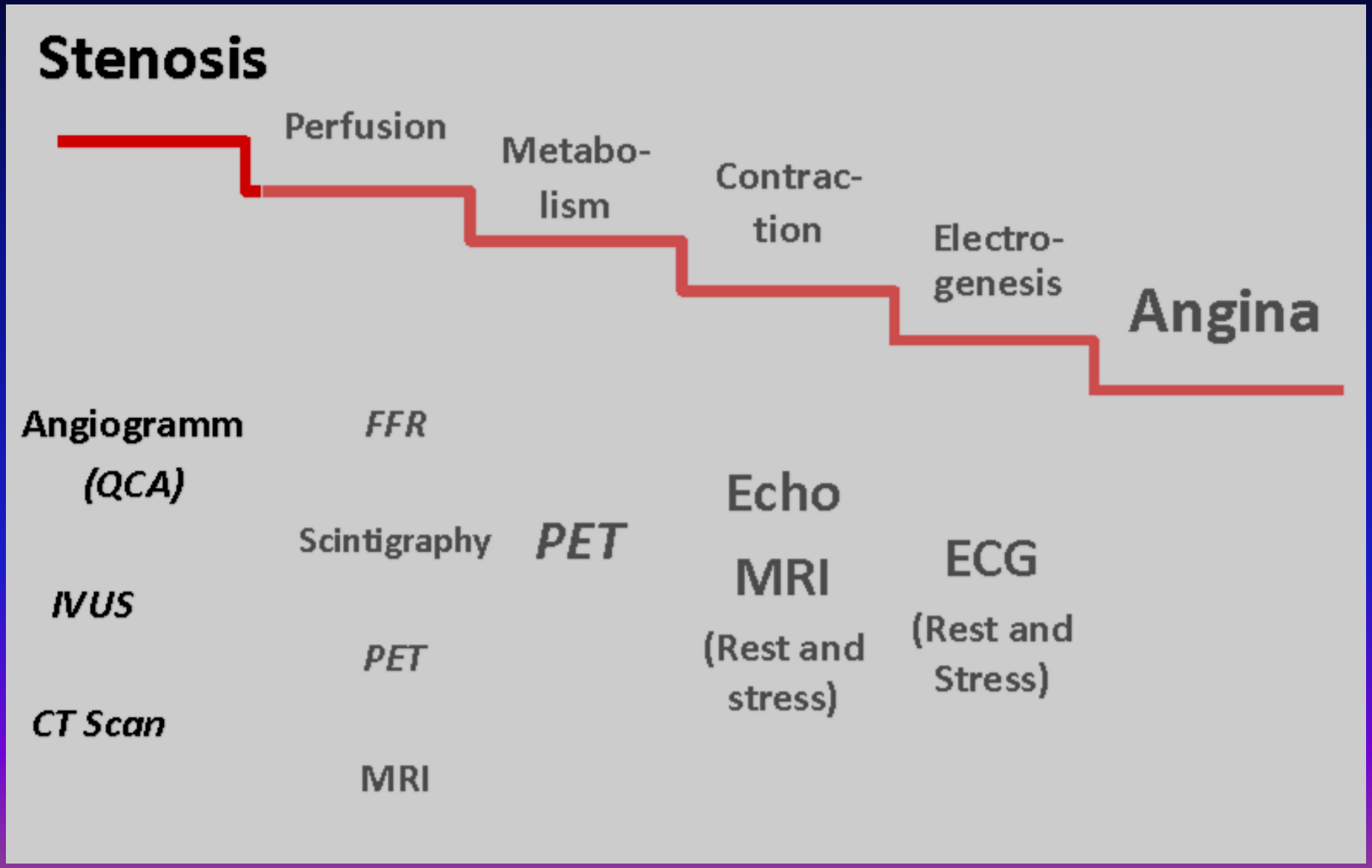

SEVERIDAD DE LAS LESIONES CORONARIAS: Angiografia

GRADO DE LESION	VASOS CORONARIOS %	TRONCO COMUN %
Leve	< 50	< 30
Moderada	50 - 70	30 - 50
Severa	> 70	> 50

SCORE DE FLUJO TIMI

SCORE	FLUJO DISTAL DE LA LESION
TIMI - 3	Flujo distal normal
TIMI - 2	Llena toda la arteria pero muy lento
TIMI - 1	Opacificación distal incompleta
TIMI - 0	Ausencia de flujo distal

Otros métodos: Count frame o el Blush miocárdico

La luz del vaso
es solo la punta del Iceberg

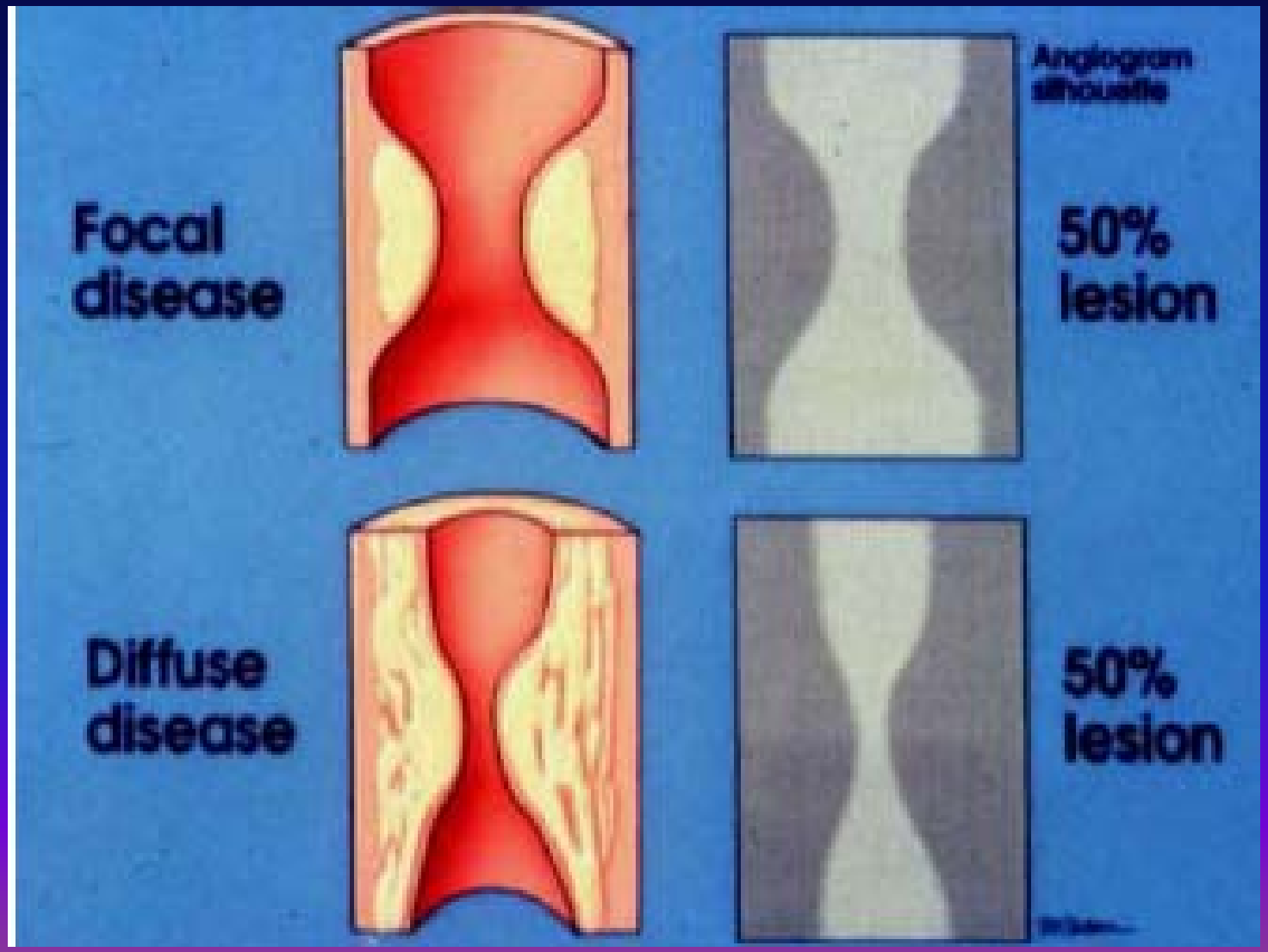

ANGIOGRAFIA CONVENCIONAL

- La observación visual: Error 10 – 30 %
  - Sobre estima lesiones 50 – 80 %
  - Sub estima lesiones < 50 %
- La Ang. Cor. Cuantitativa (QCA)
  - Diametro luminal minimo
  - Diametro de referencia
  - Porcentaje de estenosis
  - Masa del ateroma

EVALUACION CUALITATIVA

- Adquiere importancia a la hora de elegir una estrategia de Trat. de las lesiones.
- Considera características como:
  - Longitud, excentricidad
  - Angulacion, tortuosidad proximal
  - Contorno, presencia de calcio
  - Presencia en ostium o Bifurcación
  - Presencia de trombo
  - Localización en puentes venosos

EVALUACION CUALITATIVA ACC/AHA: 1988

	Tipo A	Tipo B	Tipo C
Tasa éxito ACTP	85%	60-85%	50-60%
Riesgo de oclusión	Bajo	Moderado	Alto
Longitud	<10 mm	Tubular 10-20 mm	Difusa> 20 mm
Forma	Concéntrica	Excéntrica	Muy tortuosa
Segmento proximal	Accesible	Tortuoso	Muy Tortuoso
Angulación	45°	45-90°	>90°
Pared	Lisa	Irregular	-
Calcio	No-ligero	moderado	Muy calcificadas
Estenosis	< 100%	100% < 3 meses	100% > 3 meses
Localización	No en origen No bifurcada	En origen o Bifurcada. Posible protección con doble guía	Bifurcada sin Posibilidad de proteger el vaso colateral
Trombo	Ausente	Presente	-
Otros	-	-	Lesiones en Injertos venosos

ACTP: angioplastia coronaria transluminal percutánea.

Syntax Score

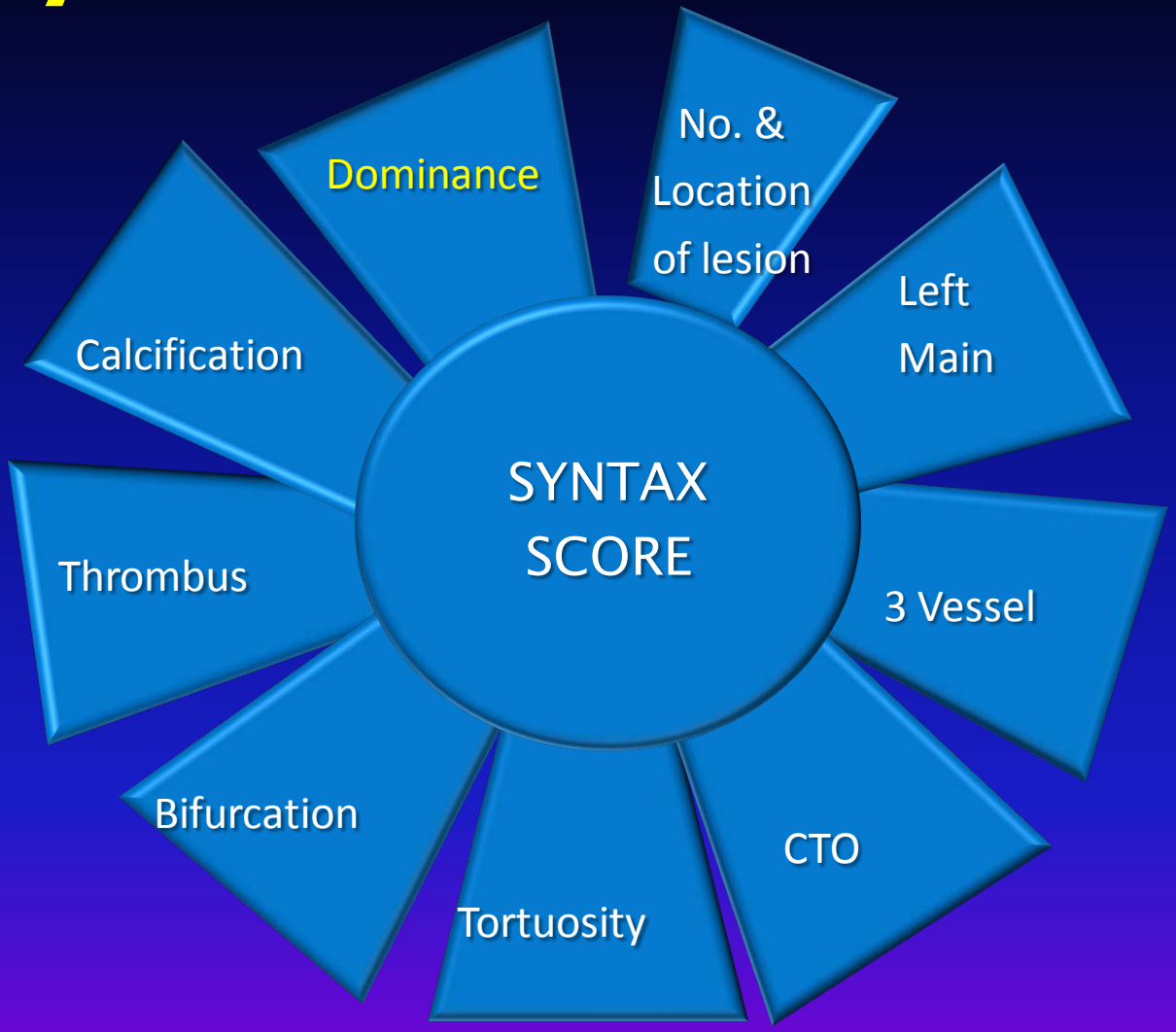

Sianos et al, EuroIntervention 2005;1:219-227
Valgimigli et al, Am J Cardiol 2007;99:1072-1081
Serruys et al, EuroIntervention 2007;3:450-459

There is '3-vessel disease' and '3-vessel disease'

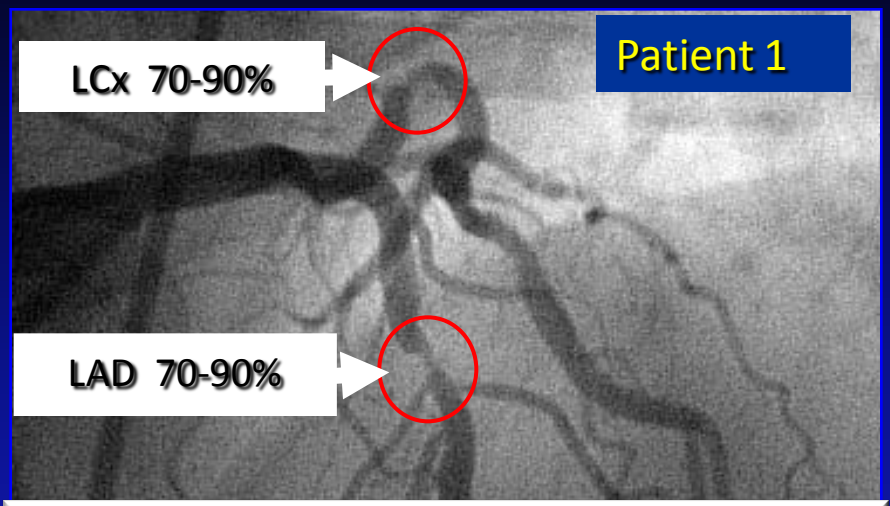

SYNTAX SCORE 21

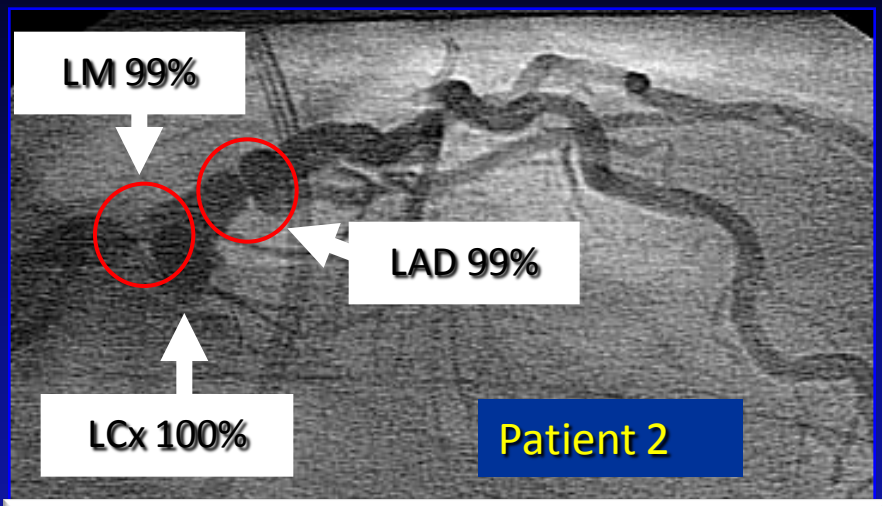

SYNTAX SCORE 52

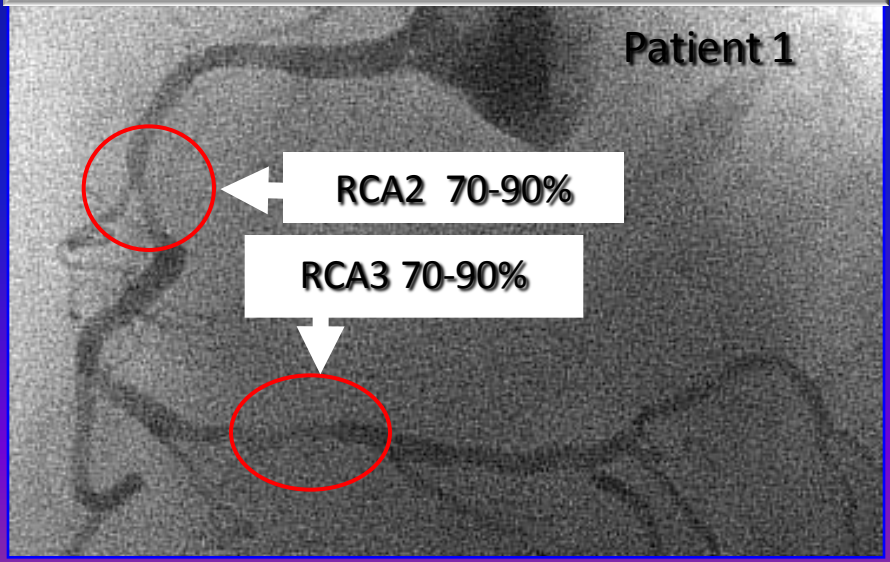

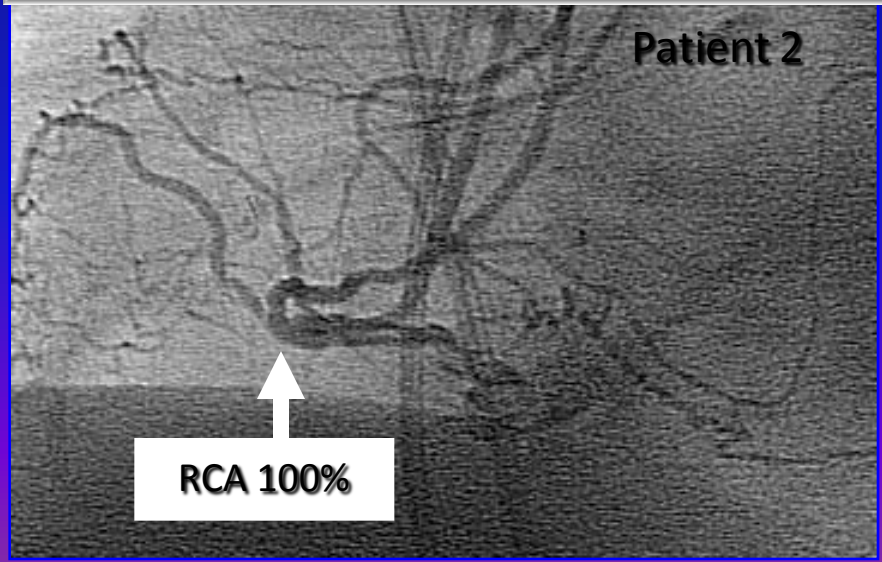

Grados de Syntax Score Implicación Terapéutica

- Score 0 – 22 : Leve
- Score 23 – 32 : Moderado
- Score > 33 : Severo

SYNTAX Trial Patient Distribution

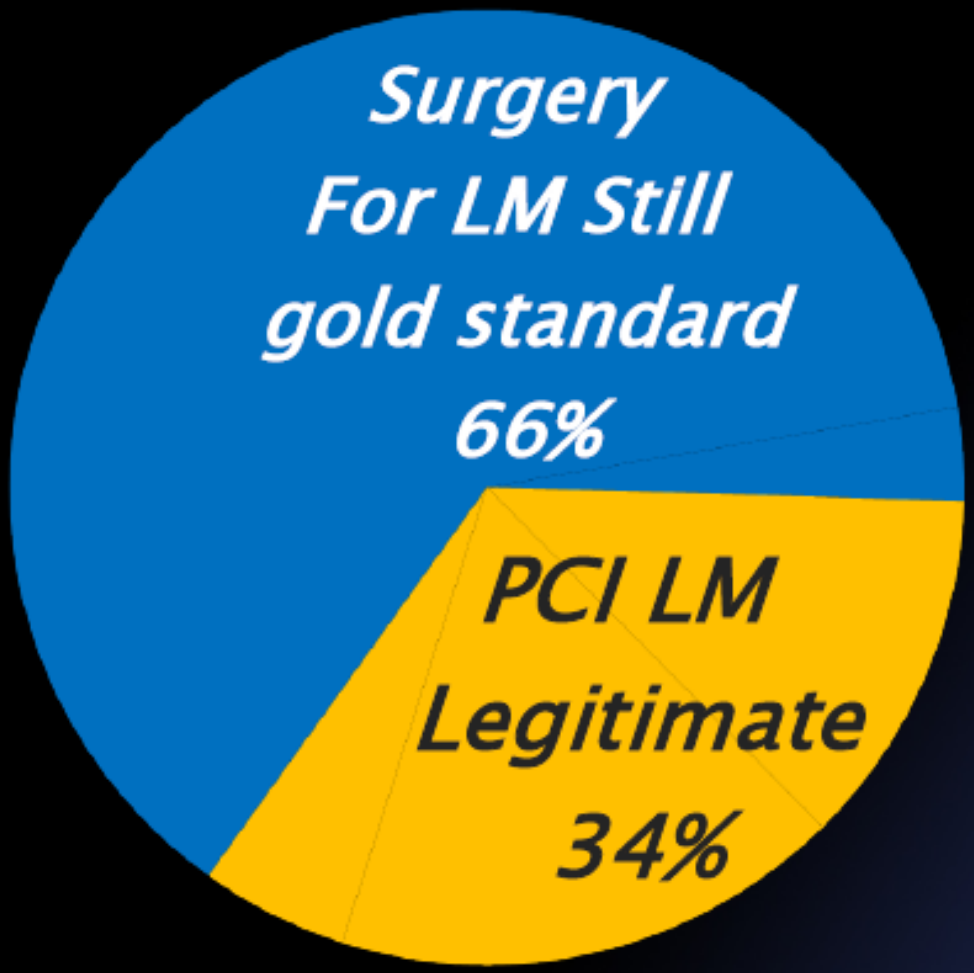

Results of the SYNTAX trial suggest that 34 % of all patients with Left Main Stem are best treated with PCI , an excellent alternative to surgery… up to three year

ULTRASONIDO INTRAVASCULAR

- Eval. Tomografica bidimensional
- Identifica componentes de la placa
- Mide con alta precisión la luz del vaso
- Es seguro y reproducible
- Detecta cambios dinamicos
- Elimina las limitaciones de la angiografia
  - Eval. correcta del área de sección transversal
  - Identifica placas en dif. niveles de evolución
  - Identifica los componentes de la placa

ULTRASONIDO INTRAVASCULAR
Datos Cualitativos

- Permite distinguir: adventicia, media, intima, lumen
- Tipos de Placas
  - LIPIDICA: Es ecogenica, brilla > adventicia
  - FIBROTICA: Ecodensa, > densa que adventicia
  - CALCIFICADA: Muy Ecodensa, sombra acustica
  - PLACA MIXTA

ULTRASONIDO INTRAVASCULAR
Datos Cualitativos

- PLACA VULNERABLE
  - Lagos Lipidicos: Hipoecoicos (áreas negras)
  - Capa fibrotica fina
  - Ulceraciones, bordes irregulares
  - Presencia de Trombo

ULTRASONIDO INTRAVASCULAR
Datos Cuantitativos

- Utiliza sistema de planimetría computarizada
- Las medidas en diástole Area del vaso y de la luz arterial en tres lugares:
  - A nivel de la lesión
  - Referencia proximal: 10 mm de la estenosis, sin ramas secundarias
  - Referencia distal: 10 mm, sin ramas

Cor. Der: Lesión compleja, Larga

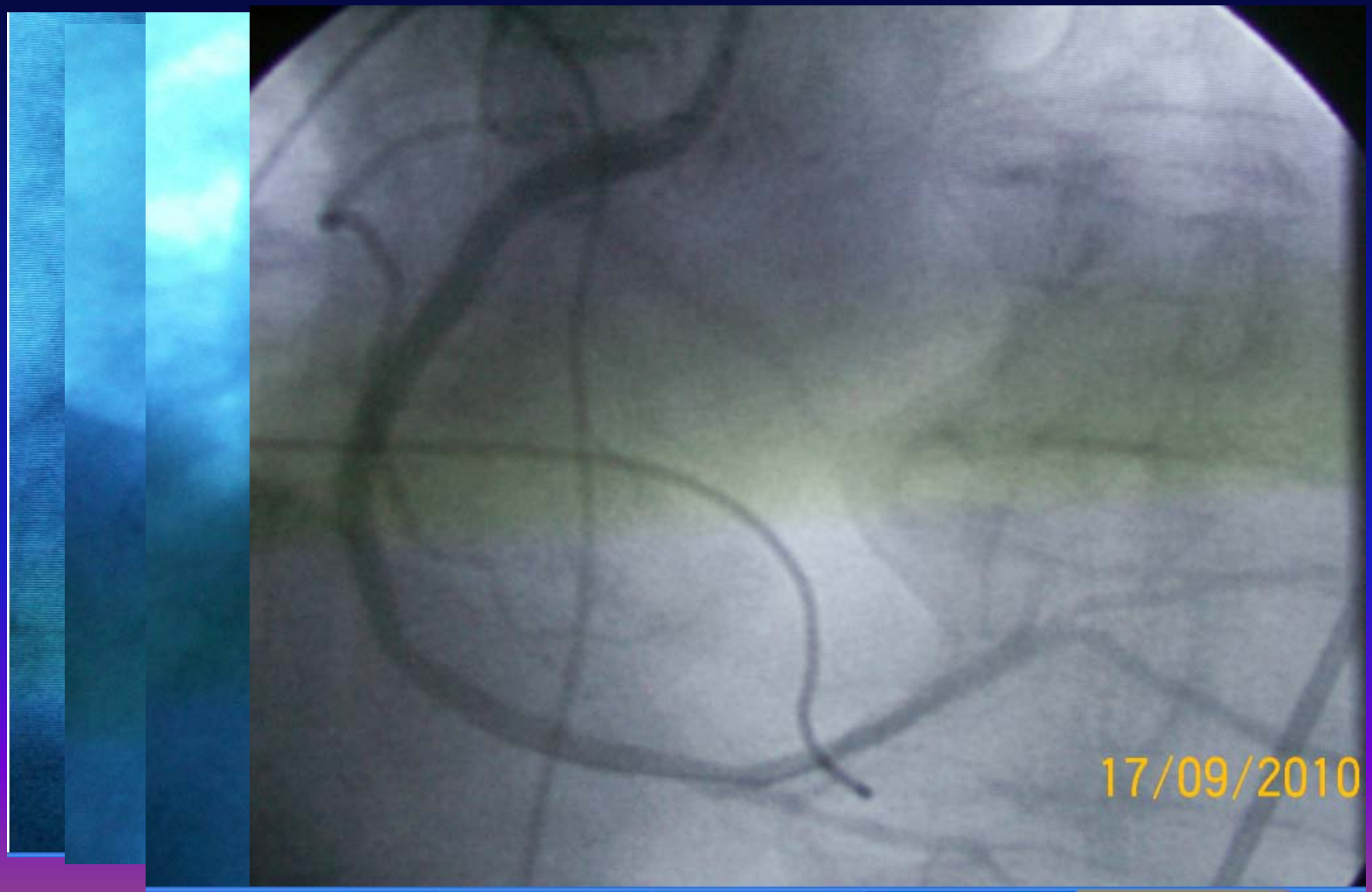

Oclusión Total de ADA

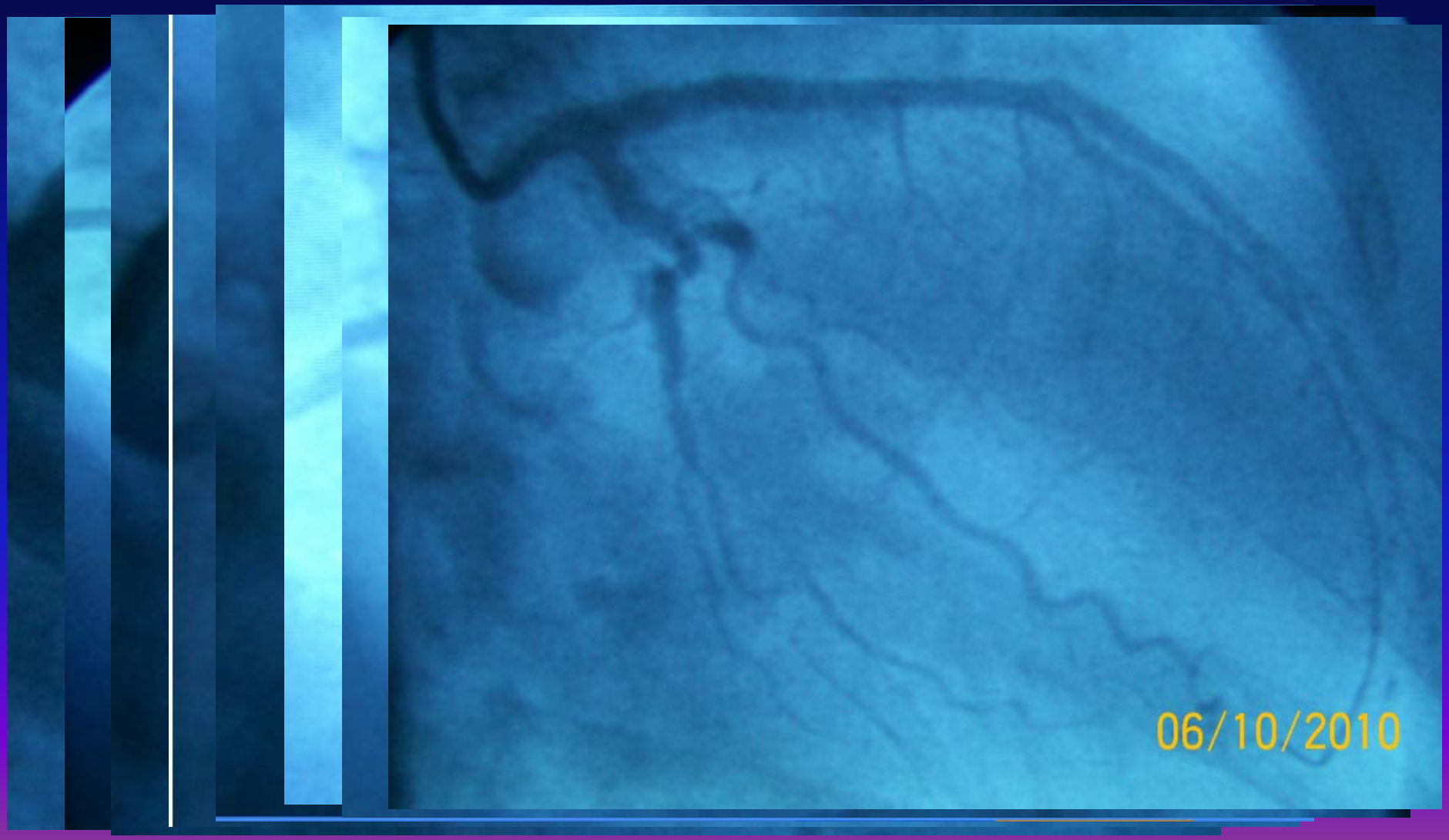

Lesión ? en ADA
ECG de Esfuerzo positivo

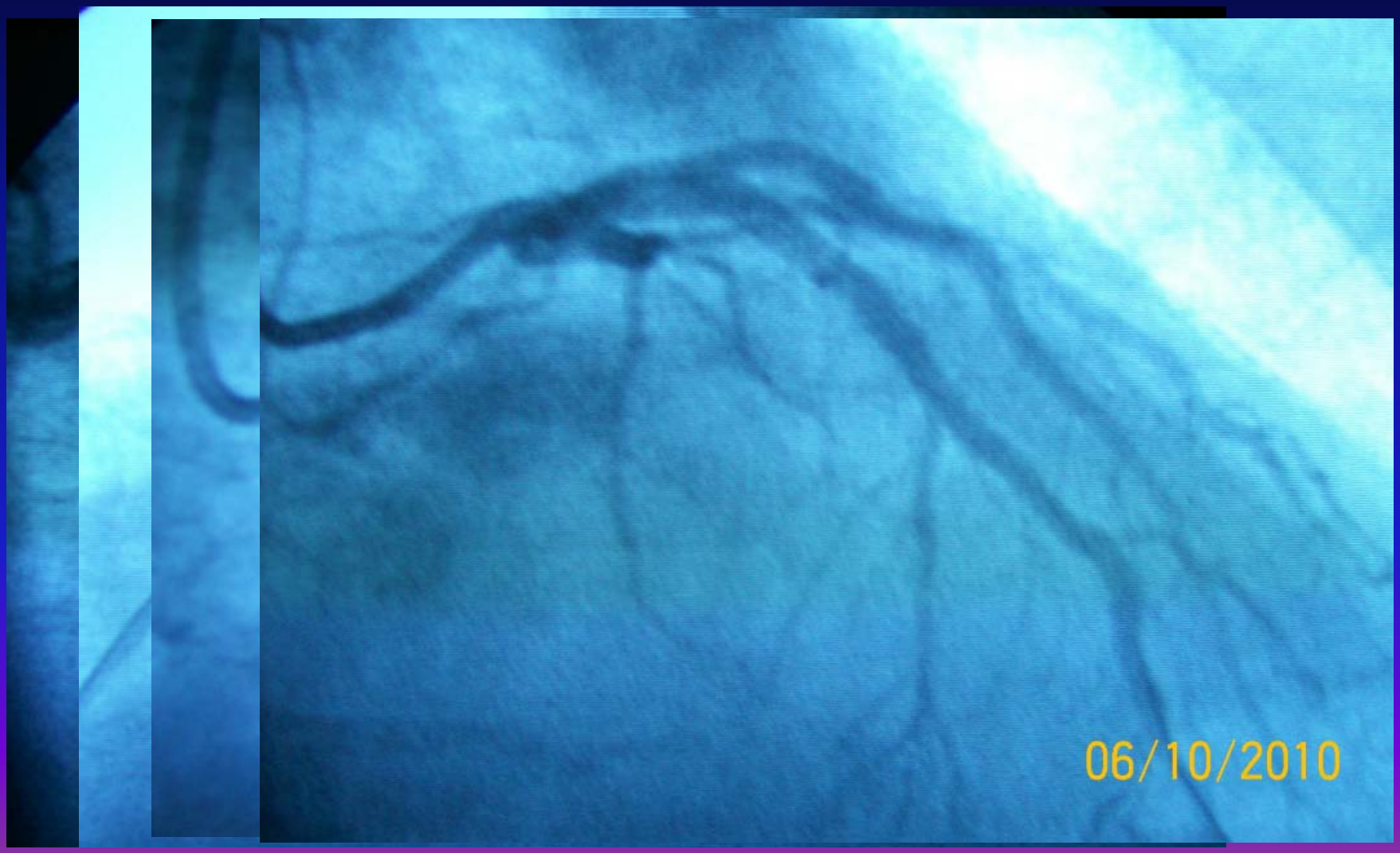

Frequency of Stress Testing to Document Ischemia Prior to Elective PCI

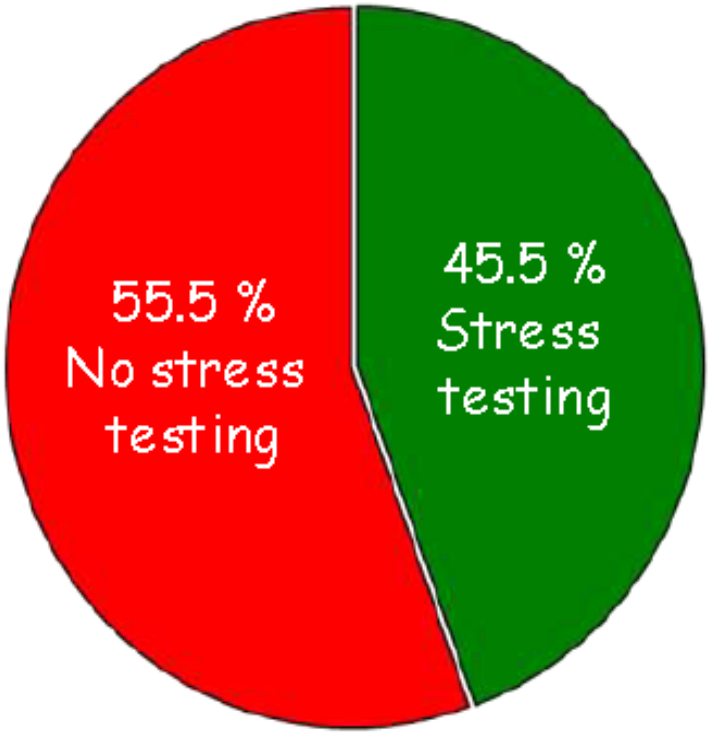

23887 Medicare patients undergoing *elective* PCI in 2004

G.A. Lin et al JAMA 2008

euro PCR

Proportion of Patients with Adequate Exercise ECG (n=1814)

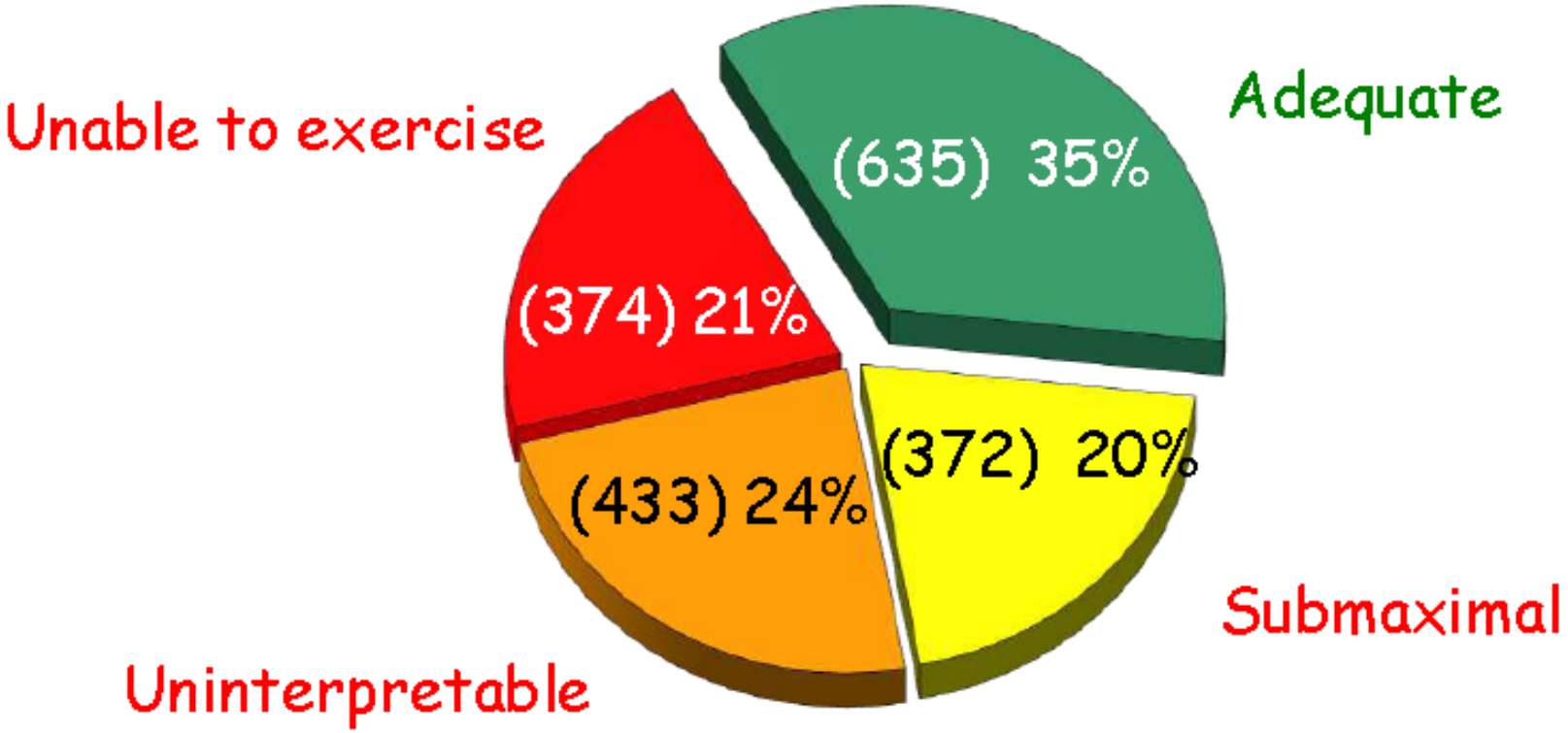

Marwick et al. 1994

Lesión Critica en Cor Der

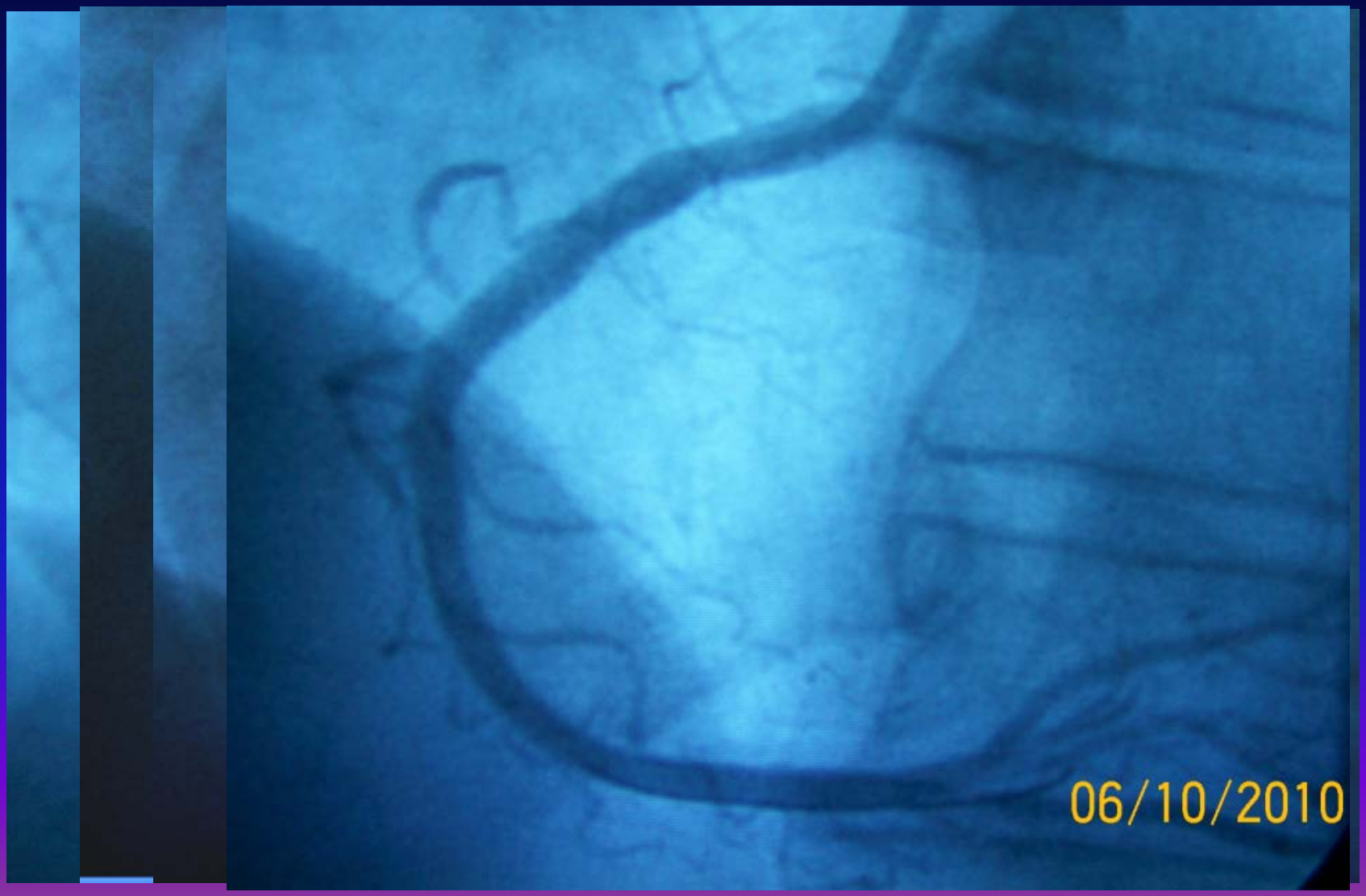

Lesión excéntrica en A Circ.

Lesión Tubular en Cor Der

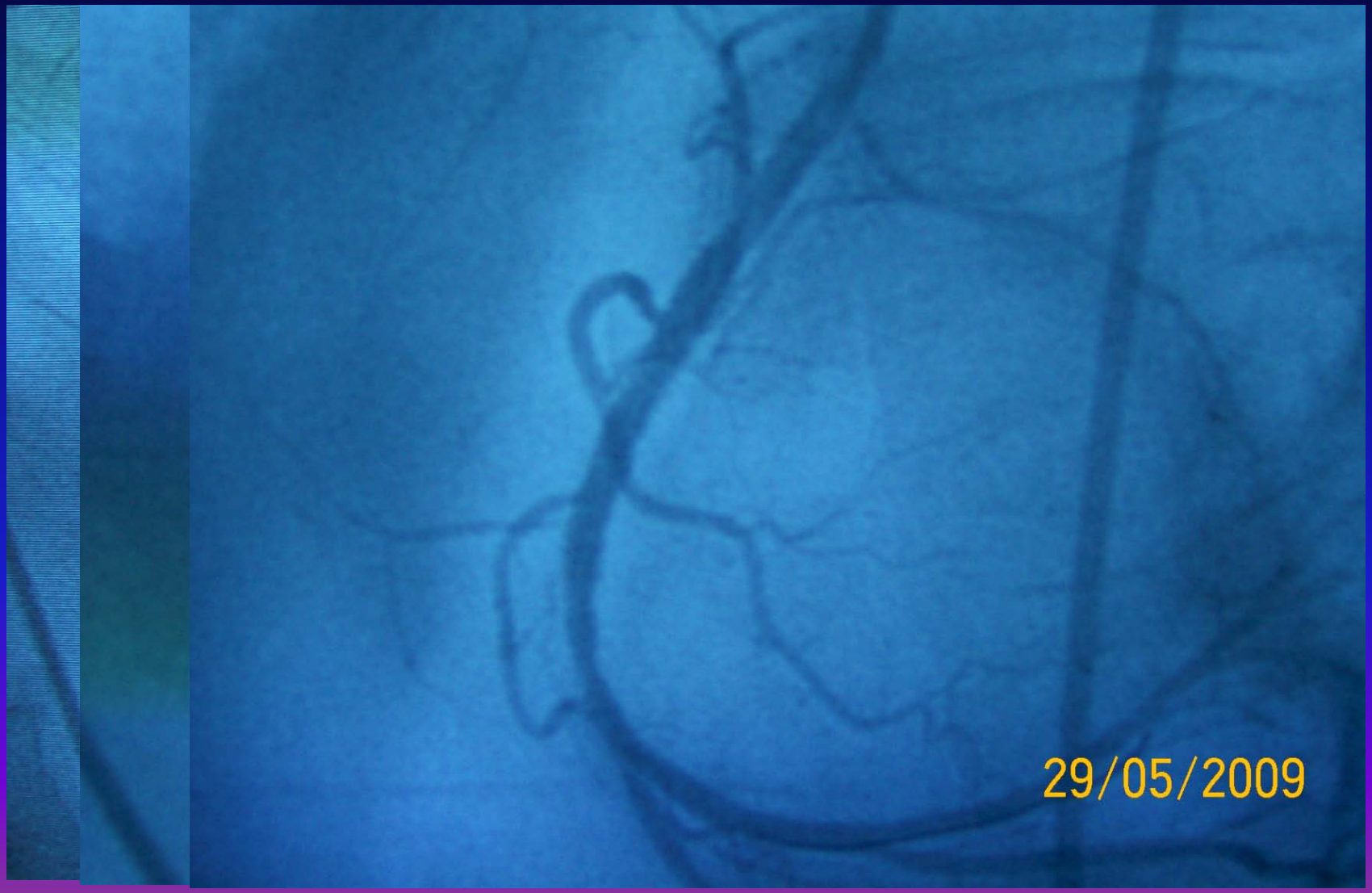

SCA SEST pared Inferior

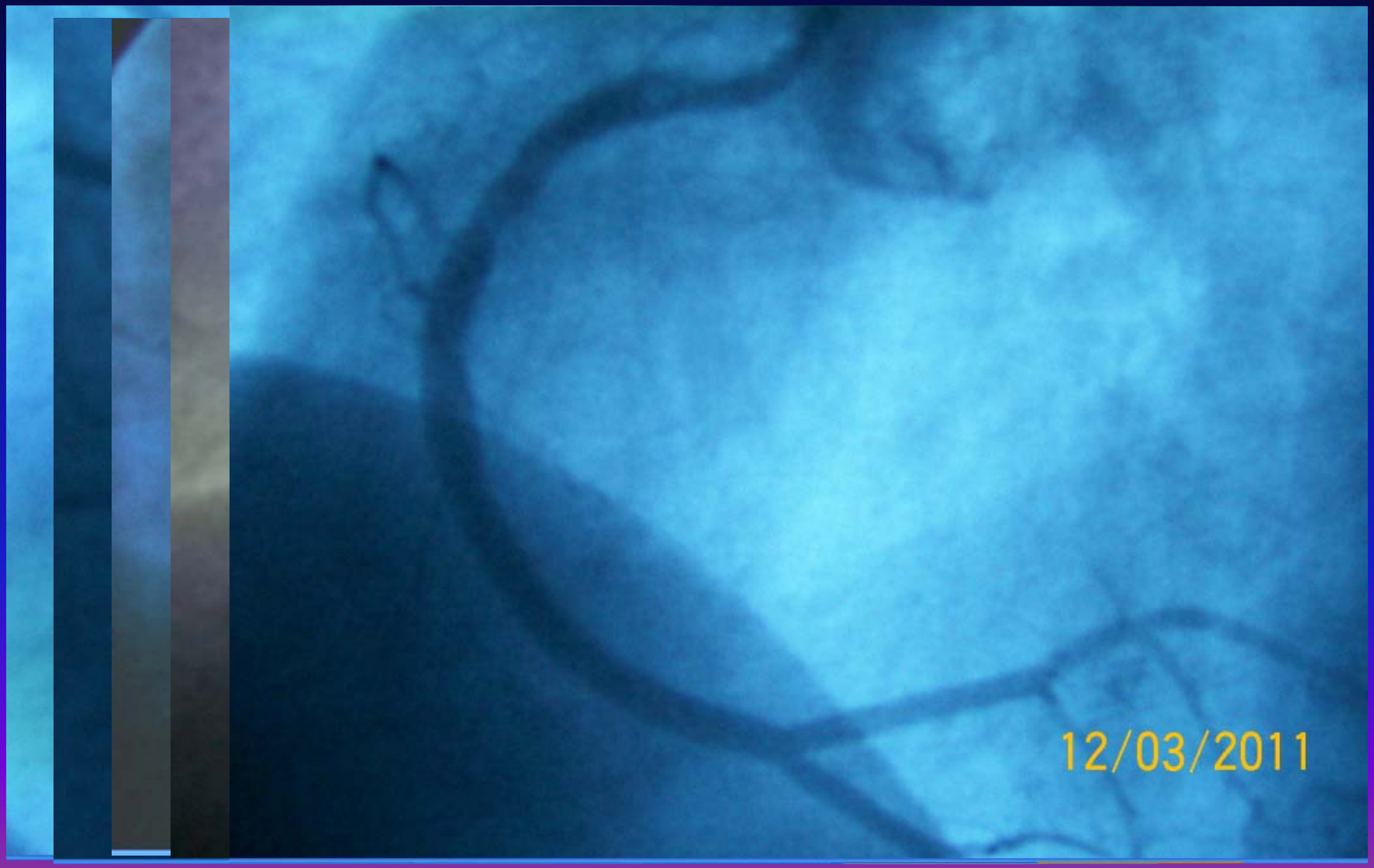

Lesión de Tronco Común
Residual post stent en CD

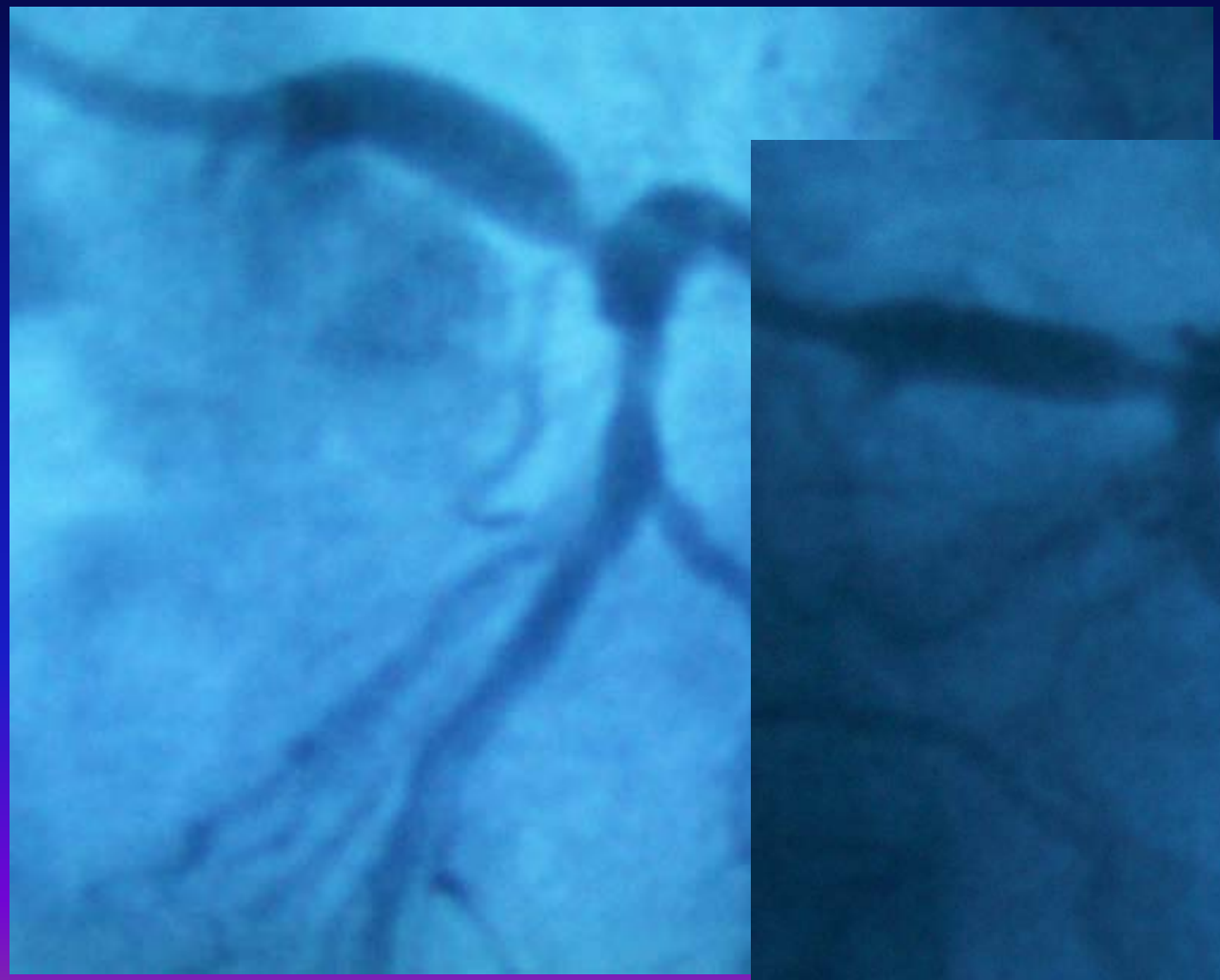

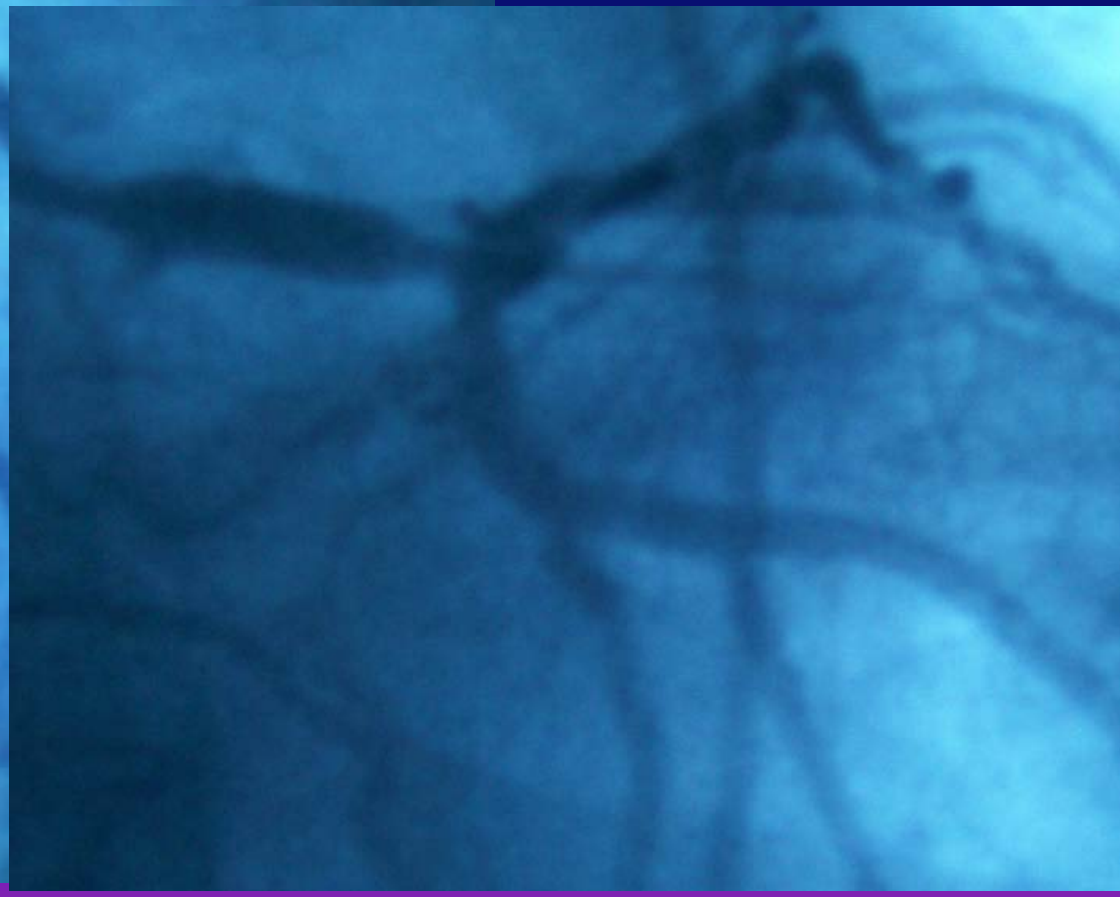

Lesión de 3V : Circ, ADA, Cor Der.

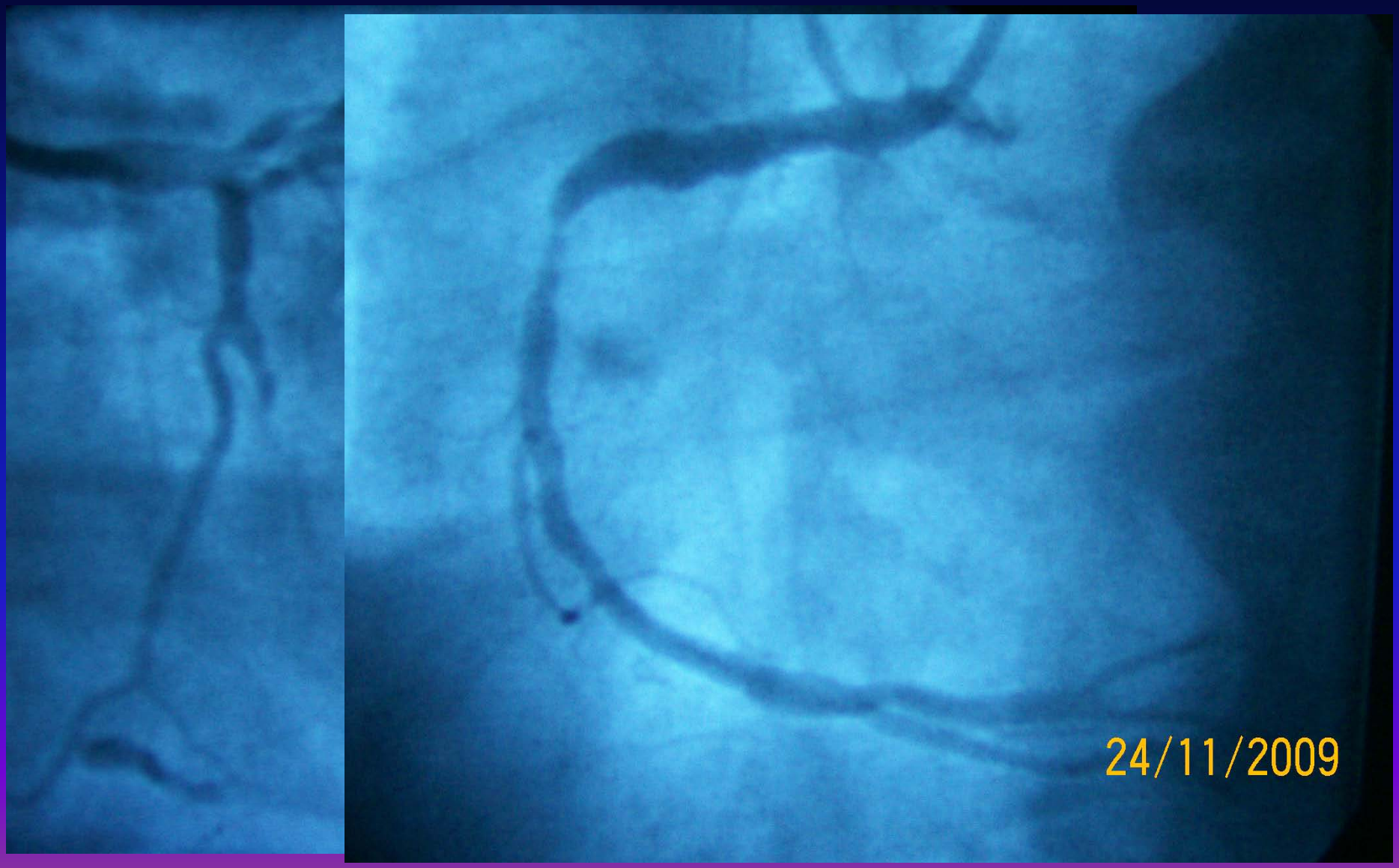

Lesión 3 V: stent Circ

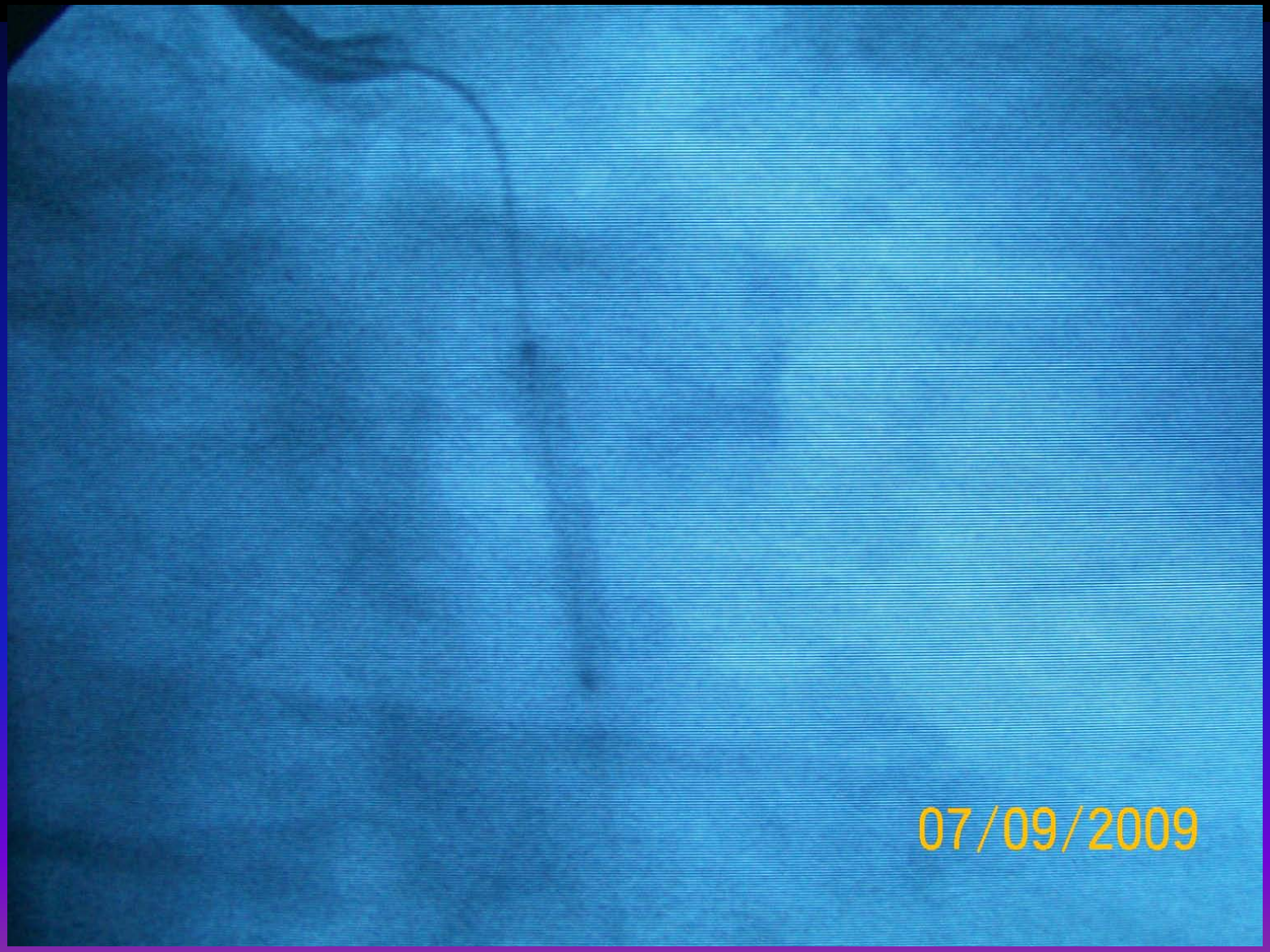

Lesion 3 V: A Circ post stent

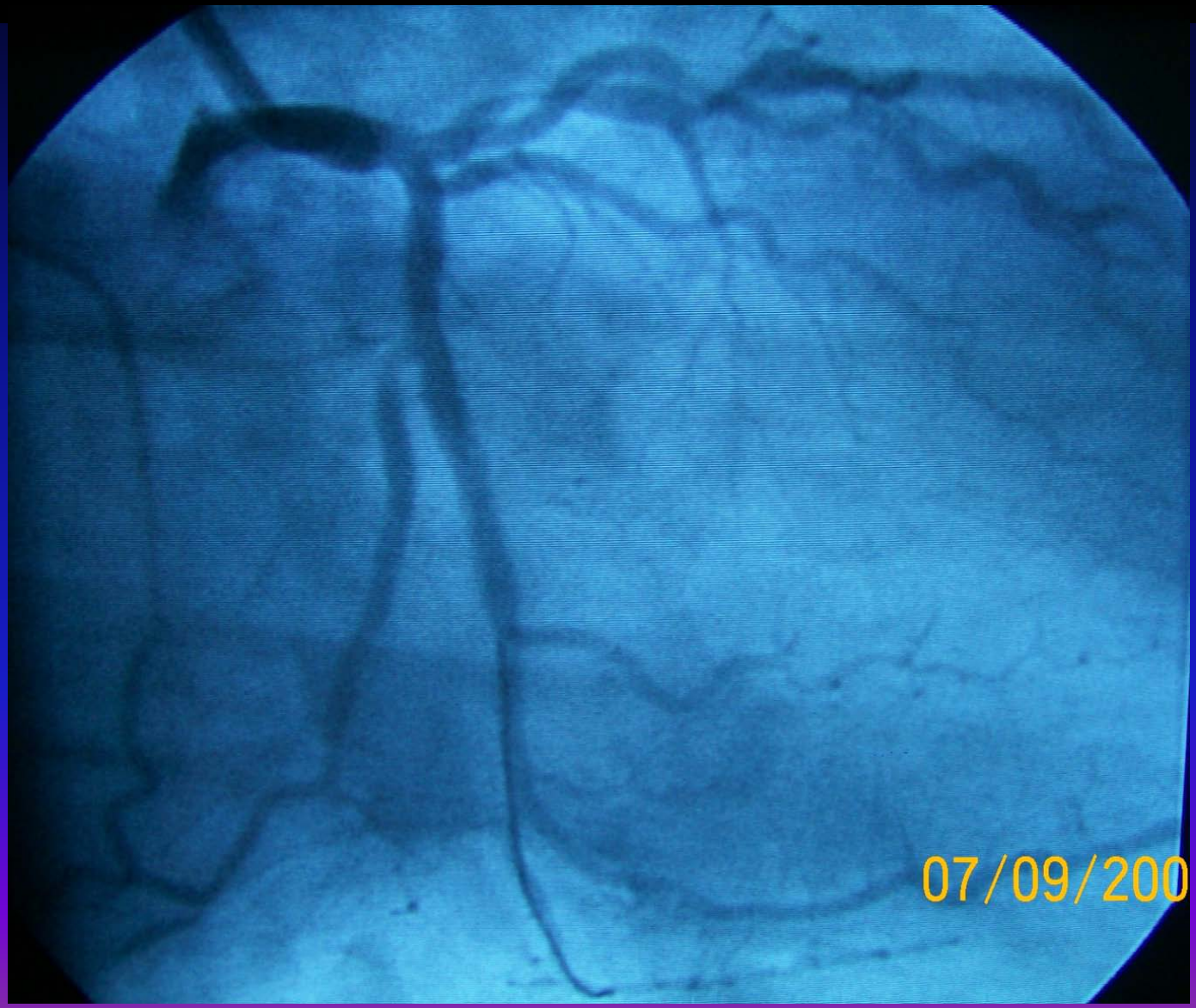

Lesion 3V: Lesión proximal en ADA

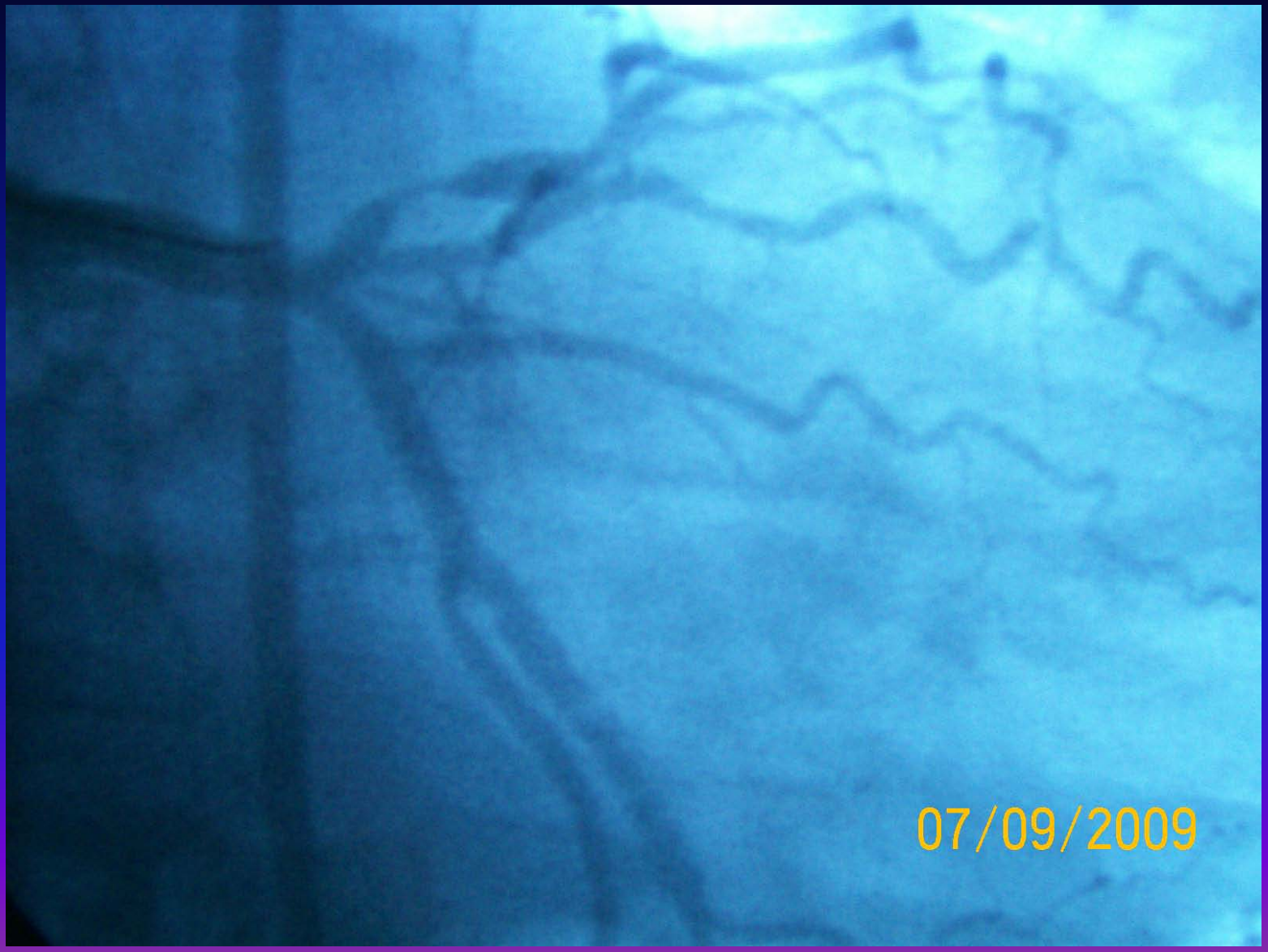

3 V: Stent en ADA proximal

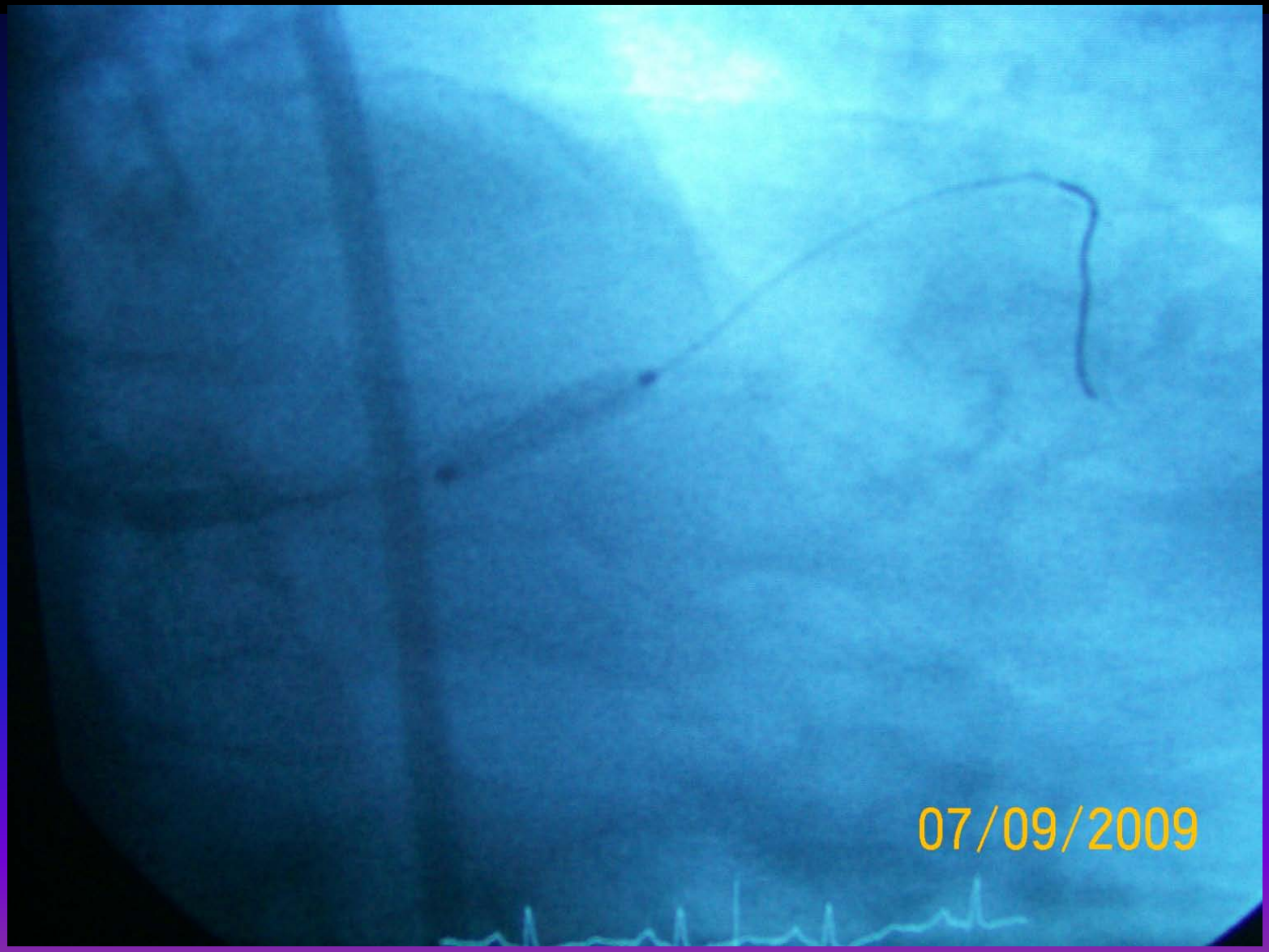

Lesion 3 V: Stent en CIR y ADA

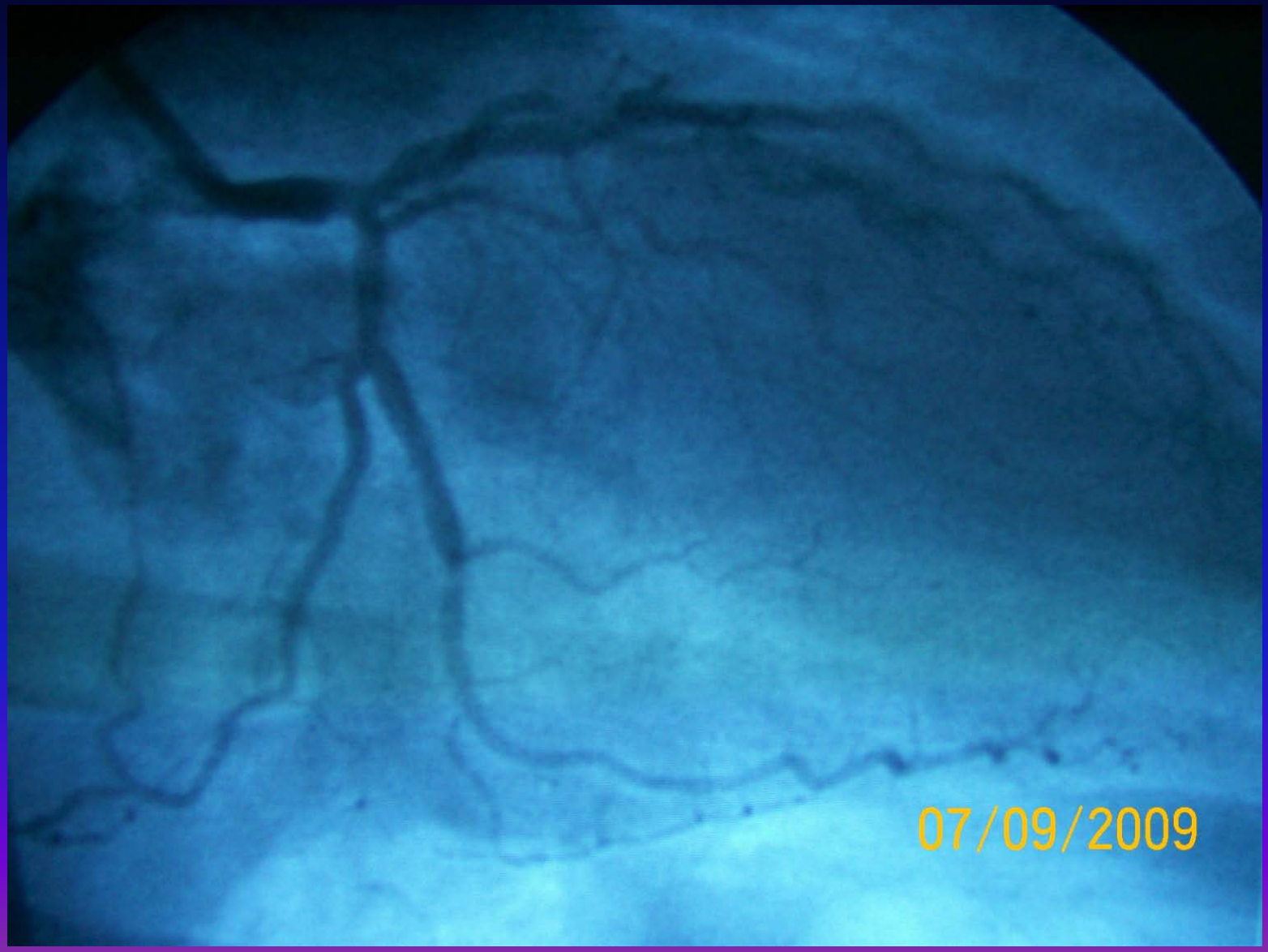

Lesion 3 V: Cor Der -> stent

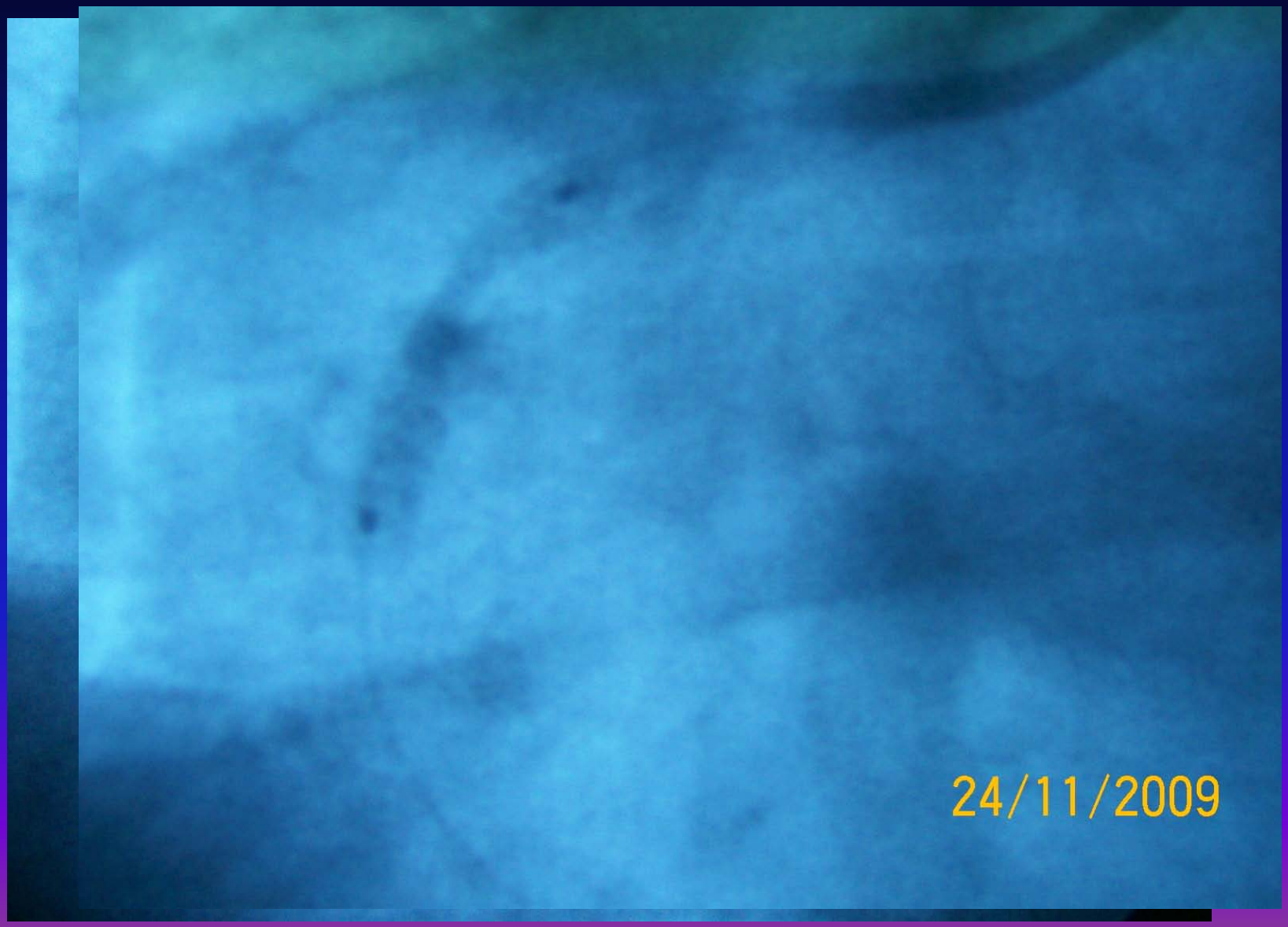

L3V: Cor Der post Stent

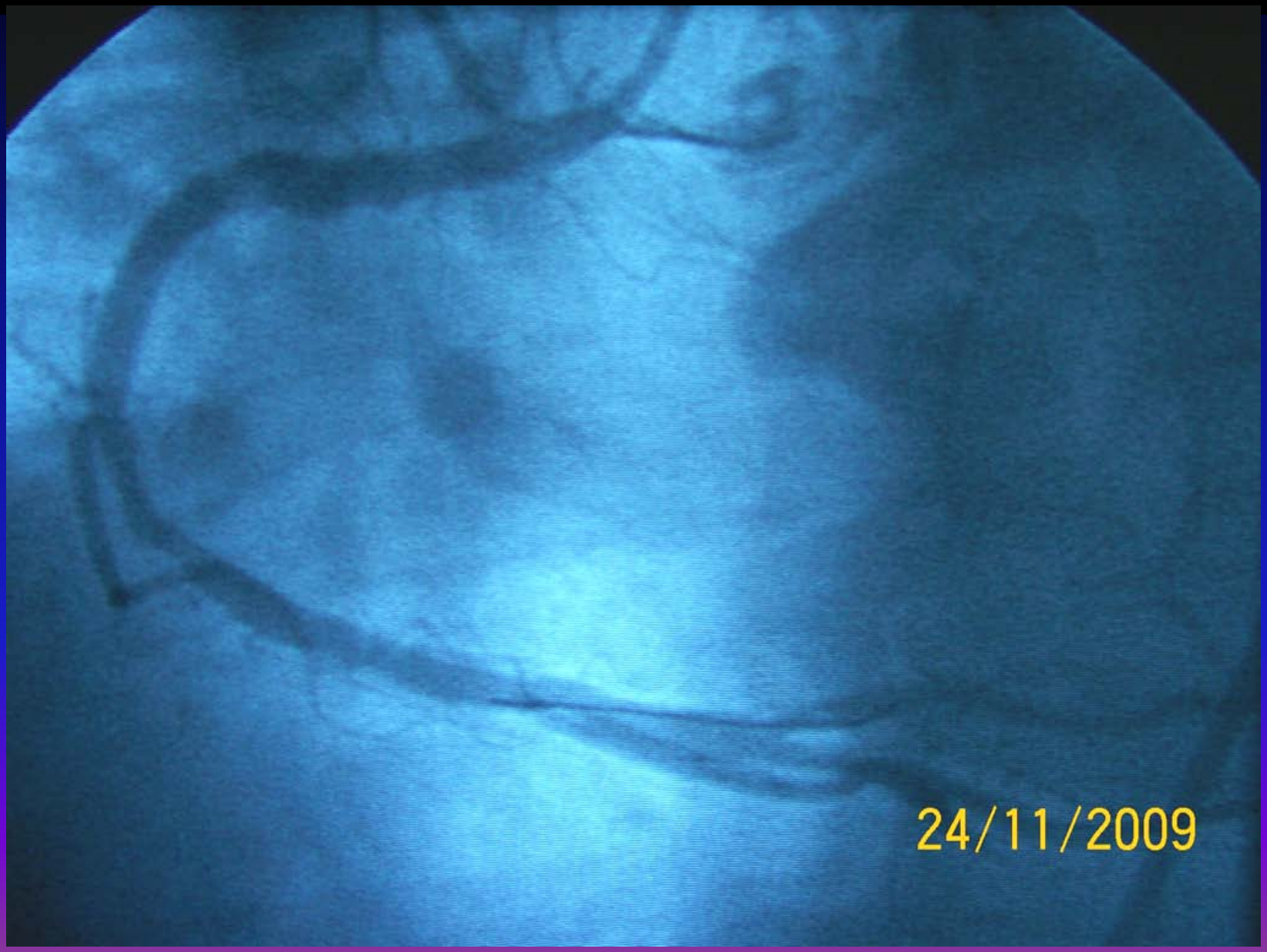

Journal of the American College of Cardiology
Published by Elsevier Inc.
© 2005 by the American College of Cardiology Foundation
Vol. 46, No. 1, 2005
ISSN 0735-1097/05/$30.00
doi:10.1016/j.jacc.2005.03.071

EXPEDITED REVIEWS

Quantification of Obstructive and Nonobstructive Coronary Lesions by 64-Slice Computed Tomography

A Comparative Study With Quantitative Coronary Angiography and Intravascular Ultrasound

Alexander W. Leber, MD,* Andreas Knez, MD,* Franz von Ziegler, MD,* Alexander Becker, MD,* Konstantin Nikolaou, MD,† Stephan Paul, MD,* Bernd Wintersperger, MD,† Maximilian Reiser, MD,† Christoph R. Becker, MD,† Gerhard Steinbeck, MD,* Peter Boekstegers, MD*

Munich, Germany

OBJECTIVES The aim of the present study was to determine the diagnostic accuracy of 64-slice computed tomography (CT) to identify and quantify atherosclerotic coronary lesions in comparison with catheter-based angiography and intravascular ultrasound (IVUS).

BACKGROUND Currently, the ability of multislice CT to quantify the degree of coronary artery stenosis and dimensions of coronary plaques has not been evaluated.

METHODS We included 59 patients scheduled for coronary angiography due to stable angina pectoris. A

INSUFICIENTE HABILIDAD DE TC PARA CUANTIFICAR EL GRADO DE LA ESTENOSIS

64-slice CT was r = 0.54. Sensitivity for the detection of stenosis <50%, stenosis >50%, and stenosis >75% was 79%, 73%, and 80%, respectively, and specificity was 97%. In comparison with IVUS, 46 of 55 (84%) lesions were identified correctly. The mean plaque areas and the percentage of vessel obstruction measured by IVUS and 64-slice CT were 8.1 mm^2 versus 7.3 mm^2 ($p < 0.03$, $r = 0.73$) and 50.4% versus 41.1% ($p < 0.001$, $r = 0.61$), respectively.

CONCLUSIONS Contrast-enhanced 64-slice CT is a clinically robust modality that allows the identification of proximal coronary lesions with excellent accuracy. Measurements of plaque and lumen areas derived by CT correlated well with IVUS. A major limitation is the insufficient ability of CT to exactly quantify the degree of stenosis. (J Am Coll Cardiol 2005;46:147–54) © 2005 by the American College of Cardiology Foundation

STATE-OF-THE-ART PAPER

Quantification of Coronary Arterial Stenoses by Multidetector CT Angiography in Comparison With Conventional Angiography

Methods, Caveats, and Implications

Armin Arbab-Zadeh, MD, PhD,* John Hoe, MD†

Baltimore, Maryland; and Singapore, Republic of Singapore

DISPARIDAD EN LA SEVERIDAD DE LAS ESTENOSIS ES COMUN ENTRE ESTOS DOS METODOS

In patients, disagreement on individual coronary arterial stenosis severity is common between MDCT and the current gold standard, conventional angiography. The reasons for such disagreement are numerous, but are at least partly inherent to MDCT's modest spatial and temporal resolution at present. Less well acknowledged, however, is the fact that MDCT and conventional angiography are fundamentally different technologies, rendering good agreement on the degree of lumen narrowing rather unrealistic, given both of their respective limitations. Discrepant stenosis assessment by MDCT and conventional angiography receives remarkable attention, whereas its significance for patient outcome is less certain. On the other hand, the ability to noninvasively assess coronary arterial plaque characteristics and composition in addition to lumen obstruction shows strong promise for improved risk assessment and may at last enable us to move beyond mere coronary stenosis assessment for the management of patients with coronary artery disease. (J Am Coll Cardiol Img 2011;4: 191–202) © 2011 by the American College of Cardiology Foundation

Limitaciones MD CT Angio

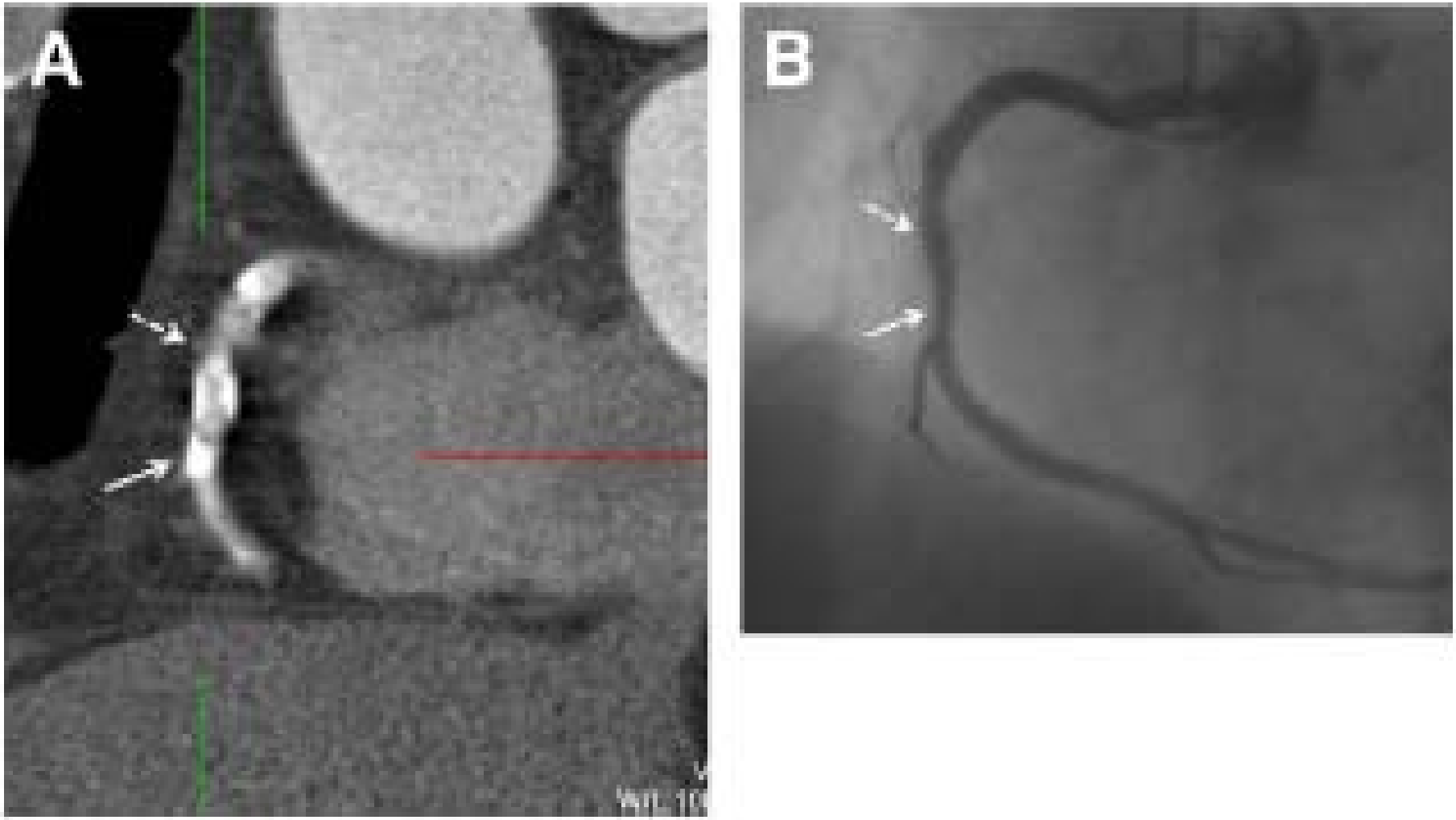

Figure 6. Influence of Cardiac Motion and Coronary Calcium on Diagnostic Accuracy

Comprehensive Assessment of Coronary Artery Stenoses

Computed Tomography Coronary Angiography Versus Conventional Coronary Angiography and Correlation With Fractional Flow Reserve in Patients With Stable Angina

W. Bob Meijboom, MD,*† Carlos A. G. Van Mieghem, MD,*† Niels van Pelt, MD,*†
Annick Weustink, MD,*† Francesca Pugliese, MD,*† Nico R. Mollet, MD, PHD,*†
Eric Boersma, PHD,* Eveline Regar, MD, PHD,* Robert J. van Geuns, MD, PHD,*†
Peter J. de Jaegere, MD, PHD,* Patrick W. Serruys, MD, PHD, FACC,*
Gabriel P. Krestin, MD, PHD,† Pim J. de Feyter, MD, PHD, FACC*†

Rotterdam, the Netherlands

Objectives We sought to determine the diagnostic accuracy of noninvasive visual (computed tomography coronary angiog-

La significación visual de las estenosis coronarias por: ACC, QCA, CTCA, QCT, no tiene una buena Correlación con la evaluación funcional por FFR. En lesiones intermedias es necesario FFR antes De decidir su revascularización

Conclusions The anatomical assessment of the hemodynamic significance of coronary stenoses determined by visual CTCA, CCA, or QCT or QCA does not correlate well with the functional assessment of FFR. Determining the hemodynamic significance of an angiographically intermediate stenosis remains relevant before referral for revascularization treatment. (J Am Coll Cardiol 2008;52:636–43) © 2008 by the American College of Cardiology Foundation

Reserva fraccional de flujo: FFR

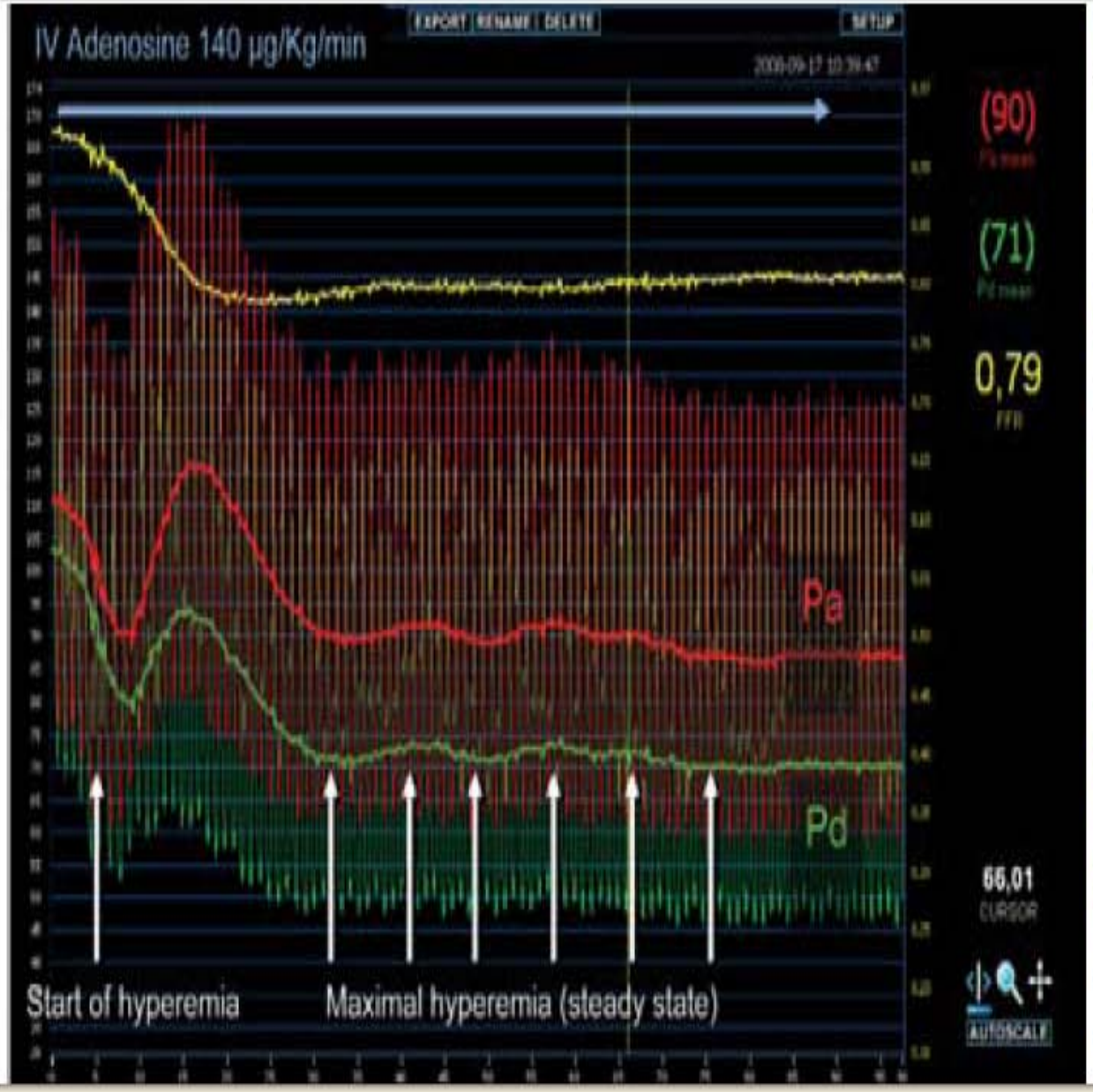

Figura 1: Registro de FFR. De izquierda a derecha se observa el gradiente de presión entre la línea roja (presión aórtica media) y la línea verde (presión distal media). Luego de la primera flecha (*start of hyperemia*) se observa un característico aumento en la presión sistémica en respuesta a la infusión de adenosina, al mismo tiempo comienza a aumentar el gradiente entre ambas presiones. La hiperemia alcanza luego una fase estacionaria a partir de la cual se calcula el FFR. En amarillo se observa el valor de FFR: el mínimo se expresa a la derecha (0,79).

CTCA y CCA - FFR

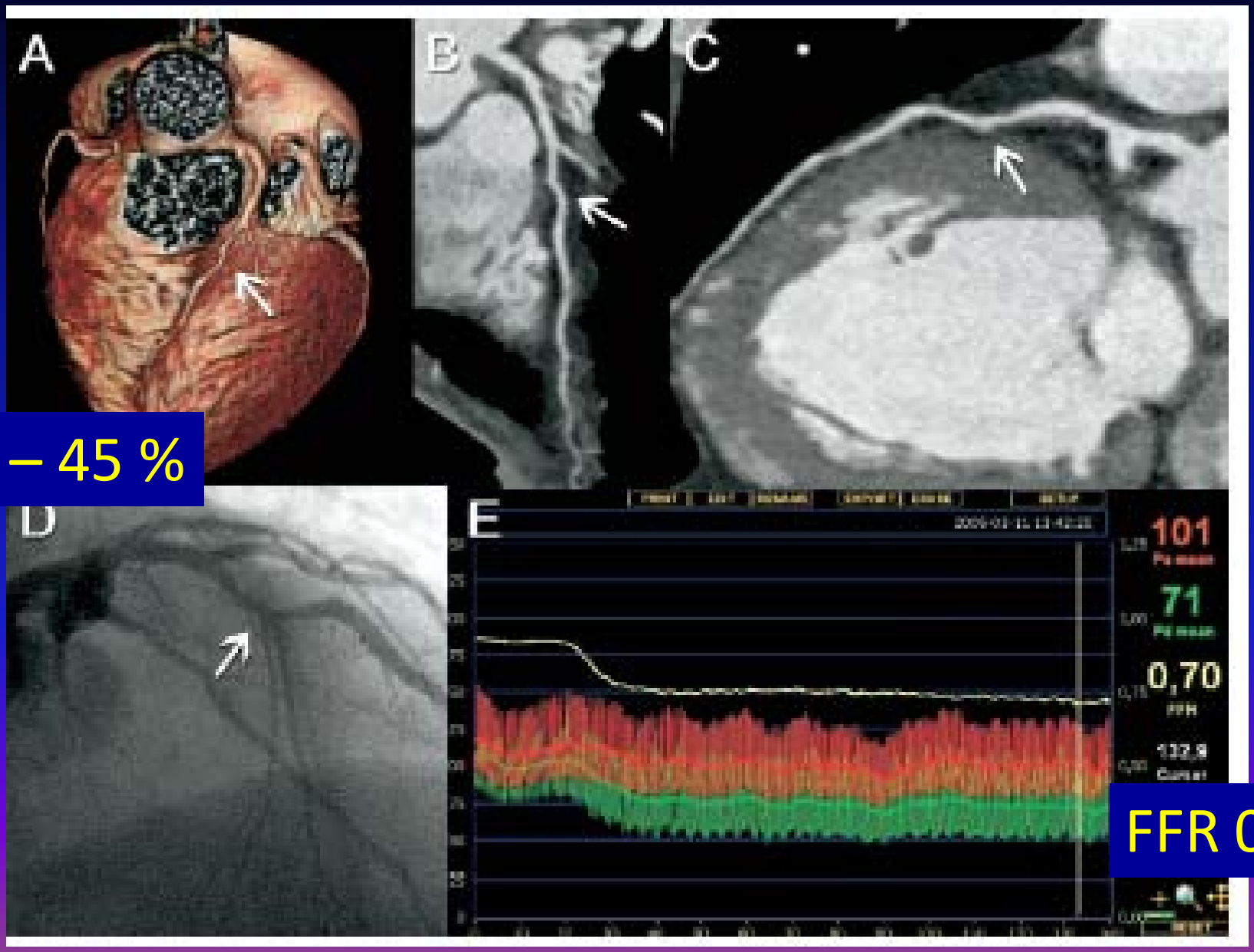

Lesión Significativa en ADA
Lesión intermedia en Circ.

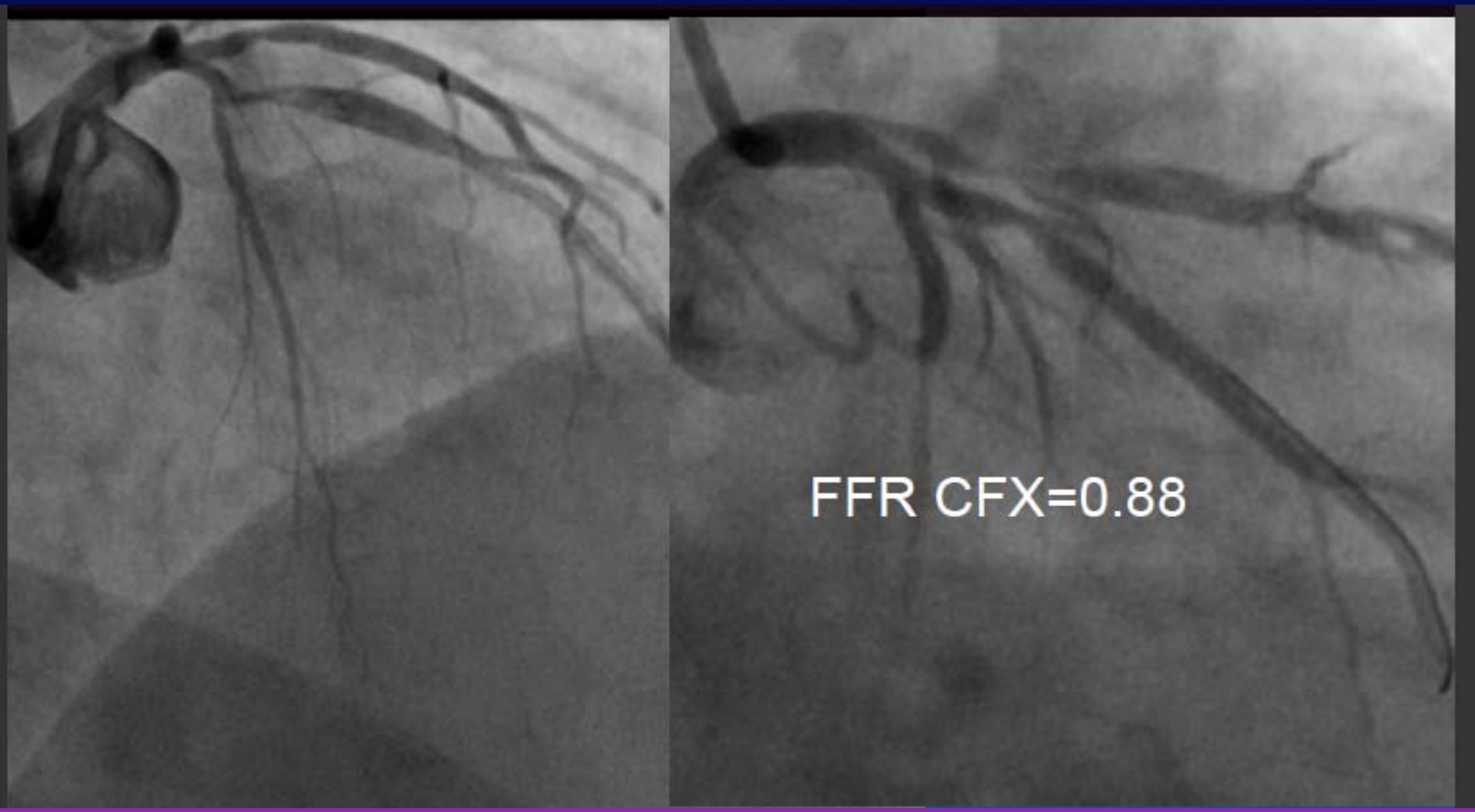

Stent solo en ADA

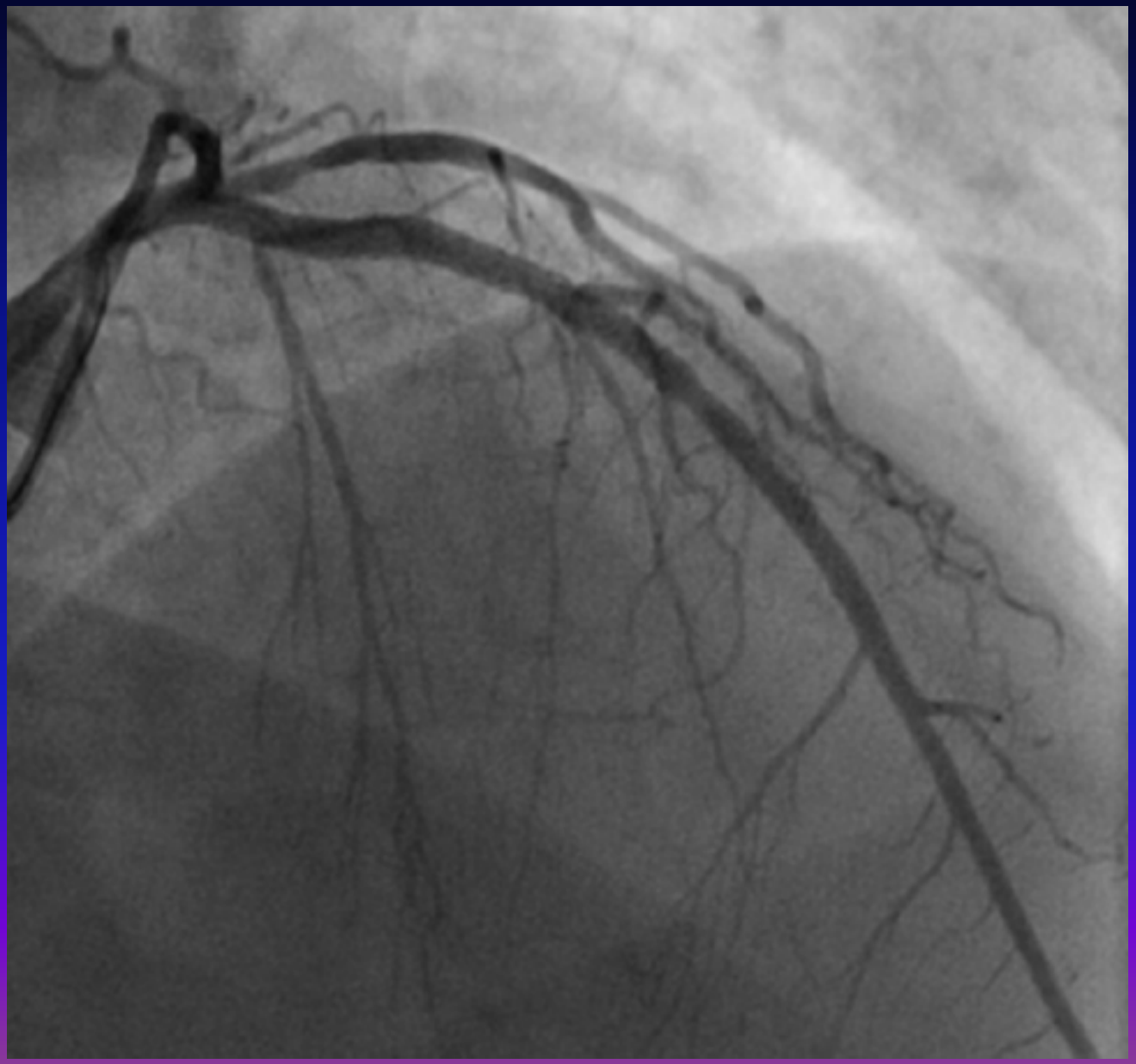

Varón, 58ª, dolor precordial atípico
Dislipidemia

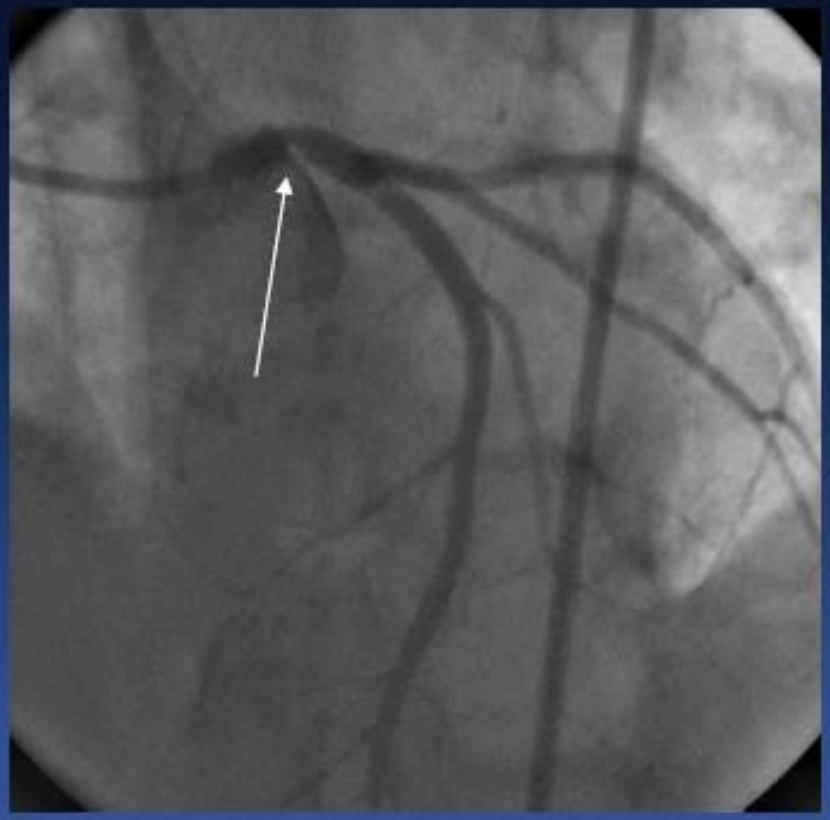

Visual Estimation 85%

IVUS

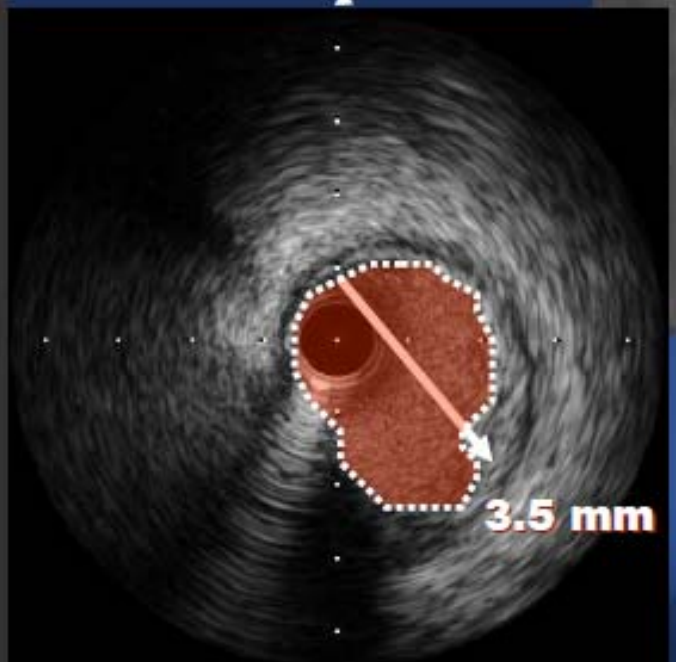

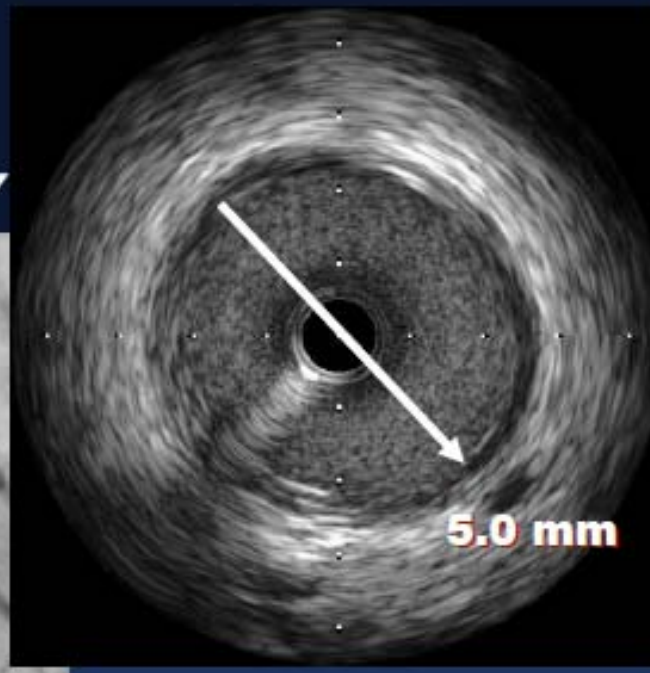

Negative remodeling
MLA : 5.2 mm²

UNIVERSITY OF ULSAN COLLEGE MEDICINE
ASAN Medical Center

FFR

Continuous Intravenous Infusion 180 μg/kg/min

Visual - Functional Mismatch

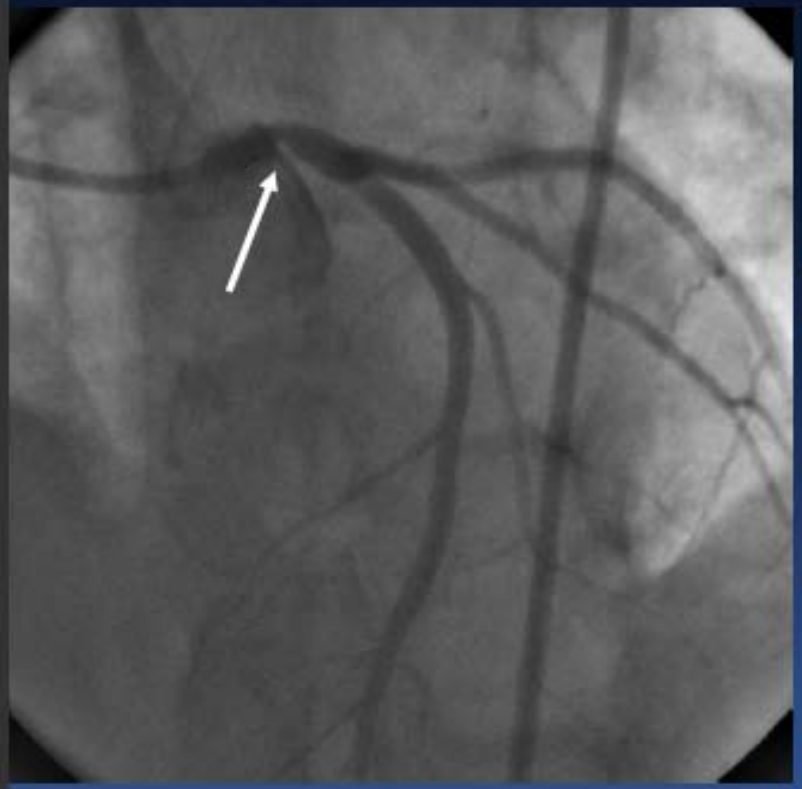

Angiographic DS(%) : 85%

IVUS MLA : 5.2 mm^2

FFR : 0.82

Treadmill test : Negative

Thallium spect : Normal

Stress Echo : Normal

FFR is matched with non-invasive stress test !

Reverse Mismatch

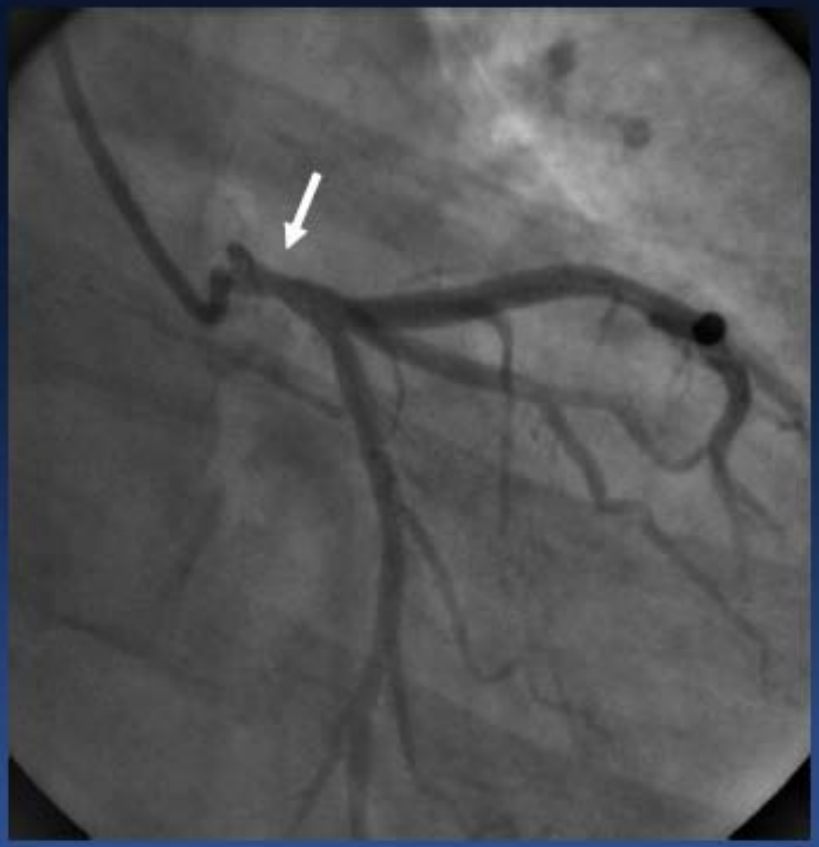

Visual Estimation
30%

IVUS MLA: 4.5 mm^2
FFR : 0.70
Treadmill test: + stage 3
Thallium spect : + large LAD

FFR is constantly matched
with non-invasive stress test again !

CardioVascular Research Foundation
UNIVERSITY OF ULSAN COLLEGE MEDICINE
ASAN Medical Center

Accurate Diagnosis

1. Consider FFR if angiographic DS <80% (visual estimation).
2. New IVUS MLA cut-off value (<4.5 mm^2) can predict FFR<0.80.

euro PCR

"MVD": what's in a name?

FAME

- 67-year-old male
- Chest pain suggestive for angina
- Normal Resting ECG

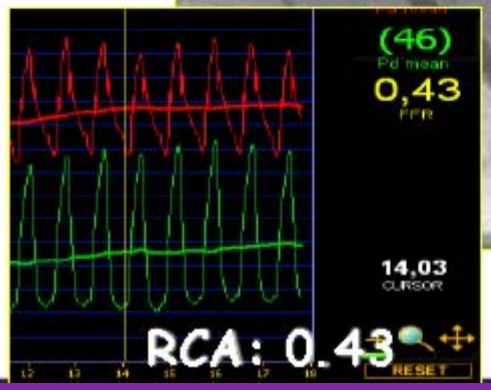

RCA: 0.43

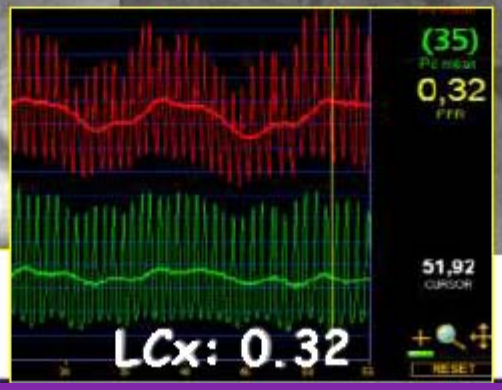

LCx: 0.32

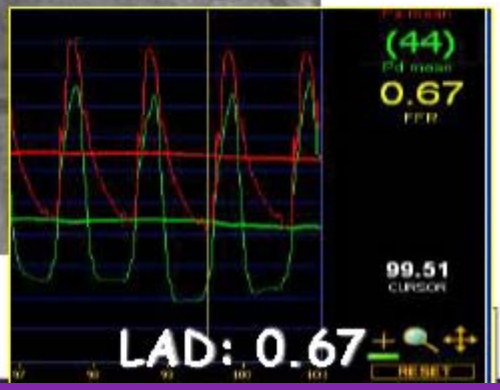

LAD: 0.67

FAME Study: Results

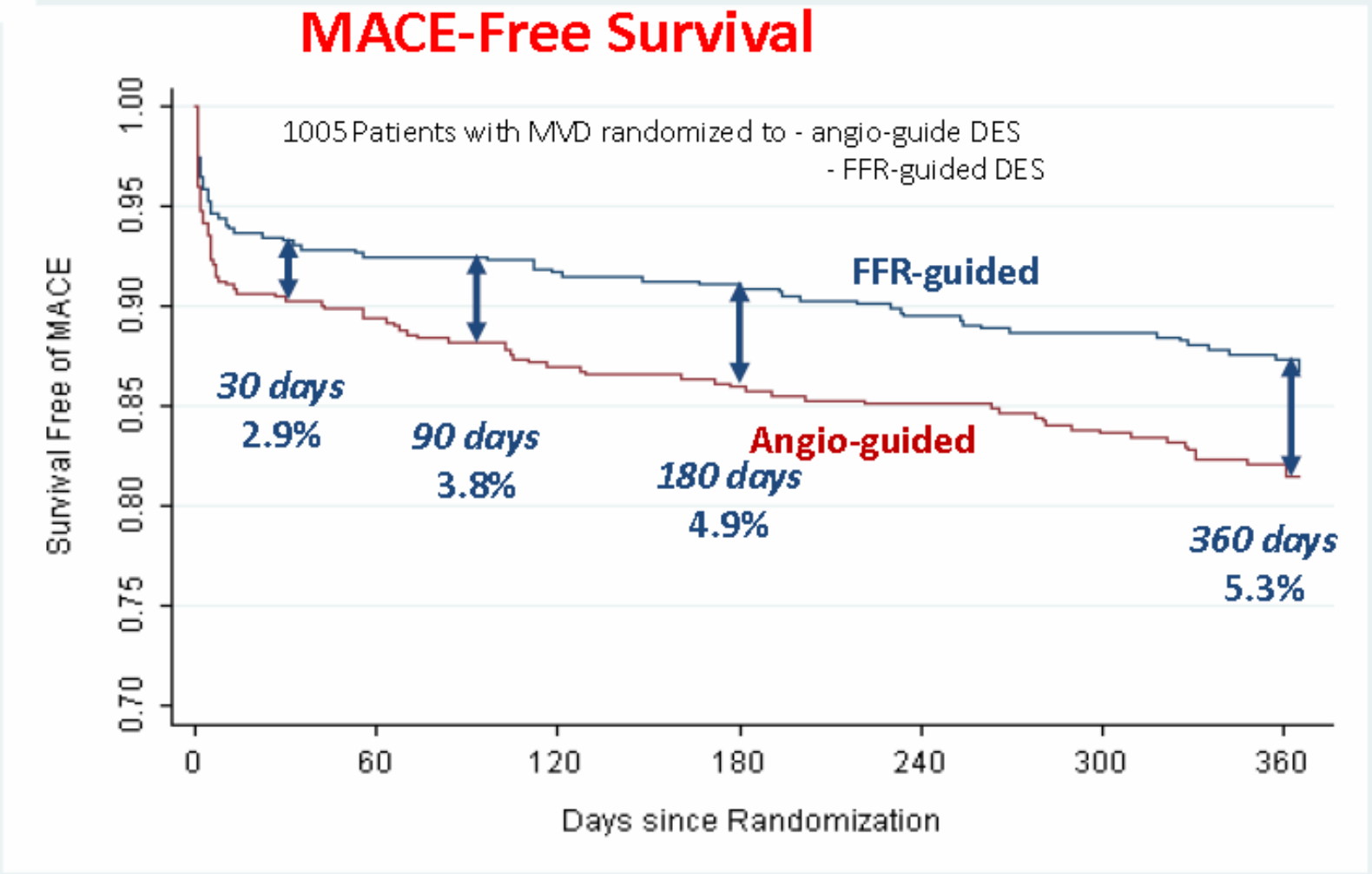

Tonino et al NEJM 2009

Angiography versus FFR in the FAME study (509 pts 1414 lesions)

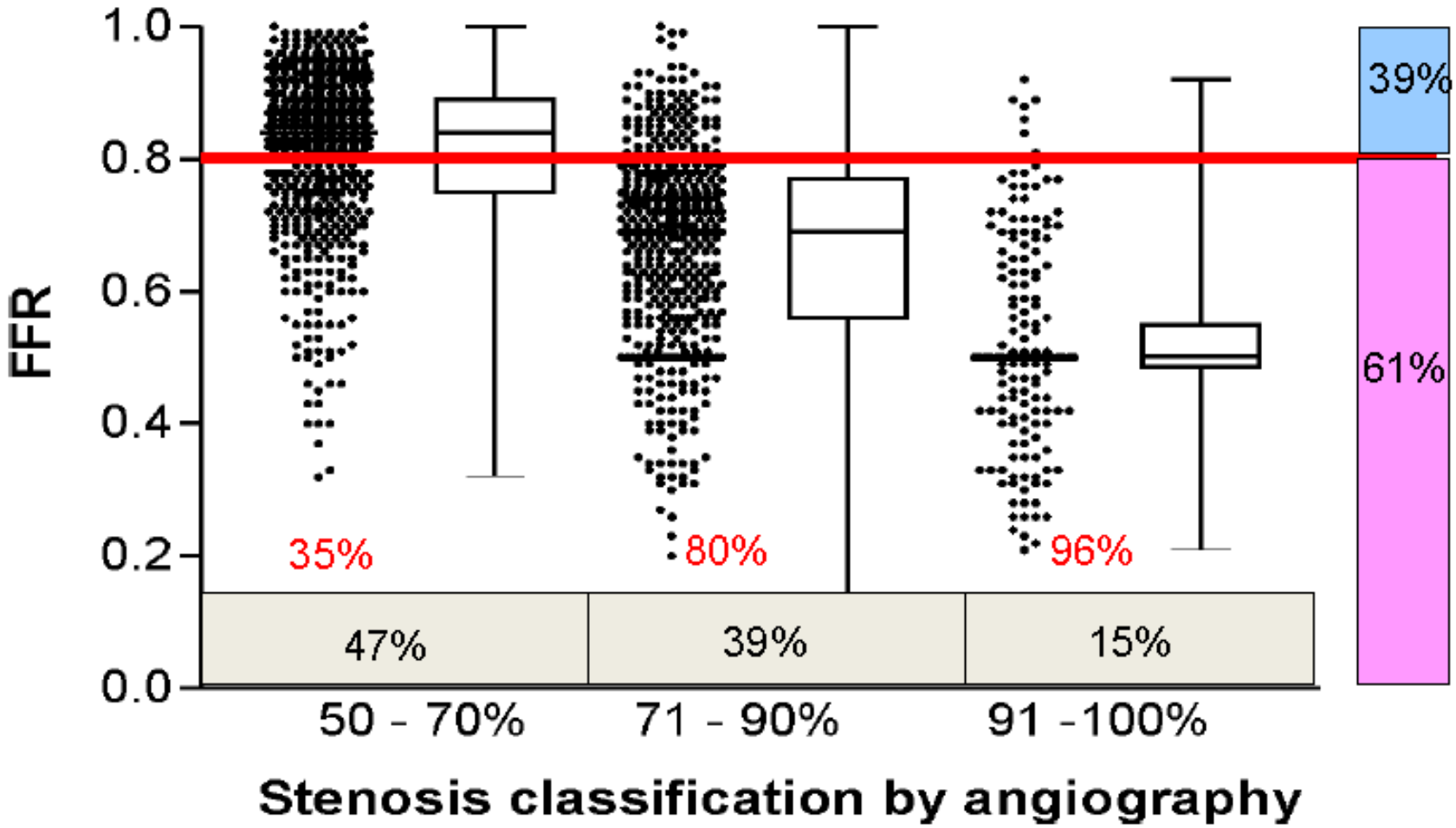

P. Tonino et al JACC 2010, in Press

FAME : Stent Diferido

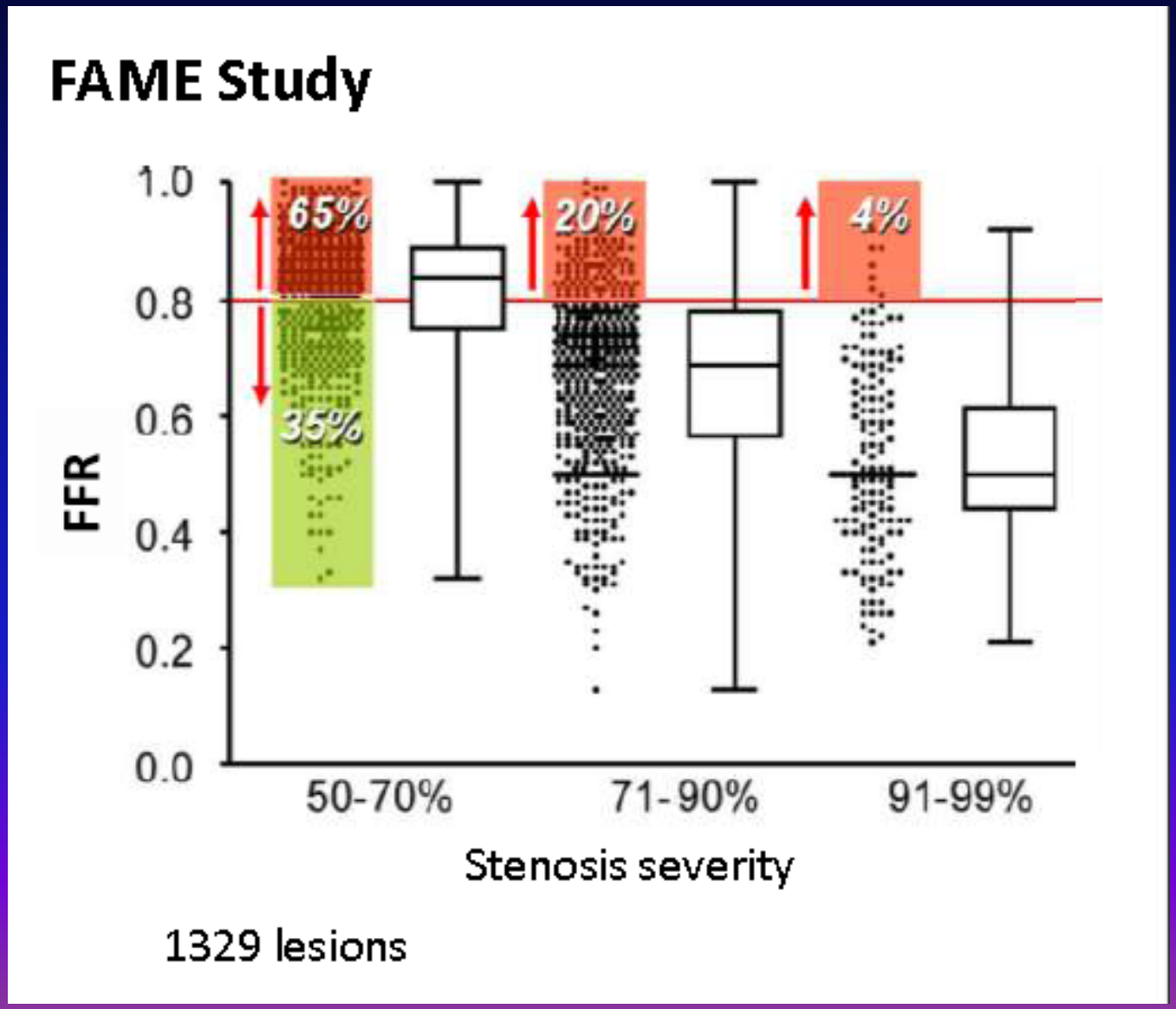

CONCLUSIONES
Tratar o no Tratar la Lesión

- Criterio Anat. Lesión Sig. (Angio, IVUS,MSCT) no implica la presencia de Isquemia.
- Evaluación de Isq. Por métodos no invasivos es un mejor parámetro, aunque tiene un valor predictivo bajo en Lesiones de 3 V.
- Decisiones de Trat. Para un paciente y para una lesión basados en FFR están asociados con una excelente evolución clínica.
- IVUS tiene un rol en la decisión de Trat , pero sobre todo en la optimización del Trat. Con stent

Muchas Gracias

Functionally Significant Ostial and Shaft LM lesions

Just Stent it !

- It takes just 5 minutes !
- We have more than 5 -10 year long-term data.
- No difference of death and MI compared with surgery (even better). Long-term clinical outcomes should be comparable to 100% of arterial revascularization.

Treatment for LM Bifurcation

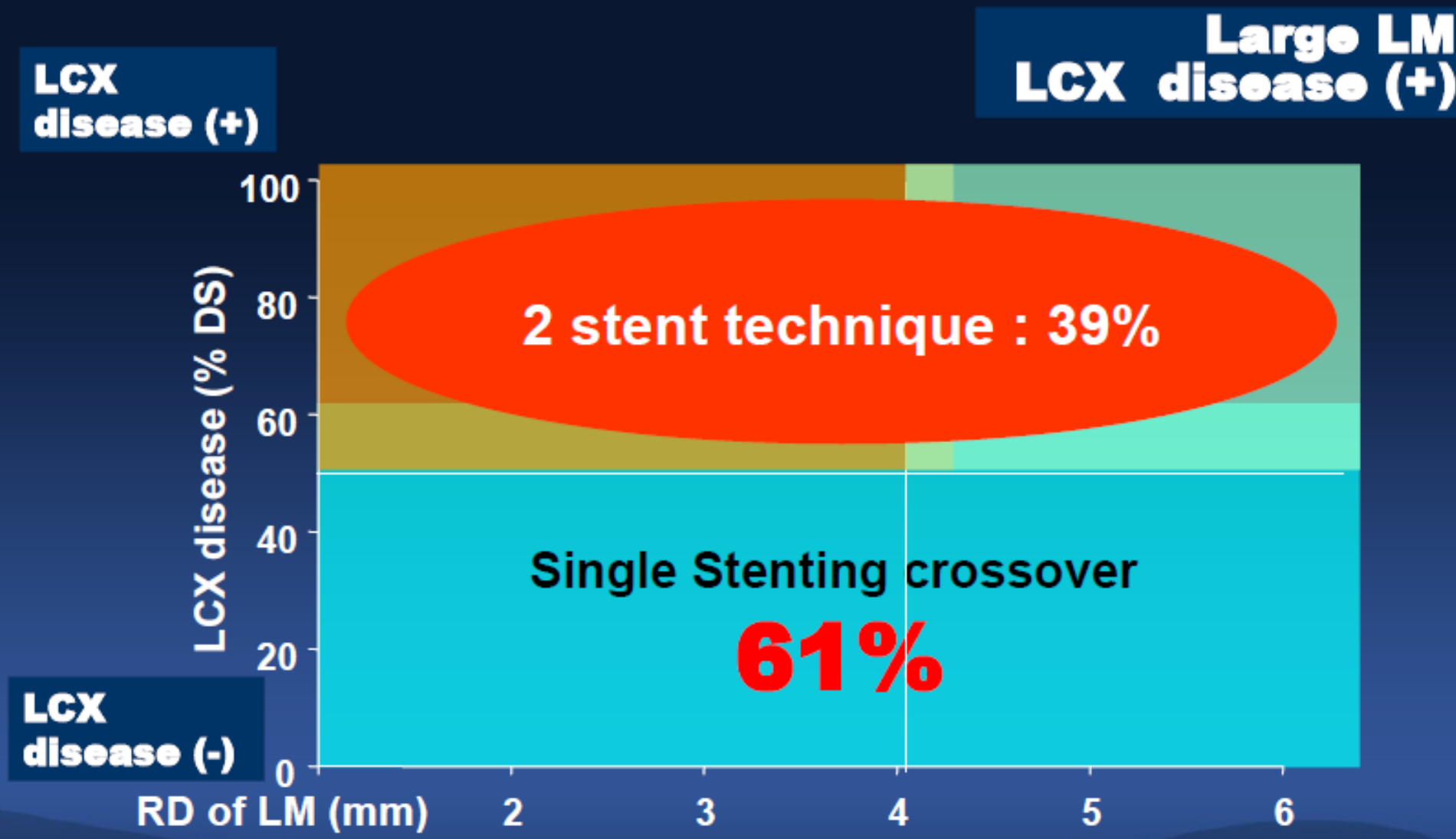

Data from MAIN COMPARE Registry

TLR at 4 year

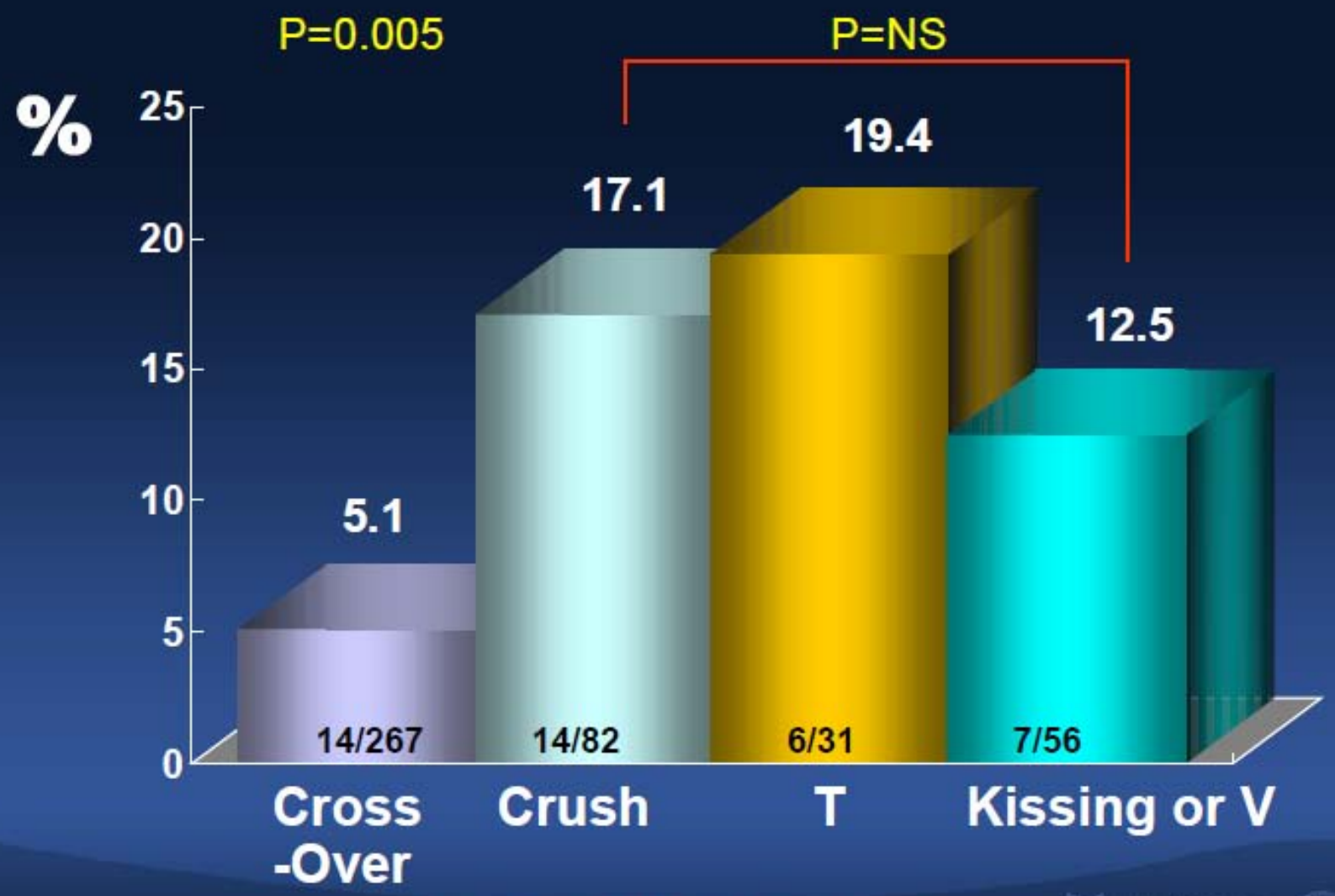

Data from MAIN COMPARE Registry

Single Stent Cross-Over

IVUS Guided Stent Cross over depending on LCX disease status by IVUS, stent size selection, stent optimization.

FFR Guided decision making for further treatment about the side branch compromise.

Causas de error en FFR

Pitfalls técnicos	Error de calibración *Damping* de presión Posición inestable de guía de presión
No se logra hiperemia	Dosis Vía de administración
Alteración microcirculatoria reversible	Sindrome Coronario Agudo Embolización
Estenosis con geometría variable	Trompo Vasoespasmo
Estenosis distal al sensor	Estenosis focal Estenosis difusa
Bypass distal al sensor	
Pseudoestenosis por rectificación de segmento tortuoso	
Puente miocárdico	

euro PCR

Unprotected left main disease: is it prime time for percutaneous coronary intervention?

Excel trial: rationale, design, endpoints and timelines

Patrick W. Serruys MD PhD

11:40-11:50, May 26
Main Arena

Patient inclusion criteria

- **Unprotected LM disease with DS ≥70% (visually estimated)**
- **Unprotected LM disease with angiographic DS ≥50% but <70% (visually estimated), *with one or more of the three conditions present:***
  - **Non-invasive evidence of ischemia *and/or***
  - **IVUS MLA ≤6.0 mm^2, *and/or***
  - **FFR ≤0.80**

•Stress-induced hypotension or transient LV dilatation, or fall in LVEF
•Scintigraphic lung uptake

- **Clinical and anatomic eligibility for both PCI and CABG as agreed to by both interventional and surgical consensus (Heart Team Conference).**
- **Silent ischemia, stable angina, unstable angina or recent MI**

Heyndrickx Functional evaluation.pdf (SECURED) - Adobe Reader
File Edit View Document Tools Window Help
29 / 38 79% Find

euro PCR

FAME Study

Objectives

To compare, in patients with MVD, two revascularisation strategies:

- *strategy based on angiography* only
- *strategy based on angiography + FFR*

-Stent only flow-limiting stenoses, which are able to induce ischemia (FFR ≤ 0.80)

-Defer all non-flow-limiting stenoses, which do not induce ischemia (FFR > 0.80)

Tonino et al NEJM 2009

PCR EAPCI