



**FUNDACIÓN
FAVALORO**
HOSPITAL UNIVERSITARIO

Transcatheter Aortic Valve Replacement (TAVR)

Oscar A. Mendiz.MD.FACC.FSCAI
Jefe Cardiología Intervencionista
Presidente SOLACI

Febrero 2012

Disclosure


Speaker: O Mendiz MD.

Proctor CoreValve Medtronic

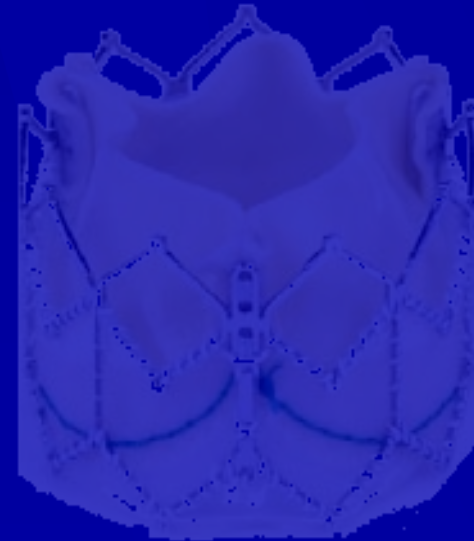

Percutaneous Aortic Valve Replacement

CoreValve



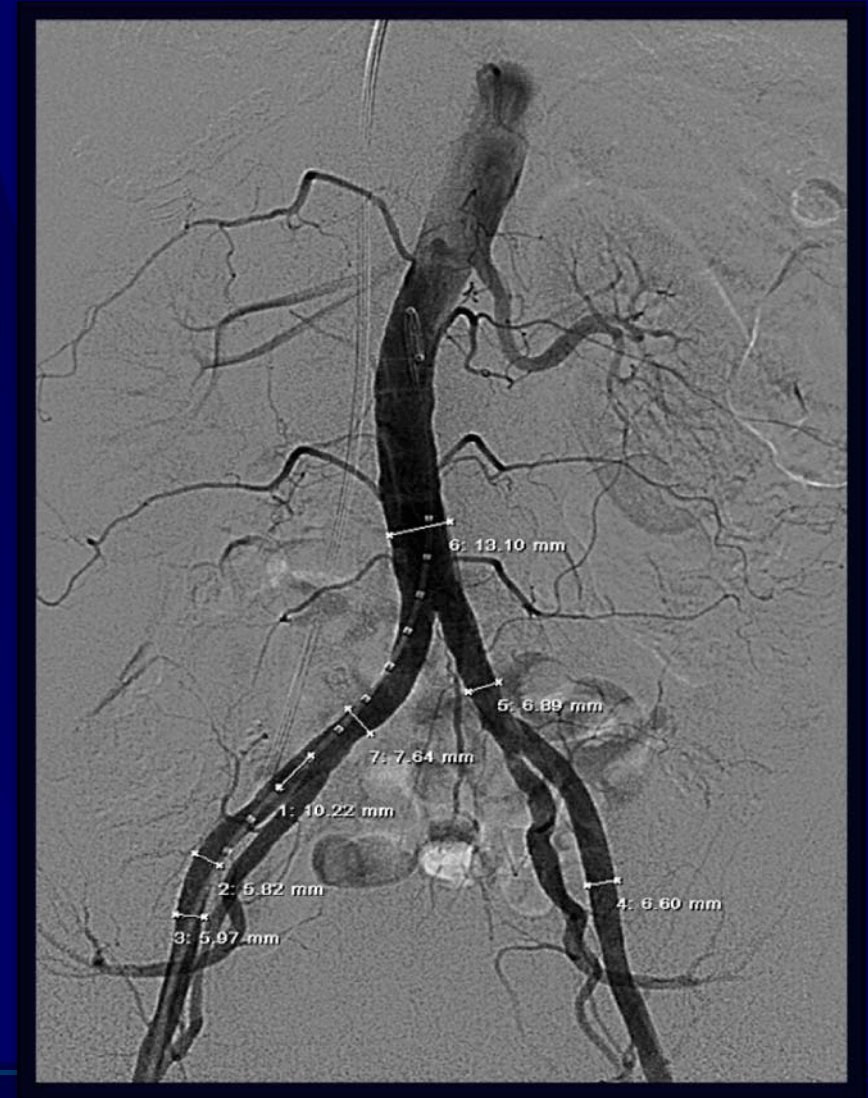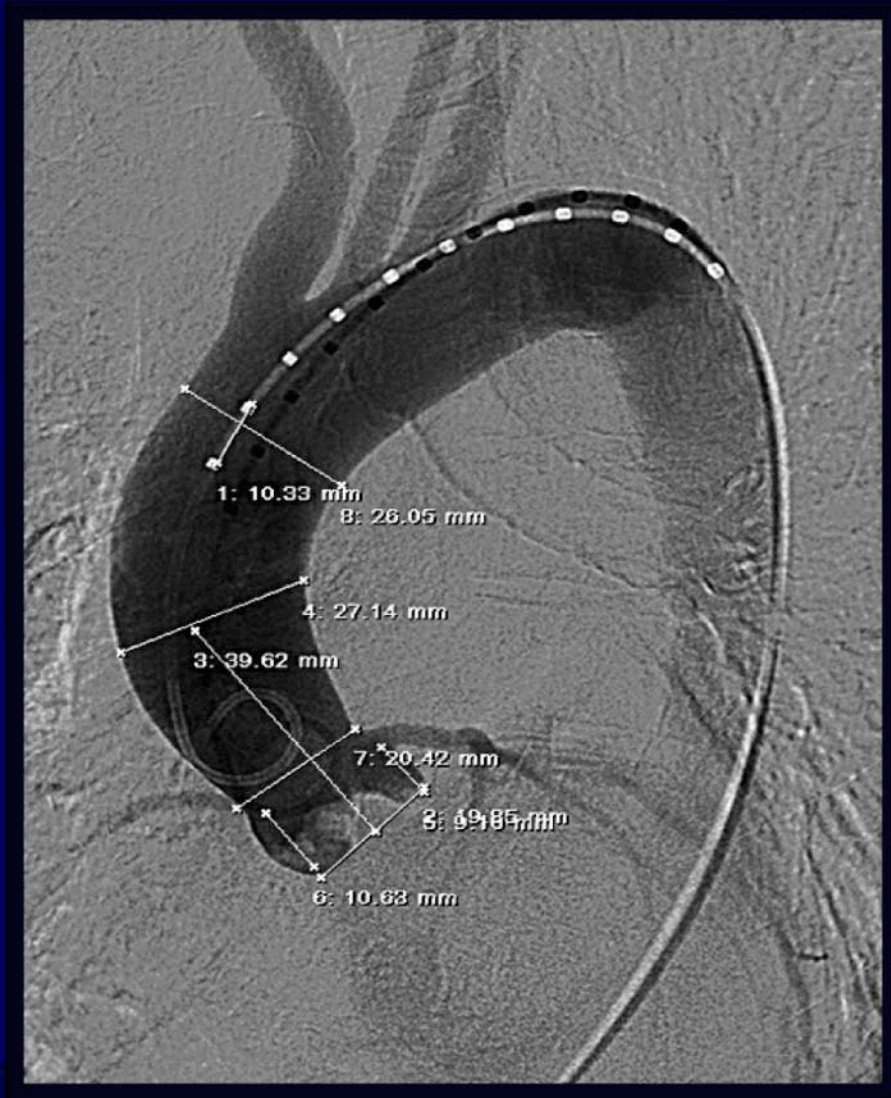
Edwards-SAPIEN



Algorithm for Patient Selection @ Favaloro Foundation

- First:
 - Transthoracic Echo for Diagnosis
- Second:
 - Catheterization
 - Coronary Angiography (CAD should be previously treated)
 - Thoracic Aortogram (marked pigtail)
 - Abdominal Aortogram (marked pigtail)
- Third:
 - Multislice CT (thoracic and abdominal aorta)
- Finally:
 - TEE: Focus in all needed measurements (advised operator)

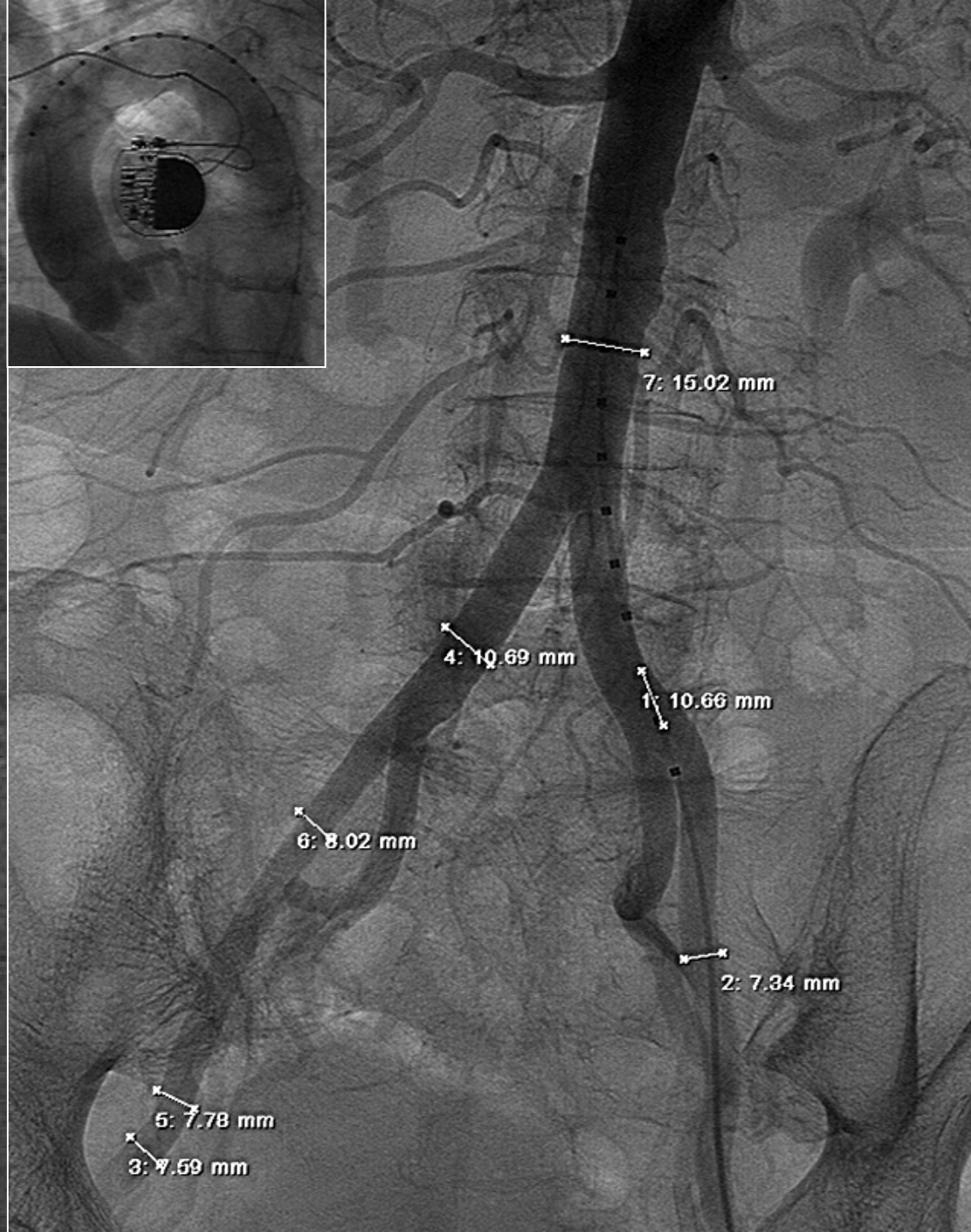
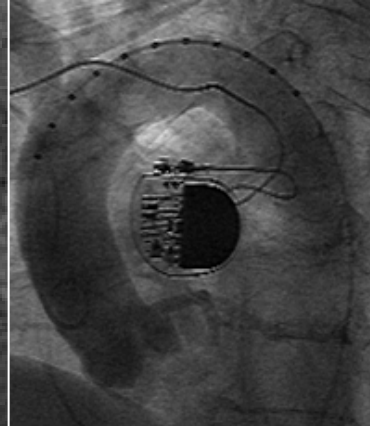
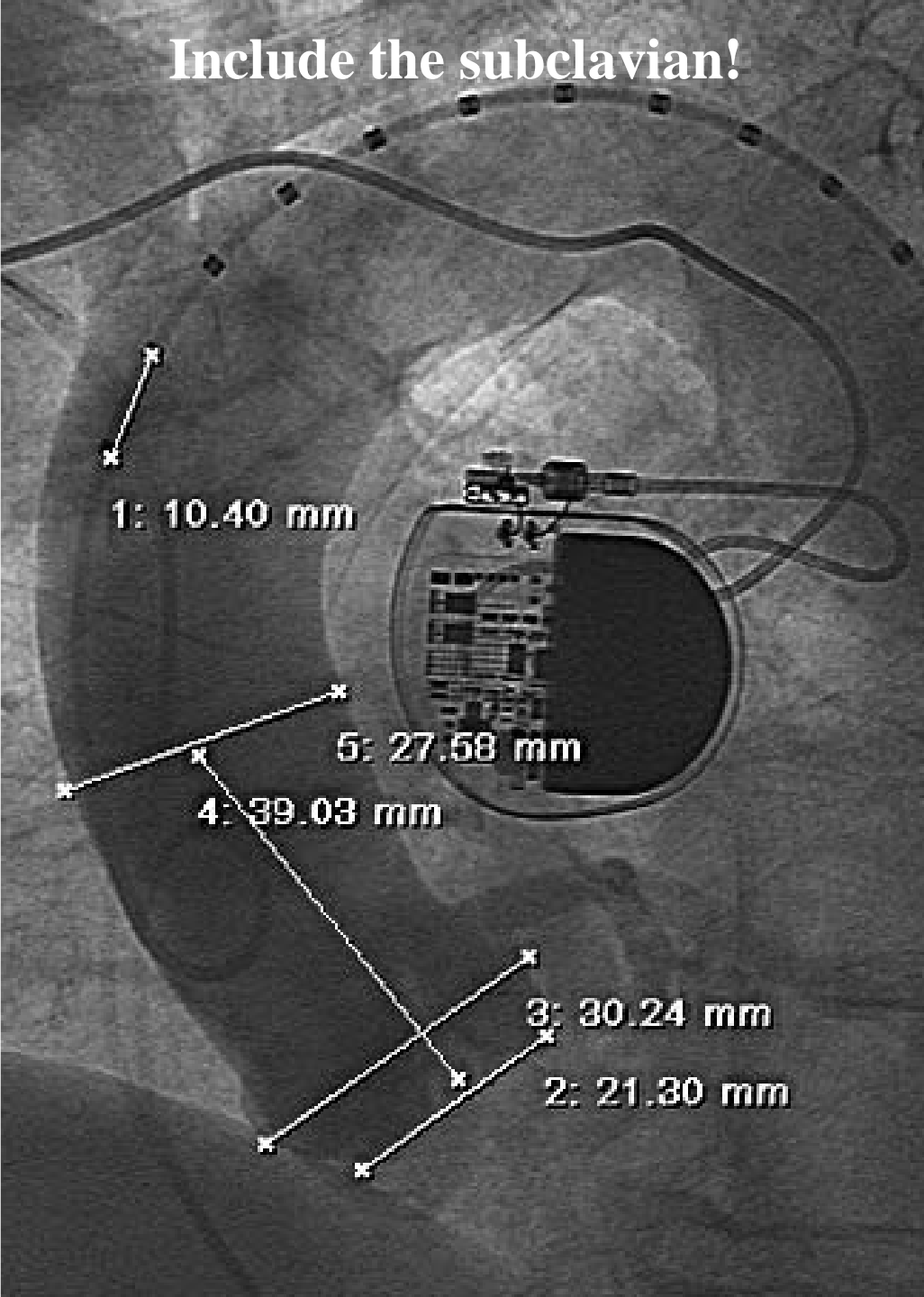
Screening Mistakes: Angiographic Evaluation

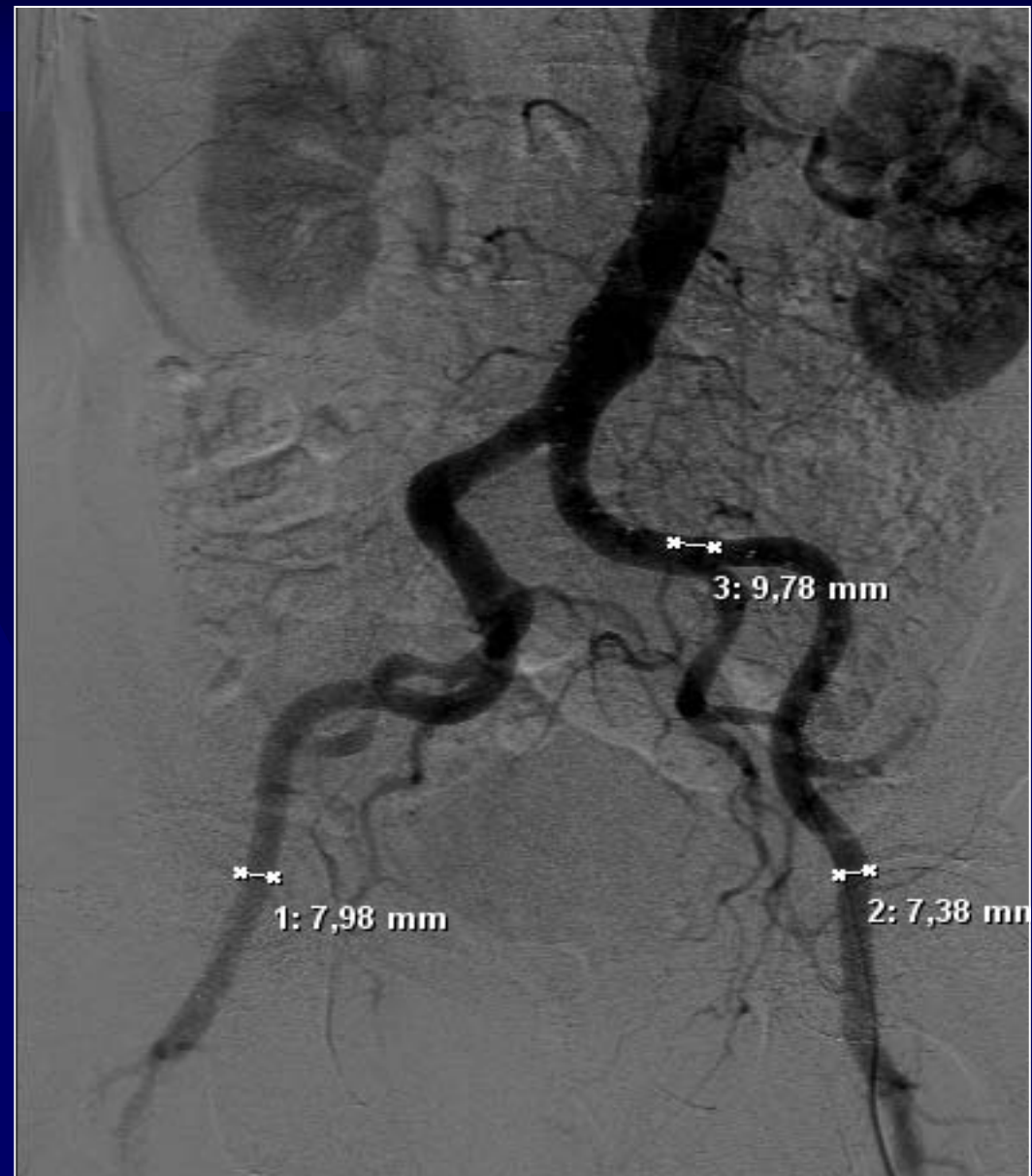
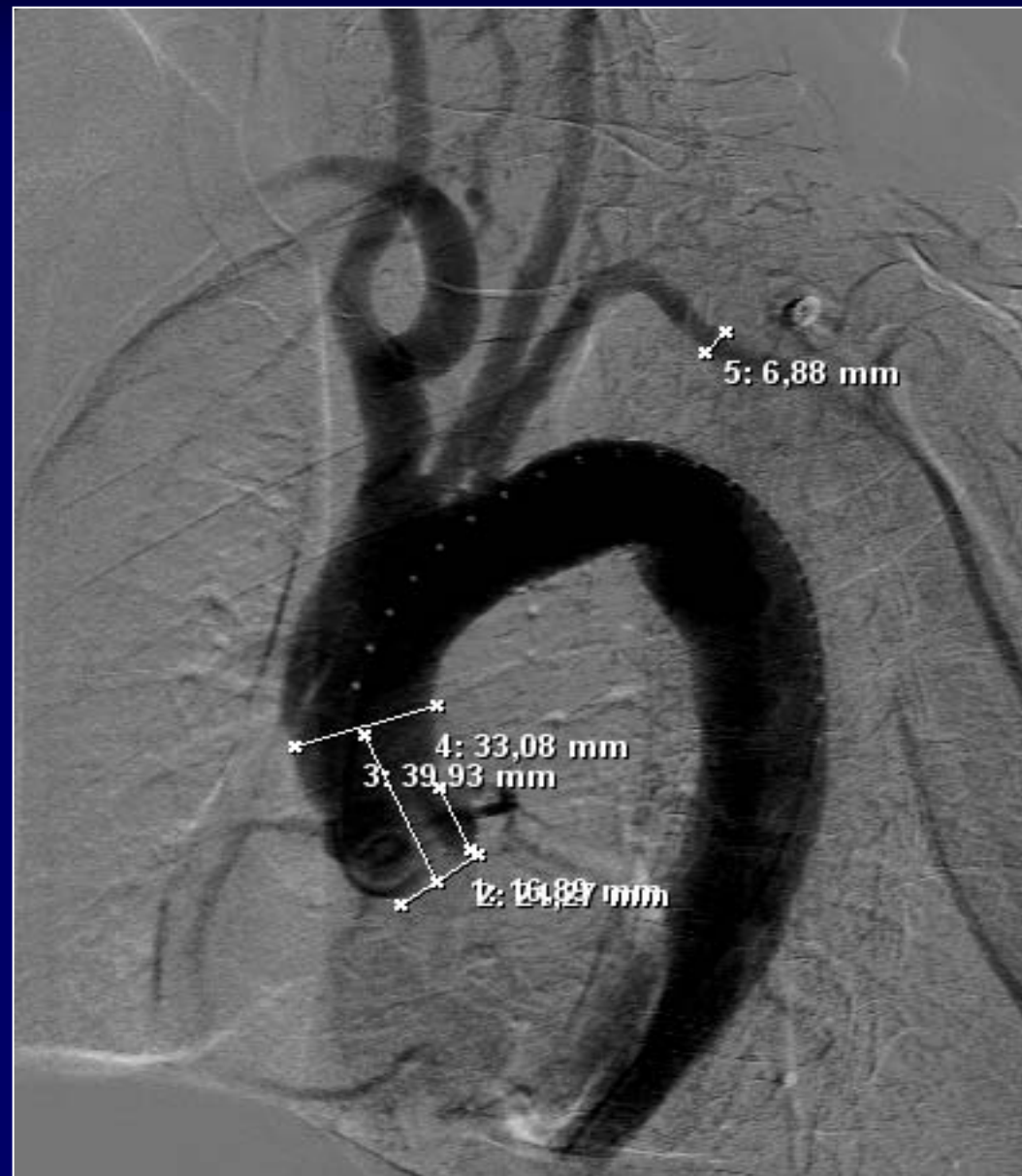
Algorithm for Patient Selection @ Favaloro Foundation

- Finding at the angio:
 - Hemodynamic evaluation (PAP, gradient, area, asociated valvulopatya, test of the overload volume in case of low gradient)
 - Coronary Disease (amenable for PCI)
 - Thoracic Aortogram (marked pigtail).
 - Annulus measurement
 - Sinus height
 - Sinotubular aortic measure.
 - Left Subclavian evaluation
 - Abdominal Aortogram (marked pigtail)
 - Tortuosity, calcium
 - External iliac artery lesion

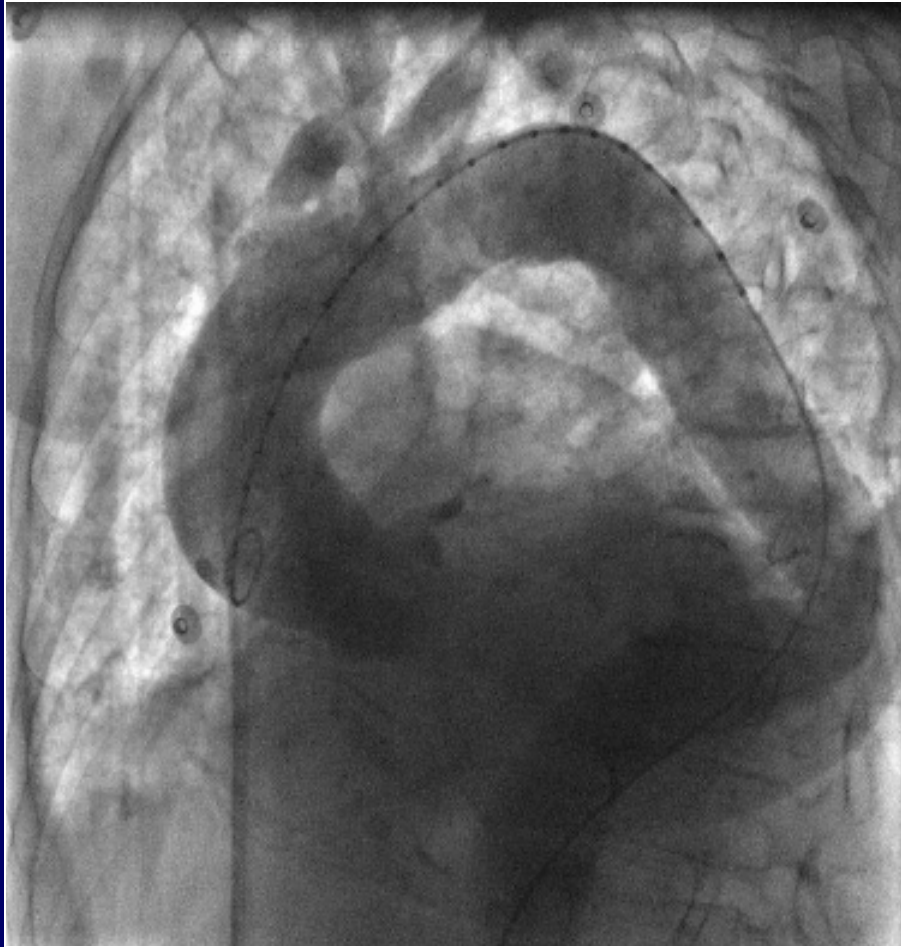Include the subclavian!



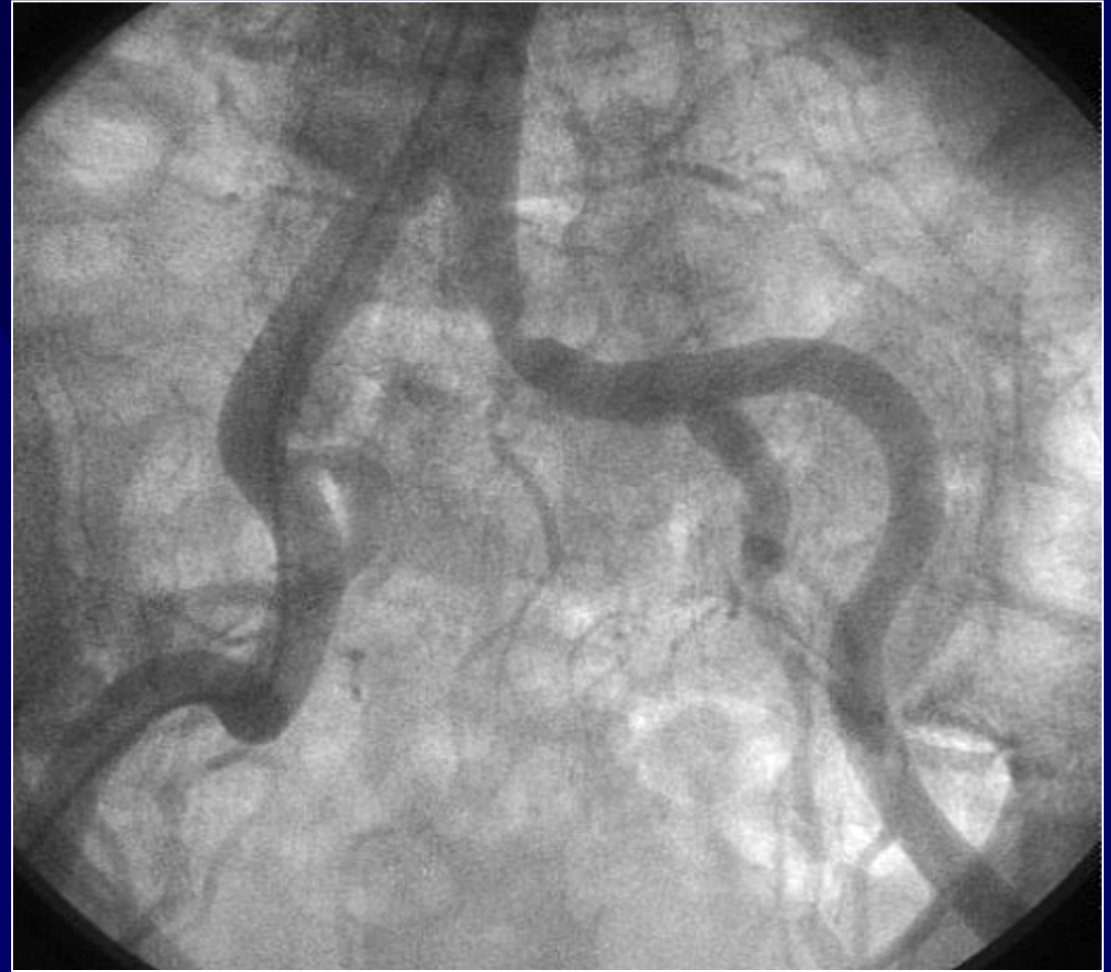

TAVR @ Favaloro Foundation

Pte Selection:



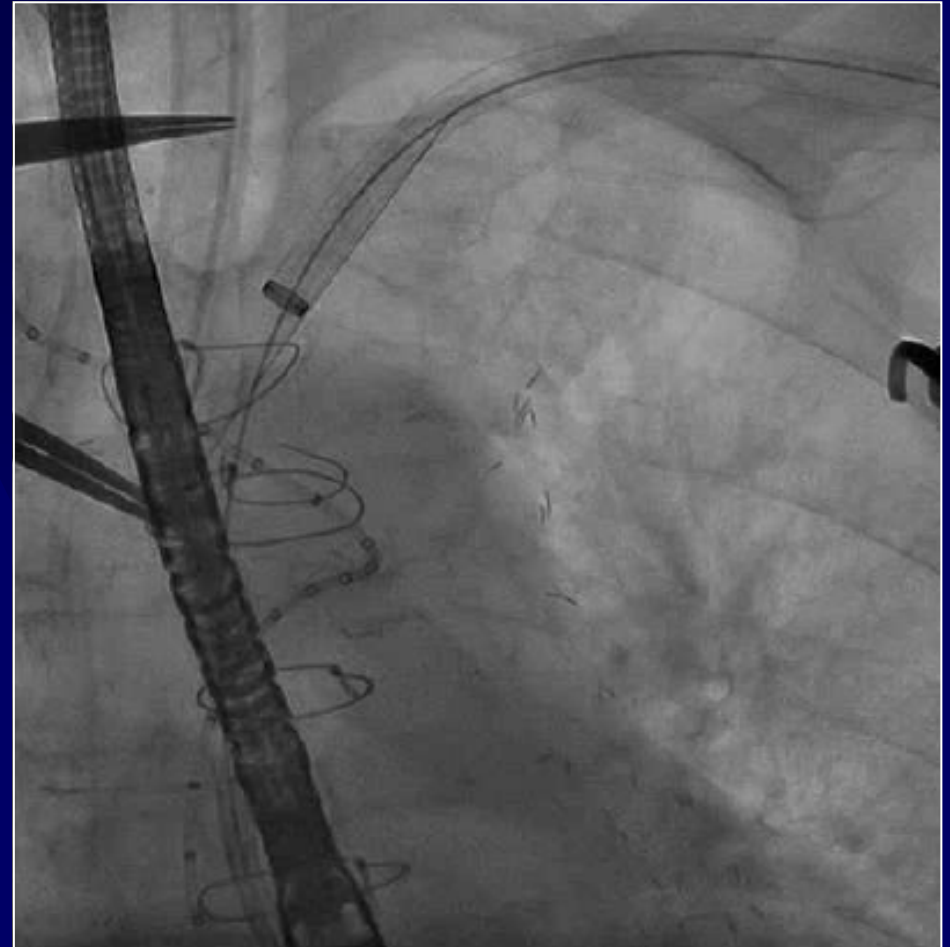
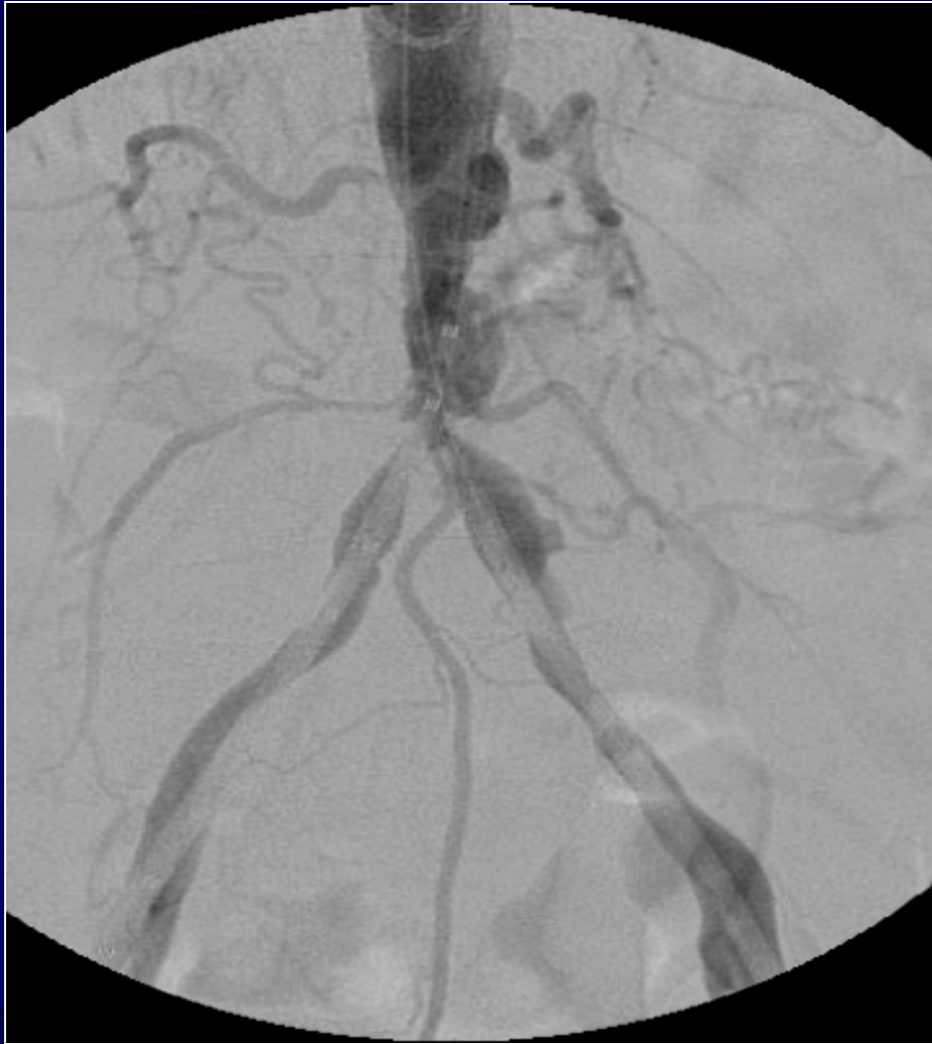Avoid this tortuous anatomy

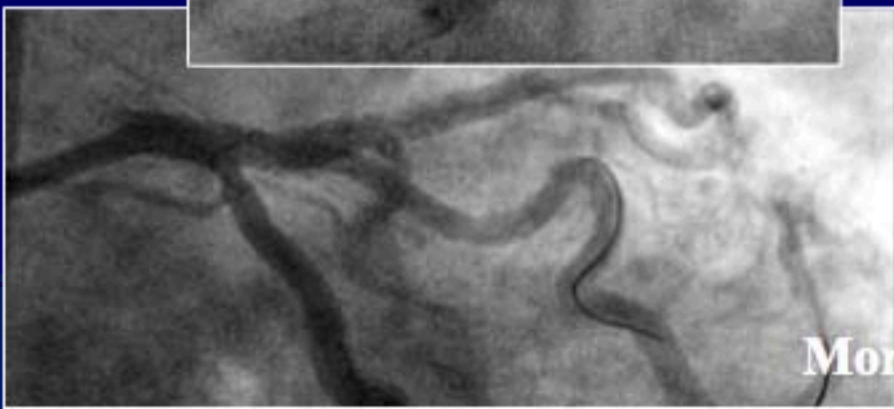
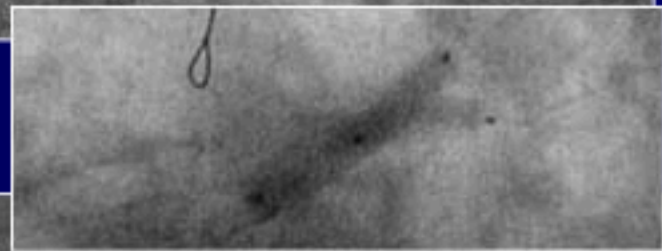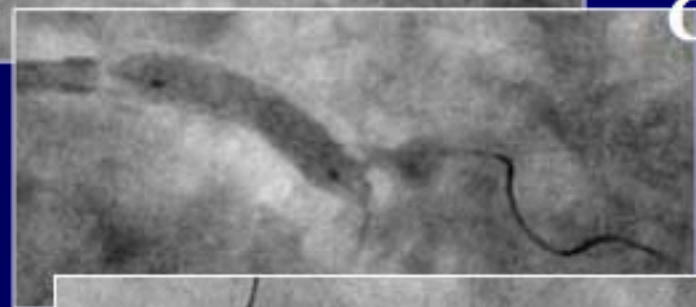
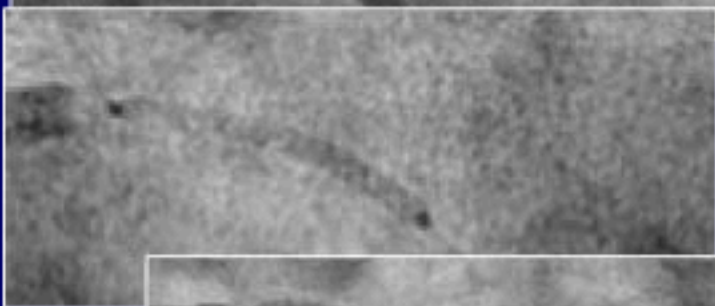

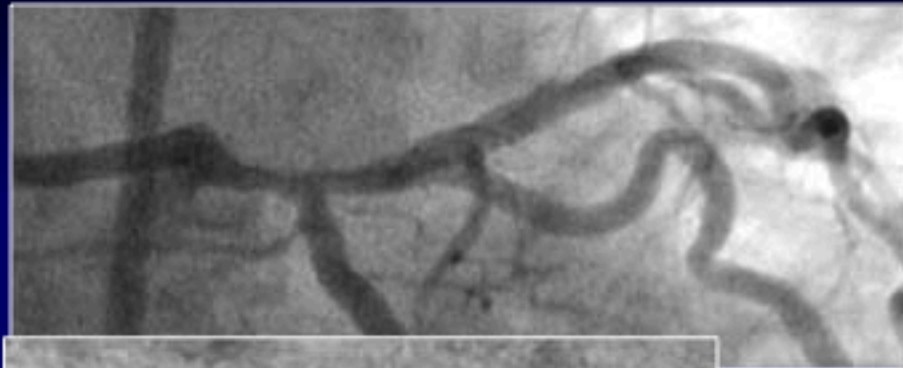
Consider another access

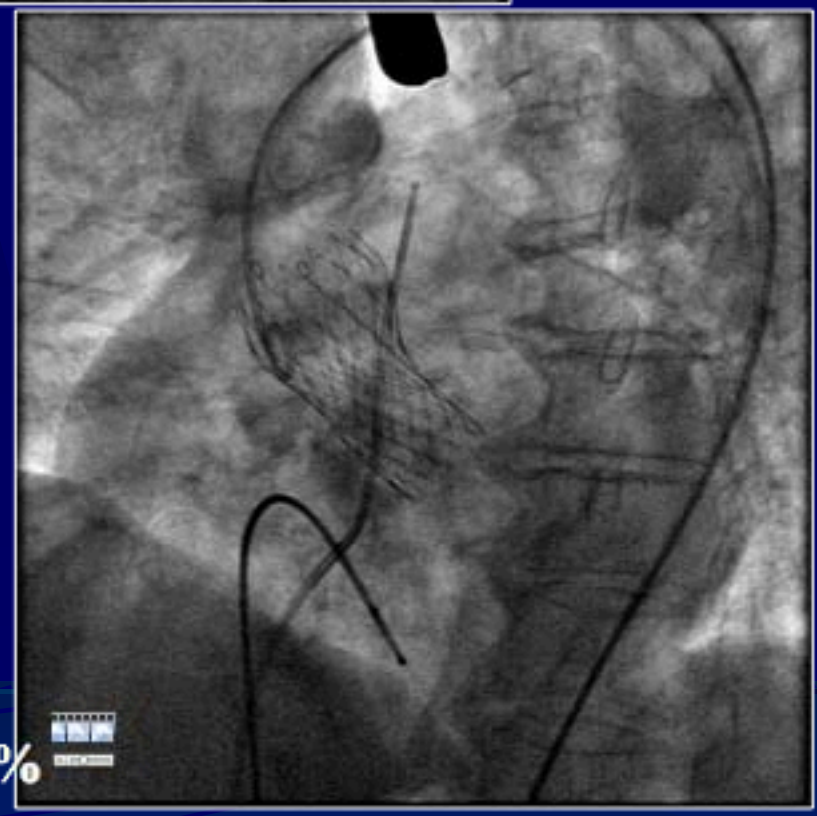
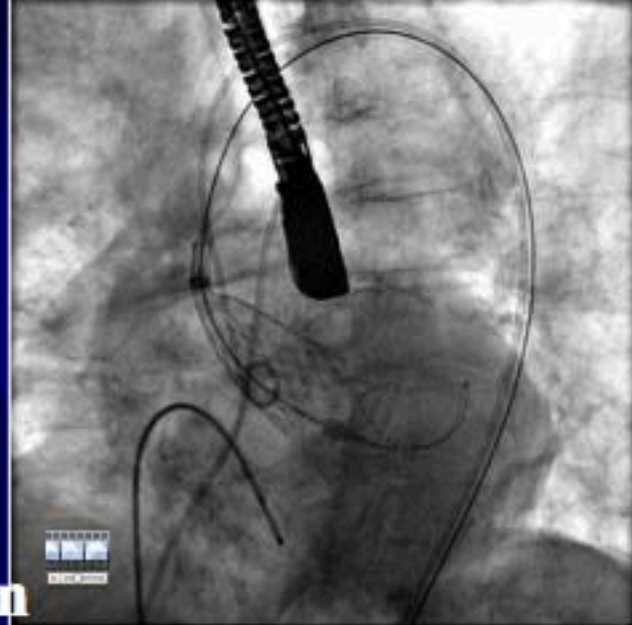
TAVR @ Favaloro Foundation

Pte Selection





CASE 7
First: LM PTCA
Chest Radiation



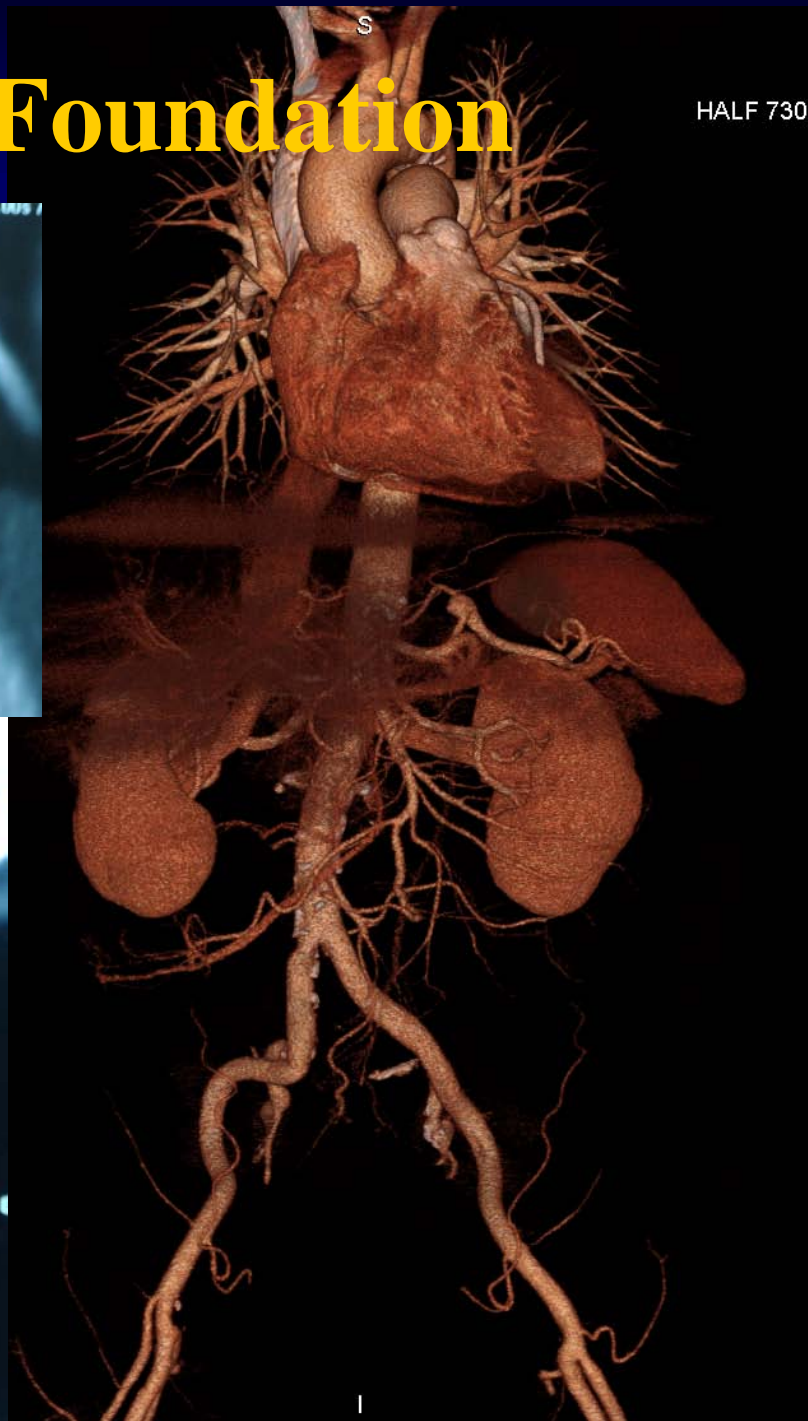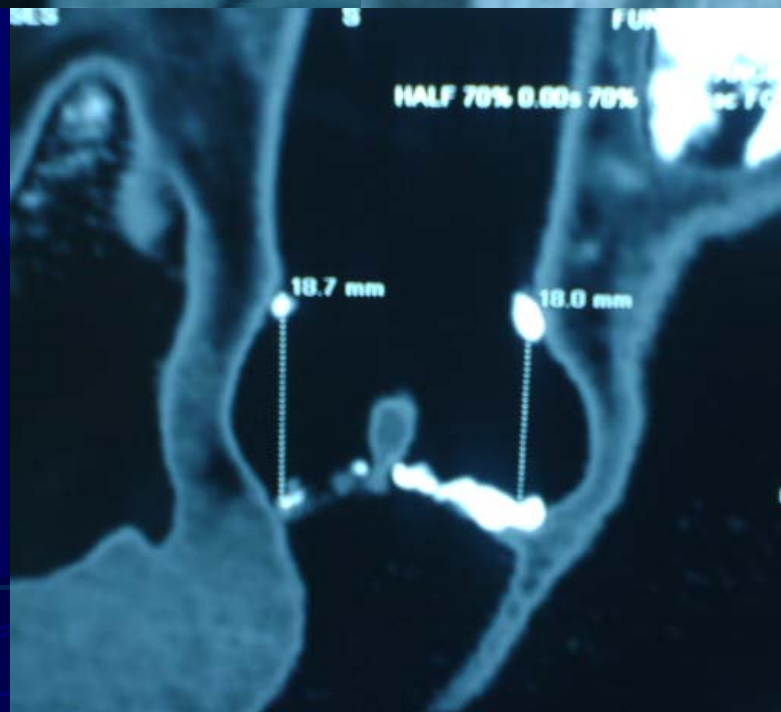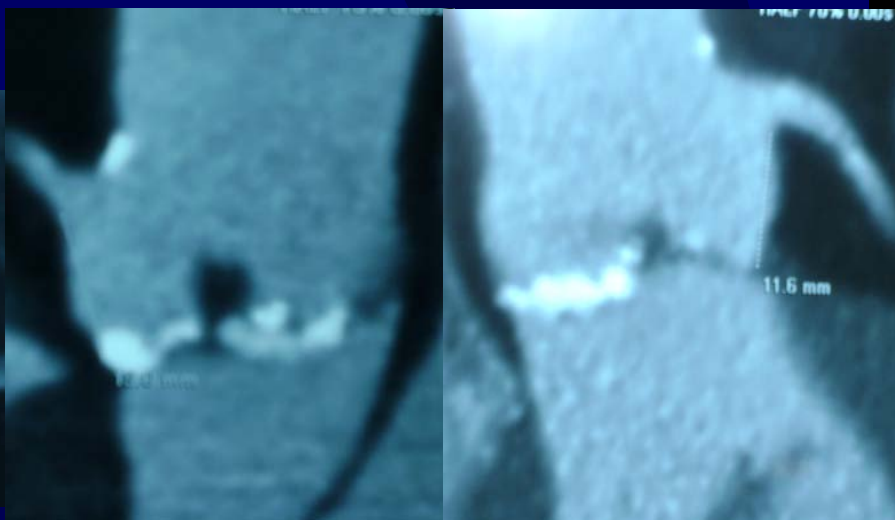
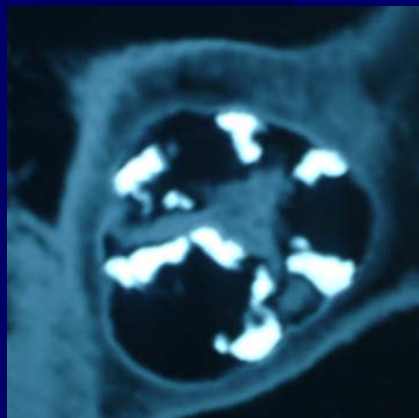
CONAREC XVI
Mort RVAo+CRM 13.9%

Algorithm for Patient Selection @ Favaloro Foundation

- First:
 - Transthoracic Echo for Diagnosis
- Second:
 - Catheterization
 - Coronary Angiography (CAD should be previously treated)
 - Thoracic Aortogram (marked pigtail)
 - Abdominal Aortogram (marked pigtail)
- Third:
 - Multislice CT (thoracic and abdominal aorta)
- Finally:
 - TEE: Focus in all needed measurements (advised operator)

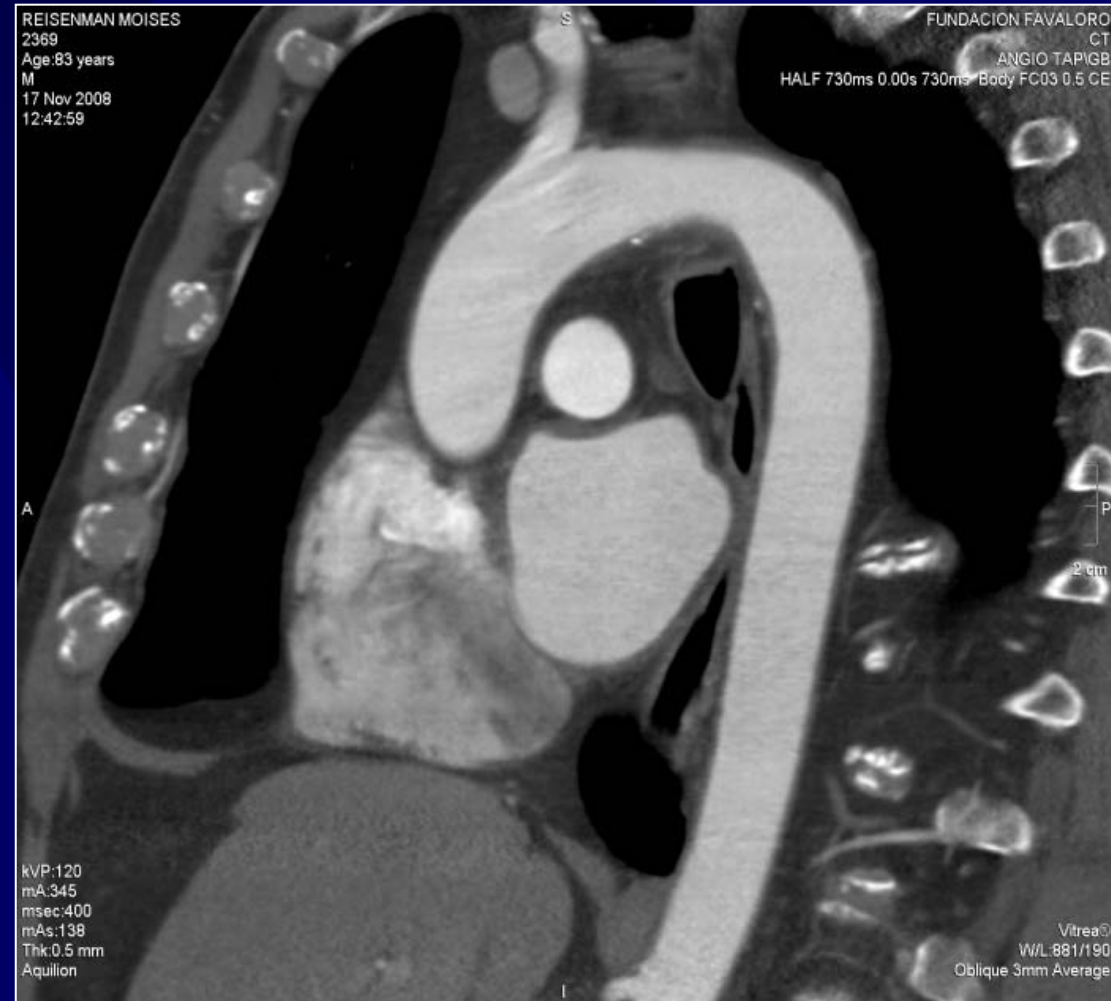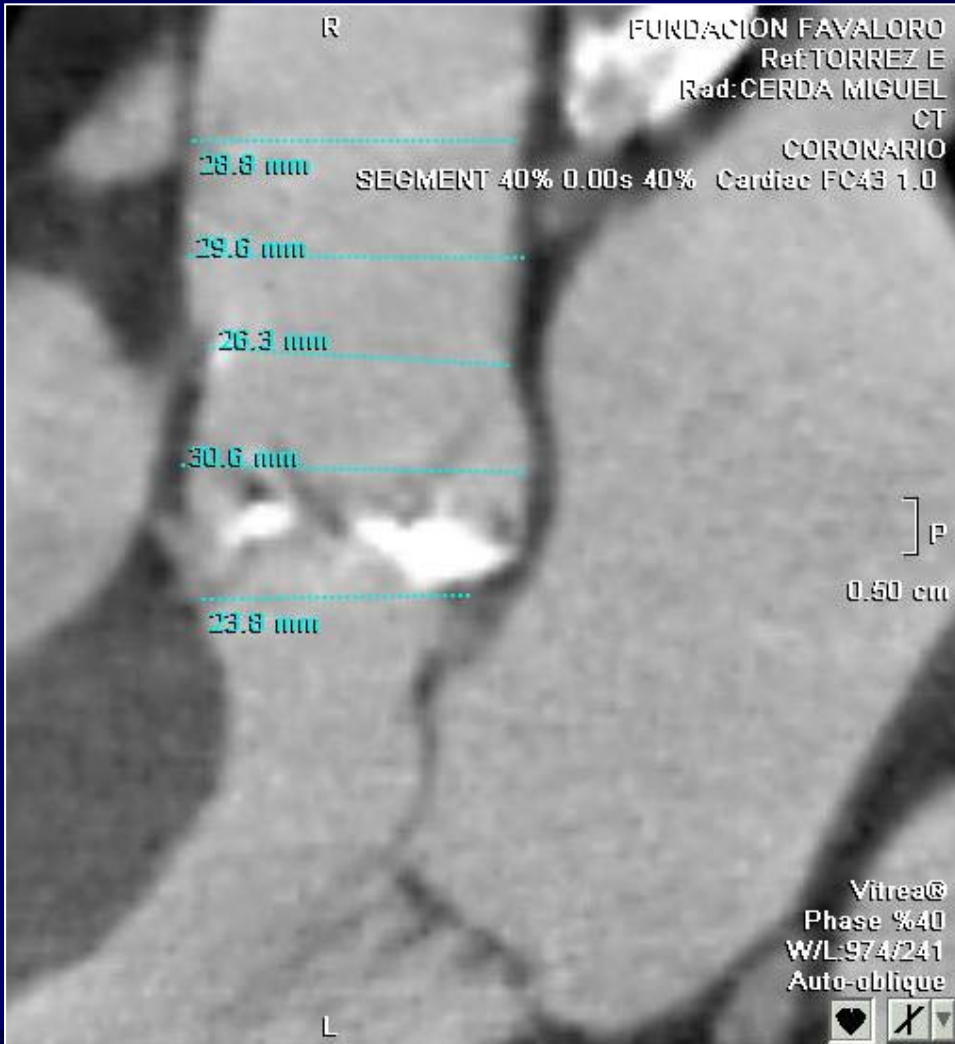
TAVR @ Favalaro Foundation

HALF 730r



TAVR @ Favaloro Foundation

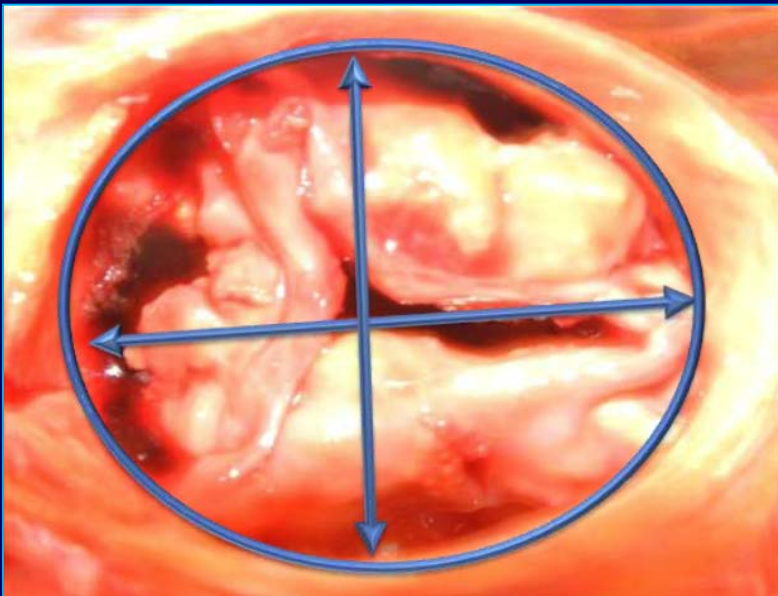
Pte Selection



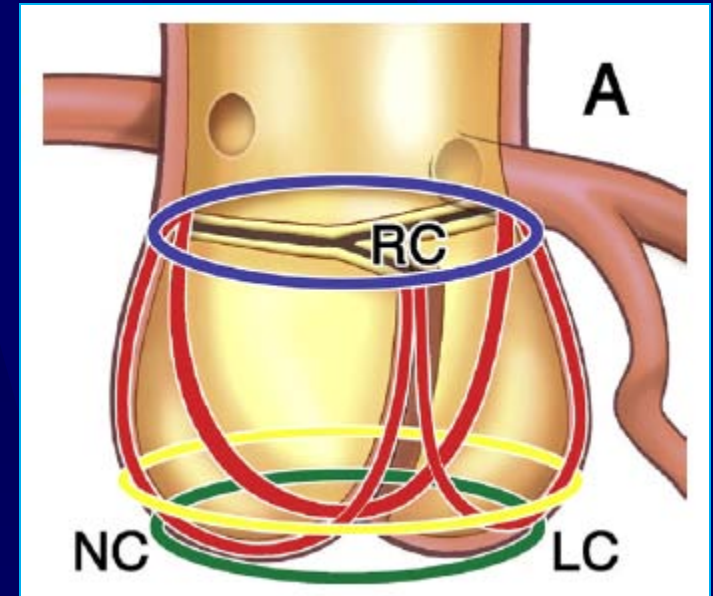
MO, 86 años

Adjunctive Imaging during TAVR

Measurement of Annulus Dimensions

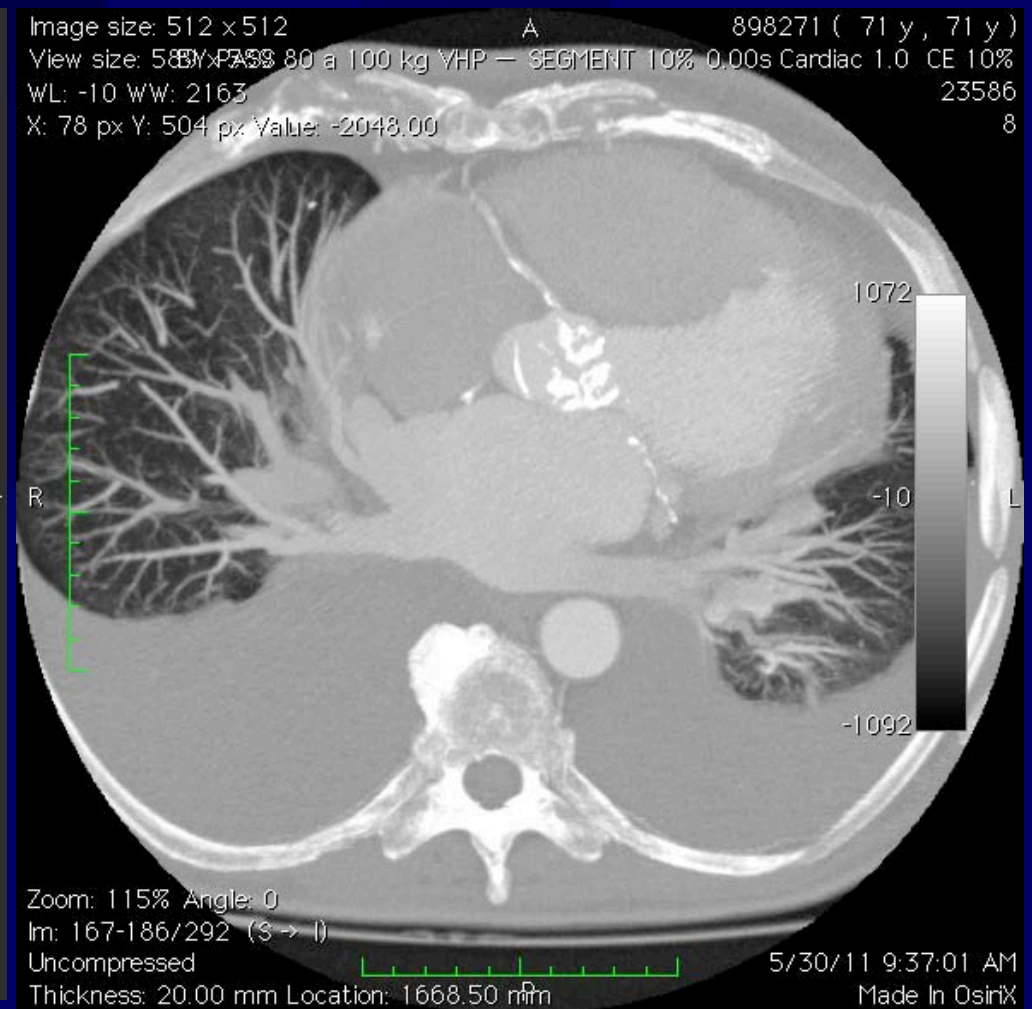
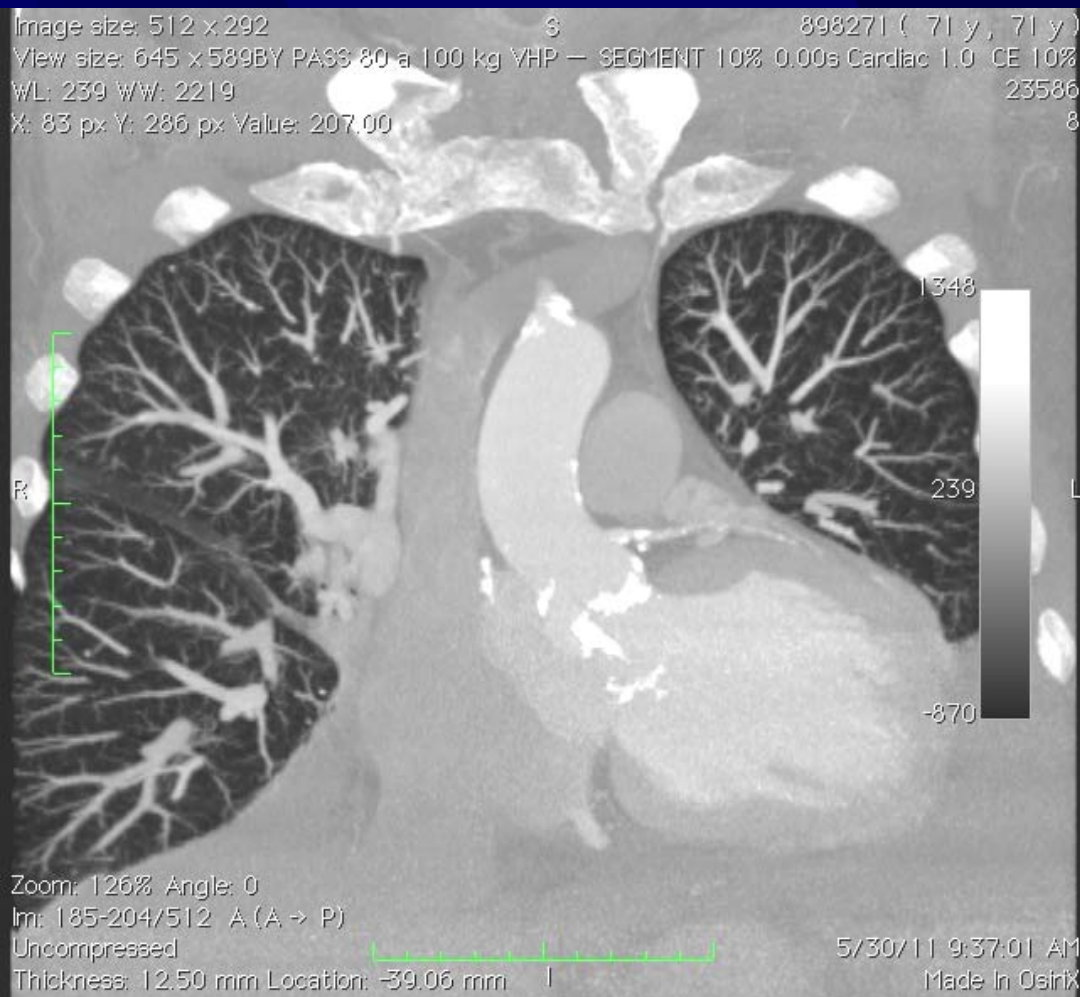


The native annulus is oval-shaped, 2D measurements assuming a circular shape are problematic



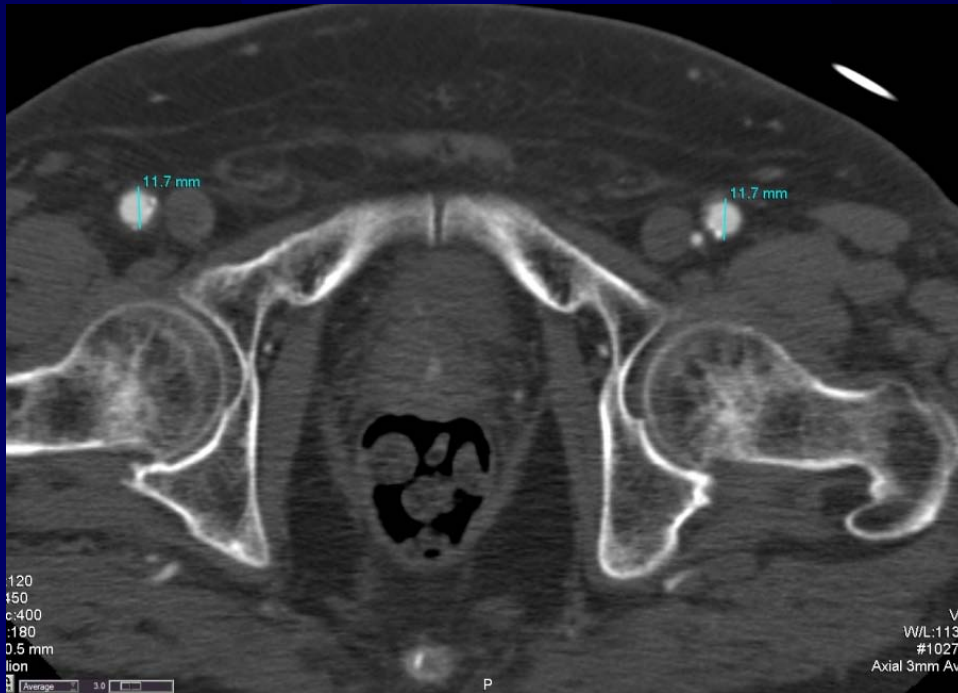
Measurements should be taken at the “hinge-point” of the valve (below the true annulus)

Personal Experience: Direct TAVI

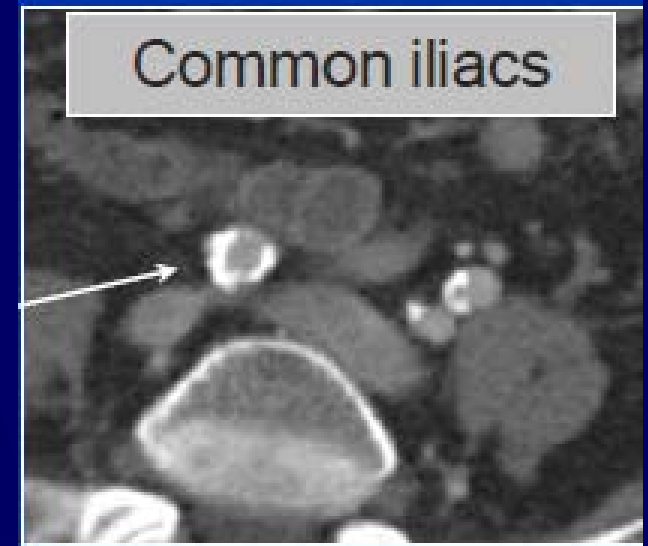
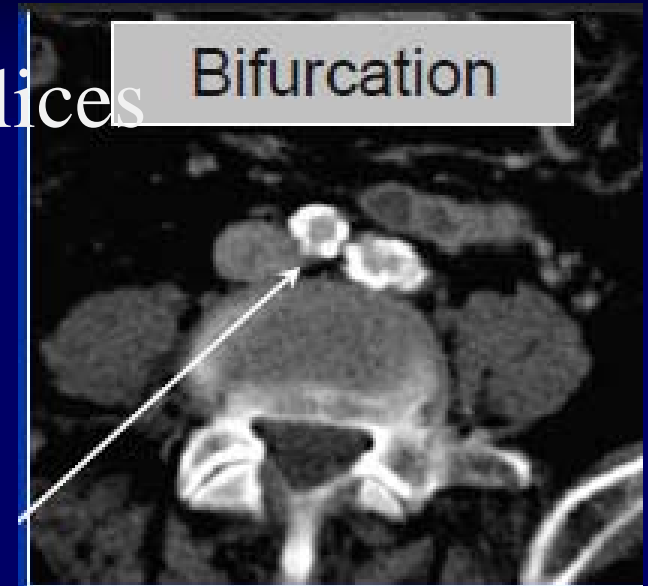


TAVI @ Favaloro Foundation

Pte Selection: Don't forget CT axial slices



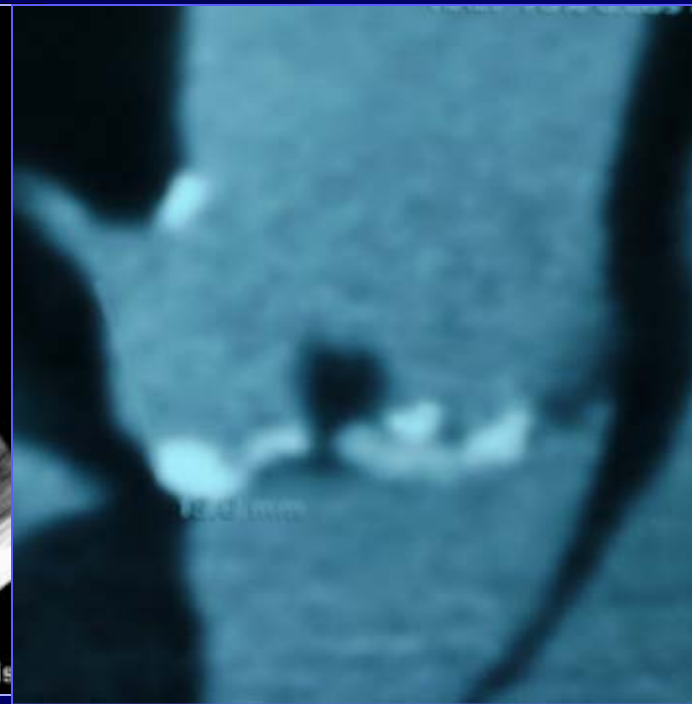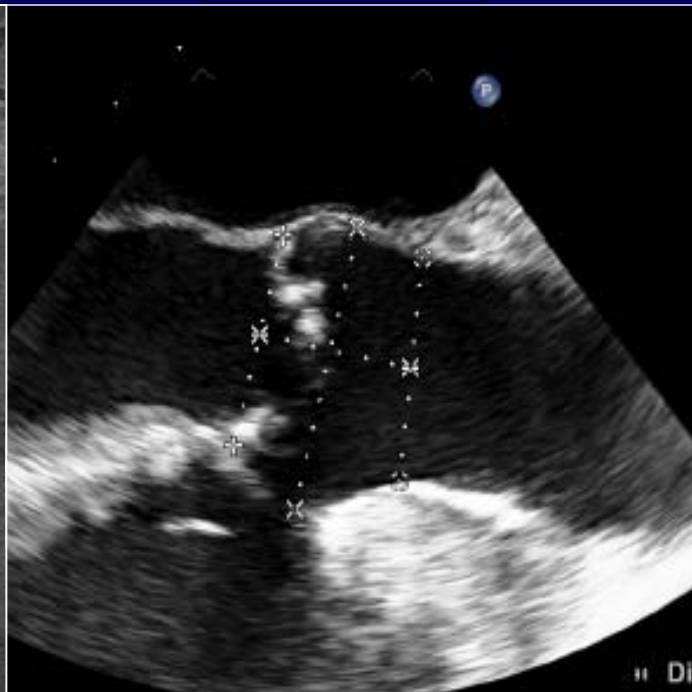
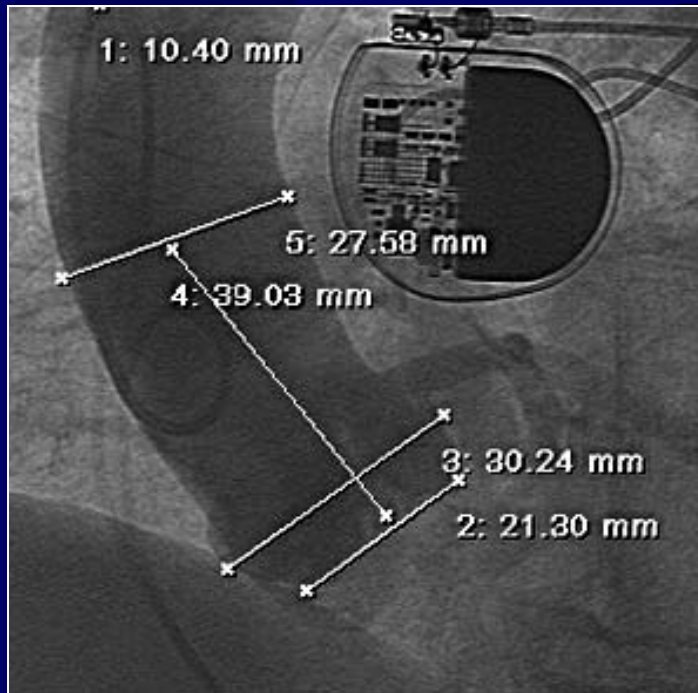
Good Candidate for Femoral Approach



Poor Candidate for Femoral Approach

Screening Mistakes: Annulus Discrepancies

- Improving with learning curve.
- Use 3 methods.

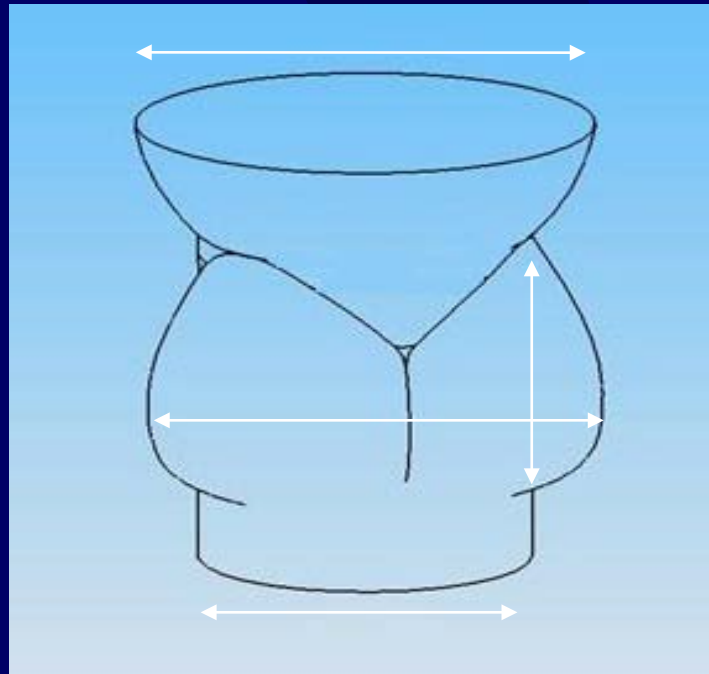


TAVI @ Favaloro Foundation

Anatomic criteria for Pte Selection

Aorta \leq 40 mm 26 mm

Aorta \leq 43 mm 29 mm



Sinus Hight:

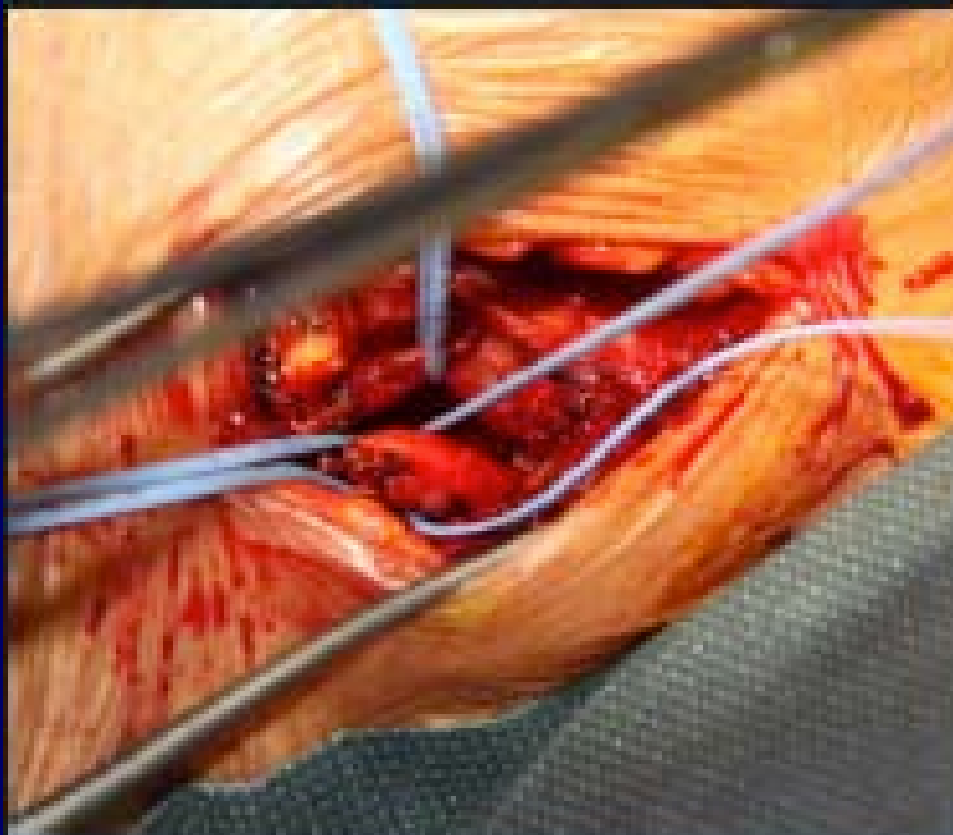\geq 15 mm Hight

\geq 30 mm wide

Annulus: 20 – 23 mm 26 mm

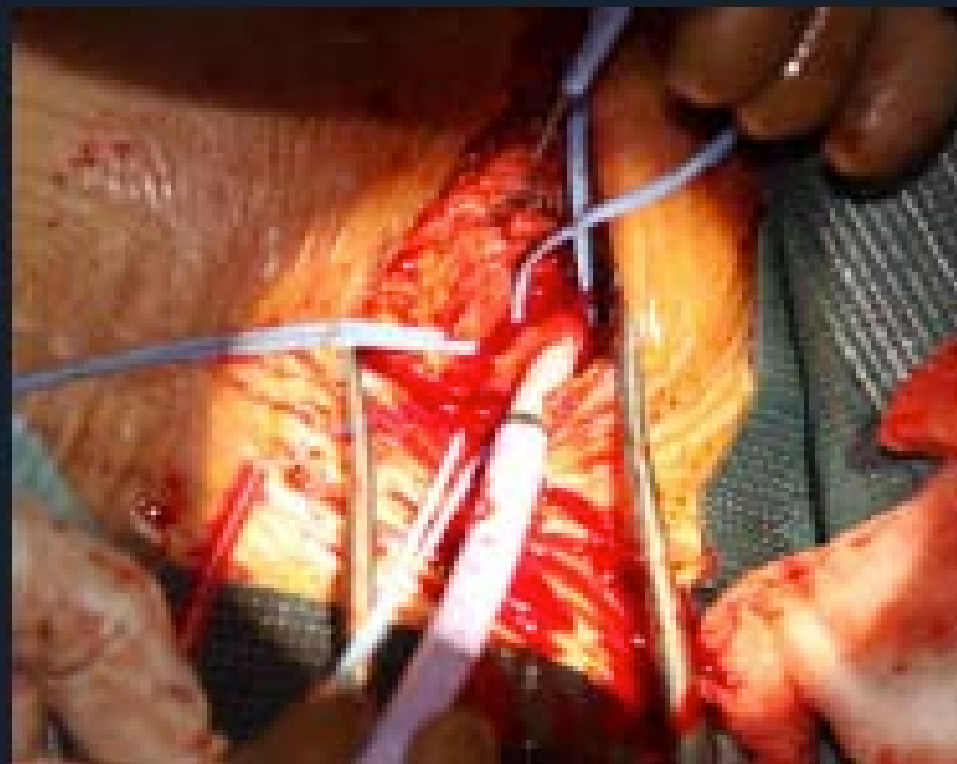Annulus: 24 – 27 mm 29 mm

Trans-axillary (subclavian) TAVI (CoreValve)



Surgical exposure

18Fr sheath (\pm graft)



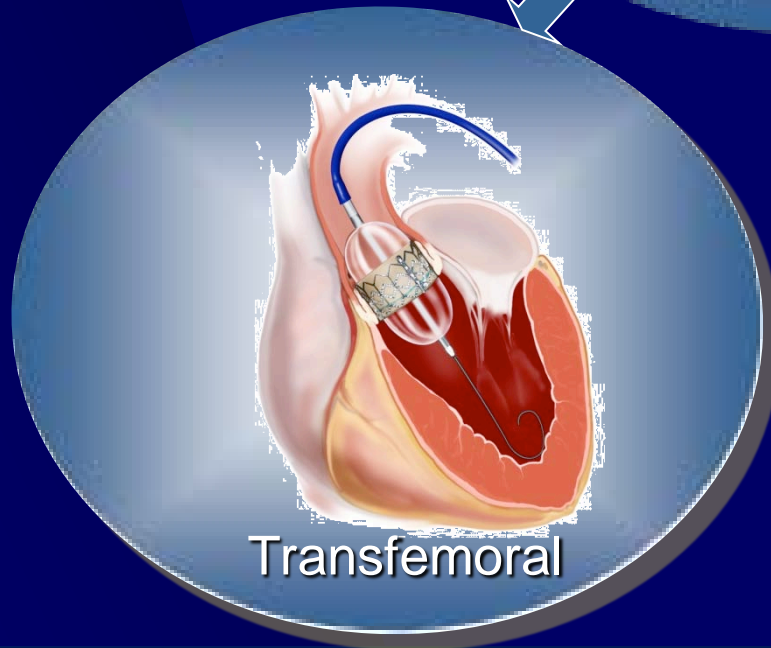
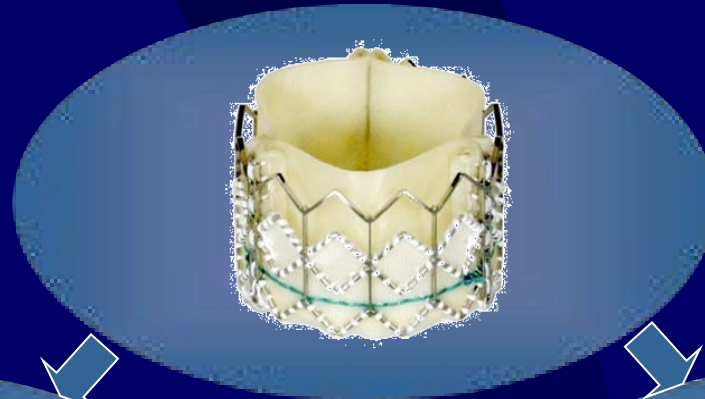
n=1/60



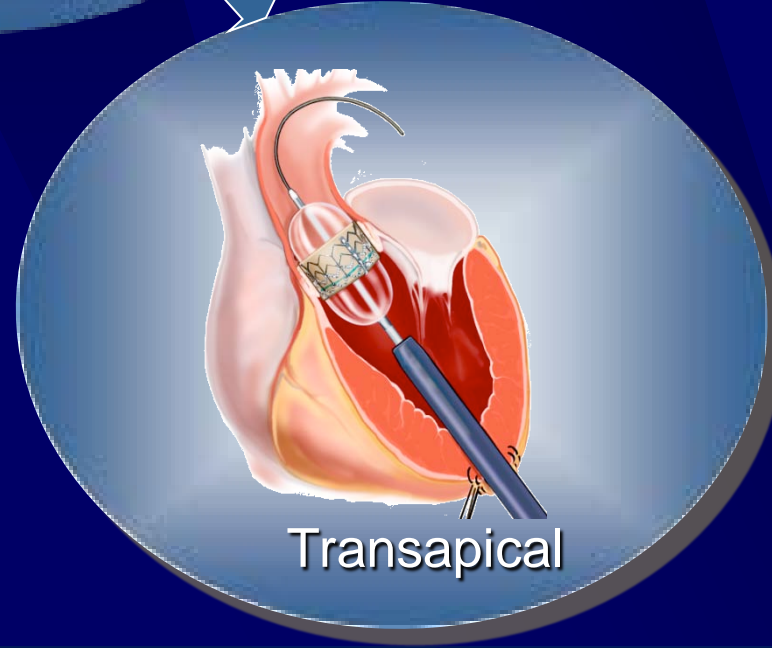
Fundación Favaloro

TAVR

Transfemoral and Transapical

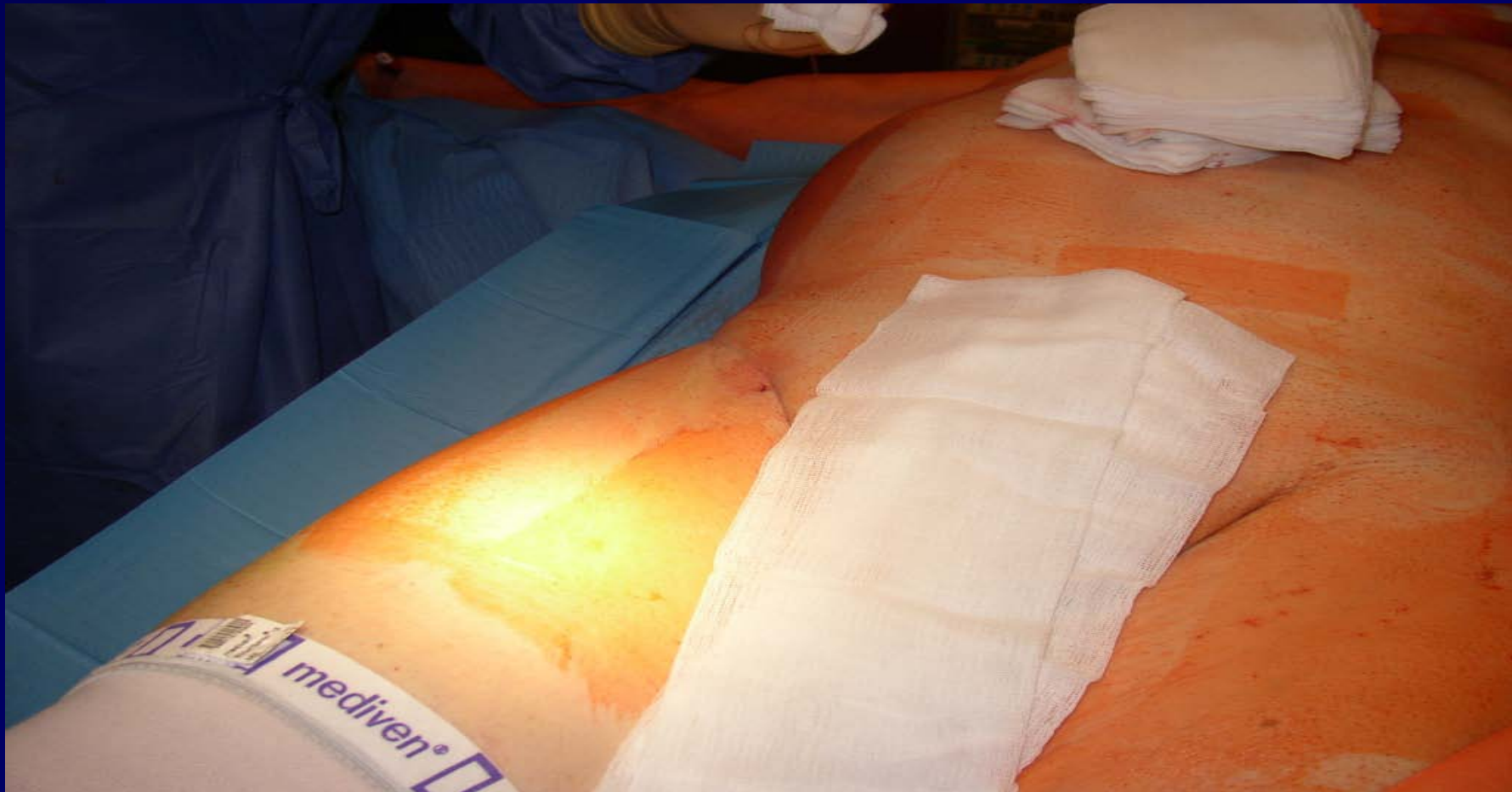

Transfemoral

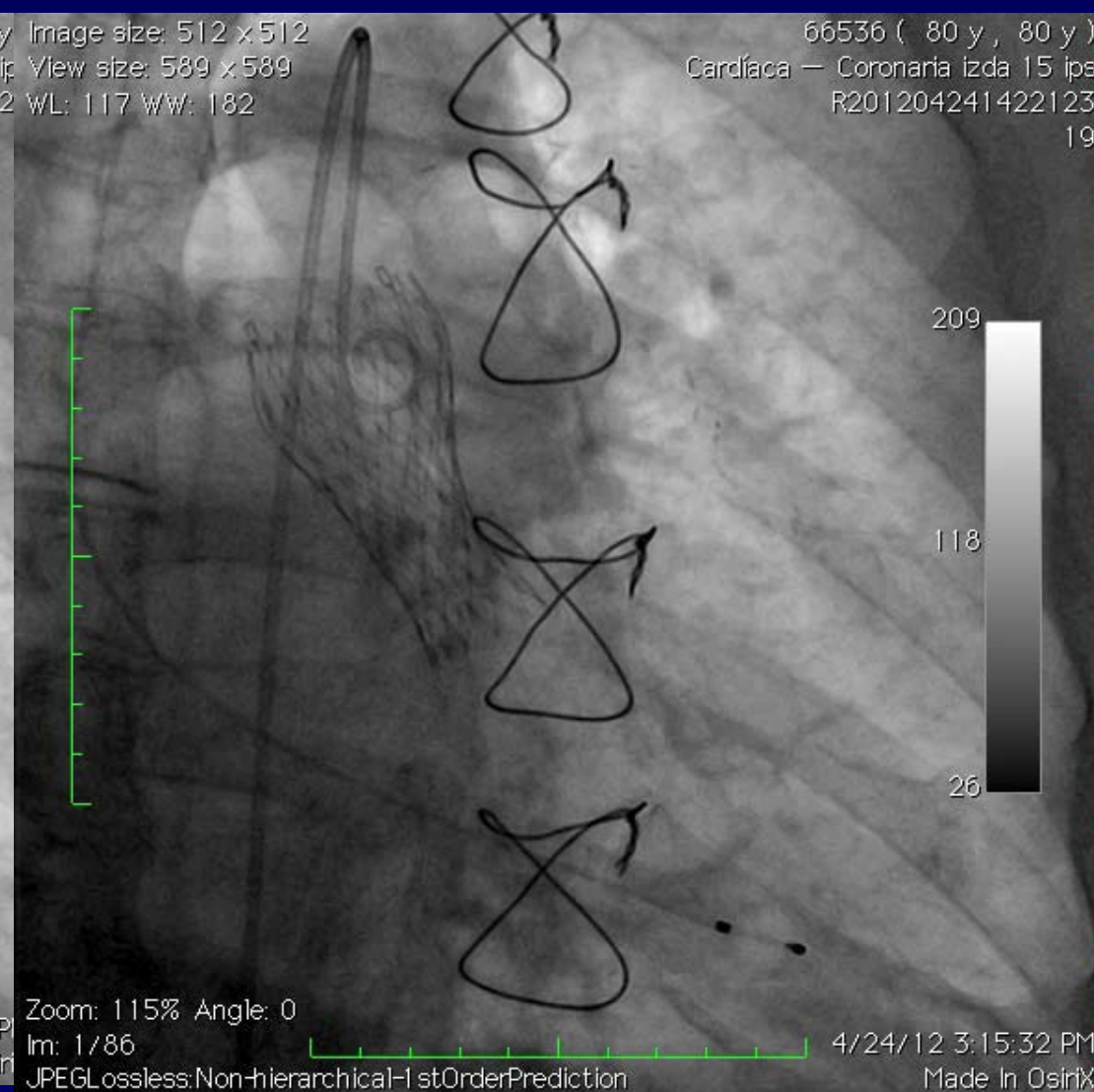
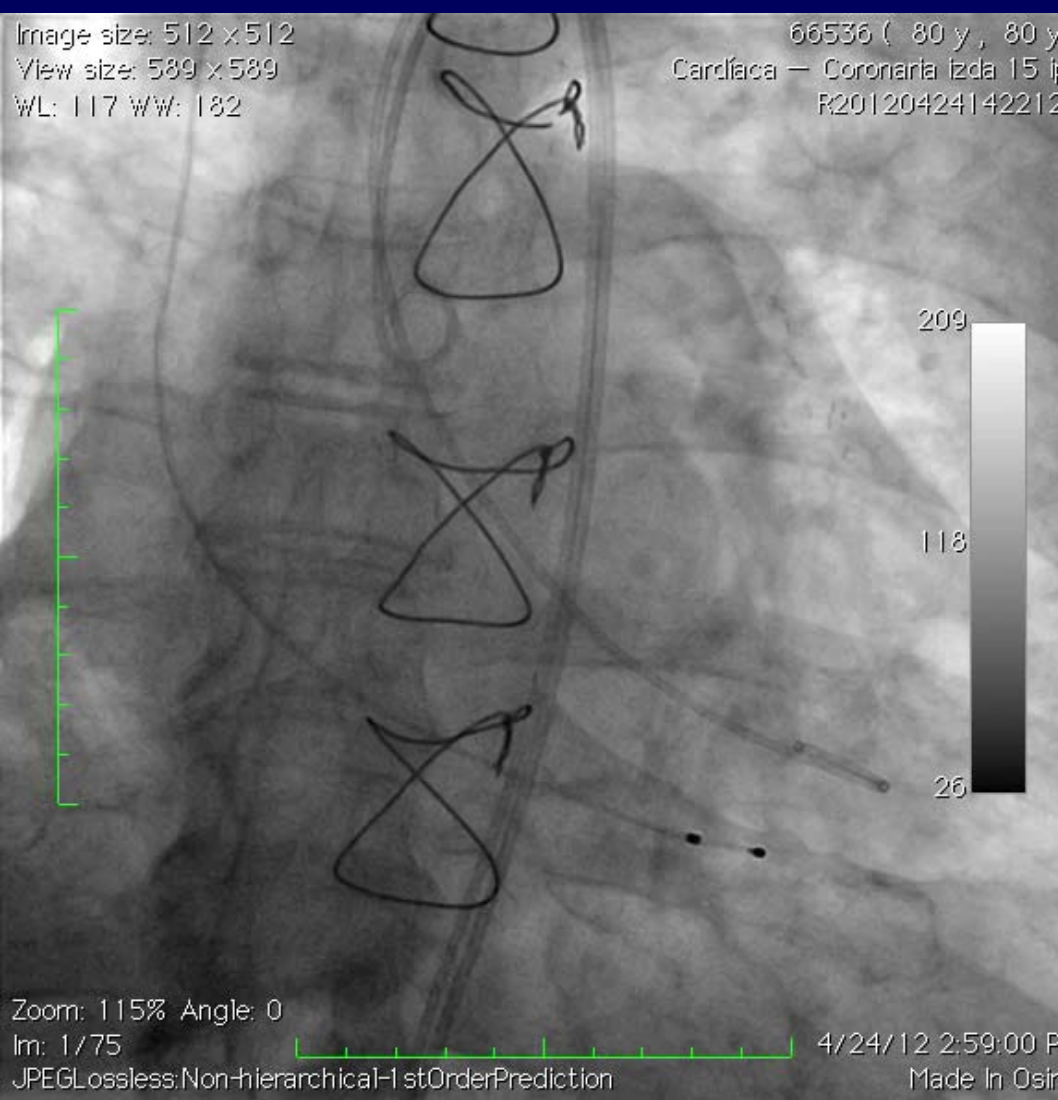


Transapical

Percutaneous TAVI

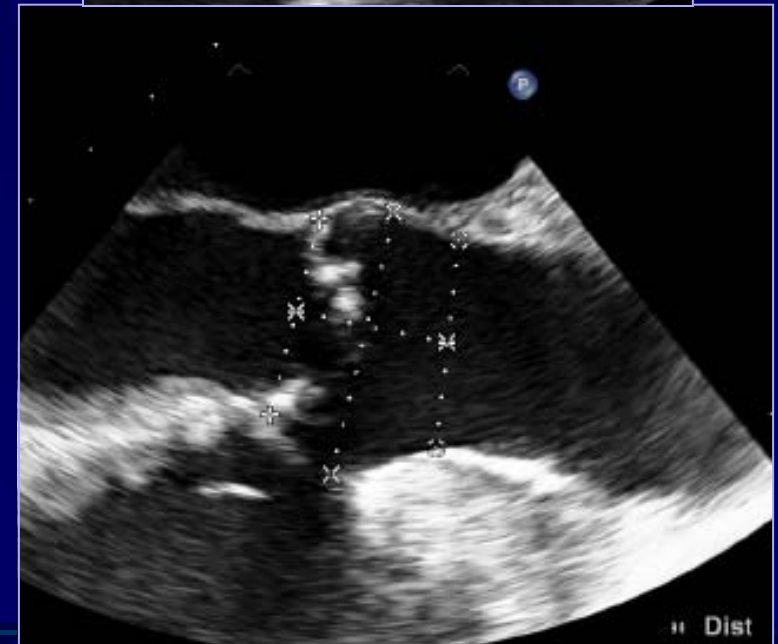
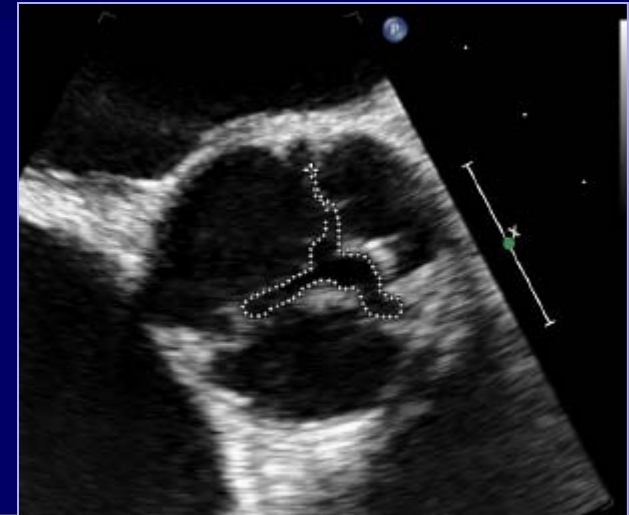
Valve-in-Valve TAVR: Fundación Favaloro

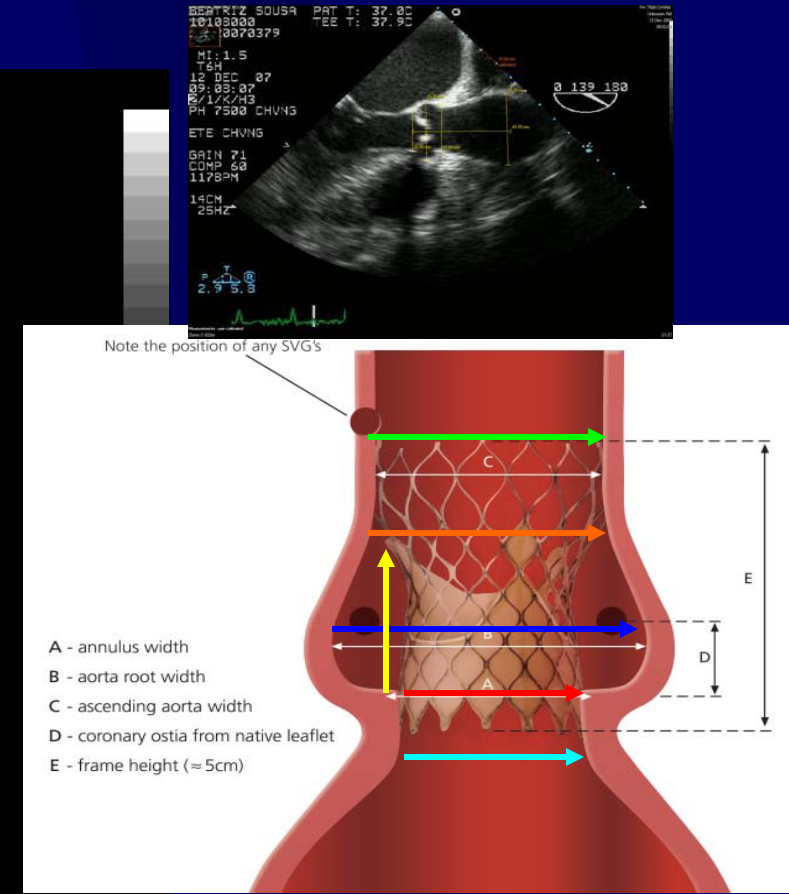
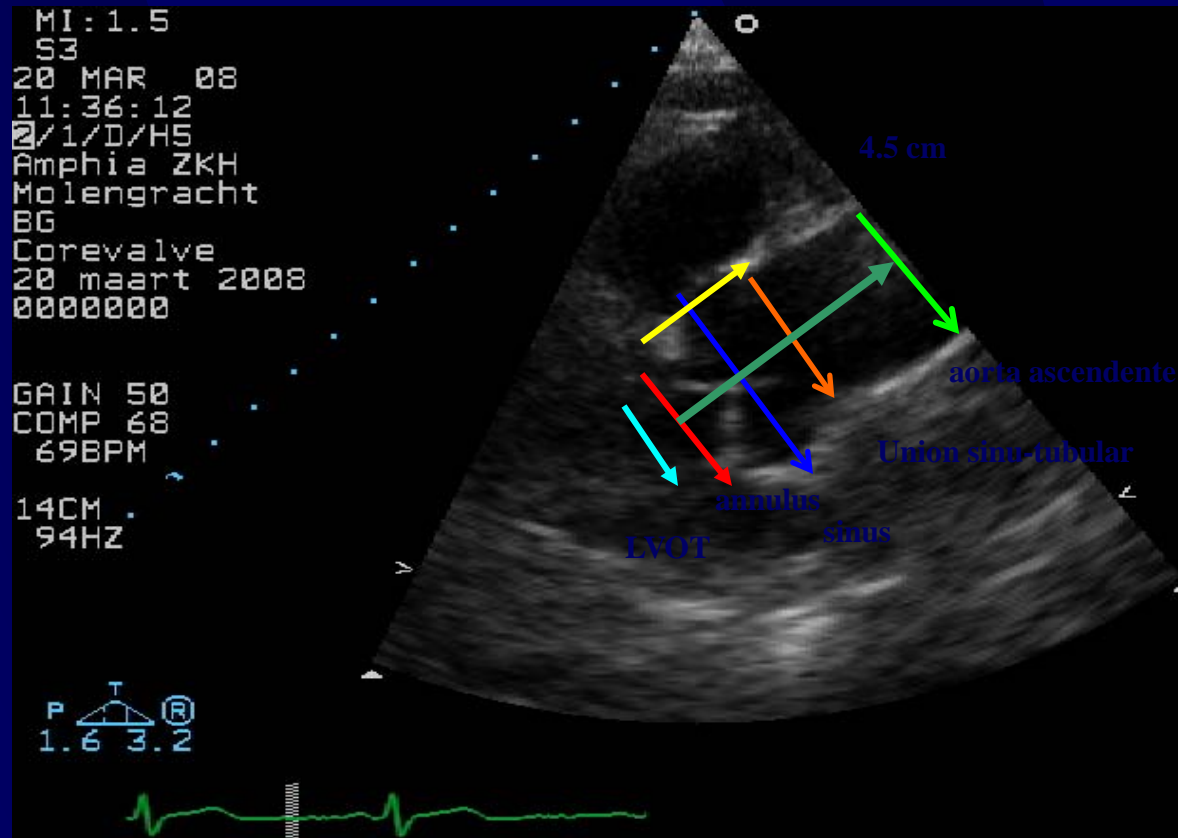


Echo - Measurements

- **Highly important among others:**
 - **Valve:**
 - **Area / Gradient**
 - **Annulus diameter !!!!**
 - **Shape (BICUSPID??)**
 - **Aorta:**
 - **Severe aortic arch atheromas**
 - **Heavily calcified aortic root**
 - **Small and calcified STJ**
 - **Ventricle:**
 - **Very small LV cavity**
 - **Upper septal budge**
 - **EF**
 - **Left Atrium: thrombus absence**



Eco-medidas de la raíz aórtica



Vista de Corte Axial Paraesternal Largo

➤ Aorta root measurements



SOLACI '12

México, DF

TCT@SOLACI Session

Agosto 8-10 - 2012
Hotel Camino Real Polanco
LOS ESPERAMOS!!!
www.solaci2012.com



Home

Welcome

About SOLACI 2012

Faculty

Scientific Activities

Commercial Exhibit

Events Calendar

Attendee Services

Contact Us

EuroIntervention

Exhibitors &
Faculty
access





Gracias por su Atención



Fundación Favaloro

Improving Technique: TAVI Direct (n=52)

