

A prospective randomized controlled 3 and 12 months OCT study to evaluate the endothelial healing between a novel sirolimus eluting stent BUMATM and an everolimus eluting stent XIENCE VTM

**Jingbo Hou MD,
Lei Xing MD, Bo Yu MD**



**The 2nd Affiliated Hospital of Harbin
Medical University, China**

Potential conflicts of interest

Speaker's name: Jingbo Hou

☒ **I do not have any potential conflict of interest**

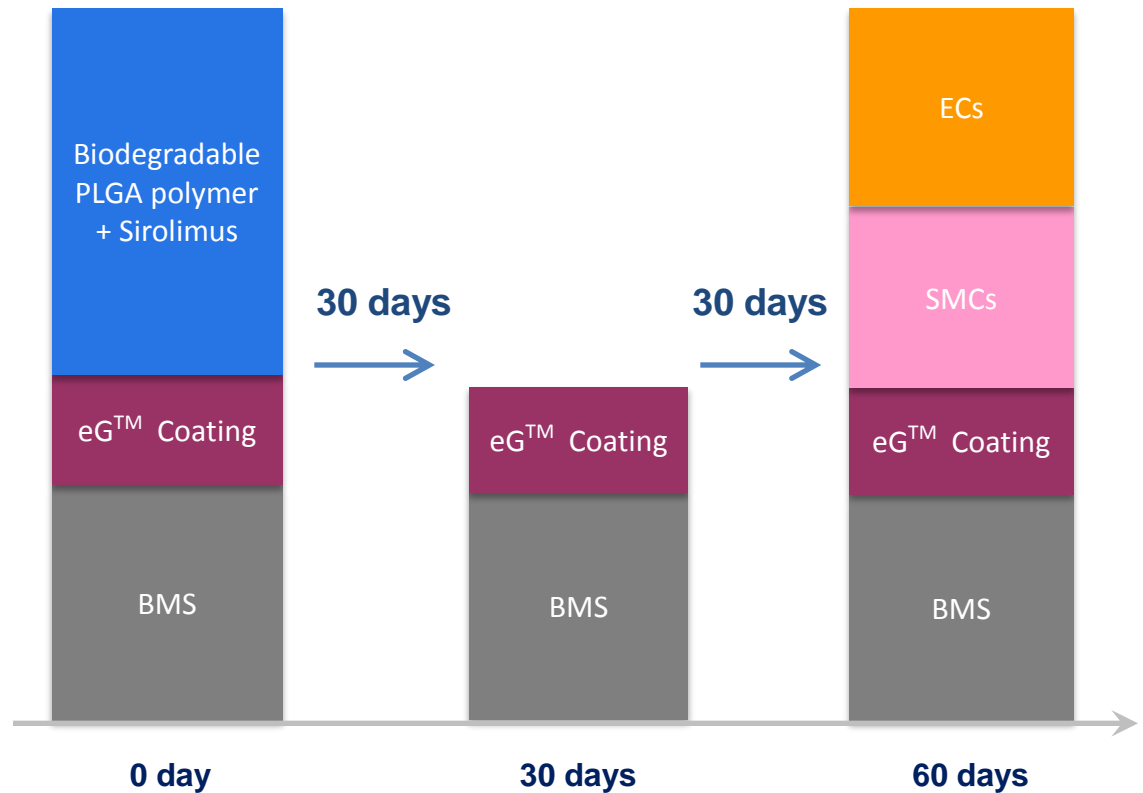
Background

- Uncovered struts and impaired re-endothelialization may induce late stent thrombosis in DES compared with bare metal stent.
- XIENCE V obtained CE indication for a minimum of 3 months DAPT medication, which can be contributed by its superior endothelialization to the 1st gen DES.
- BUMA was approved in China by the end of 2010. Superior clinical feedback was received for 50,000 implanted units so far.
- BUMA features a 30-day-release biodegradable drug coating and a nanometric electro-grafting (eG[™]) base layer. Animal studies in both rabbits and swines demonstrated its fast and complete endothelial healing.

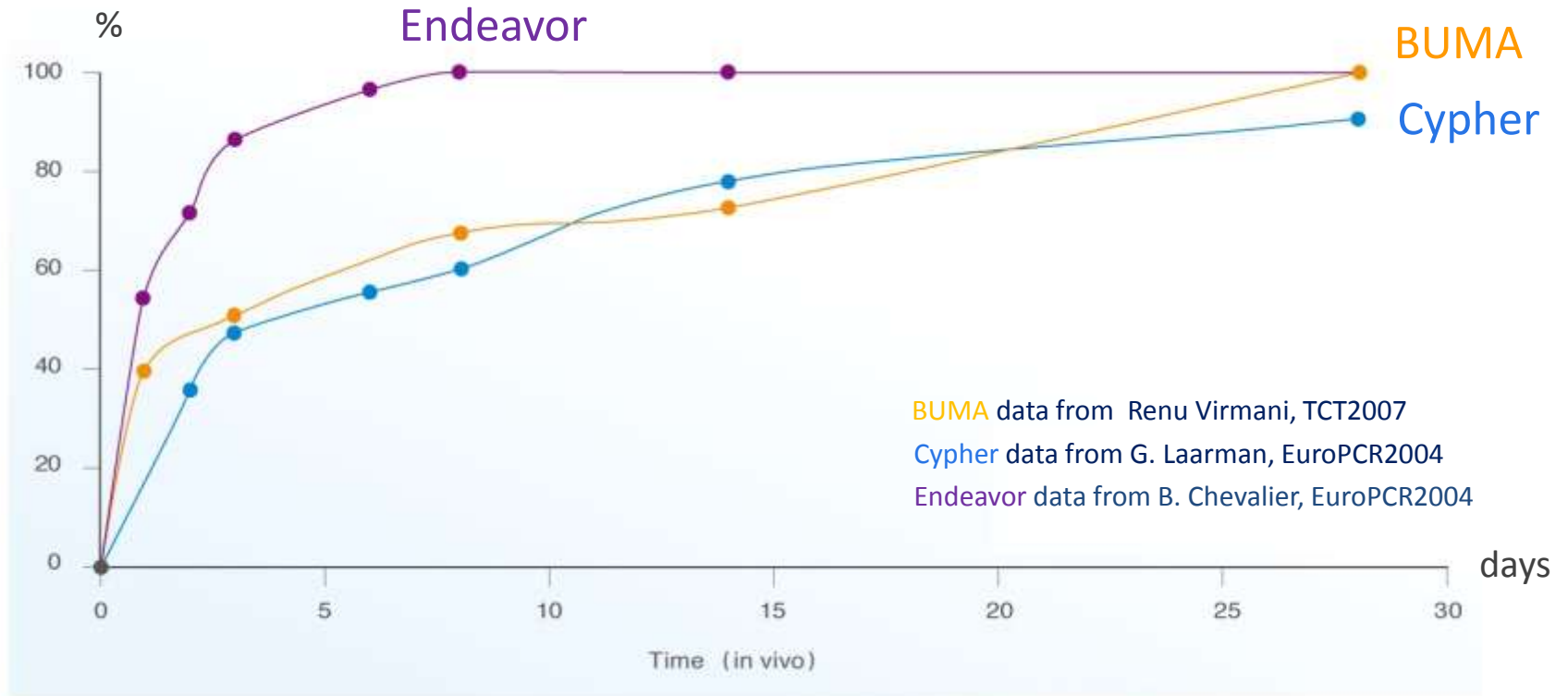
¹ Renu Virmani, *Near-to-complete short term re-endothelialization of a sirolimus eluting stent using electro-grafting (eG[™]) coating technology*, TCT 2007.

Decoupling Concept Design

- Decoupling between drug release and re-endothelialization.
- 30 days of 100% drug release.
- 60 days of fast and near-to-complete endothelialization.




Drug Release Curve



BUMA drug release curve is similar to Cypher.

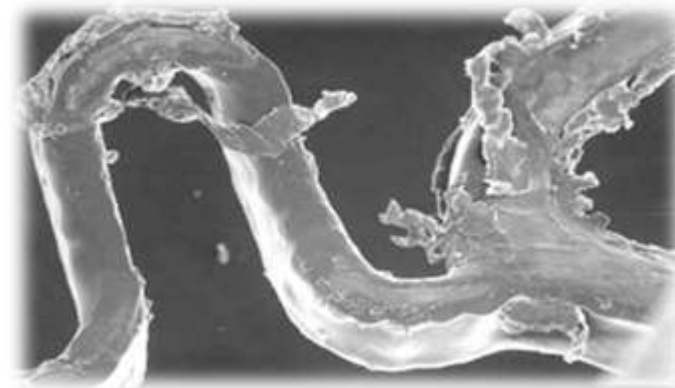
eG™ + biodegradable coating



Mechanical integrity of coating (expanded in air)



BUMA



other
DES
in the
market¹

eG™ base layer secures adhesion of the biodegradable polymer matrix hosting the drug, prevents cracking and delamination upon expansion and over time.

¹ John Ormiston et al. Presentation at TCT 2004

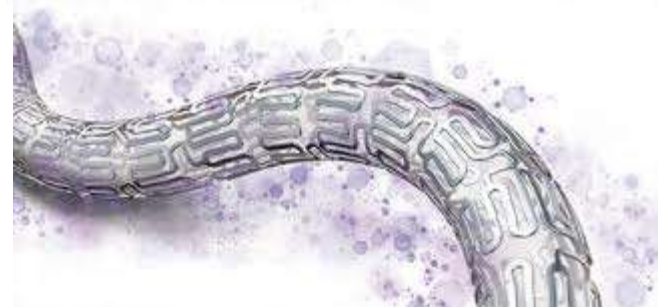Research Questions

- What are the differences in endothelialization results could be observed by comparing BUMA and XIENCE V in real life scenarios?
- Is it easier to detect differences between two kinds of stents when implanting them in the same vessel, **shoulder to shoulder**, to reduce variance in vessels, patients or interventional cardiologists?

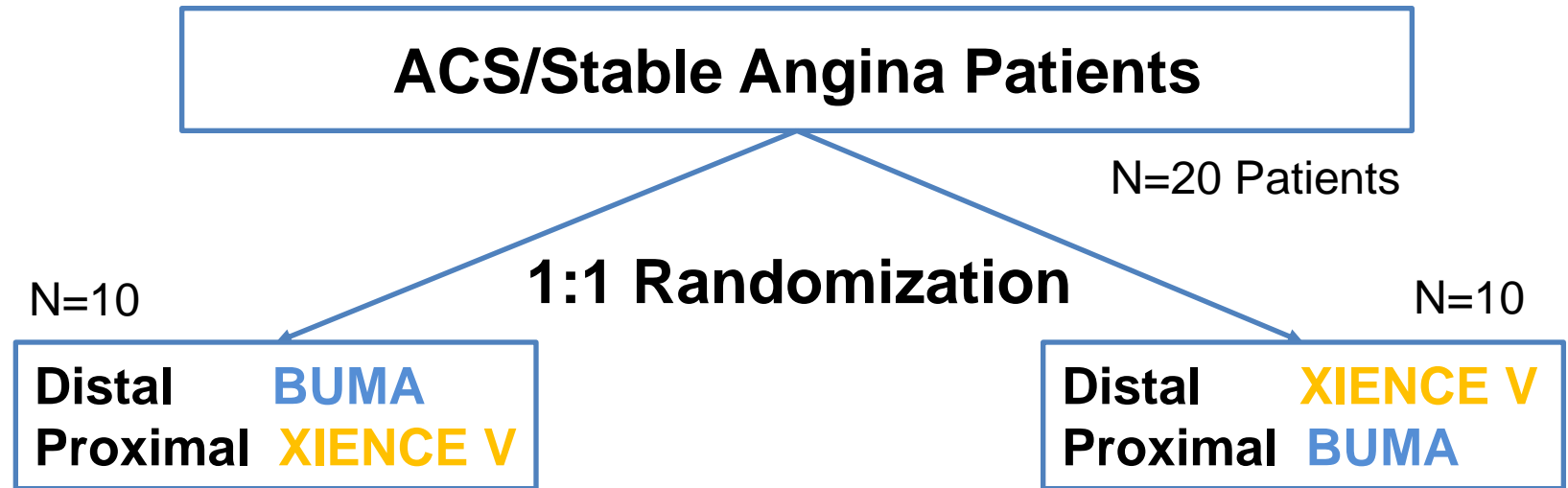
BUMATM



Xience V



Trial Design



Overlapped BUMA & XIENCE V at the same lesion (≥ 20 mm in length), in the same vessel of the same patient.

1° Endpoint	Endothelial coverage at 3 months
2° Endpoints	Endothelial coverage at 12 months; clinical events
Follow up	Clinical F/U to 3 years

Inclusion & Exclusion Criteria

Inclusion

General:

- Age from 18-75 years;
- Require PCI treatment with stable angina or ACS;
- Signed informed consent;

Angiography inclusion:

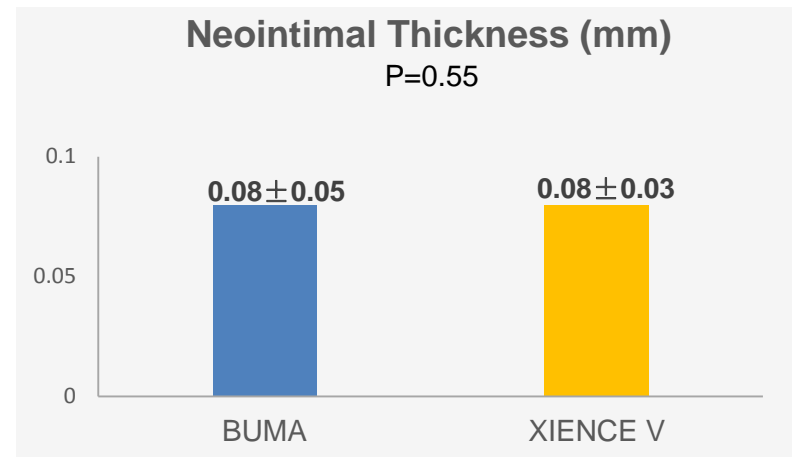
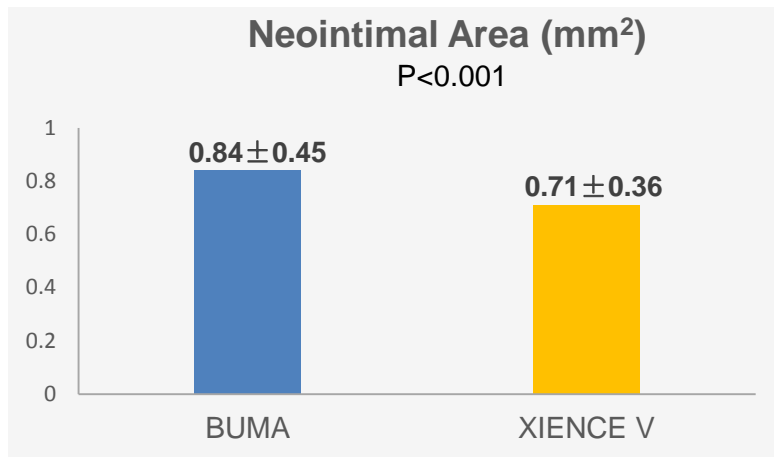
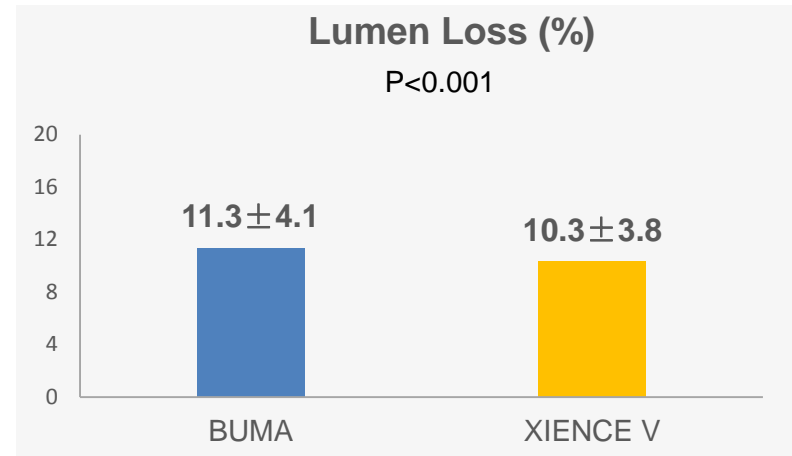
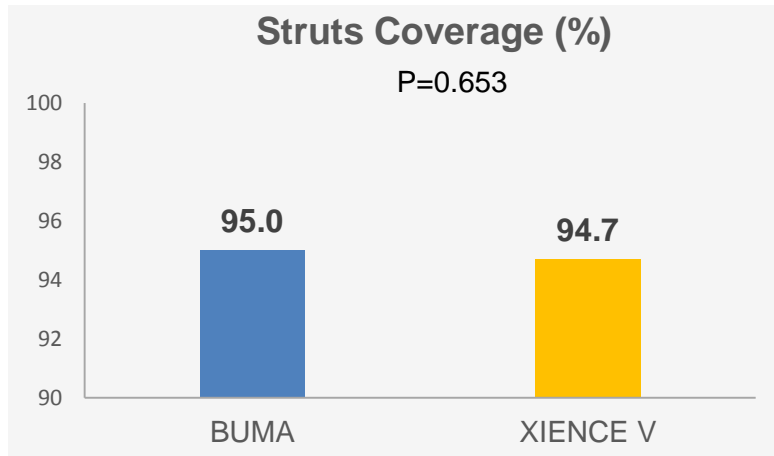
- Lesion length >20mm, vessel diameter from 2.5-3.5mm, requires overlapped stents (overlapping length 3-5mm);
- The lesion can be covered by two stents;
- Reference vessel diameter ranges from 2.5-4.0mm.

Exclusion

- STEMI within 7 days;
- CABG history;
- Life expectancy <1 year;
- Urine creatinine >2.0mg/dL or serious renal disease;
- Serious Liver dysfunction;
- Planning CABG, surgical repair or replacement, cardiac transplantation;
- Known allergy to anti-platelets, heparin, stainless steel, cobalt alloy, everolimus, sirolimus, contrast medium, polymer coating;
- Pregnancy, lactation or planning to be pregnant in 1 year;
- Investigator considers the patient is not suitable for OCT examination.

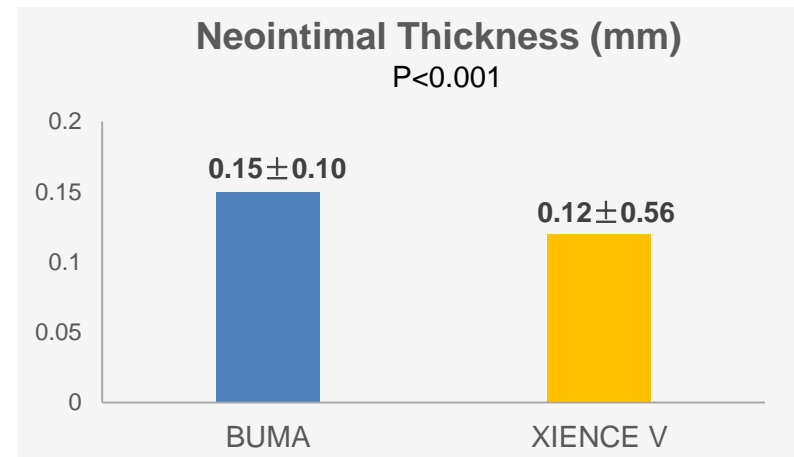
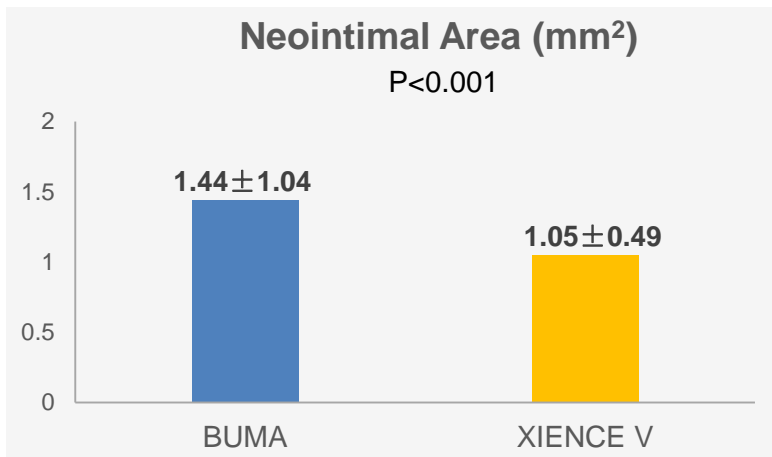
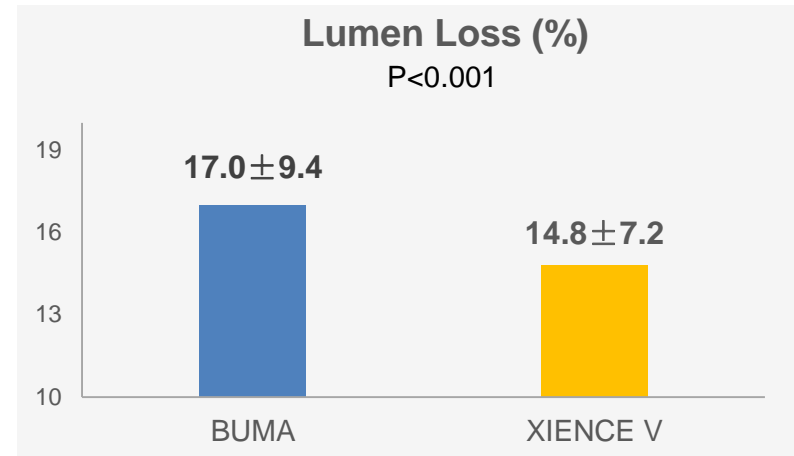
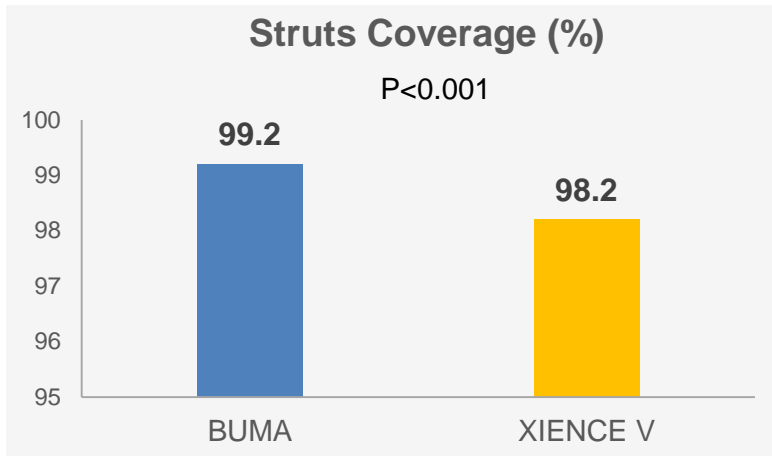
1^o Endpoint: 3 months

N= (BUMA 4312 Struts; XIENCE V 5279 Struts)



2^o Endpoint: 12 months

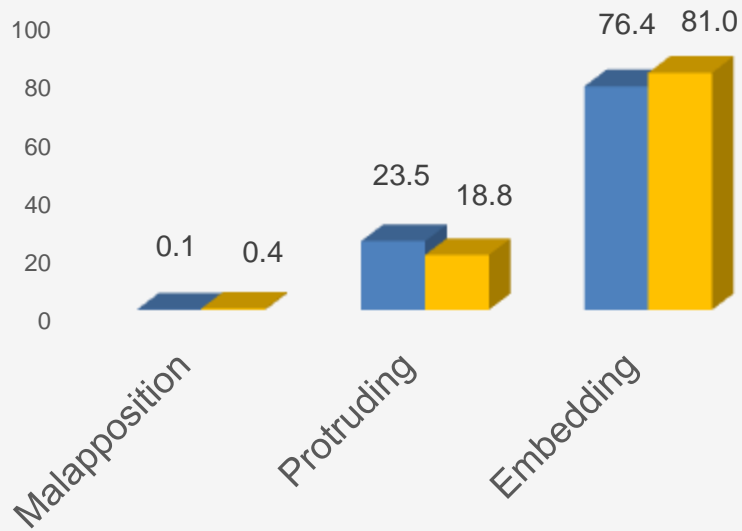
N= (BUMA 3936 Struts; XIENCE V 5400 Struts)



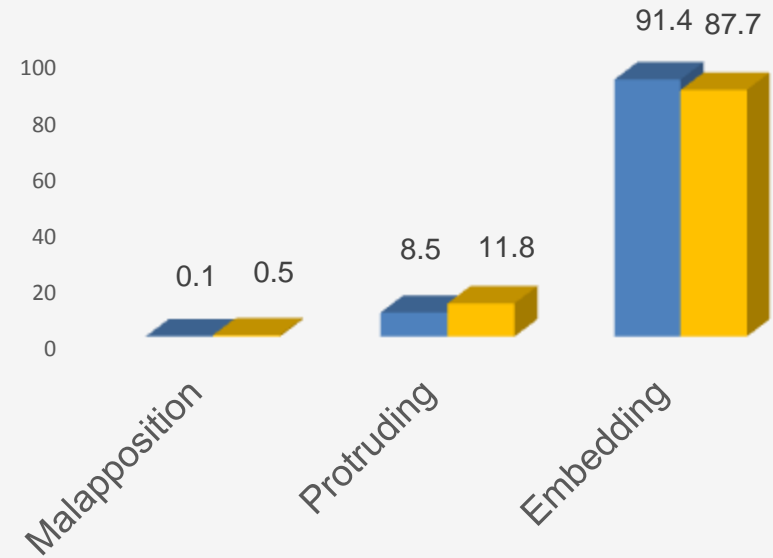
One in-stent restenosis occurred in an overlapping lesion at 10 months, no other events occurred.

Malapposition, Protruding, Embedding

3 months (%)
 $P < 0.001$



12 months (%)
 $P < 0.001$



■ BUMA ■ XIENCE V

Results & Conclusion

- Struts of both kinds of stents are well covered at 3 & 12 months OCT follow-up. BUMA has a significantly better struts coverage compared to XIENCE V at 12 months (99.2% vs. 98.2%, BUMA vs. XIENCE V, $P < 0.001$).
- The struts of BUMA have a thicker neointimal hyperplasia thickness and larger neointimal area (0.15 ± 0.10 mm vs. 0.12 ± 0.56 mm, BUMA vs. XIENCE V, $P < 0.001$). BUMA has a more uniform struts coverage compared to XIENCE V.
- Combined with the malapposition results, BUMA may have an earlier endothelial healing compared to XIENCE V.

Further Findings

- The better coverage and possible earlier endothelial healing of BUMA suggested that the patients may require a shorter DAPT medication and have a better long-term benefit compared to XIENCE V.
 - 2 years OCT follow up is planned, look forward to the long-term results.
-