




ALBERT EINSTEIN
HOSPITAL ISRAELITA



ALBERT EINSTEIN
HOSPITAL ISRAELITA

TAVI - case complication

Marco Perin, MD



Case History

Patient: M.C.T.D.S.

Gender: Female

Age: 91 years old

Weight: 67 kg

Height: 1,69 m

Medical History:

- **Heart Failure NYHA III**

Risk Factor:

- **Dyslipidemia**
- **Renal Insufficiency**
- **Hypertension**

Scores :

- **Logistic EURO I – 6,2 %**
- **STS (Risk of mortality) – 8 %**



ALBERT EINSTEIN
HOSPITAL ISRAELITA

Laboratory Assessment Baseline

Serum Creatinine – 1.0 mg/dl

Hemoglobina – 10.3 g/dl

Platelet Count – $216 \times 10^3/\mu\text{L}$

BNP – 354 pg/ml



ALBERT EINSTEIN
HOSPITAL ISRAELITA

ECHO - Baseline

Effective orifice area: 0.5 cm²

Annulus: 18 mm

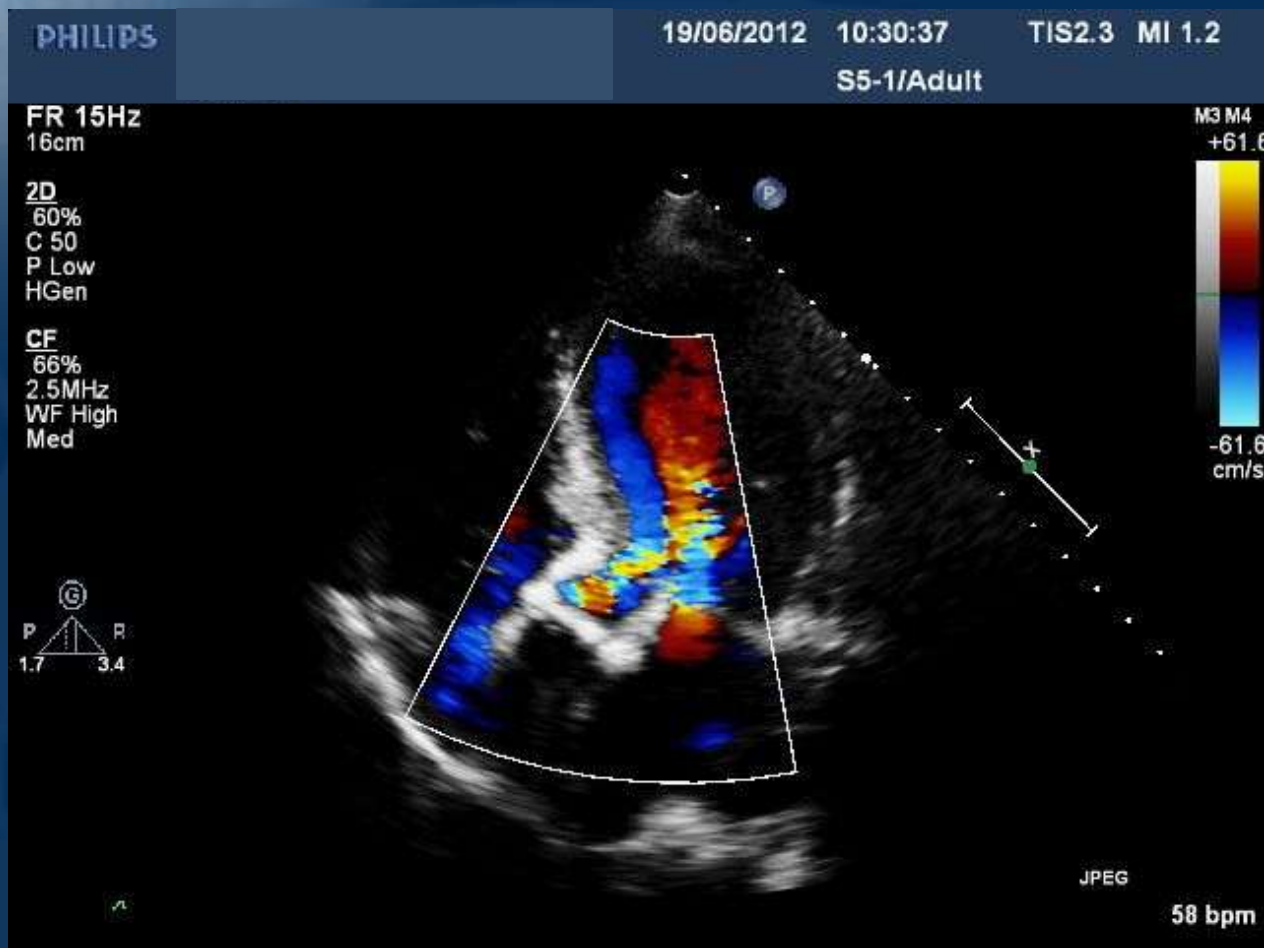LVEF: 68 %

Max Gradient: 109 mmHg

Mean Gradient: 67 mmHg



ECHO - Baseline





CT - Baseline

Porcelane Aorta

Annulus: 24 x 19 mm

Right Coronary Height: 11 mm

Left Coronary Height: 10 mm

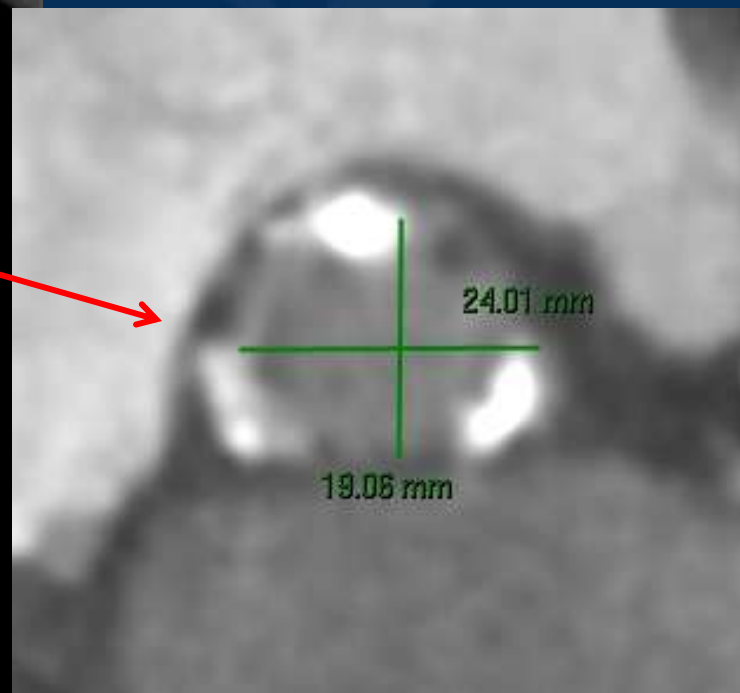
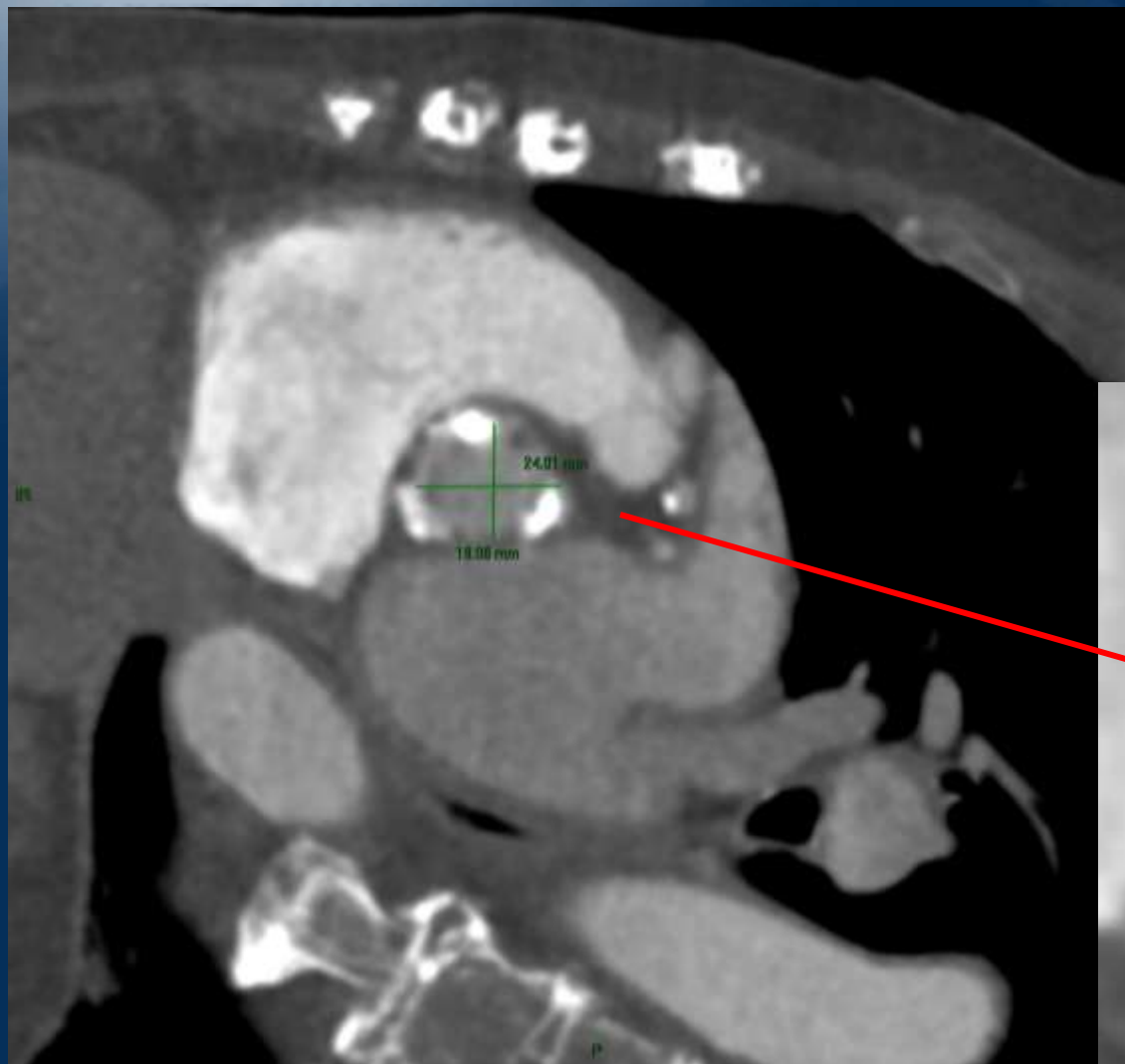
External iliacs:

Left: 11mm

Right: 10 mm



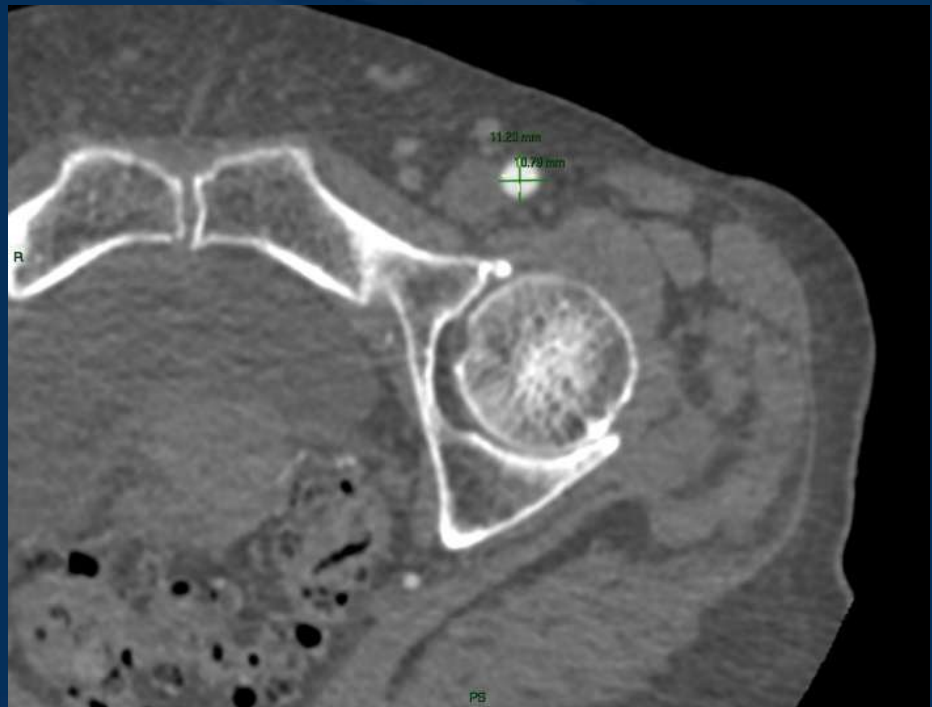
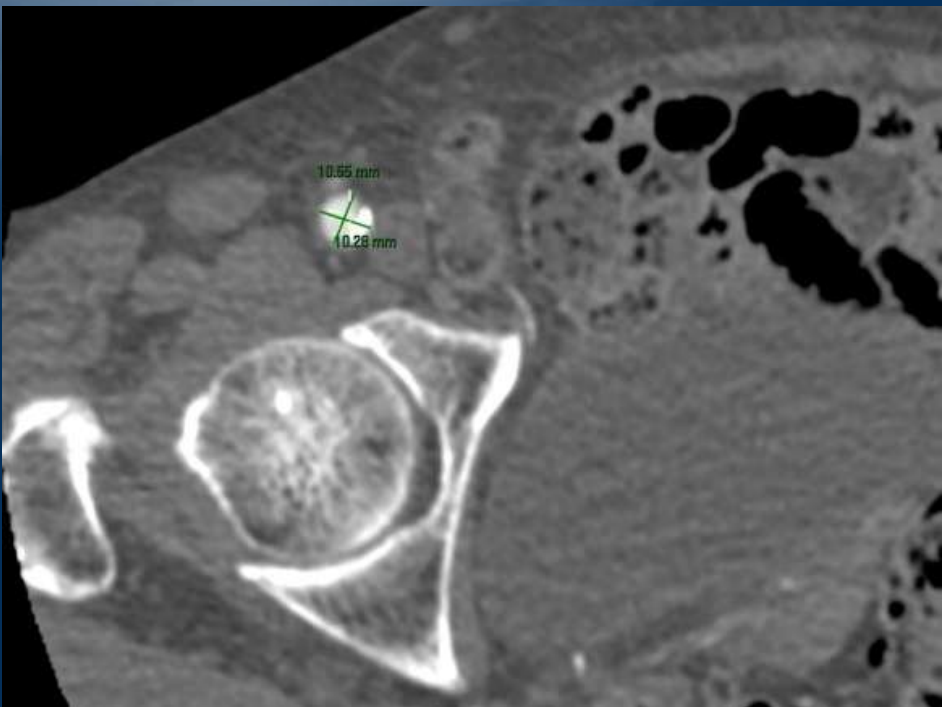
CT - Baseline





ALBERT EINSTEIN
HOSPITAL ISRAELITA

CT - Baseline





ALBERT EINSTEIN
HOSPITAL ISRAELITA

Procedure

Access: Transfemoral

Intra-procedural TEE: yes

Balloon aortic valvuloplasty: yes

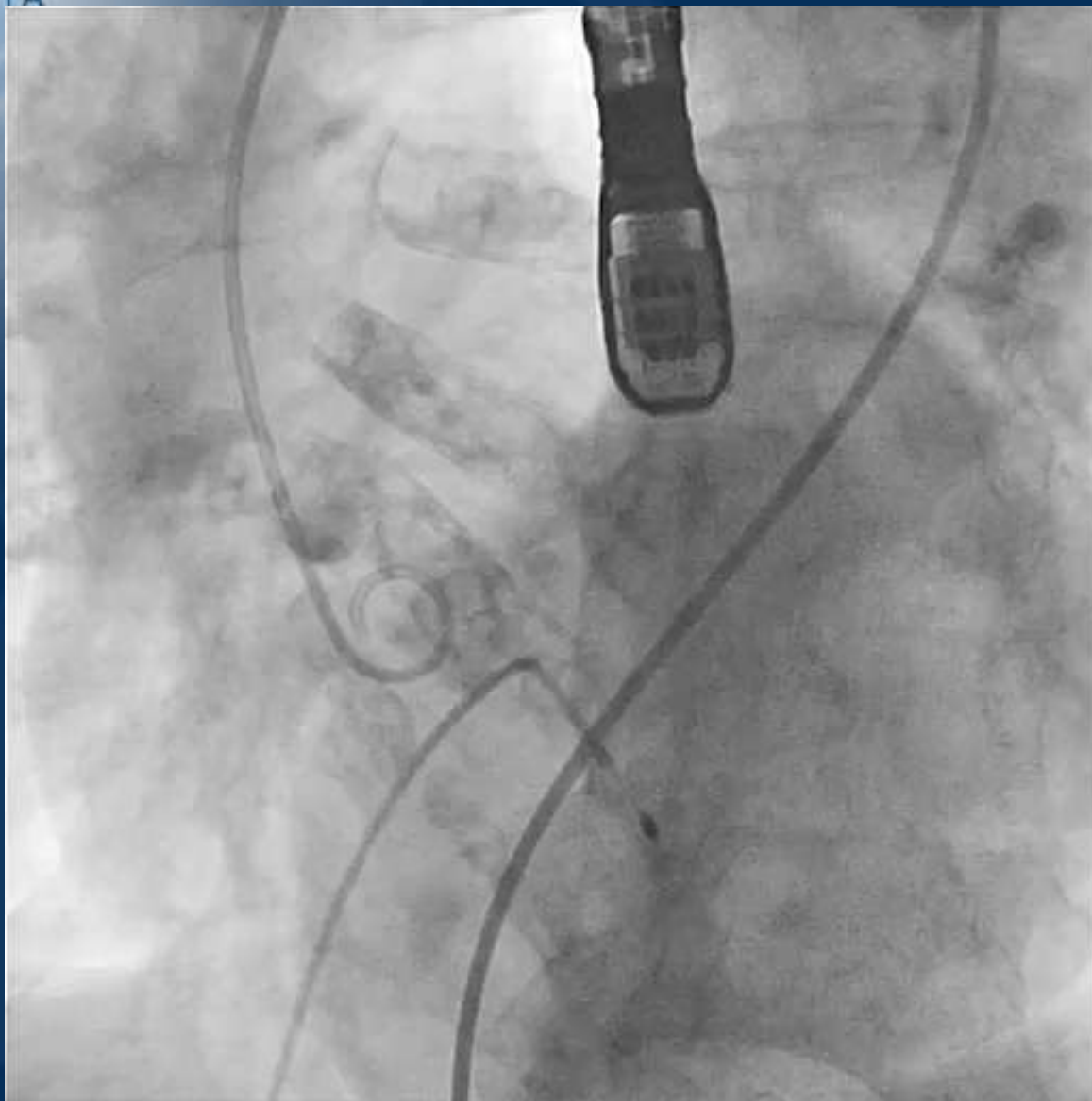
Sapien XT: 23 mm

Post dilatation: yes



ALBERT EINSTEIN
HOSPITAL ISRAELITA

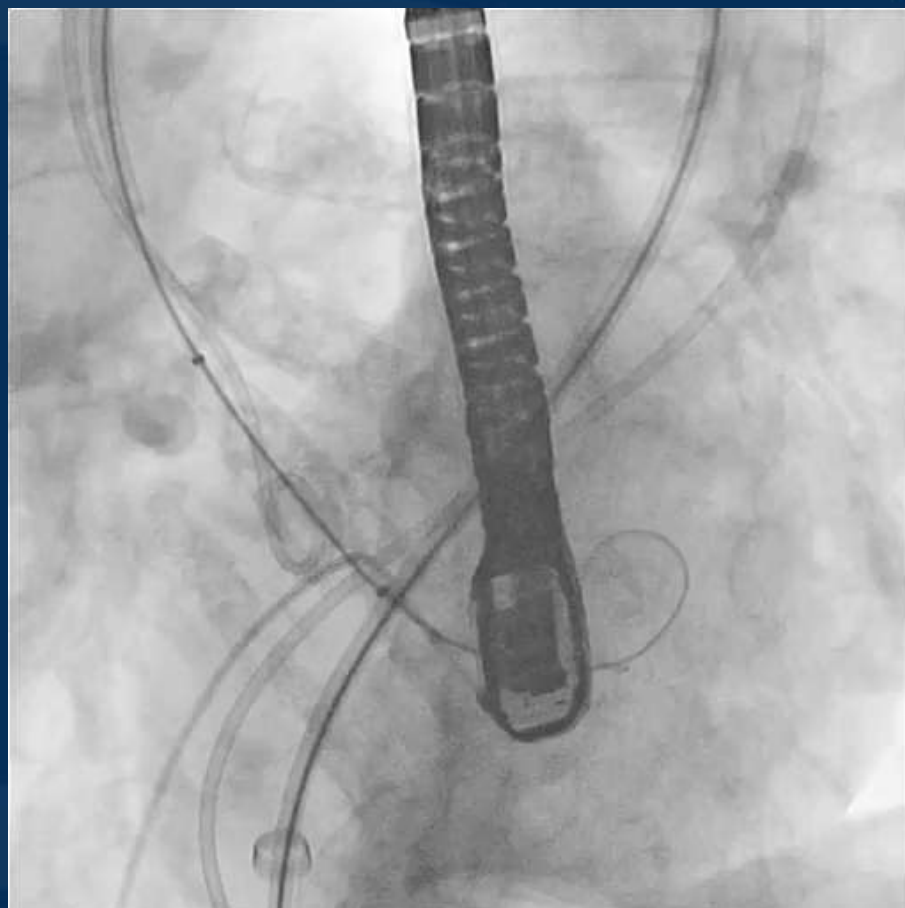
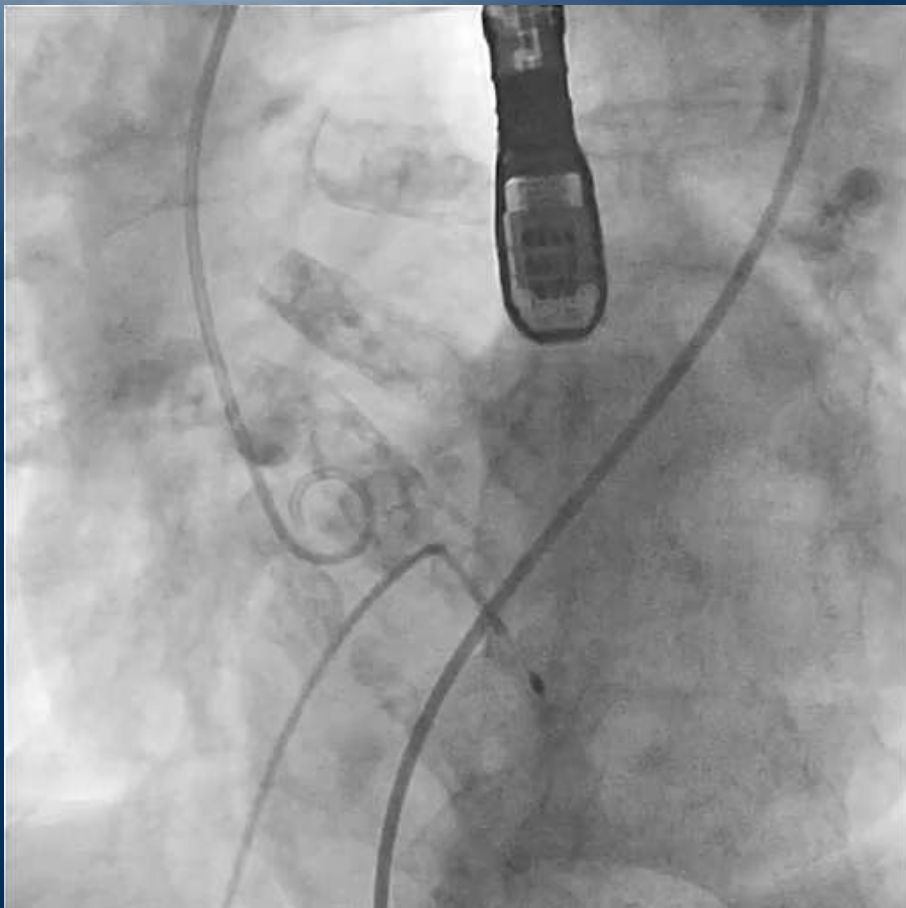
Procedure





ALBERT EINSTEIN
HOSPITAL ISRAELITA

Procedure

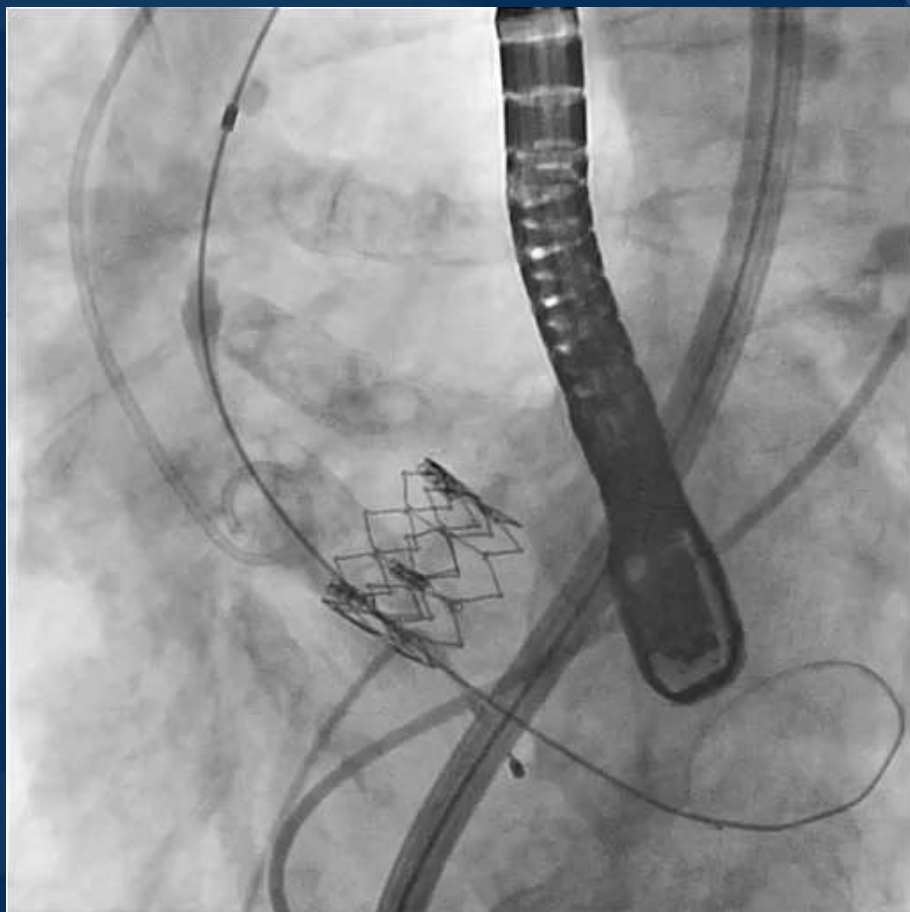
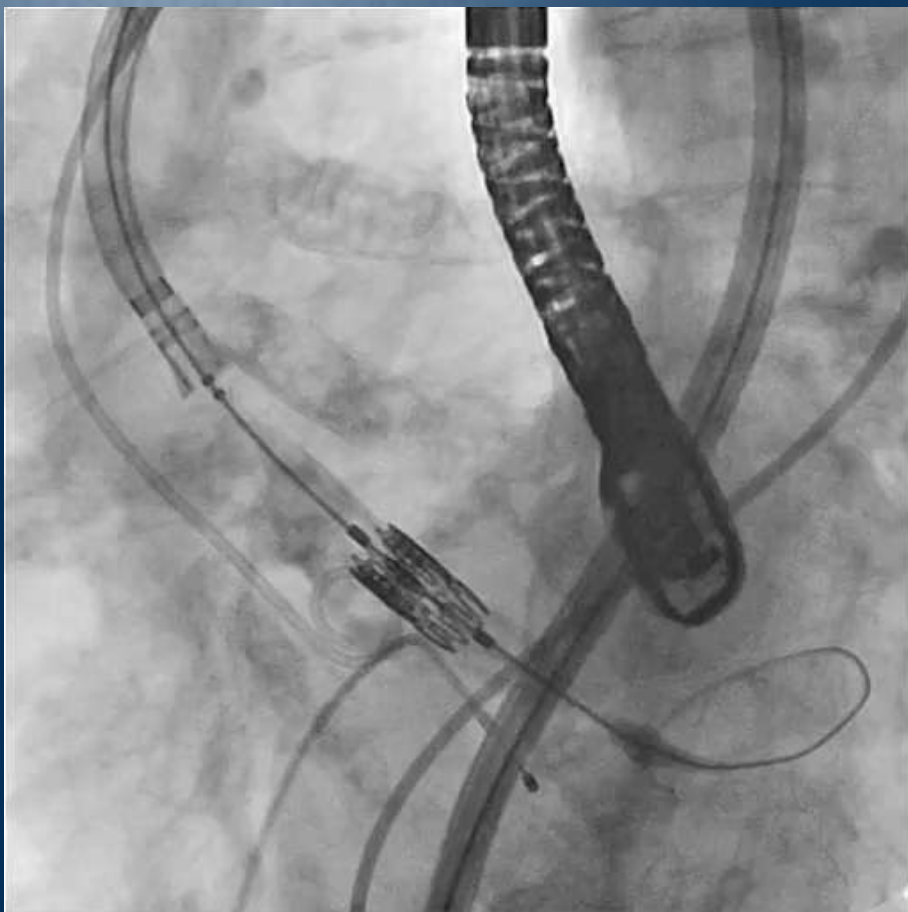


Balloon size: 20 mm



ALBERT EINSTEIN
HOSPITAL ISRAELITA

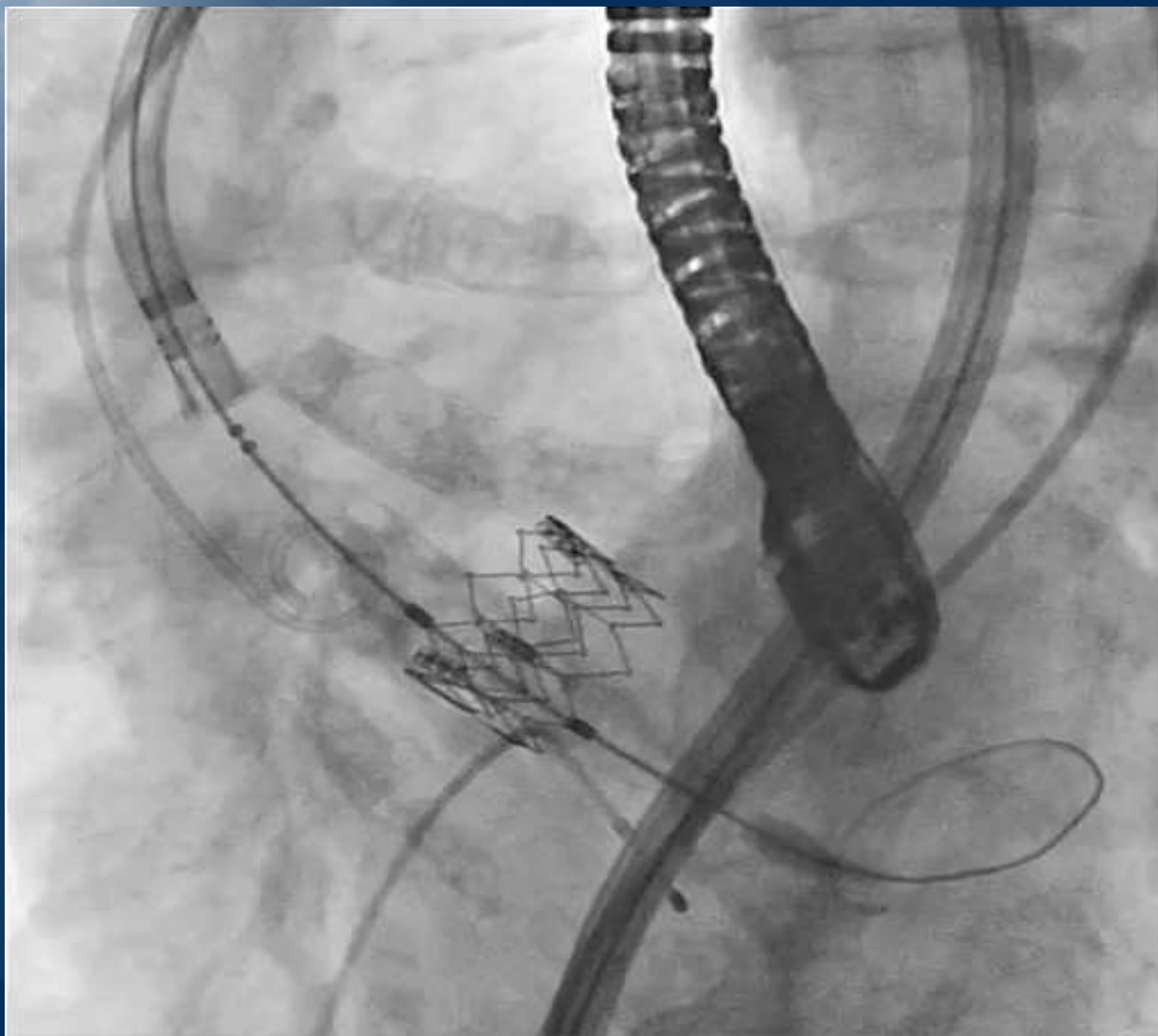
Procedure





ALBERT EINSTEIN
HOSPITAL ISRAELITA

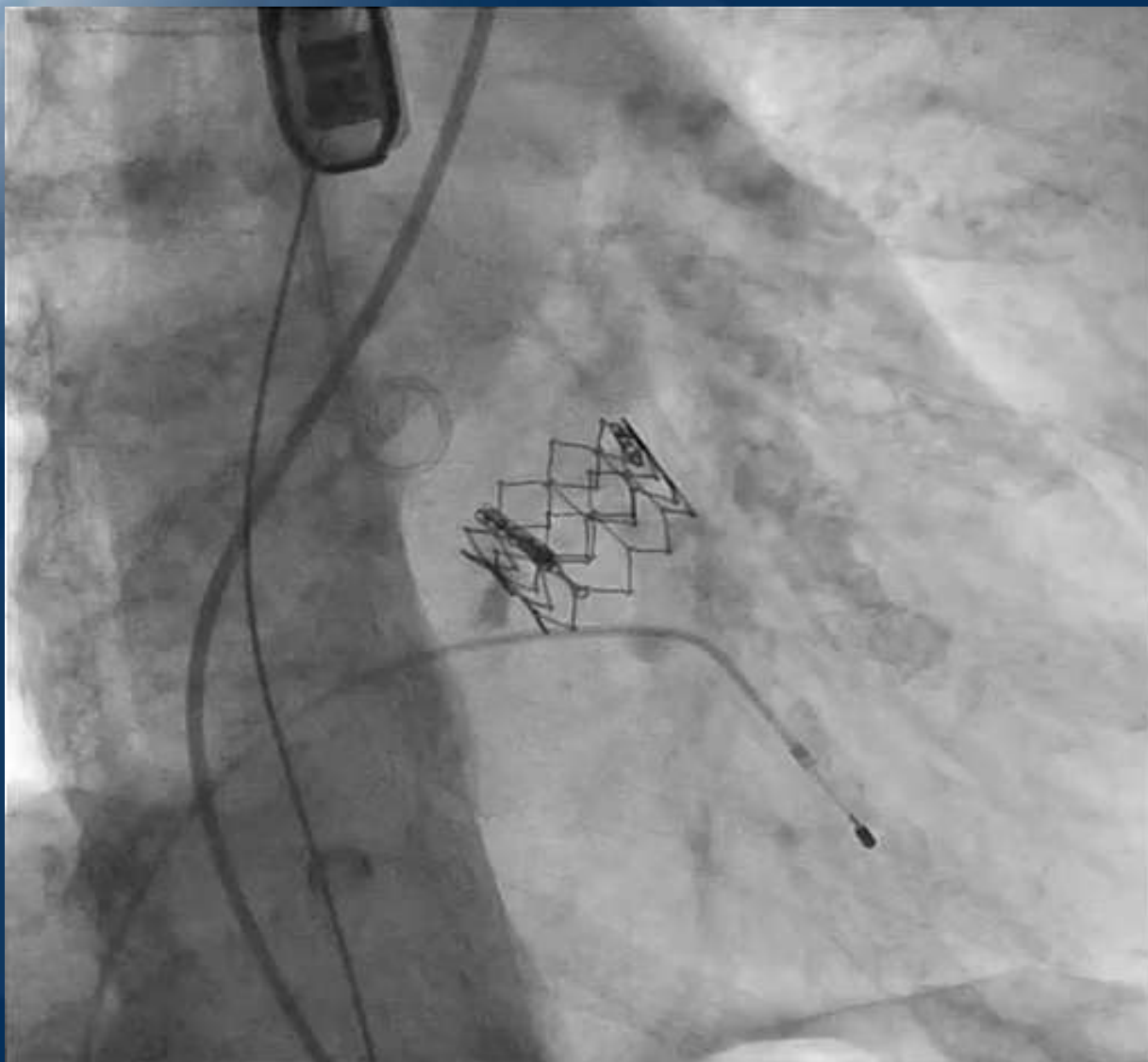
Procedure





ALBERT EINSTEIN
HOSPITAL ISRAELITA

Procedure

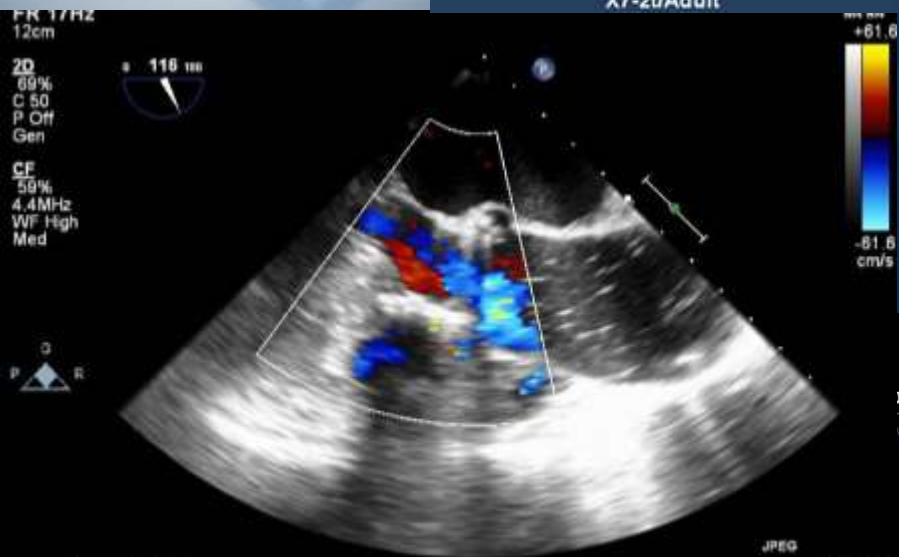



Intra-procedural TEE

06/20/2012 18:02:34 TIS0.7 MI 0.4

X7-2U/Adult

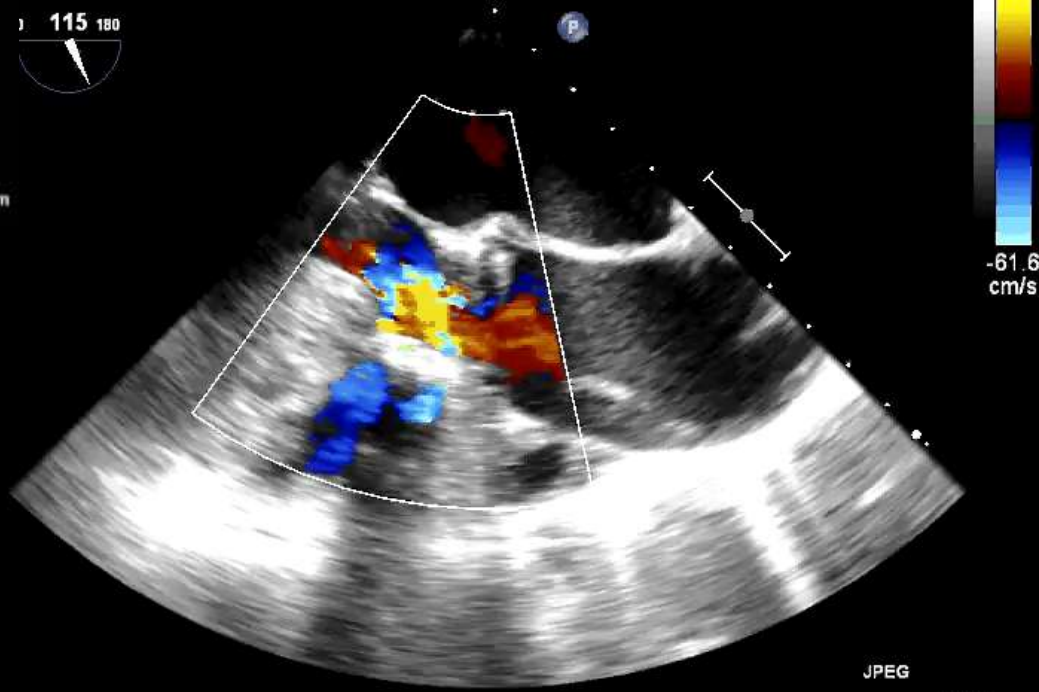


PAT T: 37.0C
TEE T: 40.3C

JPEG
105 bpm
WF High
Med



115 180



PAT T: 37.0C
TEE T: 40.5C

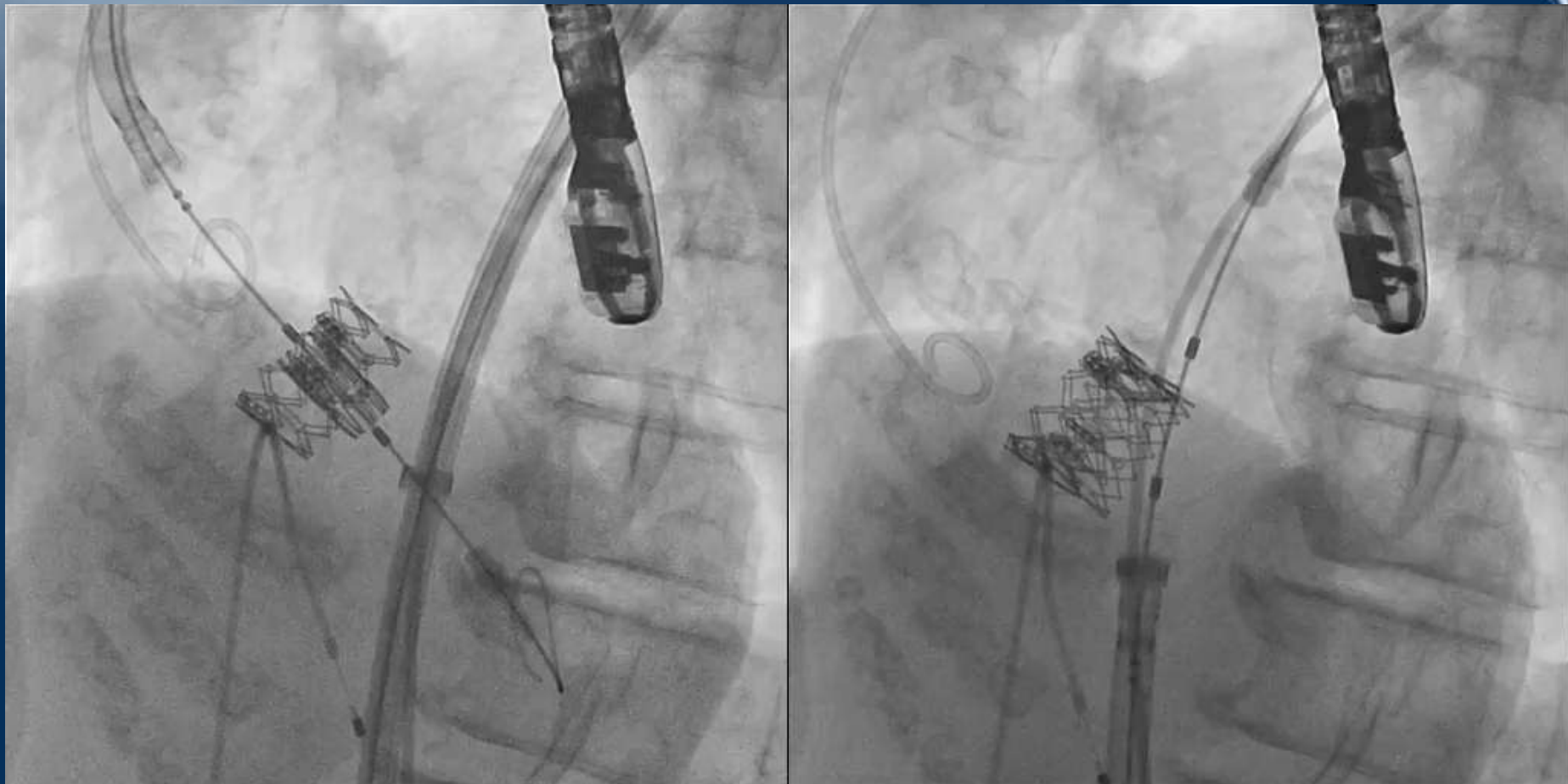JPEG

167 bpm



ALBERT EINSTEIN
HOSPITAL ISRAELITA

Procedure



Valve-in-valve: 23 mm



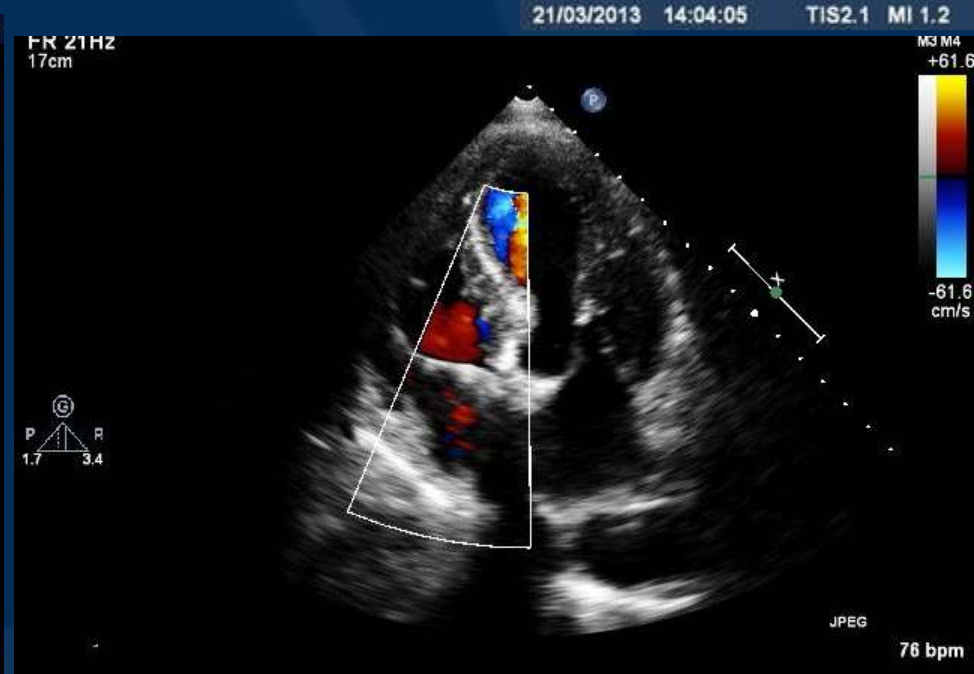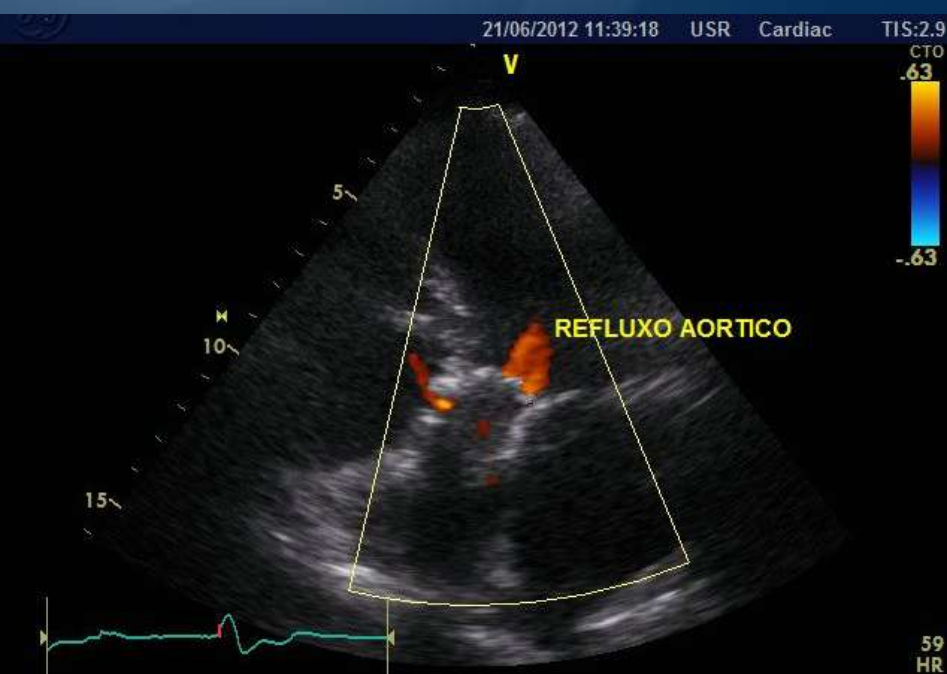
Follow-up

30 days

Functional class NYHA II

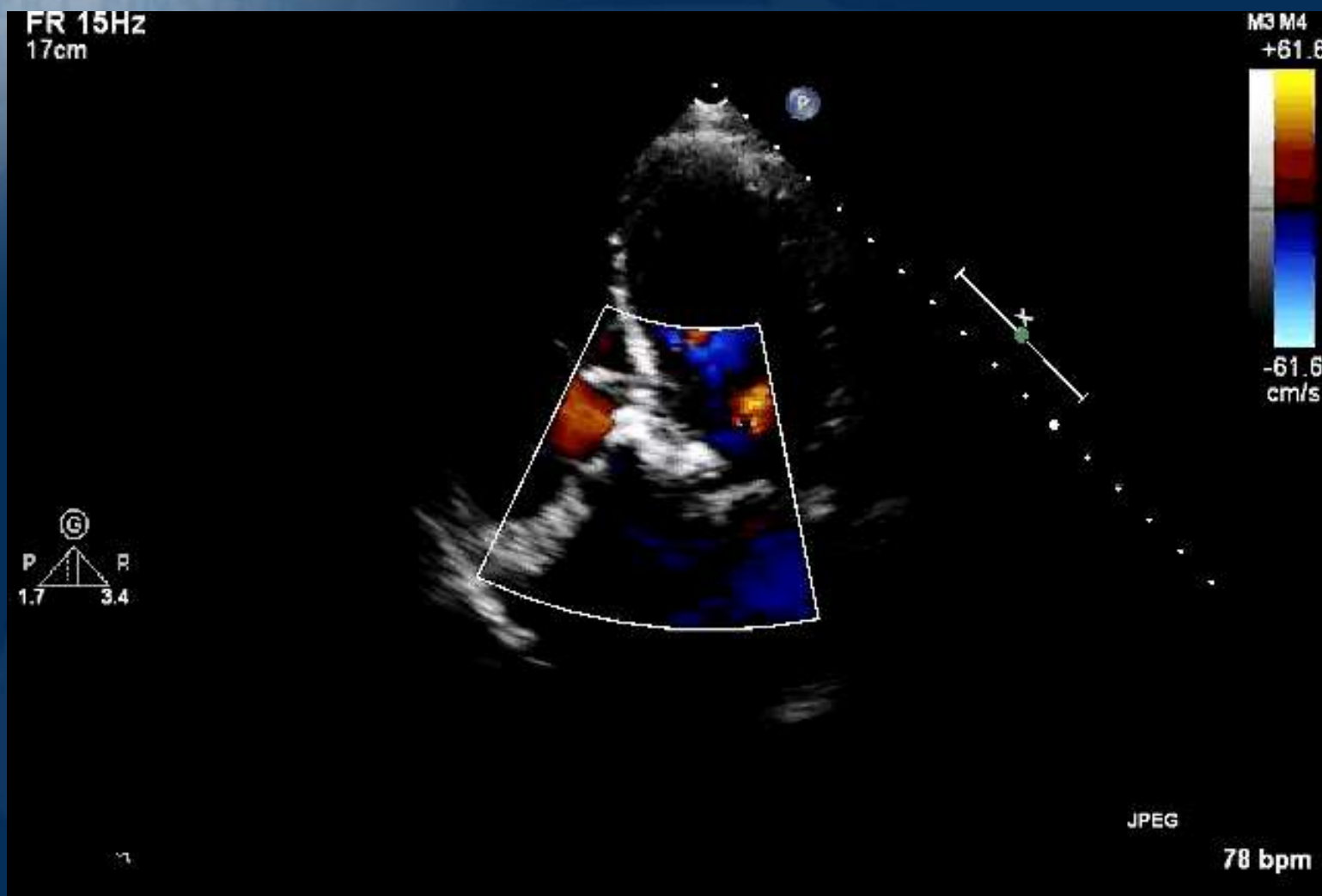8 month fu

Functional class NYHA I





TTE – 8 months





ALBERT EINSTEIN
HOSPITAL ISRAELITA

Complicações

- CIV
- 2ª Prótese
- MP Definitivo