euro PCR 2013

# Mid-term Results of Japanese Registry Study in Comparison between Everolimus-eluting Stent and Sirolimus-eluting Stent for the Bifurcation Lesion (J – REVERSE)

**Yoshinobu Murasato[1], Yoshihisa Kinoshita[2], Toshiro Shinke[3], Masahiro Yamawaki[4], Yoshihiro Takeda[5], Kenichi Fujii[6], Shin-ichiro Yamada[7], Yoshihisa Shimada[8], Takehiro Yamashita[9], Kazuhiko Yumoto[10], Masaya Arikawa[11], Yoritaka Otsuka[12] and Masaki Tanabe[13]**

**On behalf of J-REVERSE investigators**

1. New Yukuhashi Hospital, 2. Toyohashi Heart Center, 3. Kobe University, 4. Saiseikai Yokohama Eastern Hospital, 5. Rinku General Medical Center, 6. Hyogo Medical University, 7. Himeji Cardiovascular Center, 8. Shiroyama Hospital, 9. Hokkaido Ono Hospital, 10. Yokohama Rosai Hospital, 11. Oita medical Center, 12. Fukuoka Wajiro Hospital, 13. Second Okamoto Hospital

May 23, 2013, Paris

euro PCR 2013

# Disclosure

- Financial study support
  Abbott Vascular, Cordis, Orbus Neich, Kaneka

- Registered in Clinical Trials Government (NCT01266239)

# Proximal stent deformation induced by kissing balloon (KB) inflation



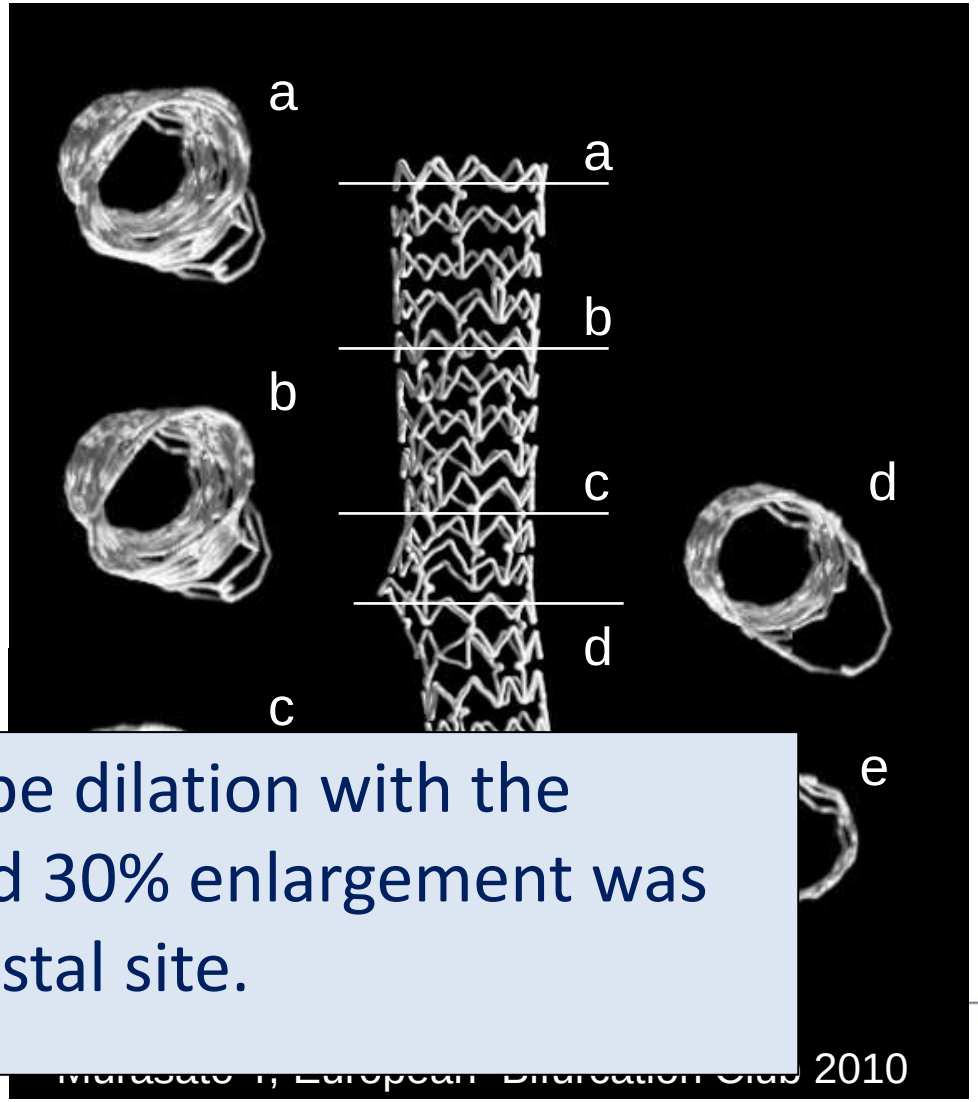


KB inflation caused oval-shape dilation with the eccentricity value of 0.75 and 30% enlargement was obtained compared to the distal site.

Guérin P. Circ Cardiovasc Interv, 2010, 3, 120

euro PCR 2013

# Impact of symmetricity

SEI: stent eccentricity index
NUS: neointima unevenness score

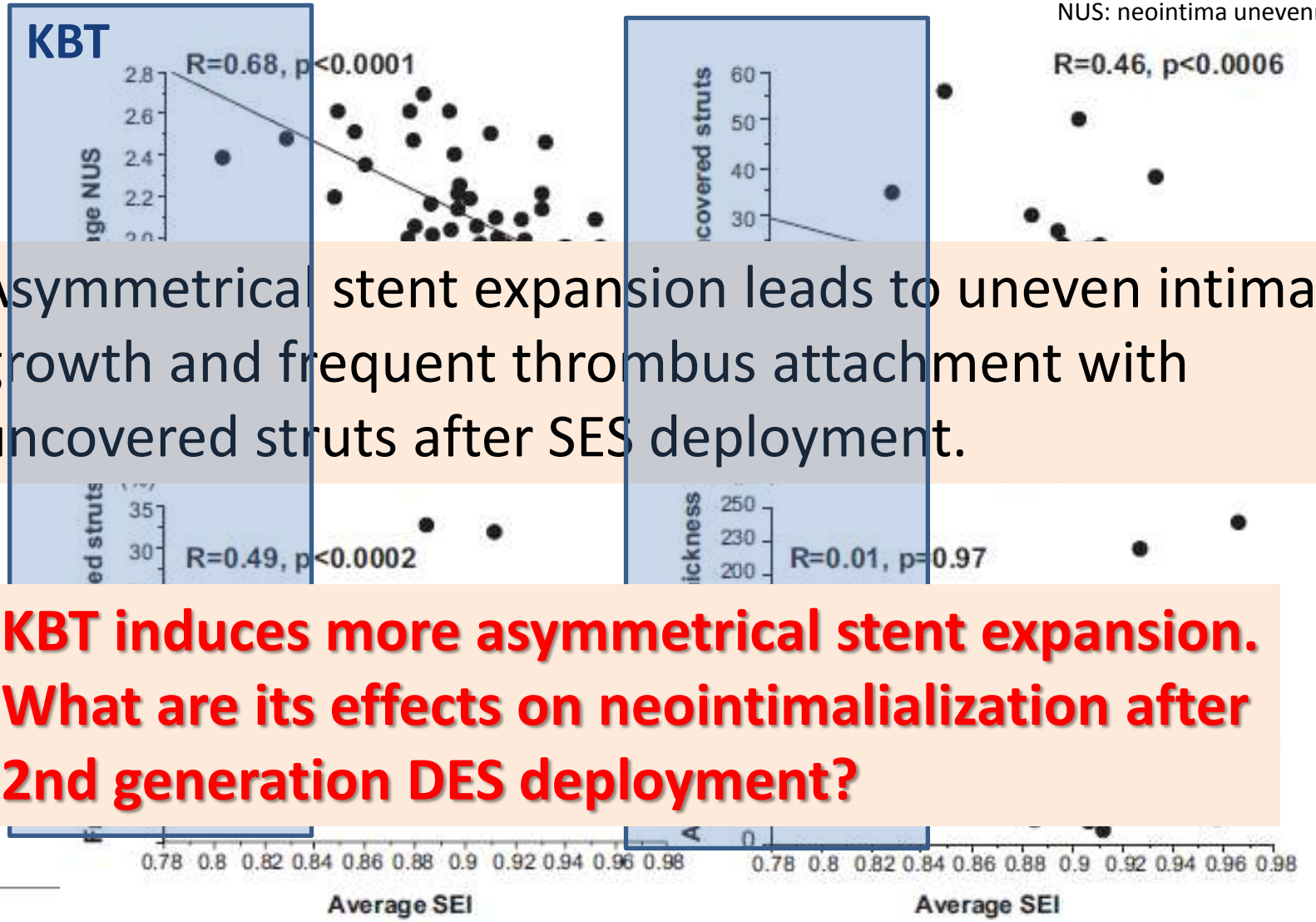


Asymmetrical stent expansion leads to uneven intimal growth and frequent thrombus attachment with uncovered struts after SES deployment.

**KBT induces more asymmetrical stent expansion. What are its effects on neointimalialization after 2nd generation DES deployment?**

Otake H, JACC Intrv, 2009, 2,459

euro PCR 2013

# Purpose of the study

**Study-1**

To compare acute phase and mid-term outcome of provisional stenting between EES and SES deployment under the IVUS guidance.

**Study-2**

To investigate whether asymmetrical expansion in the bifurcation lesion leads to more disturbance of neointimalization.

# Endpoints

**Study-1**

Major adverse cardiac events (MACE) during 9-mo F/U period
Death, Myocardial infarction, Target lesion revascularization (TLR), Target vessel revascularization (TVR), Stent thrombosis

**Study-2**

OCT abnormal findings (unevenness of intimal growth, uncovered struts, thrombus attachment)

# Study design

Multicenter
Prospective registry
study

299pts, 302 lesions

Bifurcation lesion
Provisional stenting

≧75% stenosis in MV with /wo
SB stenosis (≧75% )
Size: MV ≧ 2.5mm
SB ≧ 2mm
Lesion length < 46mm

EES 239 lns
(Xience V / Promus)

SES 60 lns
(Cypher select plus)

Exclusion
3pts,
3lns

129 lns
KBT (+)

110 lns
KBT (-)

34 lns
KBT (+)

26 lns
KBT (-)

| | Before PCI | Post PCI | 1Mo | 9Mo | 3Y |
|---|---|---|---|---|---|
| EES | | | | | |
| SES | | | | | |
| CAG | + | + | | + | + |
| IVUS | + | + | | | |
| OCT | | | | + (n=100) | |
| ECG, blood sample | + | + | + | + | + |
| Clinical event | + | + | + | + | + |

euro PCR 2013

# Complications: Acute phase

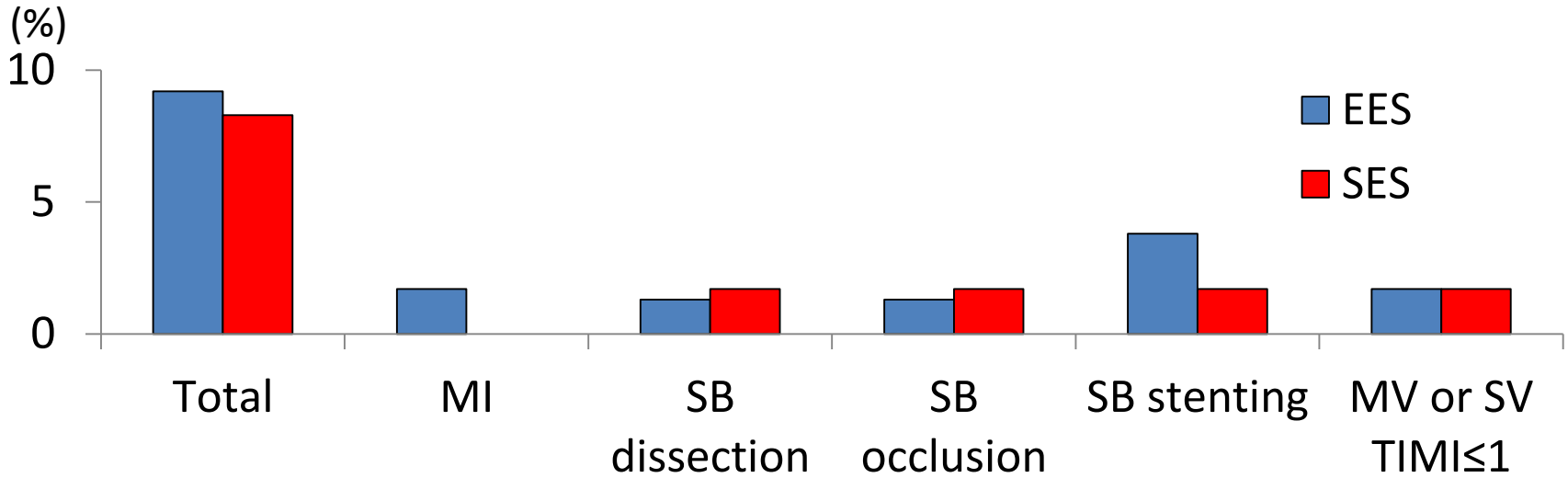


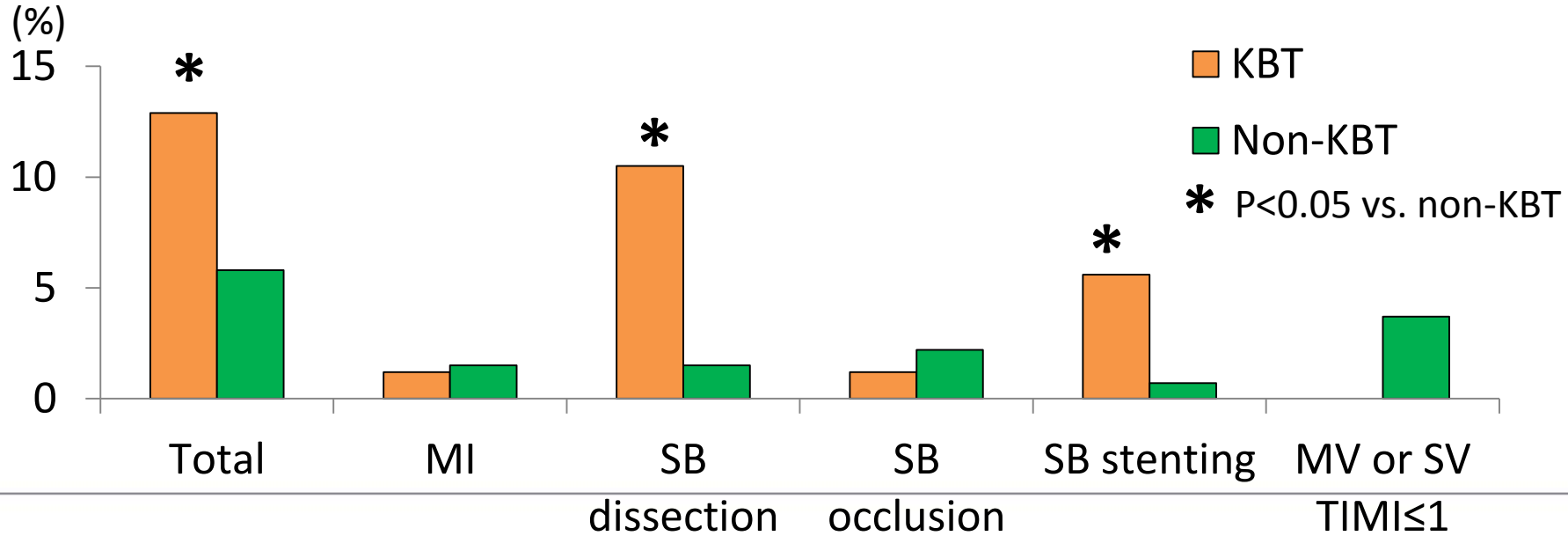

euro PCR 2013

# 9mo F/U: Major Adverse Cardiac Events (MACE)

## Restenosis in the Bifurcation

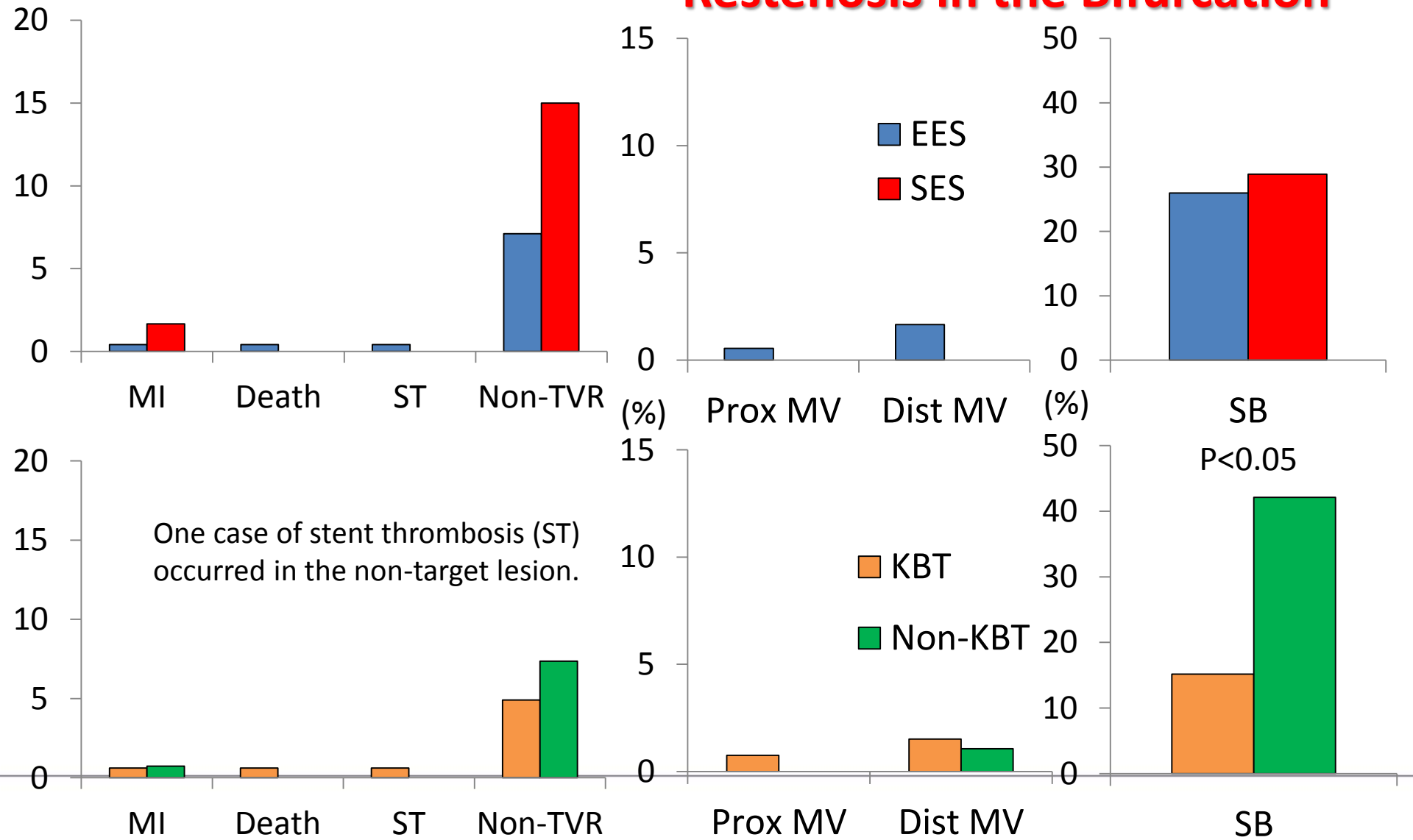

euro PCR 2013

# MACE: TLR

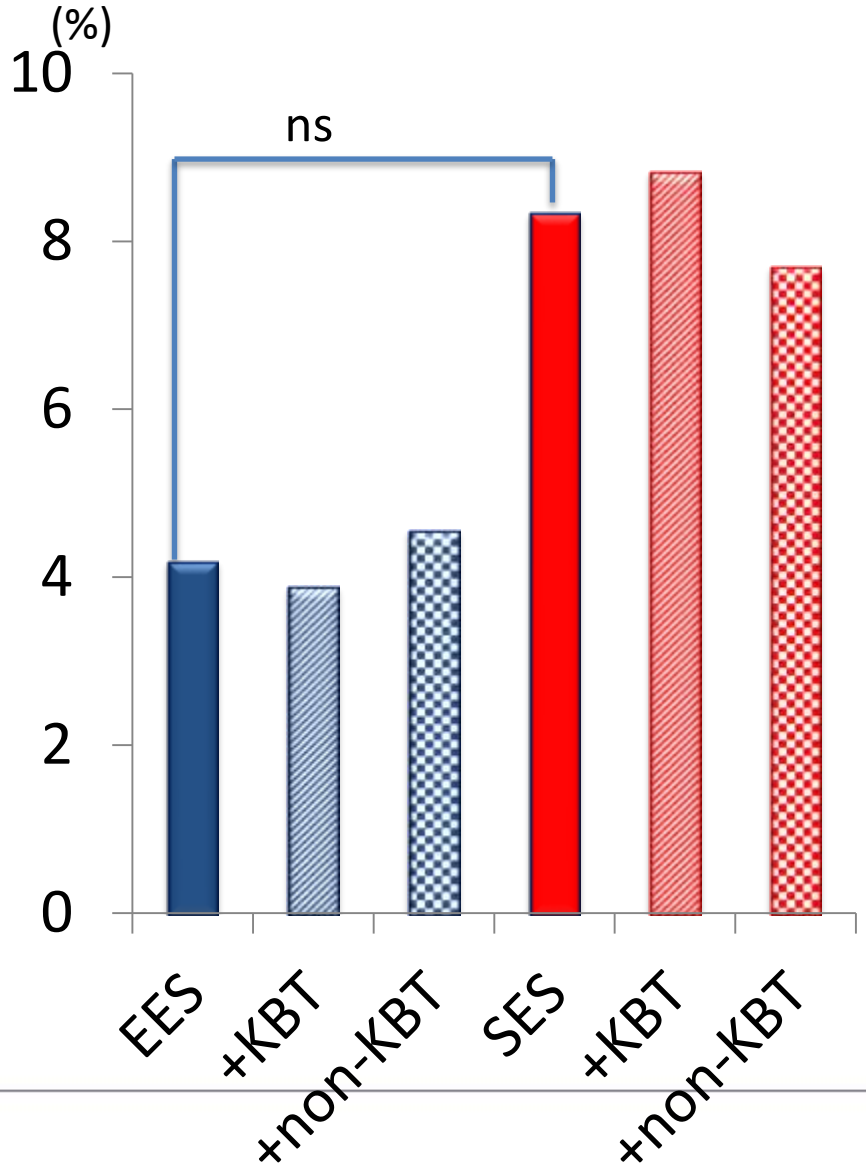


**MV edge restenosis**
**KBT 5/6, NKBT 0/7**
**(P<0.05)**

**Locatio**

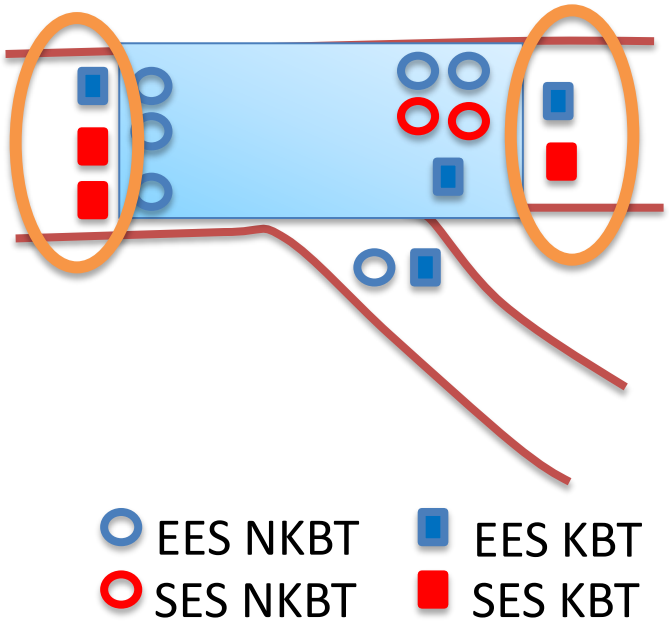


**Type of restenosis**

| | |
|---|---|
| Focal | 13 cases |
| Diffuse | 2 cases |

# QCA: KBT vs. Non-KBT

## (1) % Diameter stenosis

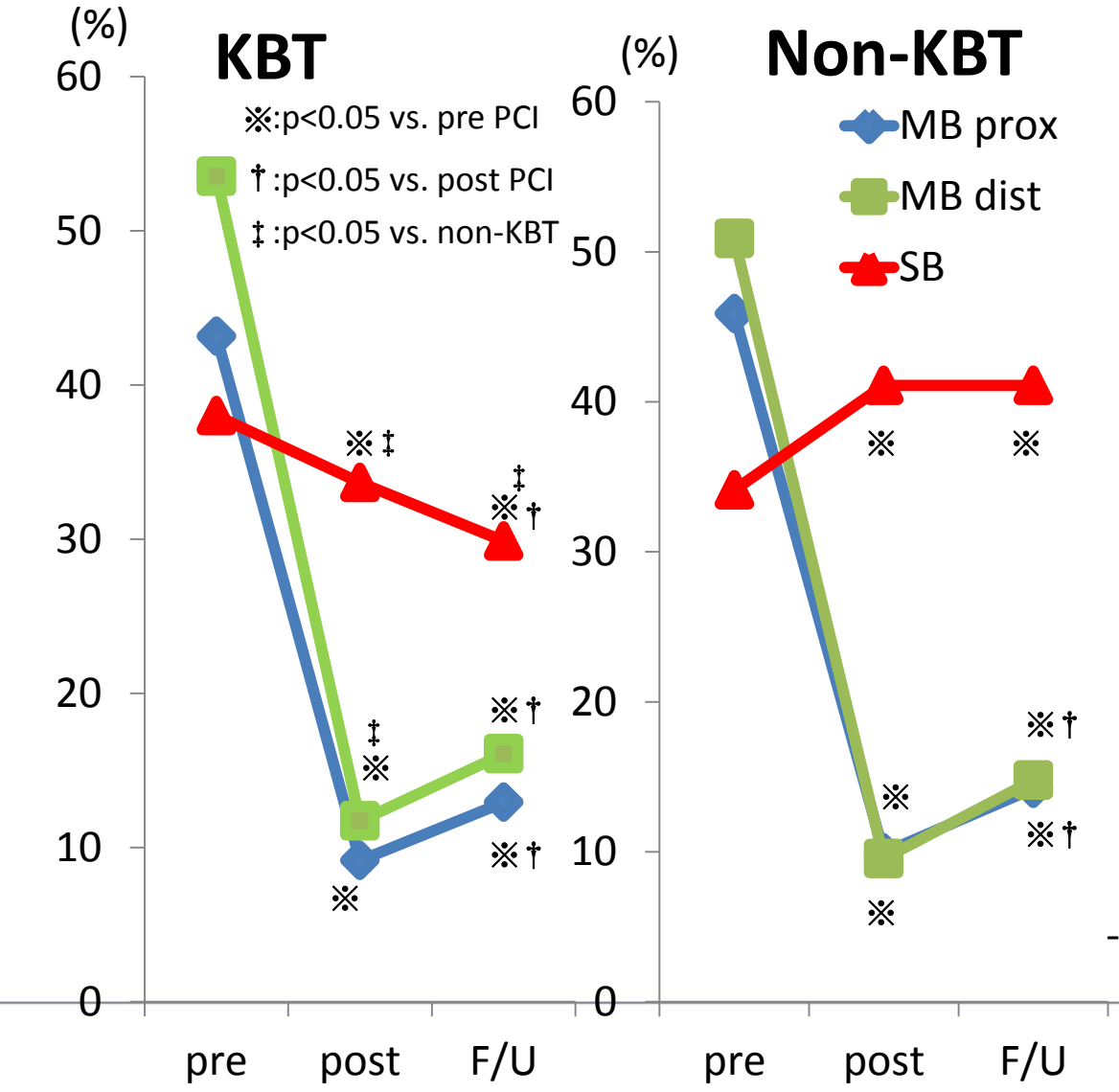


## (2) Late loss

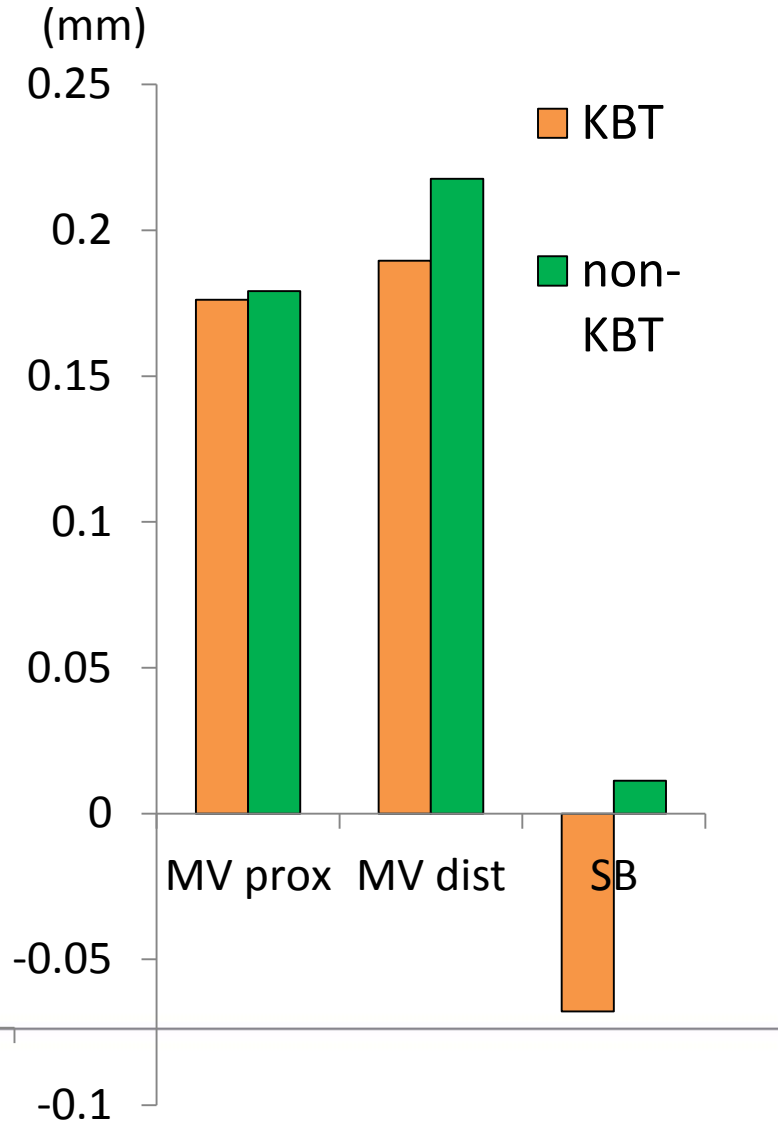

# QCU: KBT vs. Non-KBT

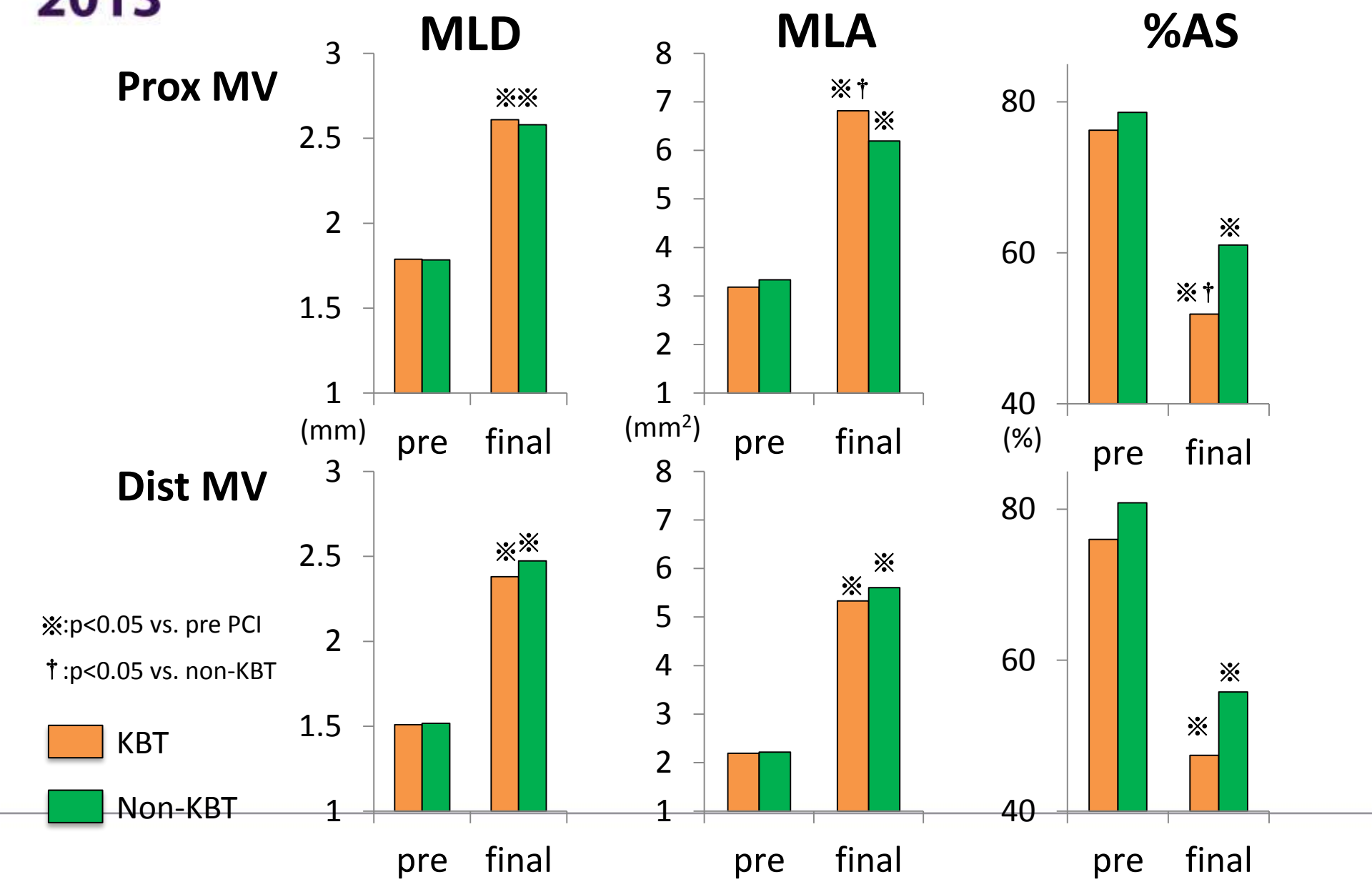

euro PCR 2013

# OCT 9mo F/U study: Interim Report

## Stent Eccentric Index (IVUS)

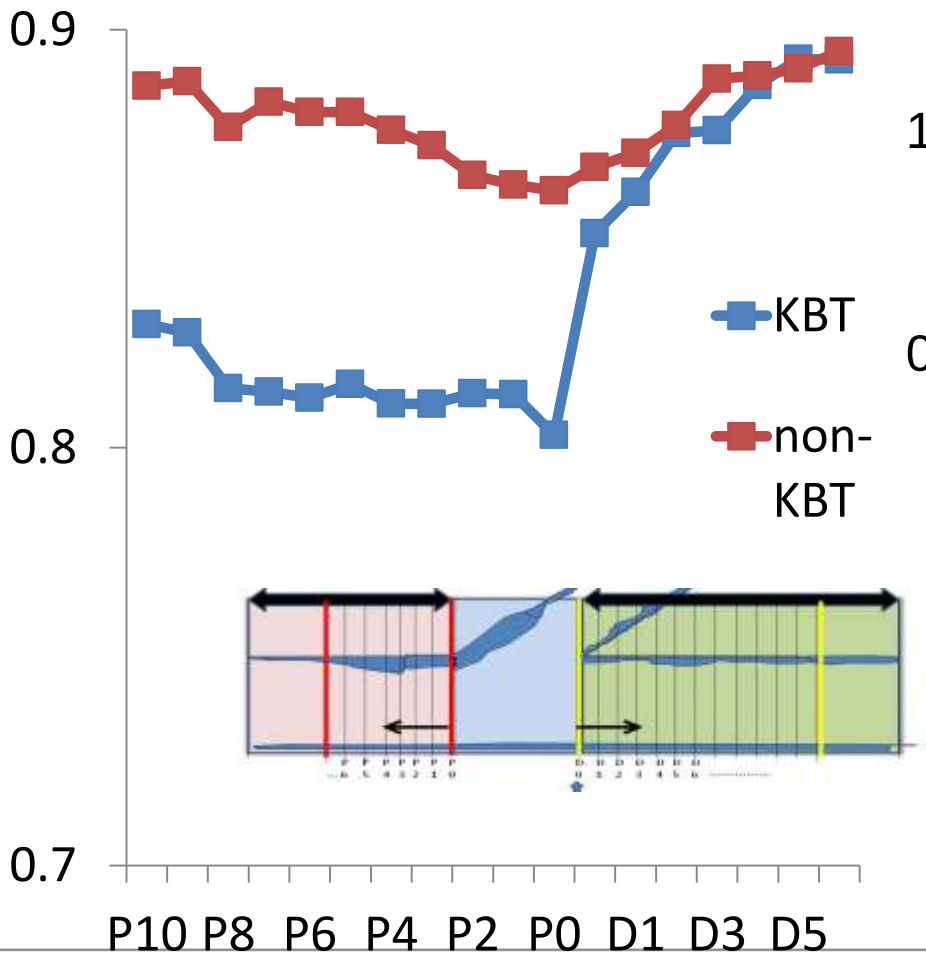


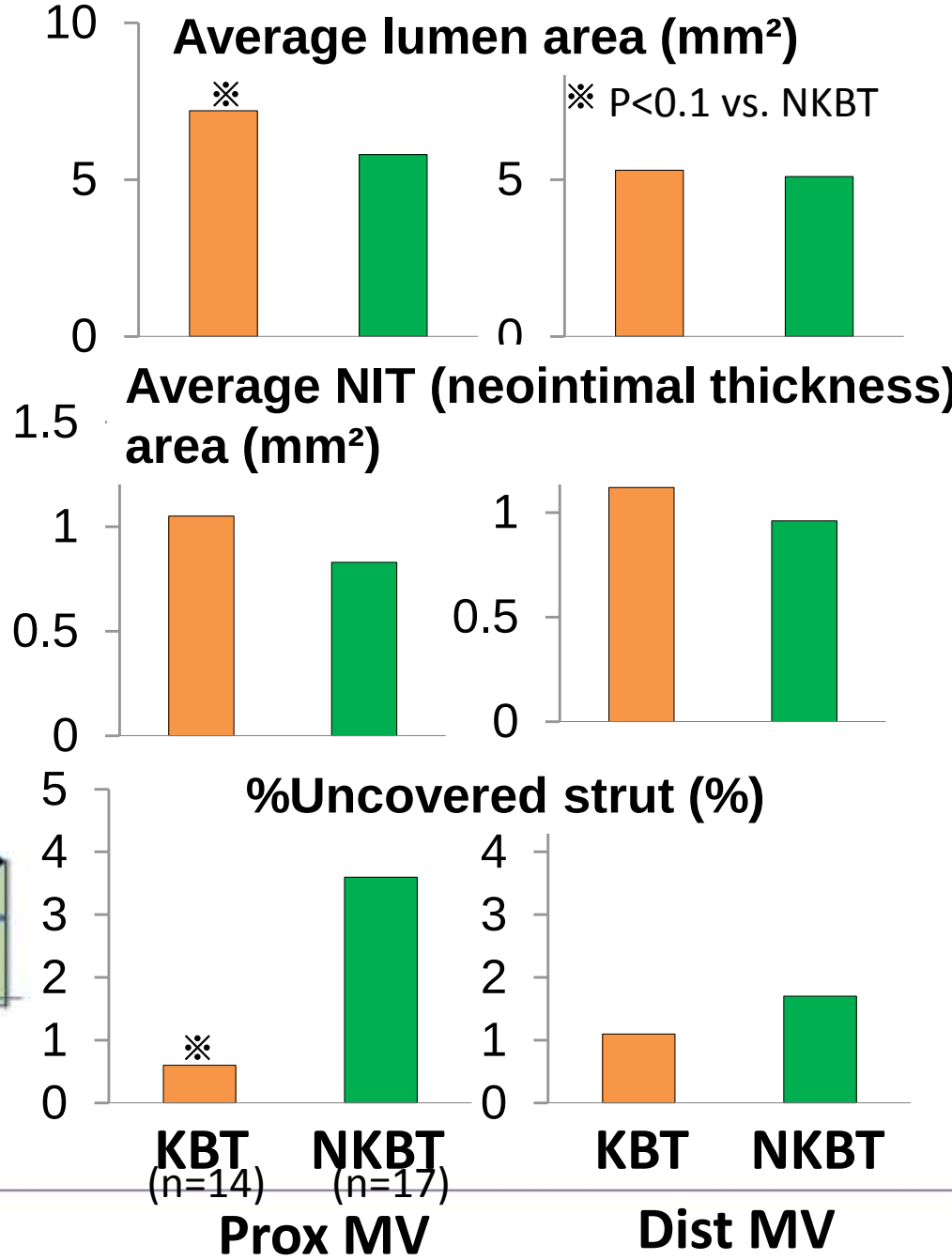

# Impact of asymmetricity on neointimalization

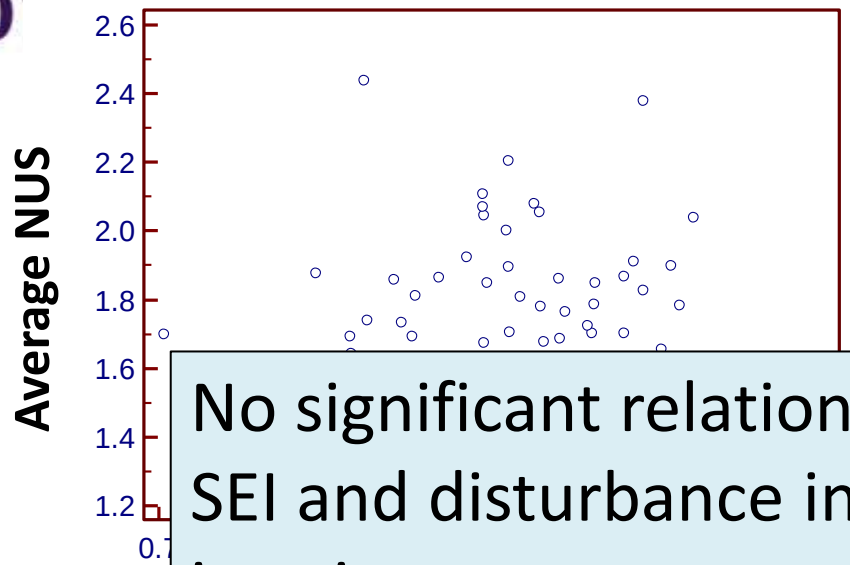


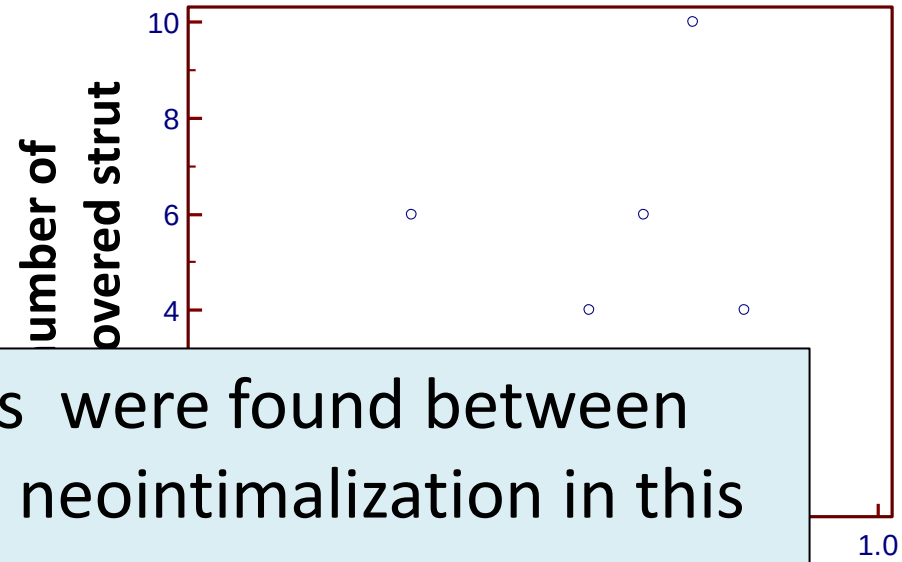


No significant relations were found between SEI and disturbance in neointimalization in this interim report.

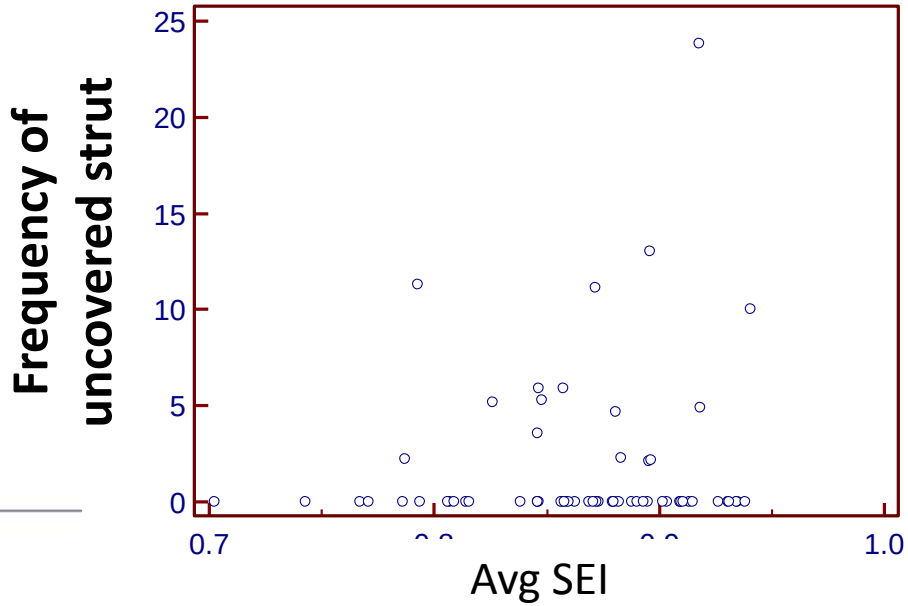


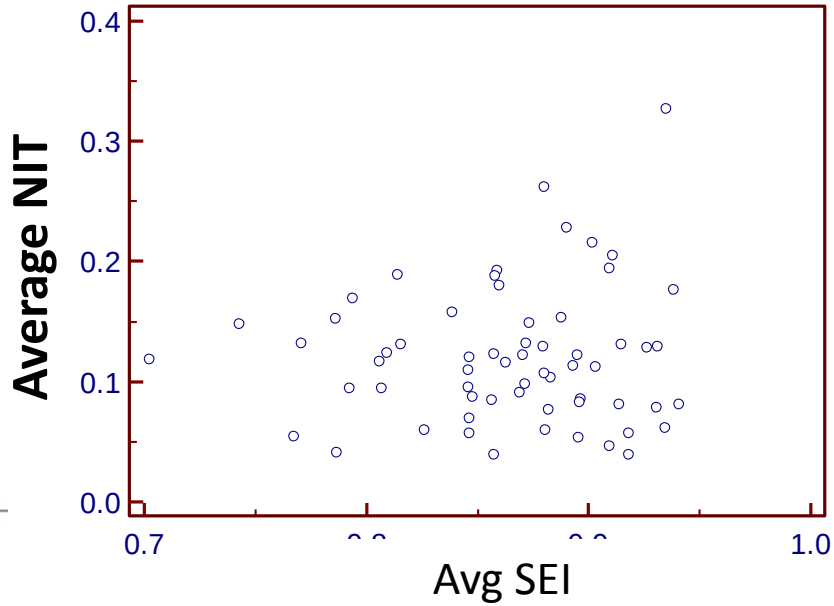

euro PCR 2013

# Conclusion

- The EES deployment under the IVUS-guidance in the coronary bifurcation lesion brought a favorable TLR rate compared to the SES.
- Although the KBT induced more SB dissection requiring stenting and asymmetrical stent expansion in the proximal MV, it maintained lower levels of SB stenosis and larger proximal MV lumen during the 9-month F/U period without any increase in MACE.
- Asymmetrical stent expansion induced by KBT did not result in more disturbance in neointimalization, which might be influenced by the improvement in malapposition or overstretch in the proximal MV.